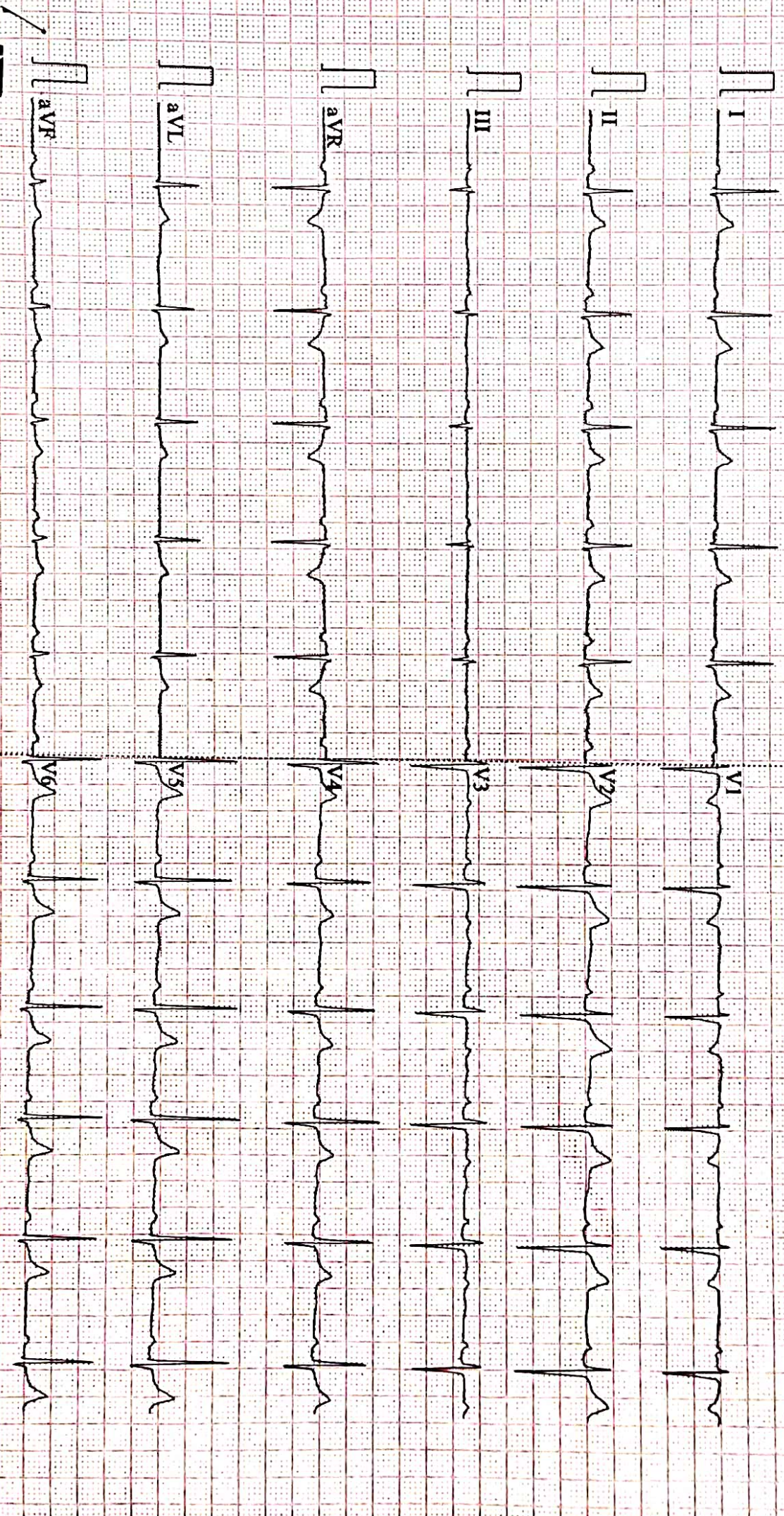


ID: 43
Meha Kumari
Female
Years

19-09-2021 10:01:48 PM
HR : 66 bpm
P : 90 ms
PR : 170 ms
QRS : 82 ms
QT/QTc : 377/397 ms
PQRST : 65/27/30 °
RV5/SV1 : 1.513/1.037 mV

Diagnosis Information:
Sinus Arrhythmia

Report Confirmed by:



0.07-100Hz AC50 25mm/s 10mm/mV 2*5.0s 666 V2.2 SEMIF V1&1 DIAGNOSTIC



ISO 9001 : 2015

AAROGYAM DIAGNOSTICS

(A UNIT OF CULPAM HEALTH CARE PVT. LTD.)

F- 41, P.C. Colony, Opp. Madhuban Complex,
Near Malahi Pakari Chowk, Kankarbagh, Patna - 20

9264278360, 9065875700, 8789391403

info@aarogyamdiagnostics.com

www.aarogyamdiagnostics.com

Name :- NEHA KUMARI
Refd by :- BOB

Age/Sex:- Yrs/F
Date :-19/09/21

Thanks for referral.

REPORT OF USG OF WHOLE ABDOMEN

- Liver** :- Enlarged in size (16.0cm) with raised echotexture. No focal or diffuse lesion is seen.
IHBR are not dilated. PV is normal in course and calibre with echofree lumen.
- G. Bladder** :- It is normal in shape, size & position. It is echofree & shows no evidence of calculus, mass or sludge.
- CBD** :- It is normal in calibre & is echofree.
- Pancreas** :- Normal in shape, size & echotexture. No evidence of parenchymal / ductal calcification is seen. No definite peripancreatic collection is seen.
- Spleen** :- Normal in size with normal echotexture. No focal lesion is seen. No evidence of varices is noticed.
- Kidneys** :- Both kidneys are normal in shape, size & position. Sinus as well as cortical echoes are normal. No evidence of calculus, space occupying lesion or hydronephrosis is seen.
Right Kidney measures 8.9x4.6cm and Left Kidney measures 9.3x4.8cm.
- Ureters** :- Ureters are not dilated.
- U. Bladder** :- It is echofree. No evidence of calculus, mass or diverticulum is seen.
- Uterus** :- Normal in size and anteverted in position with normal myometrial echotexture and endometrial thickness.
- Ovaries** :- Both ovaries show normal echotexture and follicular pattern.
No pelvic (POD) collection is seen.
- Others** :- No ascites or abdominal adenopathy is seen.
No free subphrenic / basal pleural space collection is seen.

IMPRESSION:- *Grade I fatty Liver.*

Dr. Anju Kumari
MBBS, DMRD (Radio-Diagnosis)
Consultant Radiologist