



# PANACEA HOSPITAL

B 36/44 F.K KABIR NAGAR, DURGAKUND  
TOLLFREE NO-18001233070. Whatsapp No - 8795832852  
www.paire.org  
panaceaquery@gmail.com|panceahospital@gmail.com



## OP Slip

Print Date : 15-Nov-2024 11:45AM



UHID No :-	UD-24250004380	OP No :-	OP-24250013052	OP Date :-	15 Nov 2024 11:44AM
Patient Name :-	Mr - SHIV PRATAP SINGH	Age/Sex :-	28 Y/Male	Mobile No :-	9761884970
Father :-		Department :-	GENERAL MEDICINE		
Pay Type :-	Cr	Consultant :-	Dr Pallavi Mishra (MBBS,MD,MBBS)		
Token No :-	NOR - 6	Paid/Bal :-	0.00 /1000.00		
Patient Type :-	Normal				
Address :-	KORARI SARHAD PILAKHTARFATEH 2051147, Firozabad, Firozabad				

BP :- 117/75 **Rx**  
 height :- 177  
 Weight (kg) :- 65kg  
 BMI :- 20.74

PR- 95  
 SpO2 98+  
~~PR 88~~  
 PEF 350  
 VC 34  
 WC- 83  
 CH 88

Rx  
 Tab Montemans FX HS  
 Tab Mucinac 600 BD  
 Tab Nutripure B12 OD  
 Pow Avacal 60 SUN/TNU

RIA 1 month

Printed By : Ms. Anjali Prajapati  
Created By : Ms. Anjali Prajapati

*Dr. Pallavi Misra*  
Dr. Pallavi Misra  
MBBS, MD (General Medicine)  
MCI Reg. No. 52033



# PANACEA HOSPITAL

B 36/44 F.K KABIR NAGAR, DURGAKUND  
TOLLFREE NO-18001233070. Whatsapp No - 8795832852  
www.paire.org  
panaceaquery@gmail.com|panaceaahospital@gmail.com



## OP Slip

Print Date : 15-Nov-2024 11:46AM



<b>UHID No</b> :- UD-24250004380	<b>OP No</b> :- OP-24250013055	<b>OP Date</b> :- 15 Nov 2024 11:46AM
<b>Patient Name</b> :- Mr - SHIV PRATAP SINGH	<b>Age/Sex</b> :- 28 Y/Male	<b>Mobile No</b> :- 9761884970
<b>Father</b> :-	<b>Department</b> :- OPHTHALMOLOGY	
<b>Pay Type</b> :- Cr	<b>Consultant</b> :- Dr SANTOSH VERMA (MBBS,MS)	
<b>Token No</b> :- NOR - 5	<b>Paid</b> :- 0.00	
<b>Patient Type</b> :- Normal		
<b>Address</b> :- KORARI SARHAD PILAKHTARFATEH 2051147, Firozabad, Firozabad		

BP :- 117/75 **Rx**  
 height :- 177  
 Weight (kg) :- 65  
 BMI :- 20.74

PR - 95  
 SpO2 - 98  
 PEFr - 350  
 NC - 34  
 WC - 83  
 CH - 88

VA  $\left\{ \begin{array}{l} 6/6' \\ 6/6' \end{array} \right.$

Near  $\left\{ \begin{array}{l} N6 \\ N6 \end{array} \right.$

BE. Fundus. WNL

Locally BE.

I.G. Clear Eye - 50s.  
 000

Dr. SANTOSH VERMA  
 MBBS, MS (Ophthalmologist)  
 MCI Reg. No. 09-34327

Printed By : Ms. Anjali Prajapati  
 Created By : Ms. Anjali Prajapati



# PANACEA HOSPITAL

B 36/44 F.K KABIR NAGAR, DURGAKUND  
TOLLFREE NO-18001233070. Whatsapp No - 8795832852  
www.pire.org  
panaceaquery@gmail.com|panaceahospital@gmail.com



## OP Slip

Print Date : 15-Nov-2024 11:45AM



UHID No :- UD-24250004380	OP No :- OP-24250013054	OP Date :- 15 Nov 2024 11:45AM
Patient Name :- Mr - SHIV PRATAP SINGH	Age/Sex :- 28 Y/Male	Mobile No :- 9761884970
Father :-	Department :- DERMATOLOGY	
Pay Type :- Cr	Consultant :- Dr DR ASHUTOSH MISHRA (MBBS,MD)	
Token No :- NORL - 6	Paid :- 0.00	
Patient Type :- Normal		
Address :- KORARI SARHAD PILAKHTARFATEH 2051147, Firozabad, Firozabad		

BP :- 117/75 **Rx**  
 height :- 177  
 Weight (kg) :- 65  
 BMI :- 20.74

PR - 95  
 SpO2 - 98  
 NC - 34  
 WC - 83  
 CH - 88  
 PEFr - 350

*Ads @ retel sarhad*

*R*  
*NO. 7 humer skin.*

*Bilastin 20mg tabs  $\rightarrow$  2 today*  
*. Neem soap*  
*. Blood pure water  $\rightarrow$  2 day*



Printed By : Ms. Anjali Prajapati  
Created By : Ms. Anjali Prajapati



# PANACEA HOSPITAL

B 36/44 F.K KABIR NAGAR, DURGAKUND  
TOLLFREE NO-18001233070. Whatsapp No - 8795832852  
www.paire.org  
panaceaquery@gmail.com|panceahospitalit@gmail.com



## OP Slip

Print Date : 15-Nov-2024 11:45AM



UHID No :- UD-24250004380	OP No :- OP-24250013053	OP Date :- 15 Nov 2024 11:45AM
Patient Name :- Mr - SHIV PRATAP SINGH	Age/Sex :- 28 Y/Male	Mobile No :- 9761884970
Father :-	Department :- DENTAL	
Pay Type :- Cr	Consultant :- Dr SHRUTI MISHRA (AA)	
Token No :- NOR - 6	Paid :- 0.00	
Patient Type :- Normal		
Address :- KORARI SARHAD PILAKHTARFATEH 2051147,Firozabad,Firozabad		

BP :- 117/75  
 height :- 177  
 Weight (kg) :- 65  
 BMI :- 20.74  
 PR - 95  
 SpO2 - 98  
 MC - 34  
 WC - 83  
 CH - 88  
 PFFR - 350

**Rx** c/c => patient came for routine dental check up.  
 o/e => stain/calculus => ++/++  
 P/p => chronic gen gingivitis

*Shruti*  
**Dr. SHRUTI MISHRA**  
 BDS, (DENTIST)  
 MCI Reg. No. (A-09784)

Printed By : Ms. Anjali Prajapati  
 Created By : Ms. Anjali Prajapati



# PANACEA HOSPITAL



*A shelter for many hearts A Home for many lives*  
 (An ISO 9001:2008 Certified Organisation)  
 Lab Attached with CMC Under EQAS Scheme

Dept. of Radiodiagnosis - 32 Slice CT Scan, 3D/4D USG, 2D ECHO, Colour Doppler, Intervention Procedures, Digital X-Ray

NAME: SHIV PRATAP SINGH

AGE/SEX: 28YRS/MALE

REF. DR. DR. ASHUTOSH MISHRA (MD)

DATE: 15/11/2024

## Echo - Cardiography

MITRAL VALVE Doppler	AML - normal morphology MV Flow - E - 0.5 A-0.4 E/A=1.26	PML - normal morphology MVA - 3.0 cm <sup>2</sup> Mitral Regurgitation - No
TRICUSPID VALVE Doppler	Normal TV Flow - No	Tricuspid Regurgitation - No
PULMONARY VALVE Doppler	Normal PV Flow - No	Pulmonary Regurgitation - No
AORTIC VALVE Doppler	Trileaflet-No AV Flow - no	Aortic Regurgitation - No
MEASUREMENT	Aorta - 24.0 (20-38) mm IVS ed - 8.0 (6-12) mm LVID ed - 33.1 (35-55) mm LVPW ed - 12.0 (6-12) mm OA - 7 (>5) mm	LA - 29.7 (24-32) mm IVS es - 10.9 (6-12) mm LVID es - 20.6 (24-40) mm LVPW es - 15.4 (6-12) mm EPSS - 4 (<9) mm

**CONCLUSION** All cardiac chamber dimensions are WNL  
 No valvular abnormalities  
 Good LV systolic function present Modified Simpson's method (4C, 2C) (LVEF-69%)  
 No diastolic dysfunction present (E/A = 1.26)  
 No pericardial effusion  
 No RWMA  
 Intact IAS / IV  
 No PAH  
 No intra cardiac mass /thrombus /vegetation

**IMPRESSION** Normal Echocardiogram

*Nimi Mishra*  
 Nimi Mishra  
 Physician Assistant  
 (PIRE)

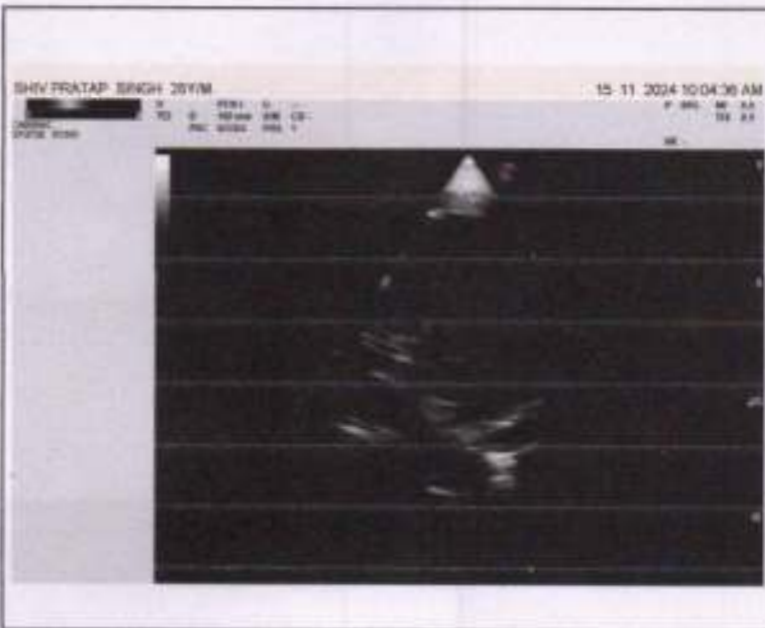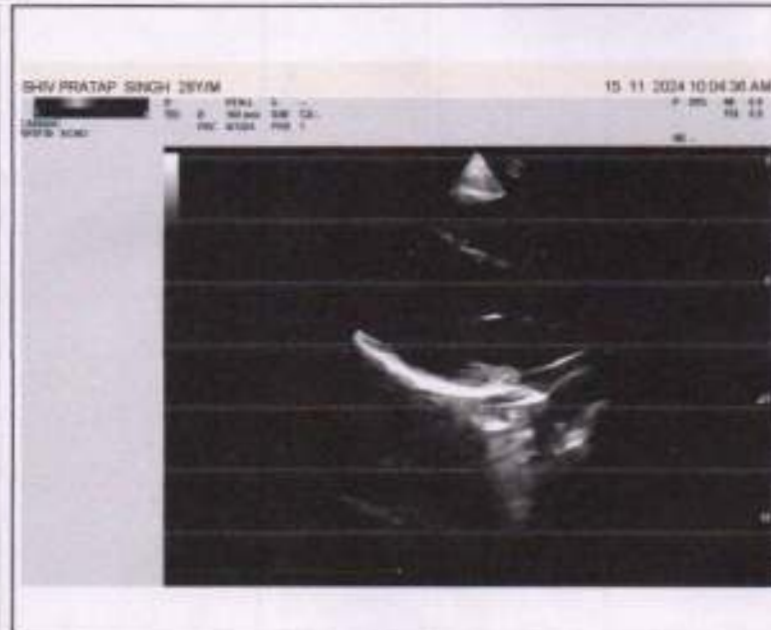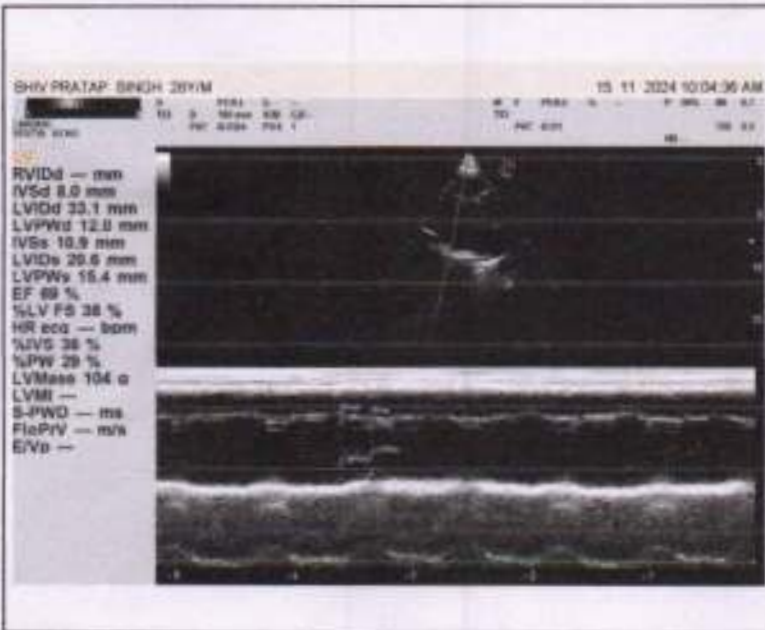
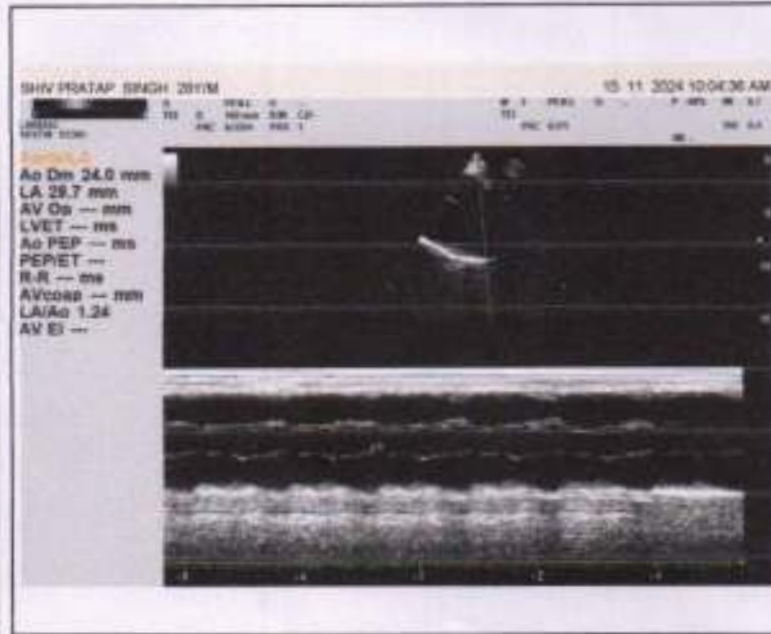
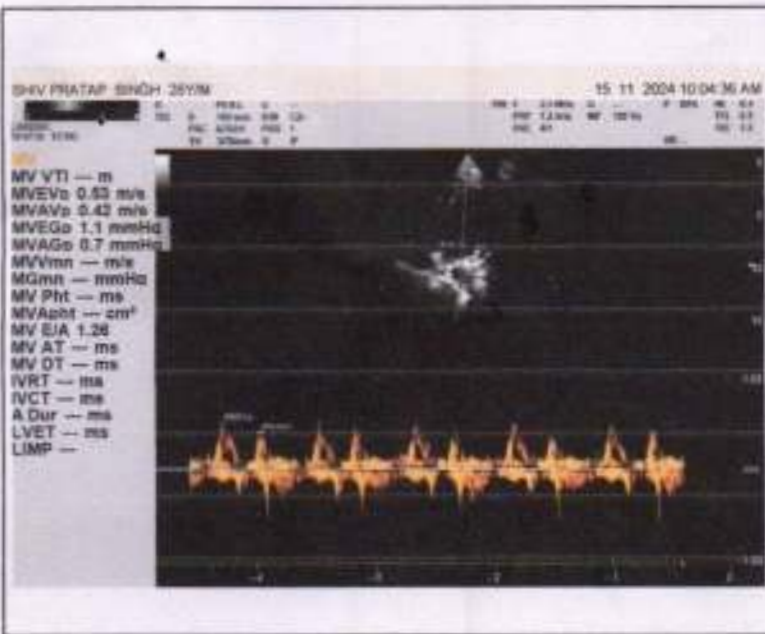
*Dr. Pallavi Mishra*  
 Dr. Pallavi Mishra  
 Echocardiography Specialist, MBBS  
 MBBS, MD (General Medicine)  
 MCT Reg. No. 52033

Disclaimer: This report is not valid for Medical or Judicial Purpose. Radiological diagnosis is solely interpretation of images produced by tissue & may not be always conclusive.

Address : B36/44 B4 Kabir Nagar (Near Sanjay Shiksha Niketan), Durgakund, Varanasi

Mobile : 9554572190 / 9453837595 / Recpn, 9389994334

Email : dramishra@gmail.com, drpallaviojha@gmail.com, Website : www.pire.org





# PANACEA HOSPITAL



*A shelter for many hearts A Home for many lives*  
(An ISO 9001:2008 Certified Organisation)  
Lab Attached with CMC Under EQAS Scheme

Dept. of Radiodiagnosis - 32 Slice CT Scan, 3D/4D USG, 2D ECHO, Colour Doppler, Intervention Procedures, Digital X-Ray

PATIENT NAME	SHIV PRATAP SINGH	AGE/SEX	28YRS/M
REF. BY DR.	DR. ASHUTSOH MISHRA	DATE	15/11/2024

## X-RAY CHEST (AP VIEW)

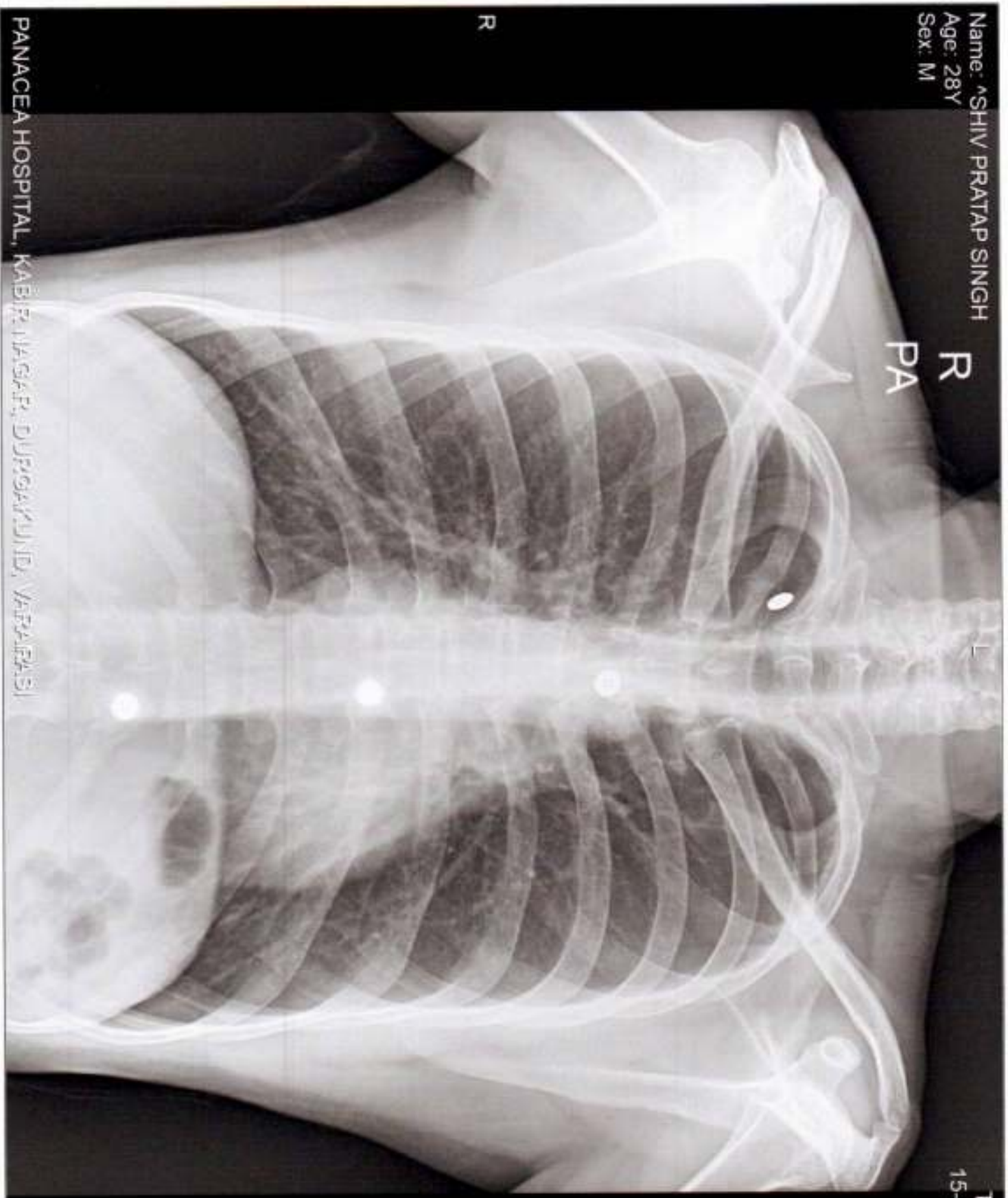
- Lung fields show hazy opacities in both parahilar, basal zone with mild prominent brochopulmonary markings.
- Rest of the bilateral lung fields appear normal.
- Trachea and mediastinum appear normal in position.
- Both hila appear normal in size and are symmetrical.
- Transverse cardiac diameter is within normal limits.
- Both CP angles appear clear. Normal position and contour diaphragms noted.
- Bony rib cage and soft tissue shadows appear normal.

*Thanks for reference.*

*Radiologist*  
**Dr. Rahul Kumar Tiwari**  
MBBS, MD (Radio Diagnosis)  
MCI Reg. No. 57557

Name: SHIV PRATAP SINGH  
Age: 28Y  
Sex: M

R  
PA



PANACEA HOSPITAL, KABIR NAGAR, DURGAMCHINDI, HYDRABAD

THORAX  
15-11-2024  
101127







Call Now - 1800-123-3070

# PANACEA HOSPITAL



*A shelter for many hearts A Home for many lives*  
(An ISO 9001:2008 Certified Organisation)  
Lab Attached with CMC Under EQAS Scheme

Dept. of Radiodiagnosis - 32 Slice CT Scan, 3D/4D USG, 2D ECHO, Colour Doppler, Intervention Procedures, Digital X-Ray

NAME: SHIV PRATAP SINGH  
REF.DR.ASHUTOSH MISHRA(MD)

AGE/SEX: 28 YRS/MALE  
DATE: 15/11/2024

## ULTRASOUND WHOLE ABDOMEN REPORT

- Liver:** Normal in size(127mm), shape, & echogenicity. Intra & extra hepatic biliary radicals & vascular structures are normal. Margins are smooth and regular.
- Gall bladder:** Normally distended with echo free lumen.
- Portal vein:** Normal in course and caliber.
- CBD diameter:** Visualized part normal in course & caliber.
- Pancreas:** Normal in size, shape & echogenicity. Margins are smooth & regular. No diffuse/ focal lesion seen. Pancreatic duct not visualized.
- Spleen:** Normal in size, shape & echogenicity. Margins are smooth & regular. No diffuse / focal lesion seen.
- Kidney:** Both normal in size, shape echogenicity & position. Cortical-medullary differentiation is maintained. Pelvicalyceal system normal. No evidence of any calculus/mass lesion seen. No hydronephrosis/ hydroureter seen. No suprarenal mass lesion.
- Urinary bladder:** Normally distended with normal wall thickness. No echogenic foci lumen or diverticula seen. Both VUJ appears normal. No evidence of calculus / mass lesion seen.
- Prostate:** Normal in size(31X39X29mmVol19.6ml), shape & echogenicity.
- Others:** No free fluid in peritoneal cavity.  
No free fluid in bilateral pleural cavity.  
No evidence of significantly enlarged retroperitoneal/ mesenteric lymph nodes noted.

**IMPRESSION: -** **NO OBVIOUS SONOLOGICAL ABNORMALITY SEEN.**

Please correlate clinically and further investigations.

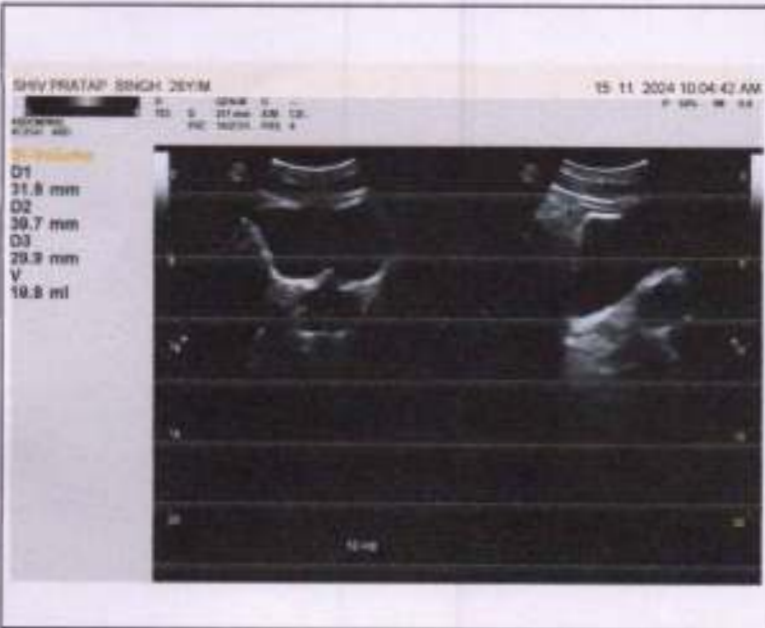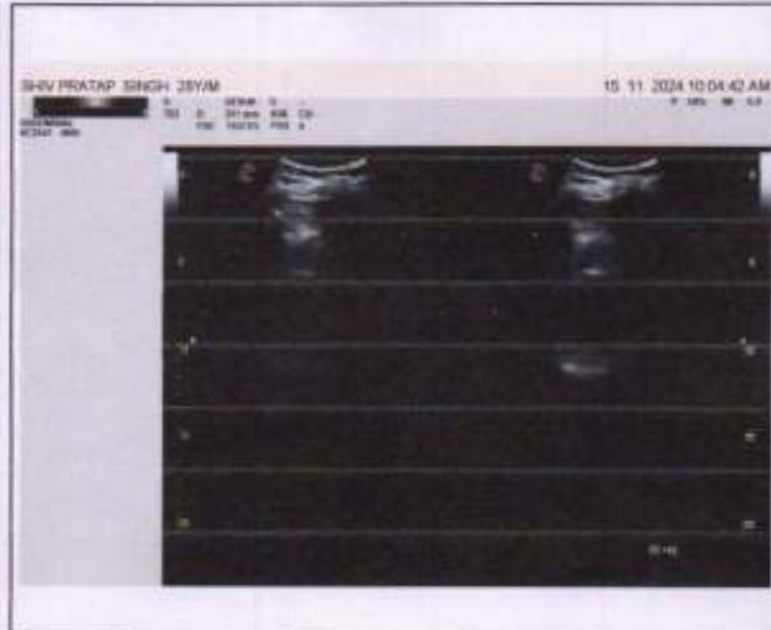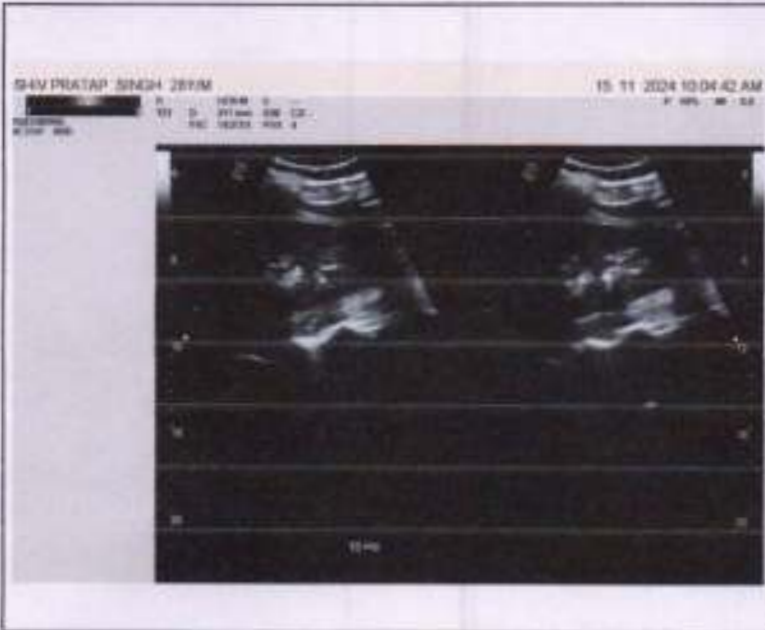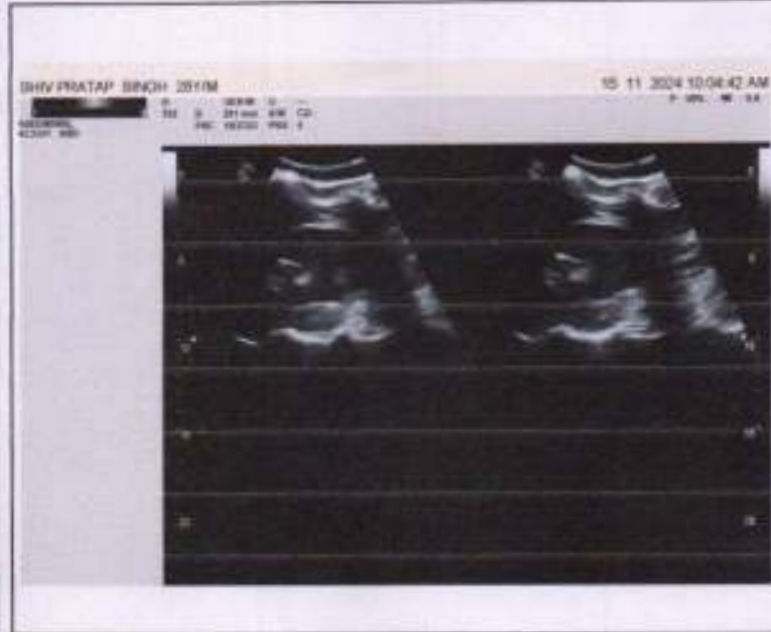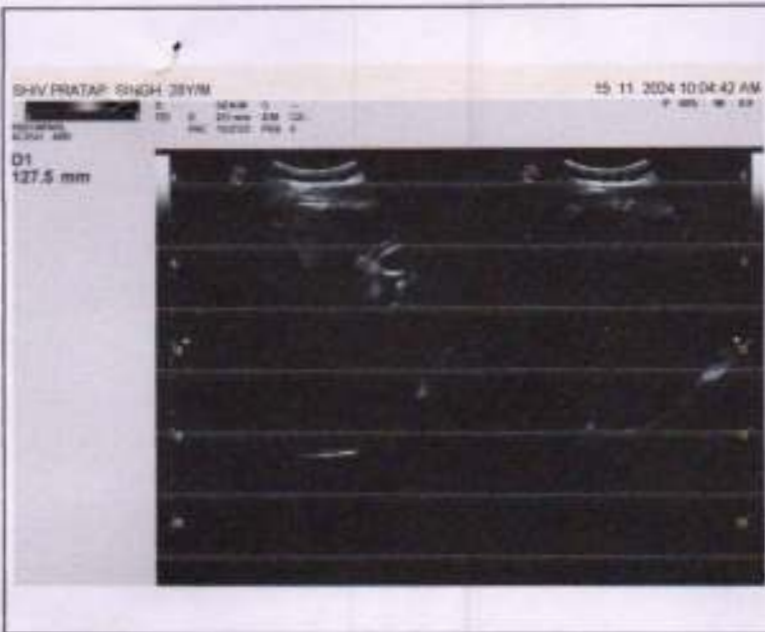Sonologist

**Dr. Rahul Kumar Tiwari**  
MBBS, MD (Radio Diagnosis)  
MCI Reg. No. 57557

- Note: (1) This report is not valid for medico-legal purposes.  
(2) In case of any discrepancy due typing error, please get it Rectified immediately.

Disclaimer: This report is not valid for Madicolegal or Judicial Purpose. Radiological diagnosis is solely interpretation of images produced by tissue & may not be always conclusive.

Address : B36/44 B4 Kabir Nagar (Near Sanjay Shiksha Niketan), Durgakund, Varanasi  
Mobile : 9554572190 / 9453837595 / Recpn, 9389994334  
Email : dramishra@gmail.com, drpallaviojha@gmail.com, Website : www.pilire.org



**Facilities:**

All clinical Biomedical & Hematology Investigations including Bone Marrow Examination  
 VPT, Podiascan & Complete Foot Care (First Time in Purvanchal)  
 All Hormonal Investigation by Chemiluminescent Method  
 Visceral Fat by (AB-140) Ambulatory BP Monitoring  
 CGMS & Insulin Pump Available  
 PFT, 2D-ECHO (Color Doppler), Holter, TMT, Cardiac-3 available  
 VIA, VILI, Colposcopy available  
 Special Endocrinological Investigation Protocols.

ISO 9001:2008 Certified  
 Mobile: 9389994334, 9554572190, 9453837595



# Panacea Pathology

## Clinical Reference Lab

Persistence, Preparedness and Precision  
 EQAS (CMC Vellore Attached) & IQAS System  
 पूर्वांचल की सर्वोत्तम गुणवत्ता वाली पैथोलॉजी

<b>UHID No</b>	:- UD-24250004380	<b>Booking No/Date</b>	:- 23 / 15-Nov-2024 12:13 PM
<b>Patient Name</b>	:- Mr - SHIV PRATAP SINGH	<b>Age/Sex</b>	:- 28 Y/M
<b>Father</b>	:-	<b>Reg No</b>	:- 24250004380
<b>Address</b>	:- KORARI SARHAD PILAKHTARFATEH 2051147, Firozabad, Firozabad	<b>Mobile No</b>	:- 9761884970
<b>Consultant</b>	:- Dr ASHUTOSH MISHRA (MD(MEDICINE),IMS,BHU)		

Investigations	Observations	Biological Ref. Interval	Unit
----------------	--------------	--------------------------	------

### HAEMATOLOGY

#### CBC

HAEMOGLOBIN <small>DefaultMethod / test Machine</small>	15.4	13.00 - 16.00	gm/dl
TLC <small>Methodology / Carm</small>	6600	4000.00 - 11000.00	Cells/cumm,
DLC DIFFERENTIAL LEUCOCYTE COUNT			
NEUTROPHILS	55	40.00 - 75.00	%
LYMPHOCYTES	36	20.00 - 45.00	%
EOSINOPHILS	04	1.00 - 6.00	%
MONOCYTES	05	2.00 - 10.00	%
BASOPHILS	00	&lt;1-2	%
PLATELET COUNT	1.63	1.50 - 4.10	lacs /cumm
PCV	48.9	33.00 - 42.00	%
RBC <small>Methodology / Carm</small>	5.78	4.50 - 5.50	million/cumm
MCV(MEAN CELL VOLUME)	84.5	83.00 - 101.00	fl
MCH(MEAN CELL HAEMOGLOBIN)	26.6	27.00 - 32.00	pg
MCHC	31.5	31.50 - 35.00	gm%
RDW-CV	13.6	11.00 - 16.00	%
RDW-SD	46.3	37.00 - 57.00	fl

Lab Technician

Consulting Pathologist

Dr. UMESH KUMAR

M.D. Pathology (ist)

MCI Reg. No. 6663

Timing : 24/7 hrs

This Report is not valid for medico legal purpose

Note: These tests have technical limitations. Clinico-pathological interpretation is necessary. In case of any disparity test may be repeated immediately.

Address : 36/44 FK Kabir Nagar, Durgakund, Varanasi – 221005

Email: [dramishra@gmail.com](mailto:dramishra@gmail.com), [drpallaviojha@gmail.com](mailto:drpallaviojha@gmail.com) Website: [panaceahospital.org](http://panaceahospital.org)

**Facilities:**

All clinical Biomedical & Hematology Investigations including Bone Marrow Examination  
 VPT, Podiascan & Complete Foot Care (First Time in Purvanchal)  
 All Hormonal Investigation by Chemiluminescent Method  
 Visceral Fat by (AB-140) Ambulatory BP Monitoring  
 CGMS & Insulin Pump Available  
 PFT, 2D-ECHO (Color Doppler), Holter, TMT, Cardiac-3 available  
 VIA, VILI, Colposcopy available  
 Special Endocrinological Investigation Protocols.

ISO 9001:2008 Certified  
 Mobile: 9389994334, 9554572190, 9453837595



# Panacea Pathology

## Clinical Reference Lab

Persistence, Preparedness and Precision  
 EQAS (CMC Vellore Attached) & IQAS System  
 पूर्वांचल की सर्वोत्तम गुणवत्ता वाली पैथोलॉजी

<b>UHID No</b>	:- UD-24250004380	<b>Booking No/Date</b>	:- 23 / 15-Nov-2024 12:13 PM
<b>Patient Name</b>	:- Mr - SHIV PRATAP SINGH	<b>Age/Sex</b>	:- 28 Y/M
<b>Father</b>	:-	<b>Reg No</b>	:- 24250004380
<b>Address</b>	:- KORARI SARHAD PILAKHTARFATEH 2051147, Firozabad, Firozabad	<b>Mobile No</b>	:- 9761884970
<b>Consultant</b>	:- Dr ASHUTOSH MISHRA (MD(MEDICINE), IMS, BHU)		

Investigations	Observations	Biological Ref. Interval	Unit
----------------	--------------	--------------------------	------

### HAEMATOLOGY

<b>ESR</b>	12.0	0.00 - 15.00	mm at 1 hr
<b>BLOOD GROUP ABO &amp; RH FACTOR</b>			
BLOOD GROUP	"B"		
RH FACTOR	POSITIVE		

### BIOCHEMISTRY

#### LIPID PROFILE

TOTAL CHOLESTROL	156.0	Desirable : - &lt; 200 mg/dL Borderline: - 200 - 239 mg/dL High : - &gt; 240mg/dL	mg/dl
TRIGLYCERIDES	146.0	35.00 - 160.00	mg/dl
HDL CHOLESTROL	40.0	35.30 - 79.50	mg/dl
LDL CHOLESTROL	86.8	&lt;130	mg/dl
VLDL	29.20	&lt;40	mg/dl
CHOLESTROL/ HDL RATIO	3.90	&lt;3.0 LOW RISK, 3.0-5.0 AVG RISK, &gt;5.0 HIGH RISK	ratio
LDL/HDL RATIO	2.17	&lt;3	ratio

#### LFT (LIVER FUNCTION TESTS)

TOTAL BILIRUBIN	0.58	0.00 - 1.20	mg/dl
DIRECT BILIRUBIN	0.18	0.00 - 0.30	mg/dl

Lab Technician

Consulting Pathologist\*  
**Dr. UMESH KUMAR**  
 MBBS, MD (Pathologist)  
 M.D. Pathology

Timing : 24/7 hrs

This Report is not valid for medico legal purpose

Note: These tests have technical limitations. Clinico-pathological interpretation is necessary. In case of any disparity test may be repeated immediately.

Address : 36/44 FK Kabir Nagar, Durgakund, Varanasi - 221005

Email: [dramishra@gmail.com](mailto:dramishra@gmail.com), [drpallaviojha@gmail.com](mailto:drpallaviojha@gmail.com) Website: [panaceahospital.org](http://panaceahospital.org)

**Facilities:**  
 All clinical Biomedical & Hematology Investigations including Bone Marrow Examination  
 VPT, Podiascan & Complete Foot Care (First Time in Purvanchal)  
 All Hormonal Investigation by Chemiluminescent Method  
 Visceral Fat by (AB-140) Ambulatory BP Monitoring  
 CGMS & Insulin Pump Available  
 PFT, 2D-ECHO (Color Doppler), Holter, TMT, Cardiac-3 available  
 VIA, VILI, Colposcopy available  
 Special Endocrinological Investigation Protocols.

ISO 9001:2008 Certified  
 Mobile: 9389994334, 9554572190, 9453837595



## Panacea Pathology

### Clinical Reference Lab

Persistence, Preparedness and Precision  
 EQAS (CMC Vellore Attached) & IQAS System  
 पूर्वांचल की सर्वोत्तम गुणवत्ता वाली पैथोलॉजी

**UHID No** :- UD-24250004380 **Booking No/Date** :- 23 / 15-Nov-2024 12:13 PM  
**Patient Name** :- Mr - SHIV PRATAP SINGH **Age/Sex** :- 28 Y/M  
**Father** :- **Reg No** :- 24250004380  
**Address** :- KORARI SARHAD PILAKHTARFATEH **Mobile No** :- 9761884970  
 2051147, Firozabad, Firozabad  
**Consultant** :- Dr ASHUTOSH MISHRA (MD(MEDICINE), IMS, BHU)

Investigations	Observations	Biological Ref. Interval	Unit
INDIRECT BILIRUBIN	0.40	0.20 - 0.70	mg/dl
SGOT	31.0	2.00 - 31.00	U/L
SGPT	33.0	10.00 - 45.00	U/L
ALKALINE PHOSPHATASE	89.0	25.00 - 140.00	U/L
TOTAL PROTIENS	7.22	6.60 - 8.70	g/dl
ALBUMIN	4.12	3.50 - 5.20	gm%
GLOBULIN	3.10	1.50 - 3.60	gms/dl
A/G RATIO	1.32	2:1	RATIO

#### RFT (RENAL FUNCTION TESTS)

SERUM CREATININE	0.69	0.60 - 1.60	mg/dl
URIC ACID	3.76	3.60 - 7.70	mg/dl

#### IMMUNOLOGY

#### THYROID PROFILE (T3, T4, TSH)


T3	0.91	0.60 - 1.81	ng/ml
T4	8.8	4.50 - 10.90	ug/dl
TSH	2.15	0.39 - 6.10	uIU/mL

\* END OF REPORT \*

Lab Technician

Timing : 24/7 hrs

This Report is not valid for medico legal purpose

  
 Consulting Pathologist  
 Dr. UMESH KUMAR  
 MBBS, MD (Pathology)  
 M.D. Pathology  
 MCI Reg. No. 41623

Note: These tests have technical limitations. Clinico-pathological interpretation is necessary. In case of any disparity test may be repeated immediately.

Address : 36/44 FK Kabir Nagar, Durgakund, Varanasi - 221005

Email: [dramishra@gmail.com](mailto:dramishra@gmail.com), [drpallaviojha@gmail.com](mailto:drpallaviojha@gmail.com) Website: [panaceahospital.org](http://panaceahospital.org)

**Facilities:**

All clinical Biomedical & Hematology Investigations including Bone Marrow Examination  
 VPT, Podiascan & Complete Foot Care (First Time in Purvanchal)  
 All Hormonal Investigation by Chemiluminescent Method  
 Visceral Fat by (AB-140) Ambulatory BP Monitoring  
 CGMS & Insulin Pump Available  
 PFT, 2D-ECHO (Color Doppler), Holter, TMT, Cardiac-3 available  
 VIA, VILI, Colposcopy available  
 Special Endocrinological Investigation Protocols.

ISO 9001:2008 Certified  
 Mobile: 9389994334, 9554572190, 9453837595



# Panacea Pathology

## Clinical Reference Lab

Persistence, Preparedness and Precision  
 EQAS (CMC Vellore Attached) & IQAS System  
 पूर्वांचल की सर्वोत्तम गुणवत्ता वाली पैथोलॉजी

<b>UHID No</b>	:- UD-24250004380	<b>Booking No/Date</b>	:- 104 / 15-Nov-2024 02:59 PM
<b>Patient Name</b>	:- Mr - SHIV PRATAP SINGH	<b>Age/Sex</b>	:- 28 Y/M
<b>Father</b>	:-	<b>Reg No</b>	:- 24250004380
<b>Address</b>	:- KORARI SARHAD PILAKHTARFATEH 2051147, Firozabad, Firozabad	<b>Mobile No</b>	:- 9761884970
<b>Consultant</b>	:- Dr PALLAVI MISHRA (MBBS)		

Investigations	Observations	Biological Ref. Interval	Unit
----------------	--------------	--------------------------	------

### BIOCHEMISTRY

<b>CALCIUM</b>	9.41	8.60 - 10.40	mg/dl
----------------	------	--------------	-------

\* END OF REPORT \*

Consulting Pathologist

**Dr. Umesh Kumar**  
**M.D. Pathology**  
 M.B.B.S, M.D (Pathologist)  
 MCI Reg. No. 41413

Lab Technician

Timing : 24/7 hrs

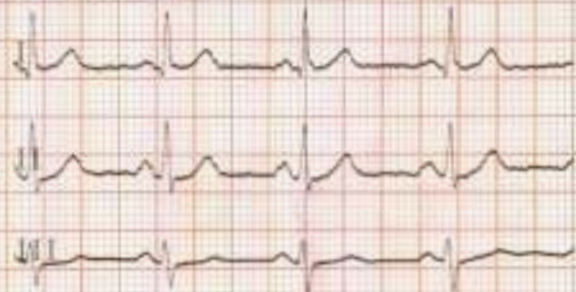This Report is not valid for medico legal purpose

Note: These tests have technical limitations. Clinico-pathological interpretation is necessary. In case of any disparity test may be repeated immediately.

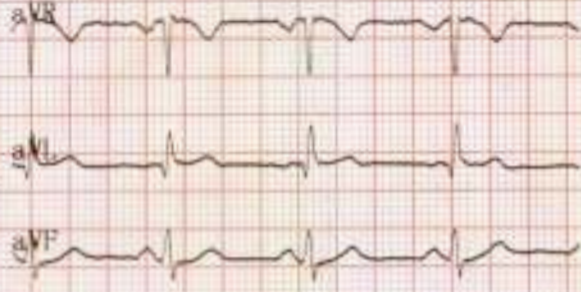Address : 36/44 FK Kabir Nagar, Durgakund, Varanasi – 221005

Email: [dramishra@gmail.com](mailto:dramishra@gmail.com), [drpallaviojha@gmail.com](mailto:drpallaviojha@gmail.com) Website: [panaceahospital.org](http://panaceahospital.org)

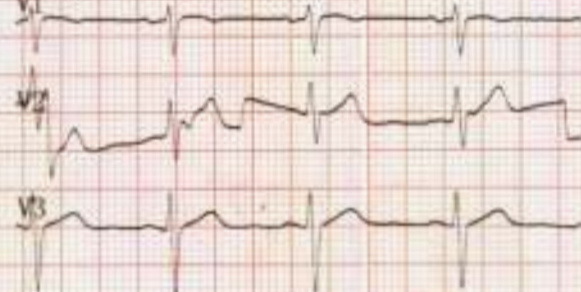AUTO 10mm/mV



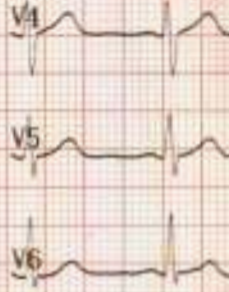
10mm/mV



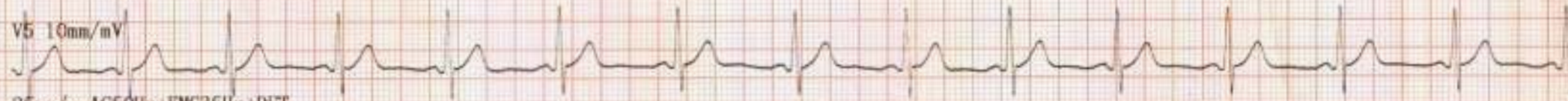5mm/mV



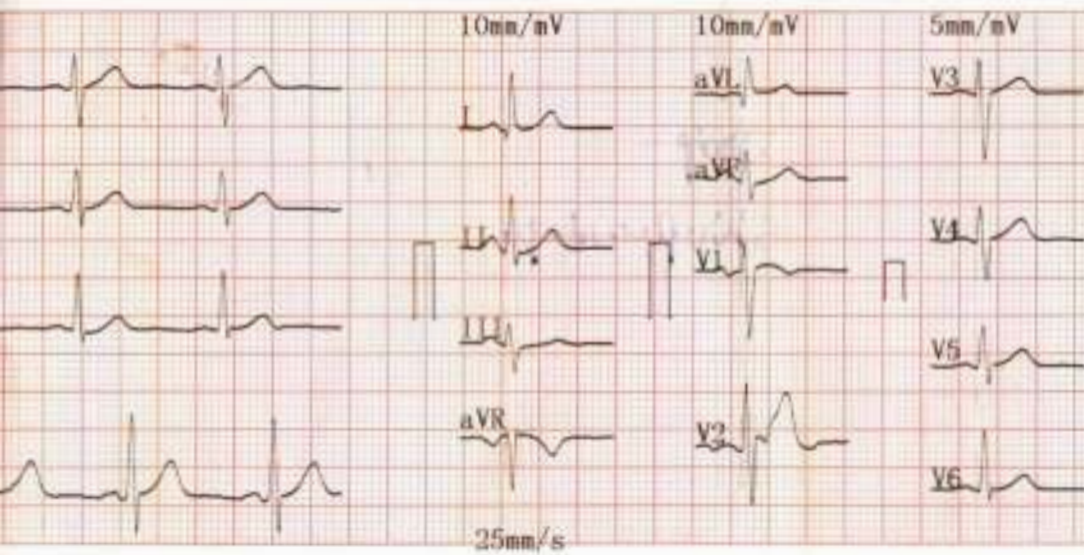
5mm/mV



V5 10mm/mV



25mm/s ACS0Hz+EMG35Hz+DFT



10mm/mV

10mm/mV

5mm/mV

2024-11-15 10:44

<< Conclusions >>

ID :  
 Name : **Shiv Pratap Singh**  
 Sex : **M** Age : **28**  
 Height : **177** Weight : **65** kg  
 SYS :  
 DIA :

Normal Sinus Rhythm.  
 Longitudinal Left axis deviation.  
 \*\*Report need physician confirm\*\*

HR bpm : 77  
 PR Interval ms : 133  
 P Duration ms : 120  
 QRS Duration ms : 73  
 T Duration ms : 193  
 QT/QTc ms : 325/368  
 P/QRS/T Axis deg : 64.5/21.2/39.0  
 R(V5)/S(V1) mV : 1.09/0.90  
 R(V5) + S(V1) mV : 1.99

*Pallavi*

**Dr. Pallavi Misra**  
 MBBS, MD (General Medicine)  
 MCI Reg. No. 52033

Physician