


78 bpm
- / - mmHg

Location: P
Order No.:
Indication:
Modification 1:
Modification 2:
Modification 3:

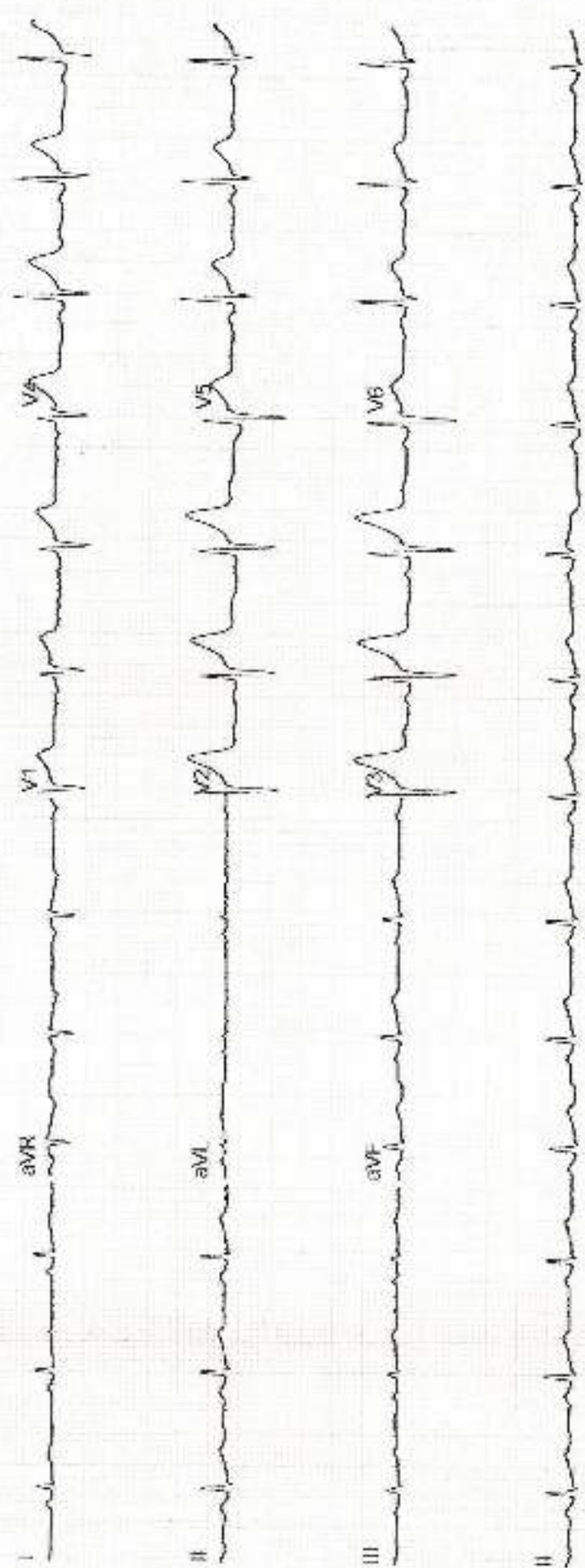
Technician:
Ordering Pt:
Referring Pt:
Attending Dr:

Normal sinus rhythm
Normal ECG



QT / QTc: 356 / 405 ms
PR: 130 ms
P: 76 ms
RR / PP: 772 / 769 ms
P / QRS / T: 44 / 57 / 54 degrees

Male



MR ANKIT, SHRIVASTAVA

ID: ASHB.0000054240 Age: 40

Sex at Birth: Male
 Ethnicity: Asian
 Smoker: No

Height: 176 cm
 Weight: 90 kg BMI: 29.8

Asthma: NO
 COPD: NO

FVL (ex/in)

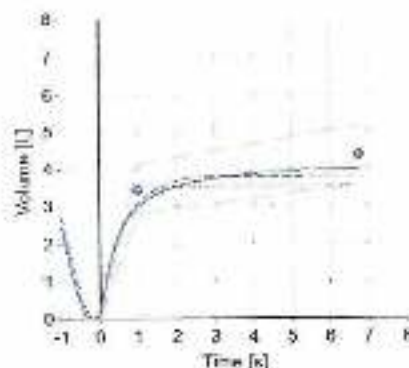

Your FEV1 / Predicted: 89%

Test Date: 25-10-2024 10:53:37 Interpretation: GOLD(2008)/Hemle
 Post Time: BTPS (IN/EX) 132/102
 Predicted: Chhabra (India), 2014 * 1.00

Parameter	Pre				Pred	Tidal 5	Tidal 3	Tidal 2
	Best	LLN	Z-Score	%Pred				
FVC [L]	3.99	3.59	-0.90	91	4.38	3.99	3.83	3.54*
FEV1 [L]	3.07	2.79	-0.94	89	3.45	2.97	3.07	2.97
FEV1/FVC [%]	77.0	69.1	-0.22	90	78.1	74.4	80.3	84.0
FF25-75 [L/s]	2.32	1.97	-1.11	76	3.07	2.32	2.01	3.14
FET [s]	5.8	-	-	-	-	6.8	6.9	6.7
FVC [L]	4.04	3.59	-0.71	92	4.38	4.04	3.70	3.72
PE [L/s]	3.91	-	-	-	-	3.91	4.33	4.09
PEF [L/min]	364*	391	-2.03	72	507	364*	358*	398*

* Indicates value outside normal range or significant post change.

Session Quality: Pre FEV1 - B, FVC - C (FVC Var=0.16, 14.1%, FEV1 Var=0.11, 3.4%)
 System Interpretation: Pre Normal Spirometry



Small airway obstruction

Dr. Khushboo Saxena
 MBBS, DNB Pulmonary Medicine
 PDCC Sleep Medicine, FCCP, (USA)
 Fellow Sleep Medicine ISDA, MNAAS
 Consultant Pulmonary & Sleep Medicine



Dr. ARPITA AGARWAL

MBBS, MS, FVPEI (GLAUCOMA AND CATARACT.)
 CATARACT, GLAUCOMA AND REFRACTIVE SURGEON
 EX FELLOW AND CONSULTANT LV PRASAD EYE INSTITUTE, HYDERABAD
 EX CONSULTANT PEOPLES'S HOSPITAL, BHOPAL
 EX CONSULTANT ASG EYE HOSPITAL, BHOPAL

NAME Mr. Ankit Shrivastava AGE 40 Yr

DATE 25/10/2024

C/O. PMHC

VN	UNAIDED	WITH GLASS	PTNUOLE	AR	SPH	CYL	AXIS
RE	6/6						
LE	6/6						

REFRACTION:

vision 88/38 BE

SUB	SPH	CYL	AXIS	VN	PG
RE					
LE					
NV					

vision 88/38 BE

no no no

eed

Refresh 7000 400

Apna



ULTRA SONOGRAPHY ABDOMEN

NAME	Mr. Ankit Shrivastava	UHID NUMBER:- ASIB.0000054240	
REF. BY	AIIC	DATE	25.10.2024
		AGE/SEX:-	40y/M

Liver:- is normal in size and echotexture. Portal and hepatic venous system appears normal. Intra and extra hepatic biliary radicals are not dilated.

Gall Bladder:- is normal in size and shape. Its lumen is echofree.

Pancreas is normal in size outline and echopattern.

Spleen is normal in size and echopattern.

Both kidneys are normal in size, shape and echogenicity. Central pelvicalyceal sinus and corticomedullary ratio are normal. Bilateral few small echogenic foci are seen in mid and lower pole region both kidneys.

Right kidney measures:- 10.2x4.3cm

Left kidney measures:- 9.6x4.6cm

Urinary bladder is normal in shape and contour. Its wall is normal.


Prostate is normal in size and shape and echotexture. Estimated volume is- 14cc.

No evidence of ascites is seen.

IMPRESSION:- Sonography Study Reveals:-

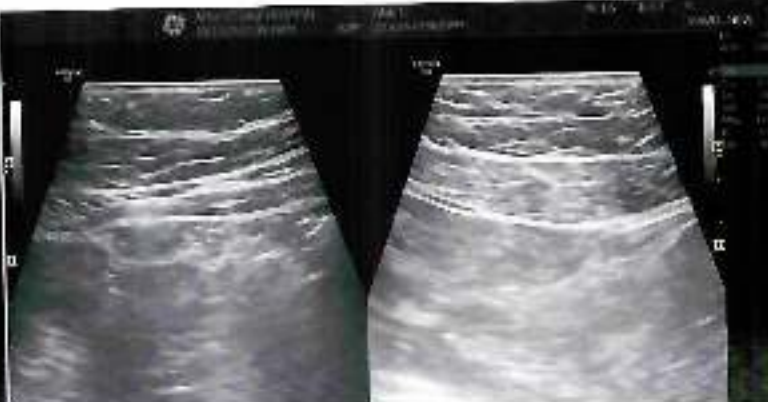
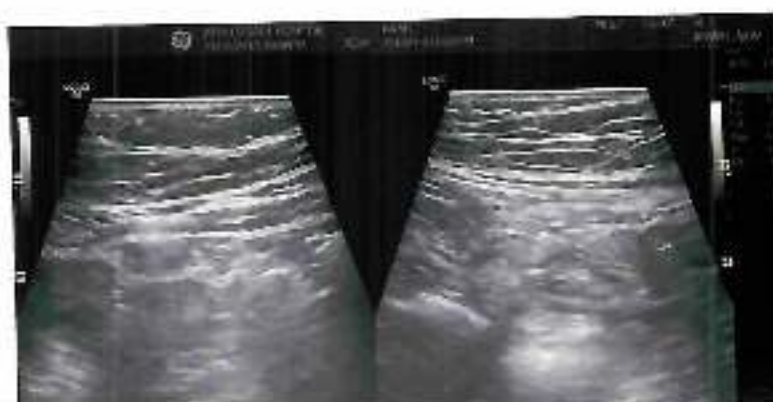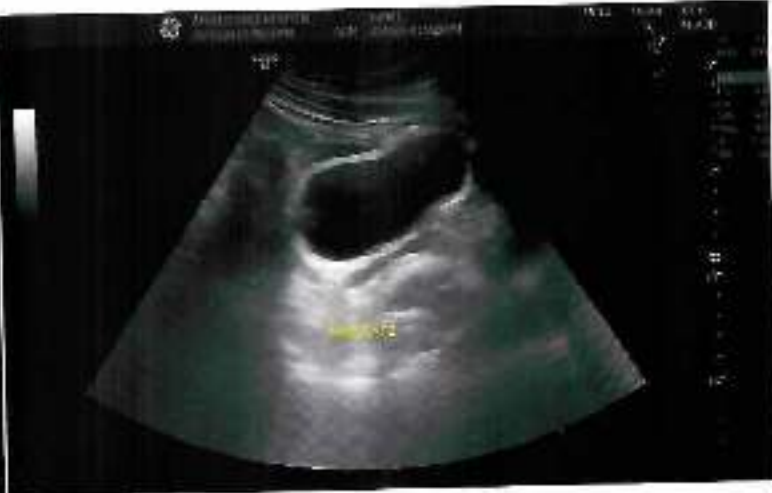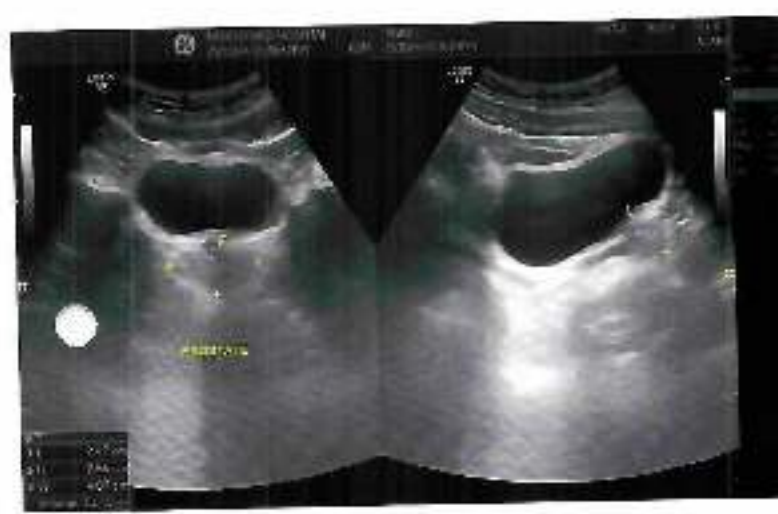
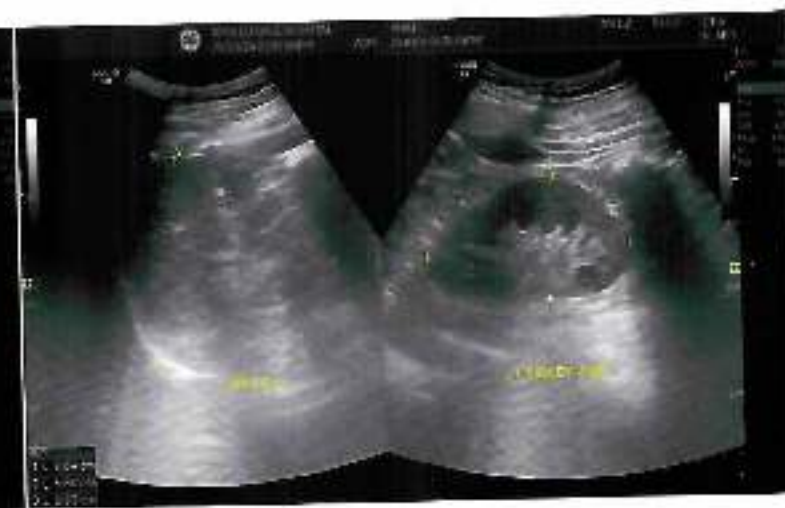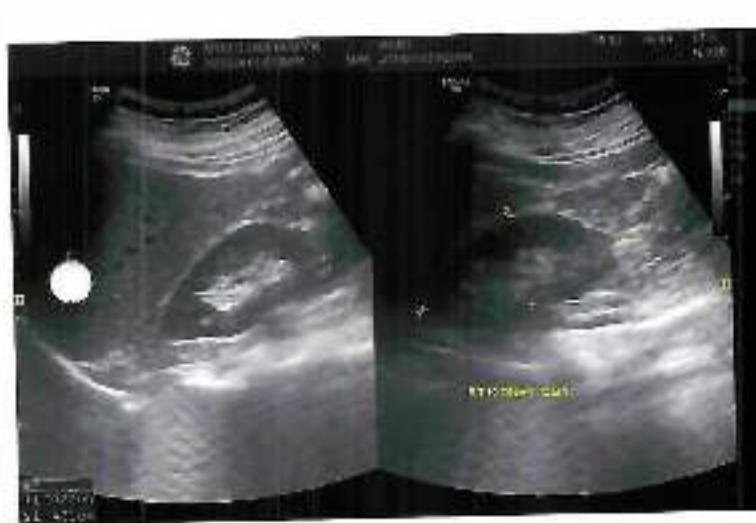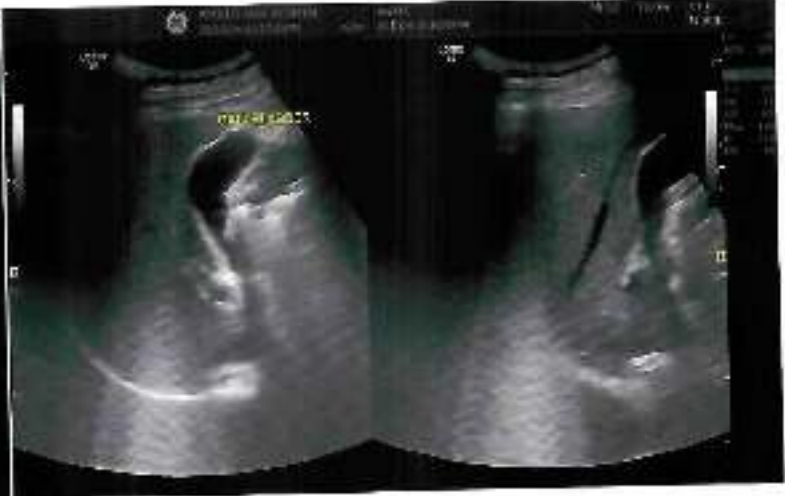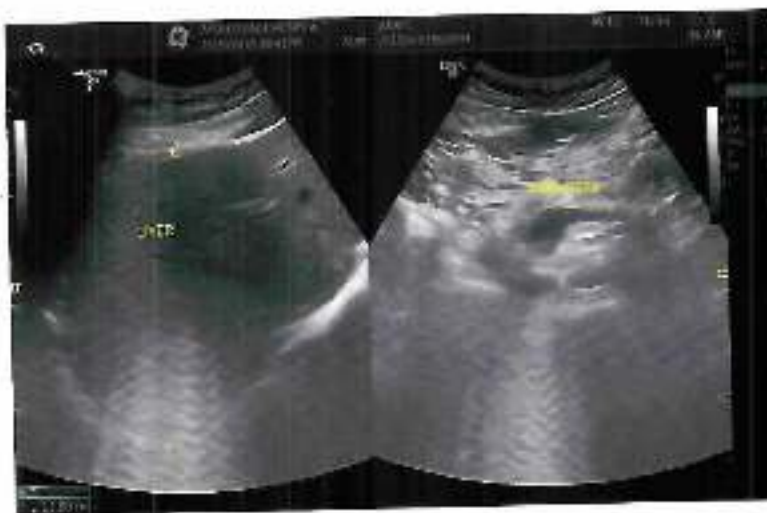
- Bilateral few renal concretions (3mm).

ADV:- Clinical Correlation.



DR. HARI SANTOSH
CONSULTANT RADIOLOGIST





NAME	Mr. Ankit Shrivastava	UHID NUMBER:- ASHB.0000054240
REF. BY	ASHL	DATE 25.10.2024 AGE/SEX:- 40y/M

X-RAY CHEST (PA VIEW)

Both lung fields are clear. No active pleural or parenchymal lesion is seen.

The hila, mediastinum, bony thoracic cage and the diaphragmatic domes are normal.

The costophrenic and cardiophrenic angles are clear.

The cardiac silhouette is unremarkable.

IMP:- RADIOGRAPHIC IMAGE REVEALS:-

Normal findings are seen.

Thanks for Ref



DR. HARI SANTOSH
CONSULTANT RADIOLOGIST

