

DAKSH HOSPITAL

396 - 397, Gandhi Nagar, Scheme No. 8, ALWAR -301001

Ref. No.

Date.....

MEDICAL EXAMINATION REPORT
Mediwheel (BOB)

Name: Mrs. Richa Rani Saiwal Age: 29 yrs Sex: Female Date: 09/03/2024

General Physical ExaminationHeight : 166cm
Pulse : 78 /mt
Respiration : 18 /mtWeight : 63 Kg
BP : 110/70 mm/hg
BMI : 22.9 kg/m²**Systemic Exam:-** NORMAL**Dental Check up :-** NORMAL**Eye check-up :-** NORMAL**Skin Check up:-** NORMAL**ENT Check up:-** NORMAL**Gynae Check up:-** Mh 4 DIM 40-45-60 on - NIL Pm mass
ML - 2 yrs - Paps smear taken
dmp - 1 Puch -**Impression:-** vly - DCs**Recommendation:-** NDDr. Mukesh Kumar Gupta
MD Gen. Medicine
Reg. No 5423/16262डॉ० मुकेश गुप्ता
M.D.F.C.C.S.
फिजिशियन एवं मधुमेह रोग विशेषज्ञ
दक्ष हॉस्पिटल, अलवर
रजि० नं०-5423/16262

Results

Run Date 09/03/2024 10:27:12 AM

Operator DAKSH

Last Name

Sample ID 10

First Name MRS RICHA RANI

Department

Gender Female Age

Physician DR. MUKESH GUPTA M.D

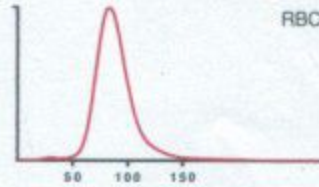
Patient ID AUTO_PID20061

Type Woman

Date of birth

Sample comments

			Range
RBC	4.66	10 ⁶ /μL	3.80 - 5.50
HGB	13.2	g/dL	11.5 - 15.2
HCT	41.3	%	35.0 - 46.0
MCV	88.7	μm ³	77.0 - 97.0
MCH	28.4	pg	26.0 - 34.0
MCHC	32.0	g/dL	32.0 - 35.0
RDW-CV	16.4	%	11.0 - 17.0
RDW-SD	57.3	H μm ³	37.0 - 49.0



Recommended actions

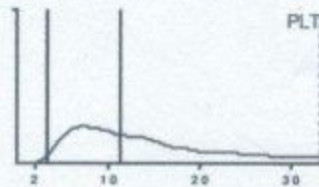
Slide review

Susp. Pathologies

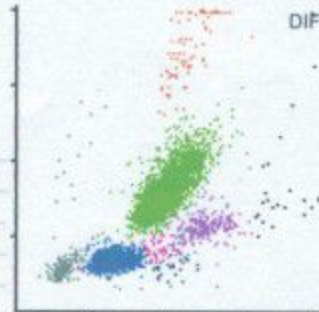
Macroplatelets

PLT aggregate or NRBC ?

			Range
PLT	204	* 10 ³ /μL	150 - 450
PCT	0.27	* %	0.15 - 0.40
MPV	13.4	H* μm ³	8.0 - 11.0
PDW	27.7	H* μm ³	11.0 - 22.0
P-LCC	109	10 ³ /μL	44 - 140
P-LCR	53.3	h %	18.0 - 50.0



			Range
WBC	8.48	* 10 ³ /μL	3.50 - 10.00
	#		
		Range	%
NEU	5.01	* 1.60 - 7.00	59.4
LYM	3.09	h* 1.00 - 3.00	36.6
MON	0.12	l* 0.20 - 0.80	1.4
EOS	0.13	* 0.00 - 0.50	1.5
BAS	0.09	* 0.00 - 0.15	1.1
LIC	0.04	* 0.00 - 0.10	0.5



Dr. R.S. GUPTA
 MD (Pathology) (MAHE)
 Reg. No. 7924/19778

Date :-09/03/2024

Name :- MRS. RICHA RANI SAIWAL

Age & Sex :- 29 Yrs/ Female

Refd. :- Dr Mukesh Gupta M.D.

	TEST NAME	RESULT	REFERENCE RANGE	
	ESR	15	00 -20 mm/hrs	
	Blood Group & Rh Factor	O ⁺ NEGATIVE		
	HbA1C	4.5	4 - 5.6%	
	Blood Sugar (R)	85.2	< 150mg/dl	
	Blood Sugar (PP)	-	< 140 mg/dl	
	Urine Sugar (F)	NIL	-	
	Urine Sugar (PP)	NIL	-	
LIVER	S.Bilirubin Total	1.1	0.30 - 1.20 mg/dl	
	S.Bilirubin Direct	0.4	0.10 - 0.30 mg/dl	
	S.Bilirubin Indirect	0.7	0.30 - 0.90 mg/dl	
	S.G.O.T.	29	> 37 u/l	
	S.G.P.T.	40	> 40 u/l	
	S.Alk. Phosp.	200	80 - 306 u/l	
	G.G.T.	23.1	5 -40 u/l	
	Total Protein	7.0	6.5 - 8.5 gm/dl	
	Albumin	4.0	3.8 - 5.4 gm/dl	
	Globulin	3.0	2.3 - 3.5 gm/dl	
	A/G Ratio	1.1	-	
	AST/ALT Ratio	0.73	-	
KIDNEY	Blood Urea	25.1	15 -45 mg/dl	
	S.Creatinine	0.3	0.60 - 1.30 mg/dl	
	BUN	24.1	6 -24 mg/dl	
	S.Uric Acid	5.8	M 3.1 - 7.0, F 2.5 - 5.6 mg/dl	
	BUN/Creatinine Ratio	26.1	-	
LIPID PROFILE	Total Cholesterol	157.1	Up to 200 mg/dl	
	S.HDL	44.1	30 - 70 mg/dl	
	S.LDL	85.1	Up to 170 mg/dl	
	S.VLDL	28.1	5.0 - 40 mg/dl	
	S. Triglycerides	140.1	Up to 170 mg/dl	
	LDL/HDL Ratio	1.9	-	
	Total Cholesterol/ HDL Ratio	3.5	-	
THYROID	T3	98.5	40 - 181 ng/dl	
	T4	6.9	4.6 - 10.5 µg/dl	
	TSH	1.05	0.30 - 5.0 mIU/l	
	URINE EXAMINATION		<i>Microscopic Examination:</i>	
General/Chemical Examination:	Colour	Pale Yellow	RBC	Absent
	Reaction	Acidic	WBC	2-3
	Specific Gravity	QNS	Epithelial Cells	0-1
	Appearance	Clear	Cast	Absent
	Albumin	Nil	Crystal	Absent
	Sugar	Nil	Spermatozoa	Absent
			Amorphous Sediments	Absent
		Other	Absent	
X-RAY CHEST	NORMAL STUDY			
	STOOL EXAMINATION		<i>Microscopic Examination:</i>	
General/ Chemical Examination:			RBC	-
	Colour	-	WBC	-
	Consistency	-	Ova & Parasites	-

Doctor


TECHNOLOGIST

All investigation have their own limitations regarding the sensitivity & specificity of individual assay procedures, Isolated laboratory investigations never confirm the final diagnosis of the disease. They only help in arriving at a diagnosis in conjunction with clinical presentation and other related investigations. Report is not valid for medico-legal purpose subject to ALWAR jurisdiction only.



दक्ष हॉस्पिटल

396, गाँधी नगर स्कीम नं.8, अलवर (राज०) ☎ 0144-2703340

Sonography / 2D Echo Cardiography / Doppler Report

2D/ ECHO REPORT

Name: - Mrs RICHA Age: - 29 Yrs Date: - 9-Mar-24

Reg. No.: - Alw/2009/04
BOB health checkup


PROCEDURES: M-MODE/2D/DOPPLER/COLOR/CONTRASTB.A.S. M²

MEASUREMENT:		DOPPLER:	
AOD	20	NORMAL (20- 37mm)	MV 0.6 (0.8- 1.3)
LA	21	(19- 40mm)	AV 1.4 (1.2- 1.8)
AVO	15	(12- 25mm)	TV 0.6 (0.3- 0.8)
RVDd.	14.9	(03- 09mm)	PV 0.8 (0.7- 1.1)
LVDd	40.7	(37- 56mm)	MITRAL VALVE-
LVDs	26.5	(22- 40mm)	AML Normal
IVS d	7	(06- 12mm)	PML Normal
IVS s	12.9		
PWd	5	(05- 10mm)	AORTIC VALVE Normal
LV FUNCTION		TV & PV are normal.	
M- E- S Separation	<0.9cm		
Minor	24.42%		
LV Ejection Fraction	65%	65 +/- 12%	

MITRAL E>A
LV WALL MOTION: NO RWMA
ALL CARDIAC CHAMBERS ARE NORMAL
ALL VALVES ARE NORMAL
NO CLOT, VEGETATION, PERICARDIAL EFFUSION

Adv. - Follow up/ review at higher center for confirmation

Note:- Please Correlate clinically. Due to technical limitations as well as inaccuracies inherent in the laboratory and statistical analysis of biological process. Diagnostic accuracy of ECHO is up to 95% only.
Report is not valid for medico-legal purpose.


DR. MUKESH GUPTA
Physician & Sonologist
RM 5423/16262



"भ्रूण लिंग परीक्षण की शिकायत 104 टोल फ्री सेवा पर भी की जा सकती है।"
"भ्रूण लिंग परीक्षण की शिकायत 104 टोल फ्री सेवा पर भी की जा सकती है।"



दक्ष हॉस्पिटल

396, गाँधी नगर स्कीम नं.8, अलवर (राज०) ☎ 0144-2703340

Sonography / 2D Echo Cardiography / Doppler Report

NAME :- MRS RICHA/F/29 YRS

9-Mar-24

BOB HEALTH CHECKUP

U.S.G. OF ABDOMEN & PELVIS

LIVER

Liver is normal in size shape with normal echo-texture. Intra hepatic biliary radicals Are not dilated. No evidence of focal or diffuse lesion.

GALL BLADDER

Gall bladder is normal.

PANCREAS

Pancreas is normal in size, shape & echo-texture. No evidence of focal or diffuse lesion. MPD not dilated.

SPLEEN

Normal in size with normal shape & echo- texture. Spleen vein is normal. No evidence of focal or diffuse lesion

KIDNEY

Both kidneys are normal.

URINARY BLADDER

UB is well distended, visualized lumen appear clear.

UTERUS:

Uterus is normal in size (8.3x2.8x4.1cm) with homogenous echo-texture. Endometrial normal in thickness & echo genicity

OVARIES:

Both ovaries appear enlarged & have multiple cyst, arrange at periphery. - PLOM

Advice- follow up/ hormonal study review at higher center for confirmation

Please correlate clinically. USG accuracy is 95 % due to technical limitations as well as inaccuracies inherent in the laboratory and statistical analysis biological process. This report is not valid for medico-legal cases


DR. MUKESH GUPTA
SONOLOGIST
Dr. Mukesh Kumar Gupta
Physician & Sonologist
RM 5423/16262



"भ्रूण लिंग परीक्षण की शिकायत
104 टोल फ्री सेवा पर भी की
जा सकती है"

भ्रूण लिंग परीक्षण की शिकायत 104 टोल फ्री सेवा पर भी की जा सकती है।

11-02-2024 06:39:22 AM

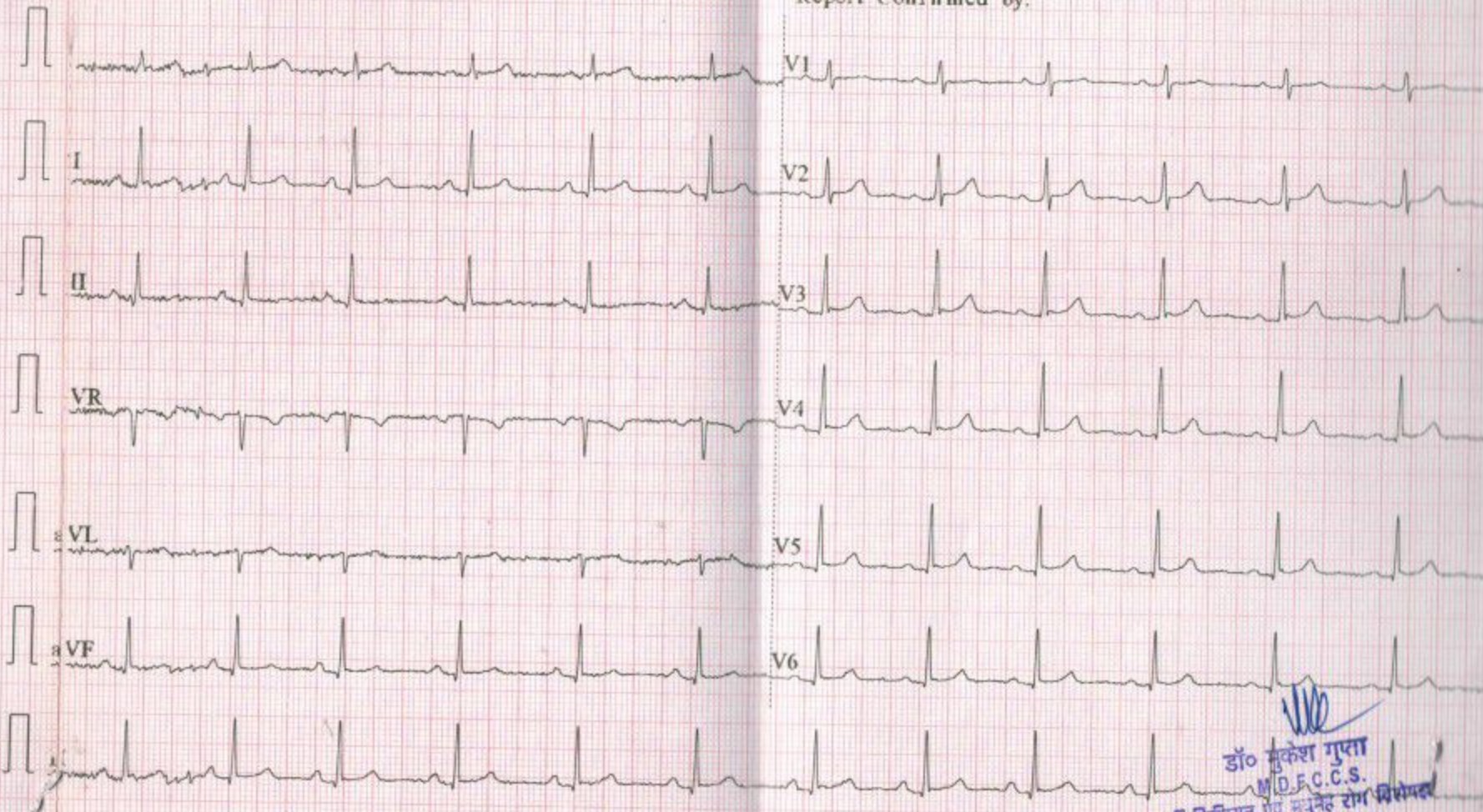
ID: /

Female Years

HR	: 74	bpm
P	: 99	ms
PR	: 168	ms
QRS	: 81	ms
QT/QTc	: 348/388	ms
P/QRS/T	: 75/72/39	°
RV5/SV1	: 1.108/0.199	mV

Diagnosis Information:
 Sinus Rhythm
 Normal ECG

Report Confirmed by:



(Signature)
 डॉ० मुकेश गुप्ता
 M.D.F.C.C.S.

फिजिशियन एप मुकुंद रोम सिरोमट्ट
 दक्ष हॉस्पिटल, अलवर
 रजि० नं०-5423/16262

R

