

Scanned

Name : Mrs. SANGITA KUMARI

Age: 36 Y

UHID:CELE.0000127377

Address : ecity

Sex: F



Plan : ARCOFEMI MEDIWHEEL FEMALE AHC CREDIT PAN INDIA OP AGREEMENT

OP Number:CELEOPV333571

Bill No :CELE-OCR-54337

Date : 25.01.2024 07:52

Sno	Service Type/ServiceName	Department
1	ARCOFEMI - MEDIWHEEL - FULL BODY HEALTH ANNUAL PLUS CHECK - FEMALE - 2D ECHO - PAN INDIA - FY2324	
1	GAMMA GLUTAMYL TRANSFERASE (GGT)	
2	2D ECHO — 11 10:45 AM	
3	LIVER FUNCTION TEST (LFT)	
4	GLUCOSE, FASTING — 12	
5	HEMOGRAM + PERIPHERAL SMEAR	
6	GYNAECOLOGY CONSULTATION	
7	DIET CONSULTATION — pending	
8	COMPLETE URINE EXAMINATION	
9	URINE GLUCOSE (POST PRANDIAL)	
10	PERIPHERAL SMEAR	
11	ECG — 13	
12	LBC PAP TEST- PAPSURE — 16 9:30 AM	
13	RENAL PROFILE/RENAL FUNCTION TEST (RFT/KFT)	
14	DENTAL CONSULTATION — 15 10:00 AM — Pending	
15	GLUCOSE, POST PRANDIAL (PP), 2 HOURS (POST MEAL)	
16	URINE GLUCOSE (FASTING)	
17	HbA1c, GLYCATED HEMOGLOBIN	
18	X-RAY CHEST PA — 9	
19	DENT CONSULTATION — 10:00 AM — Dr. Sonia	
20	FITNESS BY GENERAL PHYSICIAN	
21	BLOOD GROUP ABO AND RH FACTOR	
22	LIPID PROFILE	
23	BODY MASS INDEX (BMI)	
24	OPHTHAL BY GENERAL PHYSICIAN — 3 10:00 AM	
25	ULTRASOUND - WHOLE ABDOMEN — 8 10:30 AM	
26	THYROID PROFILE (TOTAL T3, TOTAL T4, TSH)	

Audi - 3
Physio - 14

REI - Pano — 6/6

LEI - Pano — 6/6

Color vision - normal.

Ht - 152

wt - 58.6.

BMI = 25.3

BP - 107 / 69

psr - 80

Hip - 99

ecg - 88

NAME:	Mrs. SANGITA KUMARI
AGE / SEX:	36 YRS/ FEMALE
DATE:	25/01/2024
REFERRED BY:	ARCOFEMI HEALTHCARE LIMITED

ABDOMINAL ULTRASONOGRAPHY REPORT

LIVER: Appear normal in size and echogenicity. No focal lesion seen. The intra hepatic biliary and portal venous radicals are normal. Portal vein and CBD is normal.

GALL BLADDER: moderately distended and appears normal. No abnormal wall thickening / pericholecystic fluid seen.

Pancreas: normal to the extend visualized.

SPLEEN: Normal in size and echo texture. No focal lesion noted

KIDNEYS: Both kidneys are normal in position, size and echo texture. Normal cortico-medullary differentiation is maintained. No calculus/ hydronephrosis on both sides.

PELVIC ORGANS:

Urinary bladder well distended and appears normal in size, contour and wall thickness.

Uterus is not visualized history of surgery.

Right ovary is not visualized separately. **Cyst measuring 5.4x4 cm noted arising from the right adenexa.**

Left ovary is not visualized.

No free fluid in the abdomen and pelvis.

IMPRESSION:

- ***Right adenexal cyst as described above.***

*To correlate clinically & with other investigations.
Not for medico-legal purpose*



DR. VIGNESH K

CONSULTANT RADIOLOGIST

Apollo Health and Lifestyle Limited

(CIN - U85110TG2000PLC115819)

Regd. Office: 1-10-60/62, Ashoka Raghupathi Chambers, 5th Floor, Begumpet, Hyderabad, Telangana - 500 016.

Ph No: 040-4904 7777, Fax No: 4904 7744 | Email ID: enquiry@apollohl.com | www.apollohl.com

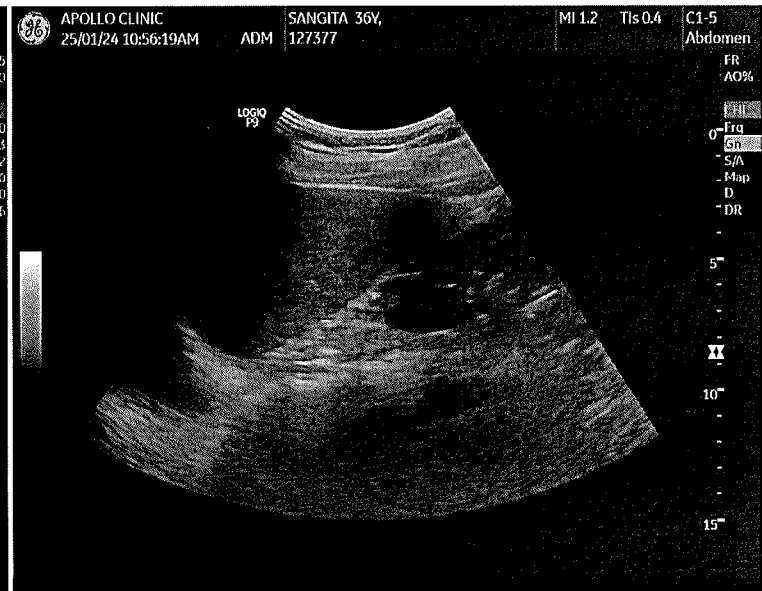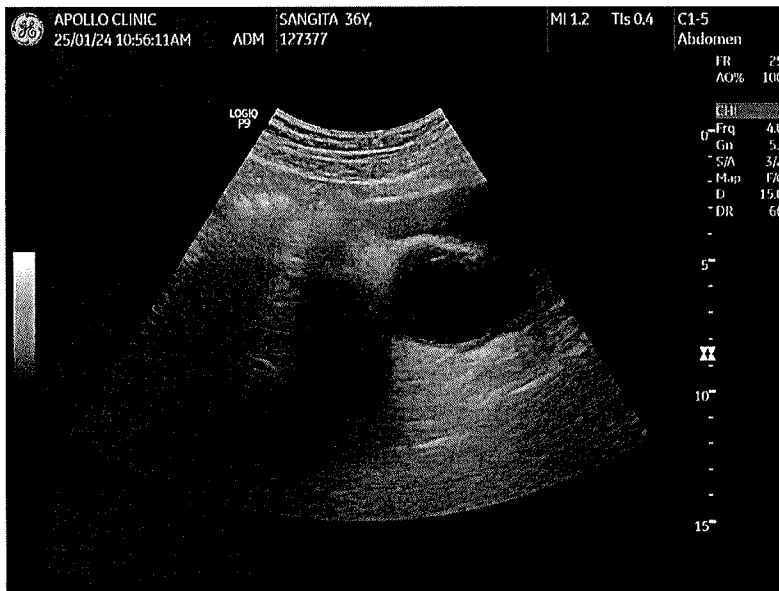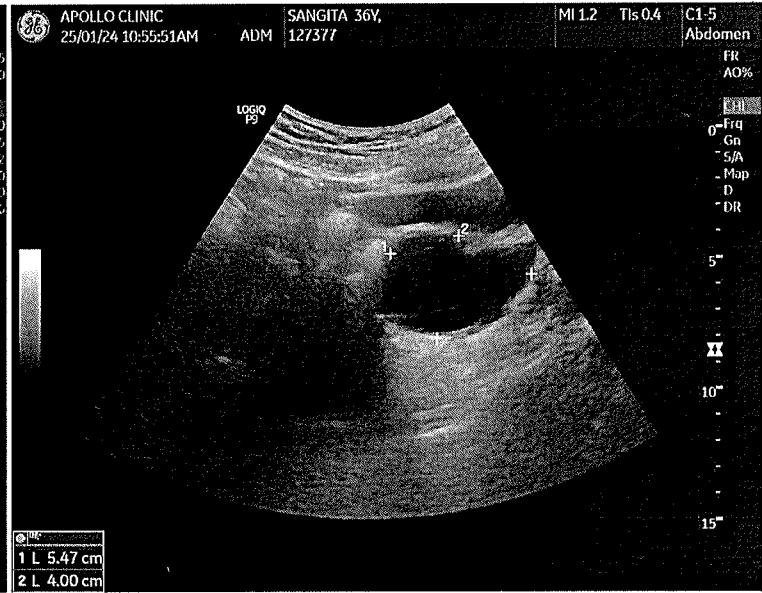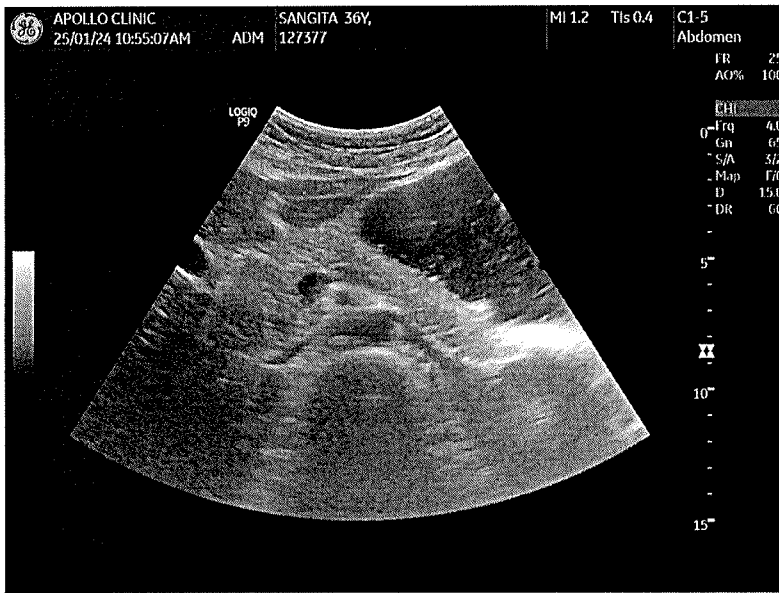
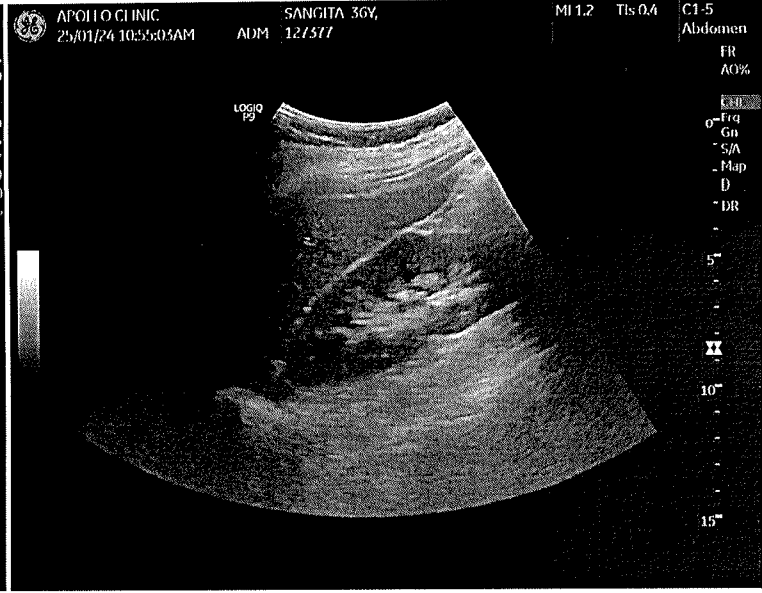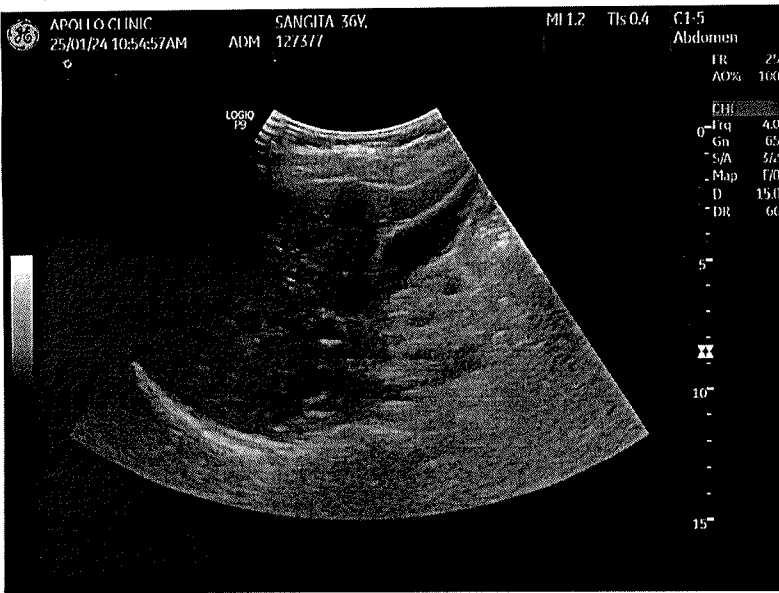
APOLLO CLINICS NETWORK KARNATAKA

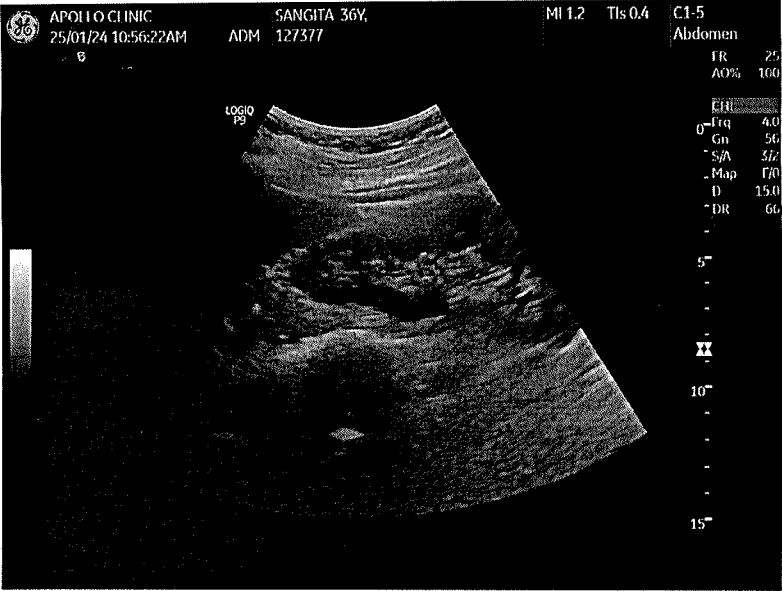Bangalore (Basavanagudi | Bellandur | Electronic City | Fraser Town | HSR Layout | Indira Nagar | JP Nagar | Kundalahalli | Koramangala | Sarjapur Road) **Mysore** (VV Mohalla)

Online appointments: www.apolloclinic.com

TO BOOK AN APPOINTMENT

 **1860 500 7788**





2-D ECHO-CARDIOGRAPHY DOPPLER & COLOUR DOPPLER REPORT

NAME : MRS SANGITA KUMARI

DATE :25/01/2024

AGE/SEX:36 Y / F

REF : ARCOFEMI

UHID:127377/01/81

***** MEASUREMENTS & FLOW VELOCITIES AS DEPICTED IN IMAGES OVERLEAF.**

1. NORMAL VALVES.
2. NORMAL FLOW ACROSS ALL VALVES.
3. NO MR/ AR/ TR.
4. NORMAL GREAT VESSELS.
5. NORMAL SYSTEMIC VEINS & AT LEAST 3 PULMONARY VEINS SEEN DRAINING INTO LA.
6. NORMAL SIZED CHAMBERS.
7. NO REGIONAL WALL MOTION ABNORMALITIES.
8. INTACT SEPTAE (IVS & IAS).
9. GOOD LV & RV SYSTOLIC FUNCTION.
10. PERICARDIUM : NORMAL
11. NO OBVIOUS VEGETATION / CLOTS.



DR (CAPT.)S.V KRISHNA RAO

MD (PGI), DNB (Card)

Senior Consultant – Cardiologist

Reg No : ANP 19780000746KTK

To correlate with clinical findings & other relevant investigations .

Apollo Health and Lifestyle Limited

(CIN - U85110TG2000PLC115819)

Regd. Office: 1-10-60/62, Ashoka Raghupathi Chambers, 5th Floor, Begumpet, Hyderabad, Telangana - 500 016.

Ph No: 040-4904 7777, Fax No: 4904 7744 | Email ID: enquiry@apollohl.com | www.apollohl.com

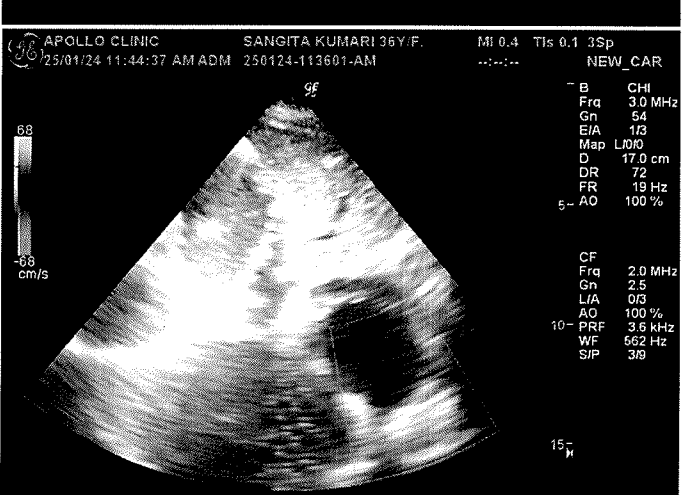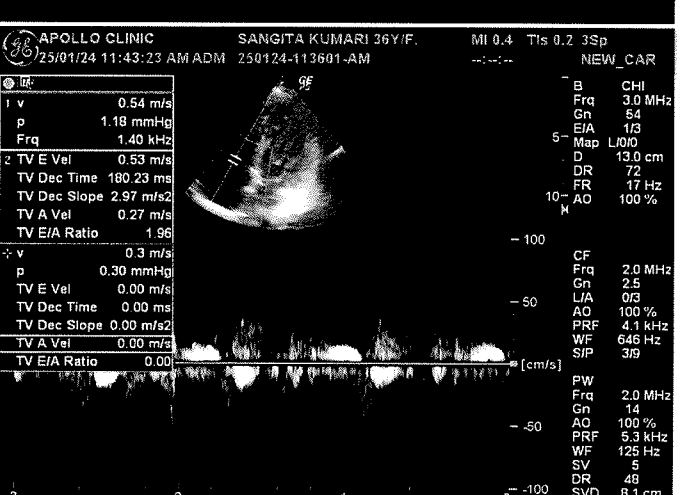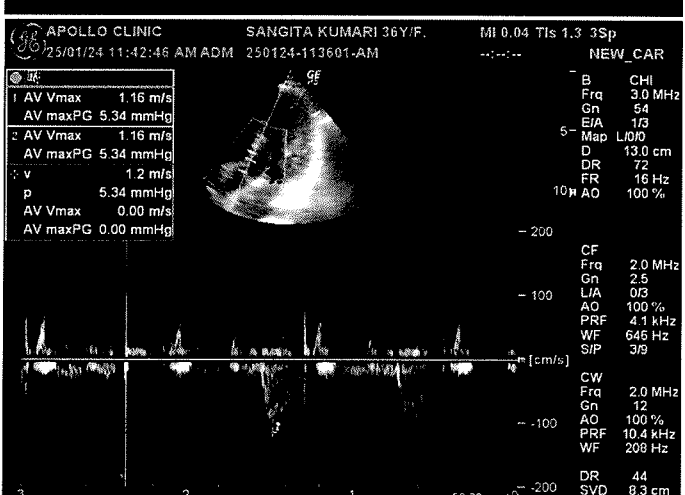
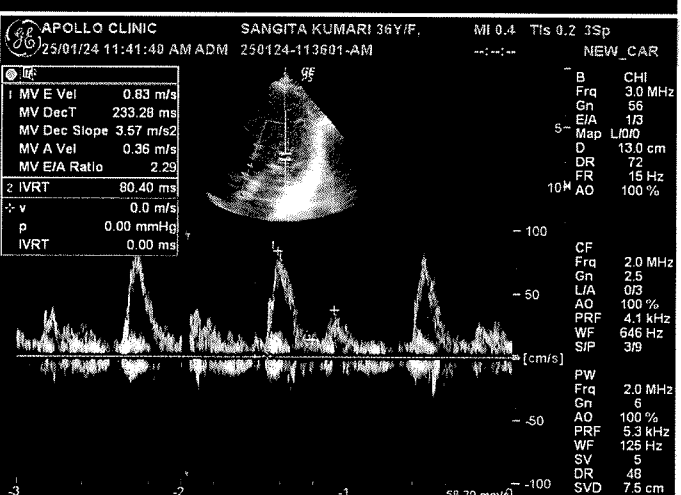
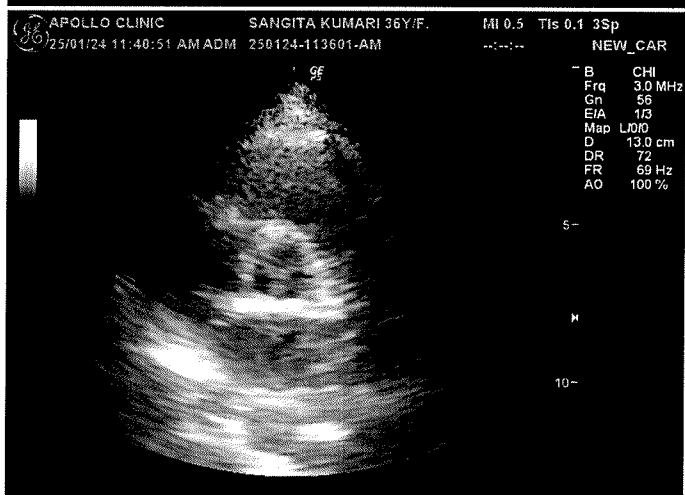
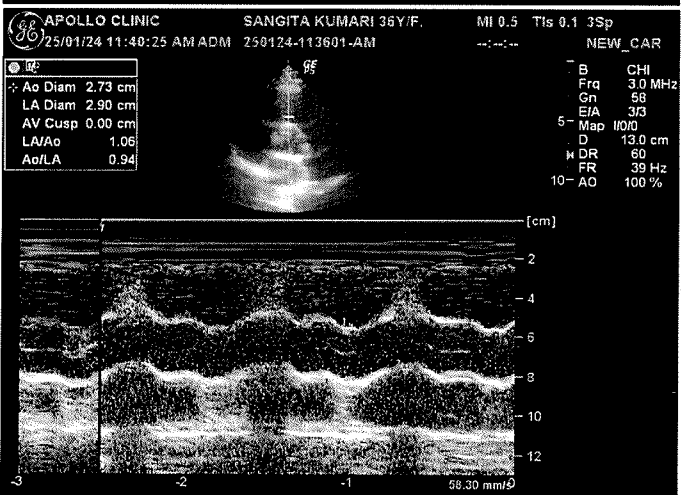
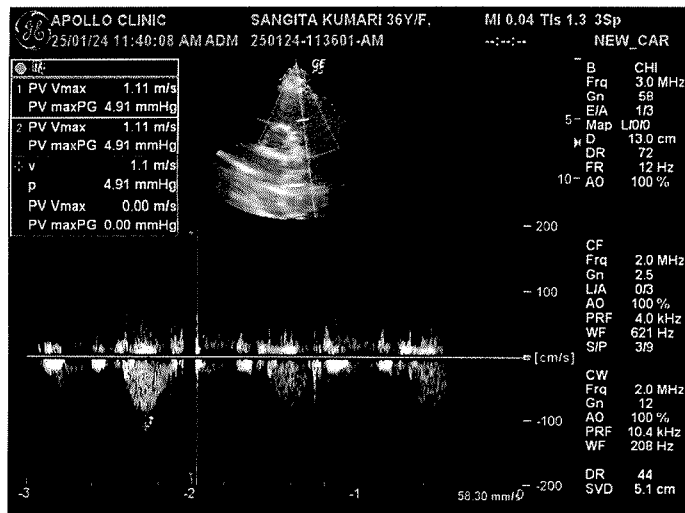
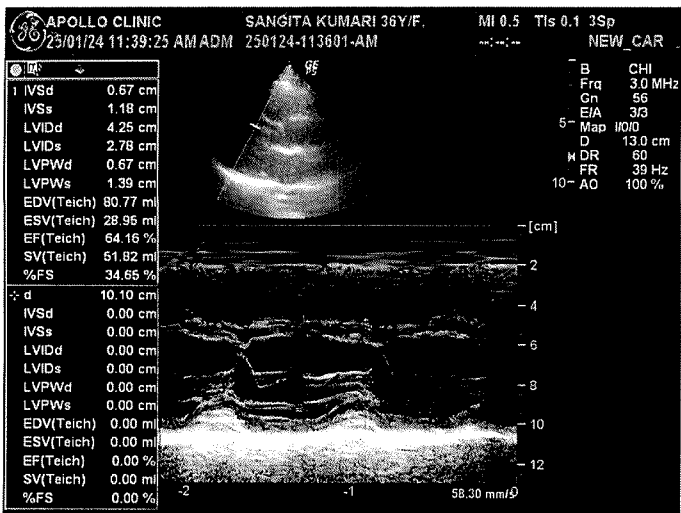
APOLLO CLINICS NETWORK KARNATAKA

Bangalore (Basavanagudi | Bellandur | Electronic City | Fraser Town | HSR Layout | Indira Nagar | JP Nagar | Kundalahalli | Koramangala | Sarjapur Road) **Mysore** (VV Mohalla)

Online appointments: www.apolloclinic.com

TO BOOK AN APPOINTMENT

 **1860 500 7788**



Personal Details
 UHID: 00XHE1PU6S7007K
 PatientID: 127377
 Name: Mrs Sangita Kumari
 Age: 36
 Gender: Female
 Mobile: 8880810509


Pre-Existing Medical- Symptoms
 Conditions

Vitals

Measurements
 HR: 69 BPM
 PR: 165 ms
 PD: 115 ms
 QRS: 85 ms
 QRS Axis: 50 deg
 QT/QTc: 369/395 ms

Report ID: AHLLP_00XHE1PU6S7007K_V6S700AZ
Interpretation
 Normal sinus rhythm
 Normal axis

This trace is generated by **KardiaStream Cloud Connected, Portable, Digital, 6/11 Lead Single-Strap ECG Platform from MEDRIX**

Authorized by

 Dr. Yogesh Kohari
 MD, DNB, FESC, FEP
 Reg. No. - KMC 44065

Apollo Medical Centre
 Apollo Hospitals
 Special Diagnostics

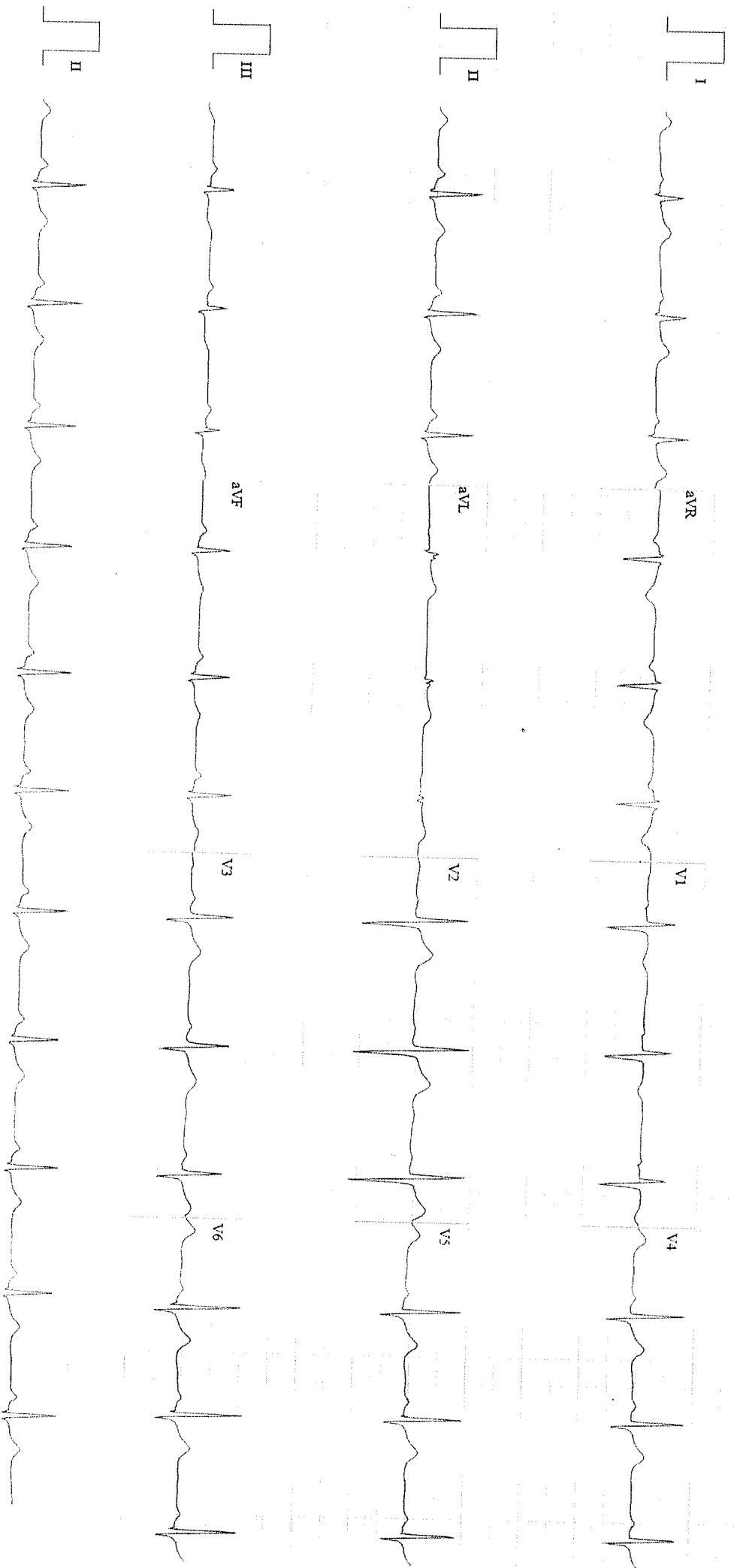


Figure 1: Analysis on this report is based on 12-lead ECG which should be used as an adjunct to the clinical history, symptoms and physical examination. It is not intended to be used as a substitute for a standard 12-lead ECG. Normal ECG does not rule out heart disease. Measurement of ECG wave and intervals from a single-lead ECG should not be used for diagnosis. Conduction system disease may not be detected by a single-lead ECG. **Speed: 25 mm/sec F: 0.05 - 40 Hz Limb: 10 mm/mV Chest: 10 mm/mV**

Patient Name	: Mrs. SANGITA KUMARI	Age	: 36 Y F
UHID	: CELE.0000127377	OP Visit No	: CELEOPV333571
Reported on	: 25-01-2024 12:47	Printed on	: 25-01-2024 12:59
Adm/Consult Doctor	:	Ref Doctor	: SELF

DEPARTMENT OF RADIOLOGY

X-RAY CHEST PA

Both lung fields and hila are normal .

No obvious active pleuro-parenchymal lesion seen .

Both costophrenic and cardiophrenic angles are clear .

Both diaphragms are normal in position and contour .


Thoracic wall and soft tissues appear normal.

CONCLUSION :

No obvious abnormality seen

Printed on:25-01-2024 12:47

---End of the Report---



Dr. VIGNESH K
MBBS, MD Radio-Diagnosis
Radiology

Apollo Health and Lifestyle Limited

(CIN - U85110TG2000PLC115819)

Regd. Office: 1-10-60/62, Ashoka Raghupathi Chambers, 5th Floor, Begumpet, Hyderabad, Telangana - 500 016.

Ph No: 040-4904 7777, Fax No: 4904 7744 | Email ID: enquiry@apollohl.com | www.apollohl.com

APOLLO CLINICS NETWORK KARNATAKA

Bangalore (Basavanagudi | Bellandur | Electronic City | Fraser Town | HSR Layout | Indira Nagar | JP Nagar | Kundalahalli | Koramangala | Sarjapur Road) **Mysore** (VV Mohalla)

Online appointments: www.apolloclinic.com

TO BOOK AN APPOINTMENT

 **1860 500 7788**

Mrs Sangita Kumari
36y / F

25 / 1 / 24

Dr. YASHASWI, MBBS, DLO
FELLOW IN RHINOLOGY
ALLERGY SPECIALIST
REG. No.: 71613
MOB.: 9448089291 / 9945126633

Height :	Weight :	BMI :	Waist Circum :
Temp :	Pulse :	Resp :	B.P :

General Examination / Allergies
History

Clinical Diagnosis & Management Plan

Came for regular ENT
check-up.

O/E (R) (L)
EAC (N) (W)
TM (R) (L)

Nose
Throat] NAD

Clinically ENT - NAD

(1) Soli wax ear drop
3^o - 3^o - 3^o
x 5 days

Follow up date:

Doctor Signature

Ms Sangita 38yr

25/1/2024.

Height :	Weight :	BMI :	Waist Circum :
Temp :	Pulse :	Resp :	B.P :

General Examination / Allergies
History

Clinical Diagnosis & Management Plan

Came for Master health
Check up

Lap. Hysterectomy done - 3 months
back. Breast - NAD

P2 L2
LSCS

P1 R Soft - N5 - , LSCS scar ⊕

Lap. Scar ⊕

P1 L vault ⊕

P1 V. vault ⊕

Adho

Review &
reports

Follow up date:

Doctor Signature



आयकर विभाग
INCOME TAX DEPARTMENT

भारत सरकार
GOVT OF INDIA



आयकर विभाग
Permanent Account Number Card
BKWP K8726B



05062020



आयकर दाता का नाम
SANGHVI, ANANDI

आयकर दाता का पता
MARBAYAN, HIRSAID SAHU

आयकर दाता का जन्म तिथि
01/03/1988

आयकर दाता का हस्ताक्षर



LETTER OF APPROVAL / RECOMMENDATION

To,

The Coordinator,
Mediwheel (Arcofemi Healthcare Limited)
Helpline number: 011- 41195959

Dear Sir / Madam,

Sub: Annual Health Checkup for the employees of Bank of Baroda

This is to inform you that the following employee wishes to avail the facility of Cashless Annual Health Checkup provided by you in terms of our agreement.

PARTICULARS	EMPLOYEE DETAILS
NAME	MRS. KUMARI SANGITA
EC NO.	72841
DESIGNATION	MSME CREDIT PROCESSING OFFICER
PLACE OF WORK	HOSUR,SSI HOSUR
BIRTHDATE	01-01-1988
PROPOSED DATE OF HEALTH CHECKUP	15-01-2024
BOOKING REFERENCE NO.	23M72841100083732E

This letter of approval / recommendation is valid if submitted along with copy of the Bank of Baroda employee id card. This approval is valid from **11-01-2024** till **31-03-2024** The list of medical tests to be conducted is provided in the annexure to this letter. Please note that the said health checkup is a **cashless facility** as per our tie up arrangement. We request you to attend to the health checkup requirement of our employee and accord your top priority and best resources in this regard. The EC Number and the booking reference number as given in the above table shall be mentioned in the invoice, invariably.

We solicit your co-operation in this regard.

Yours faithfully,

Sd/-

Chief General Manager
HRM Department
Bank of Baroda

(Note: This is a computer generated letter. No Signature required. For any clarification, please contact Mediwheel (Arcofemi Healthcare Limited))

SUGGESTIVE LIST OF MEDICAL TESTS

FOR MALE	FOR FEMALE
CBC	CBC
ESR	ESR
Blood Group & RH Factor	Blood Group & RH Factor
Blood and Urine Sugar Fasting	Blood and Urine Sugar Fasting
Blood and Urine Sugar PP	Blood and Urine Sugar PP
Stool Routine	Stool Routine
Lipid Profile	Lipid Profile
Total Cholesterol	Total Cholesterol
HDL	HDL
LDL	LDL
VLDL	VLDL
Triglycerides	Triglycerides
HDL / LDL ratio	HDL / LDL ratio
Liver Profile	Liver Profile
AST	AST
ALT	ALT
GGT	GGT
Bilirubin (total, direct, indirect)	Bilirubin (total, direct, indirect)
ALP	ALP
Proteins (T, Albumin, Globulin)	Proteins (T, Albumin, Globulin)
Kidney Profile	Kidney Profile
Serum creatinine	Serum creatinine
Blood Urea Nitrogen	Blood Urea Nitrogen
Uric Acid	Uric Acid
HBA1C	HBA1C
Routine urine analysis	Routine urine analysis
USG Whole Abdomen	USG Whole Abdomen
General Tests	General Tests
X Ray Chest	X Ray Chest
ECG	ECG
2D/3D ECHO / TMT	2D/3D ECHO / TMT
Stress Test	Thyroid Profile (T3, T4, TSH)
PSA Male (above 40 years)	Mammography (above 40 years) and Pap Smear (above 30 years).
Thyroid Profile (T3, T4, TSH)	Dental Check-up consultation
Dental Check-up consultation	Physician Consultation
Physician Consultation	Eye Check-up consultation
Eye Check-up consultation	Skin/ENT consultation
Skin/ENT consultation	Gynaec Consultation