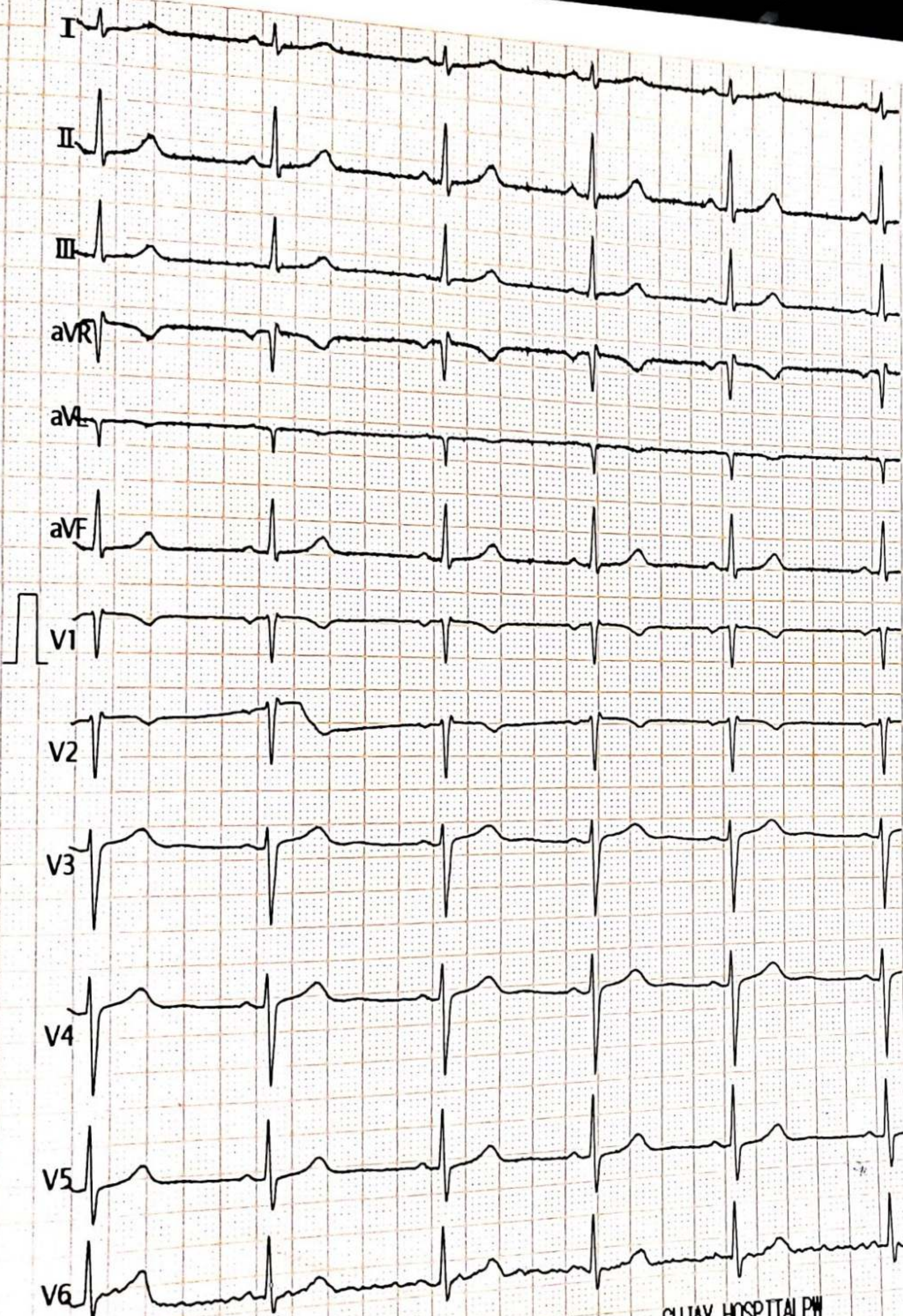


SUJAY HOSPITAL AND MATERNITY HOME
 JAYMALA BAVASKAR 27/01/2024 03 CHEST PA 27-Jan-24

10mm/mV



Vent. Rate(BPM) : 61
 PR Int.(ms) : 126
 P/QRS/T Int.(ms) : 82 93 192
 QT/QTc Int.(ms) : 409 413
 P/QRS/T Axis(Deg.) : 50 83 73
 RV1/SV5 Amp.(mV) : 0.03 0.49
 RV5/SV1 Amp.(mV) : 0.86 0.61

<ECG Analysis Result>
 800 Normal Sinus Rhythm
 500 rSR' Pattern in V1/V2
 *** Borderline Normal ECG ***

[Handwritten Signature]

Dr. Sunil Suryawanshi
 M.D.(Medicine)
 Reg.No.074611


V2.35 Technician :

Note : Unconfirmed Report Need to Review

ST LEVEL(mV)

| | | | | | |
|-------|-------|-------|-------|-------|-------|
| I | II | III | aVR | aVL | aVF |
| +0.01 | +0.01 | +0.00 | -0.01 | +0.00 | +0.00 |
| V1 | V2 | V3 | V4 | V5 | V6 |
| +0.01 | +0.02 | +0.07 | +0.07 | +0.01 | +0.00 |

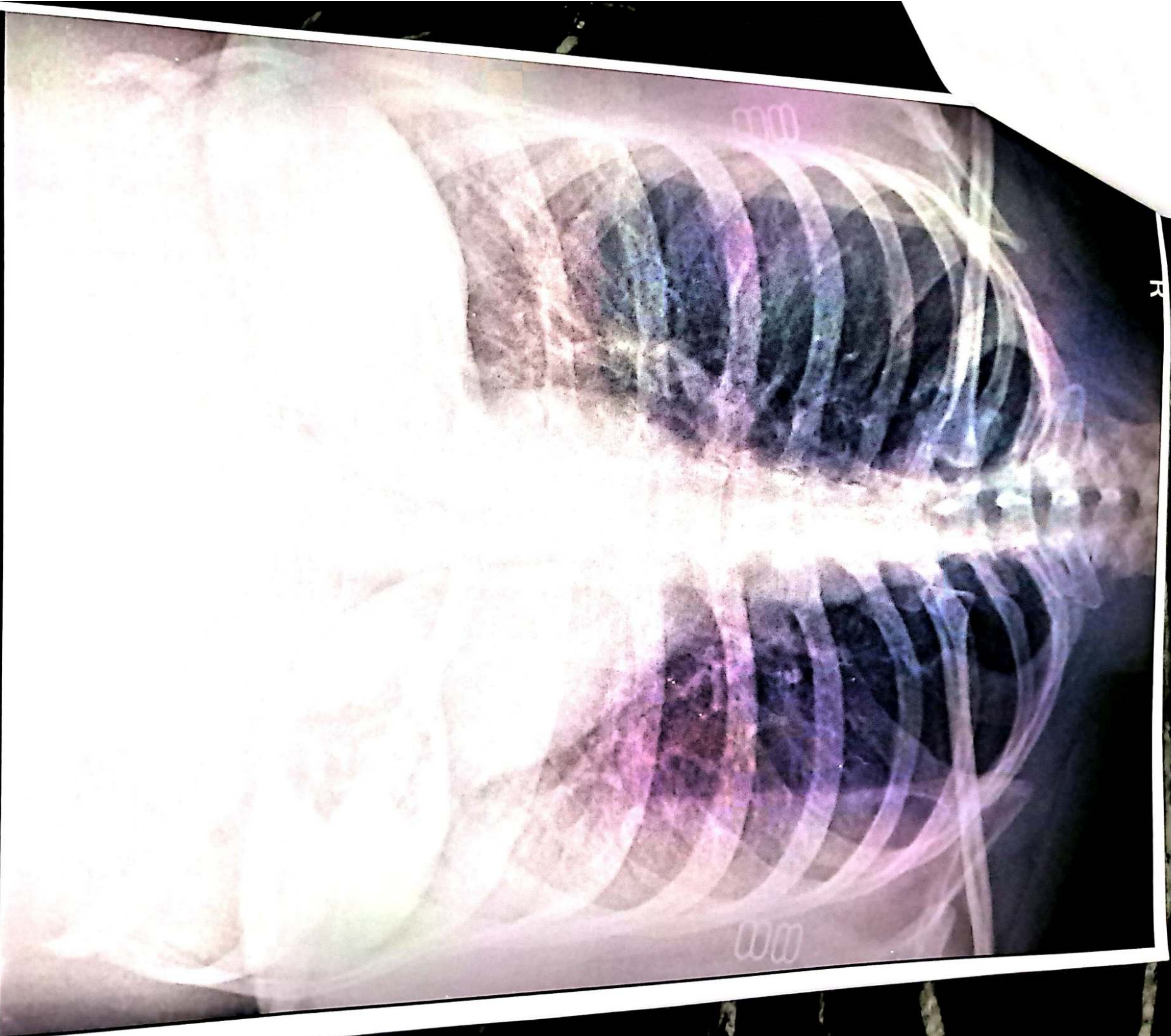
[Handwritten Signature]



<JAYMALA BAVASKAR> 224000003951 F 40Y 154/73 cm/Kg 125/79 mmHg

25mm/s ADS 2024-01-27 09:31:23

SUJAY HOSPITAL PW



JAYMALA BAVSKAR 27010202403

CHEST PA 27-Jan-24

SUJAY HOSPITAL AND MATERNITY HOME, JALGAON



Scanned with OKEN Scanner

DR. CHETAN S. KAKLIYA

M.B.B.S., D.M.R.D. (Sion Hospital, Mumbai University)

• Ex-Consultant Radiologist In Asian Heart Hospital (Mumbai)

• Ex - Radiologist Wockhardt Hospital (Mulund)



SAGAR IMAGING CENTRE

• Whole body sonography • Colour doppler • Digital X-ray

54-B, Onkar Nagar, Near Parikhpark, Jalgaon - 425001. Phone : 0257-2237634, e-mail : drchetanjj@rediffmail.com

| | | | |
|--------|--------------------|---------|---------------|
| Name | : JAYMALA BAVASKAR | Date | : 27-01-2024 |
| Ref By | : SUJAY HOSPITAL | Age/Sex | : 40 / Female |

SONOGRAPHY OF ABDOMEN AND PELVIS

The liver is normal in size, shape and has smooth margins. No focal lesion. The portal vein appears normal.

The gall bladder is physiologically distended. No evidence of calculus, wall thickening or mass lesion.

The common bile duct is normal in caliber. No evidence of calculus is noted in common bile duct.

The pancreas is normal in size, shape and echotexture. No focal lesion is noted.

The spleen is normal in size and shape. No evidence of focal lesion is noted.

There is no evidence of enlarged coeliac, mesentric, portal pre or para aortic lymph nodes.
No vascular mass lesion. No evidence of ascitis or pleural effusion.

Both kidneys are normal in size and echotexture. No evidence of calculus, hydronephrosis or cortical scarring.

Right kidney measures - 9.6 x 4.6 cms.

Left kidney measures - 10.9 x 4.9 cms.

The urinary bladder is well distended. No evidence of calculus, wall thickening or mass lesion.

Uterus is anteverted, bulky in size measures 9.3 x 5.6 x 5.4 cms and no focal lesion is noted. Few nabothian cysts are noted largest measures 8.0 mm.

The endometrium is well defined measures 7.0 mm and show echogenic area measures 23 x 10 mm with vascularity likely suggestive of polyp .

Both adnexa are clear. Both ovaries are normal and show small follicles
No evidence of free fluid or mass in pouch of Douglas.

IMPRESSION:

Bulky uterus with endometrium polyp.

Umbilical hernia is noted with herniation of omentum, anterior abdominal wall defect is 5.9 mm

REPORT WITH THANKS.

Clinico pathological correlation is suggested.


DR. CHETAN KAKLIYA





DR. CHETAN S. KAKLIYA

M.B.B.S., D.M.R.D. (Sion Hospital, Mumbai University)

• Ex-Consultant Radiologist In Asian Heart Hospital (Mumbai)

• Ex - Radiologist Wockhardt Hospital (Mulund)

SAGAR IMAGING CENTRE

• Whole body sonography • Colour doppler • Digital X-ray

54-B, Onkar Nagar, Near Parikhpark, Jalgaon - 425001. Phone : 0257-2237634, e-mail : drchetanjj@rediffmail.com

| | | | |
|--------|--------------------|---------|---------------|
| Name | : JAYMALA BAVASKAR | Date | : 27-01-2024 |
| Ref By | : SUJAY HOSPITAL | Age/Sex | : 40 / Female |

SONOGRAPHY OF BOTH BREAST

The skin is seen as homogenous echogenic band. The skin thickness is normal.

The nipple is visualised as well defined nodul, causing distal attenuation of sound beam. The sub areolar tissue is normal. The lactiferous duct is well visualised and is normal in caliber.

The subcutaneous fibro fatty tissue shows normal echo texture and is normal in thickness. There is no evidence of dilated lymphatics.

There is no evidence of enlarged intramammary lymph nodes.

The retromammary region consisting of fat ribs, and muscles is normal.

The axillary fat shows normal thickness and echo texture.

IMPRESSION :

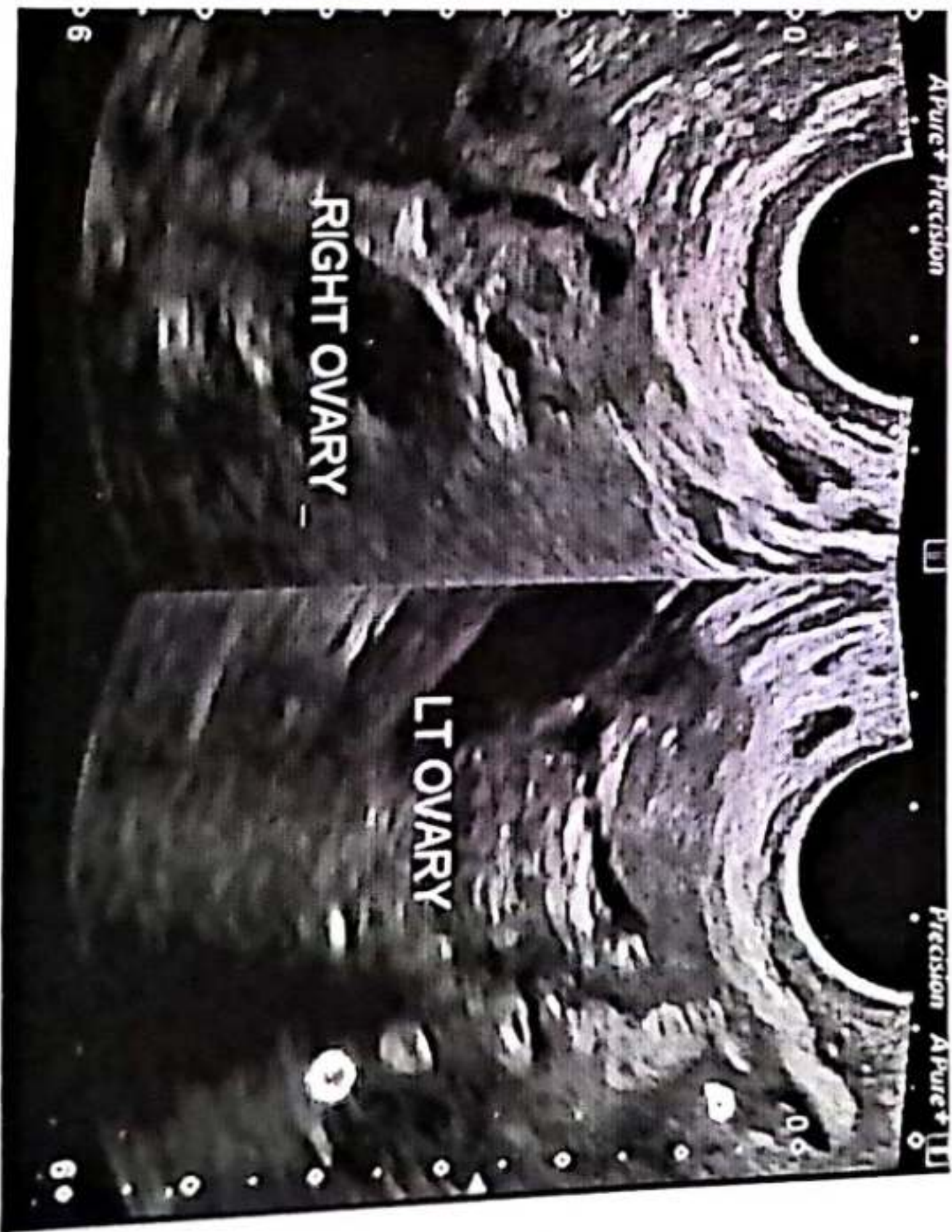
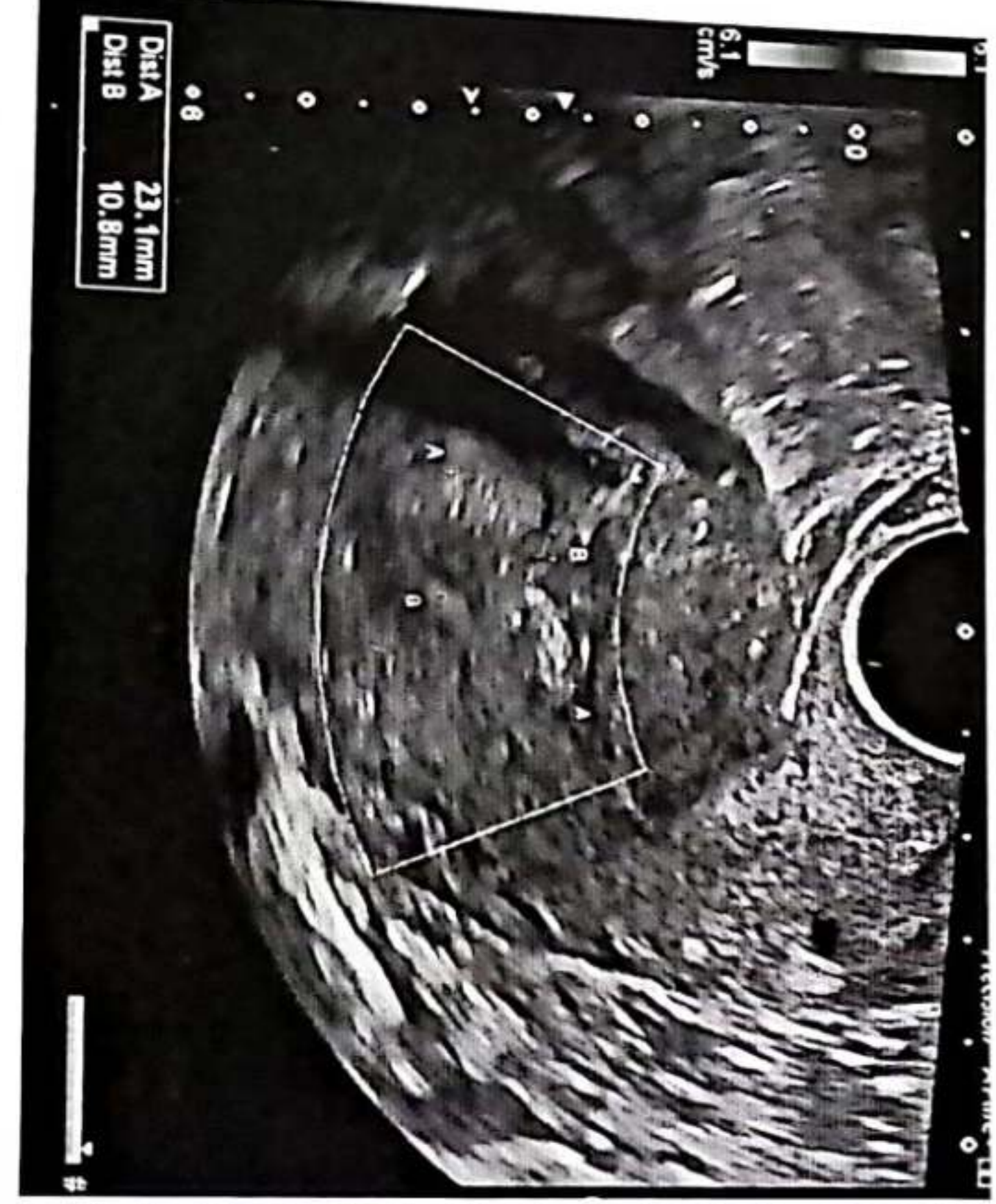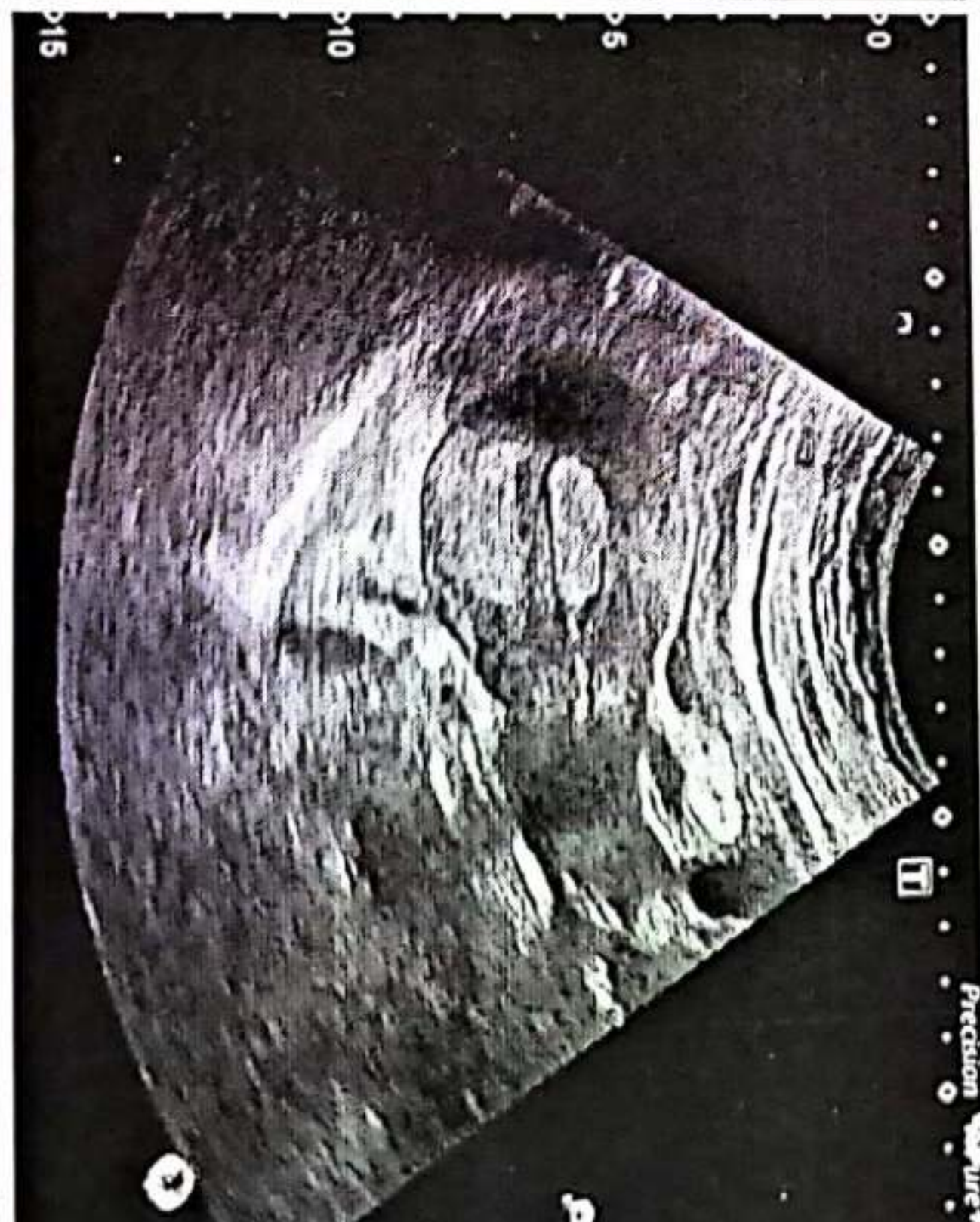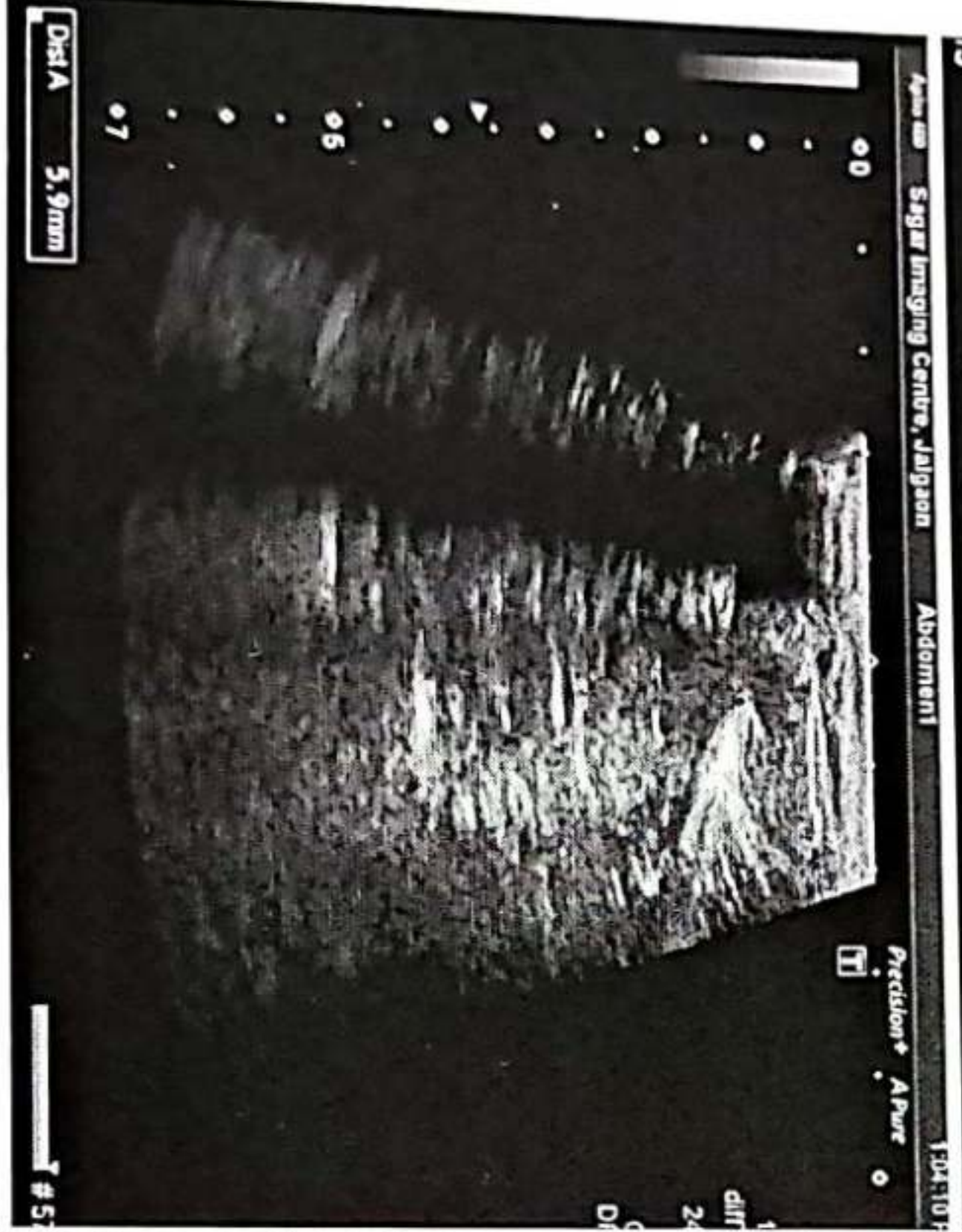
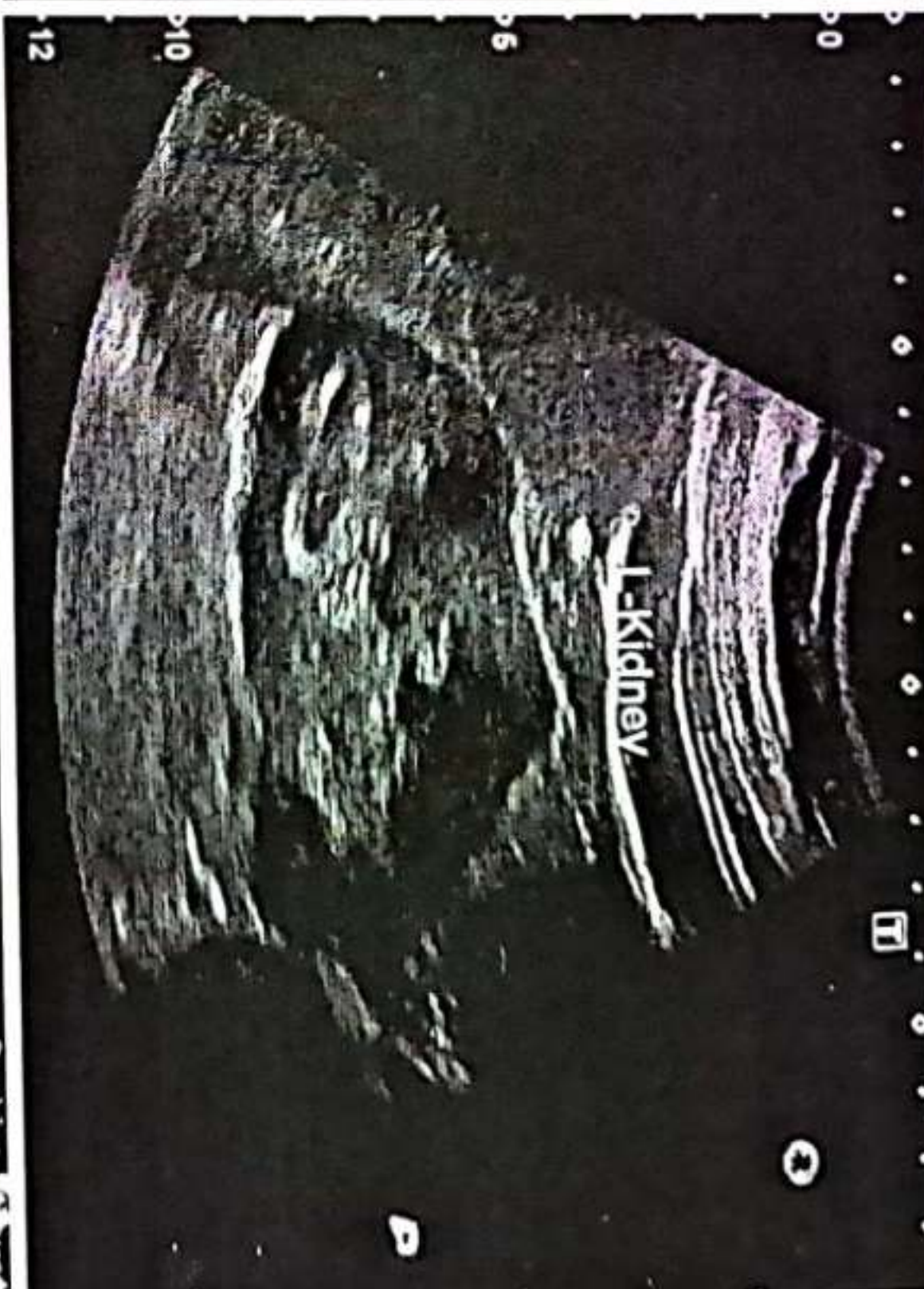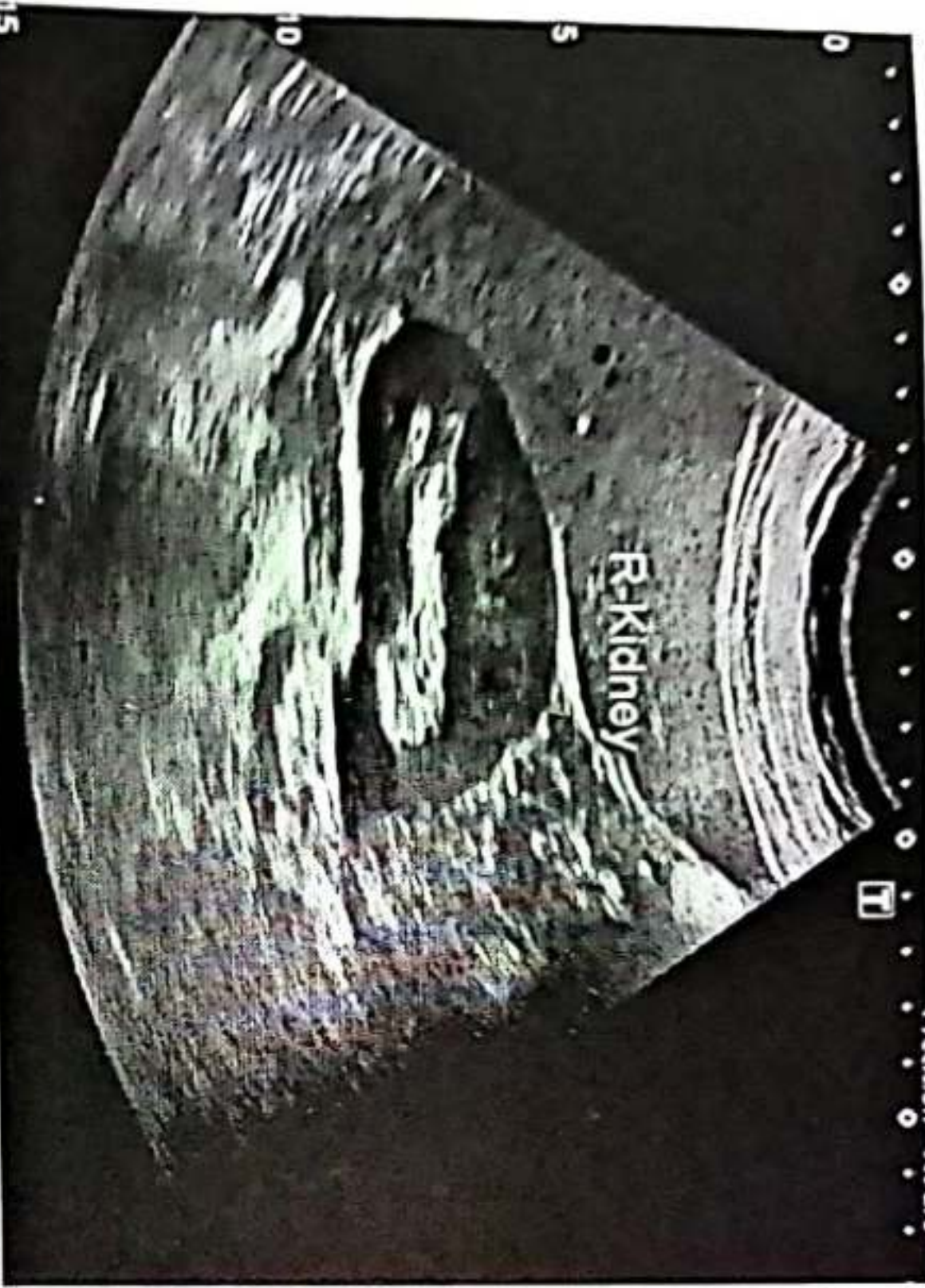
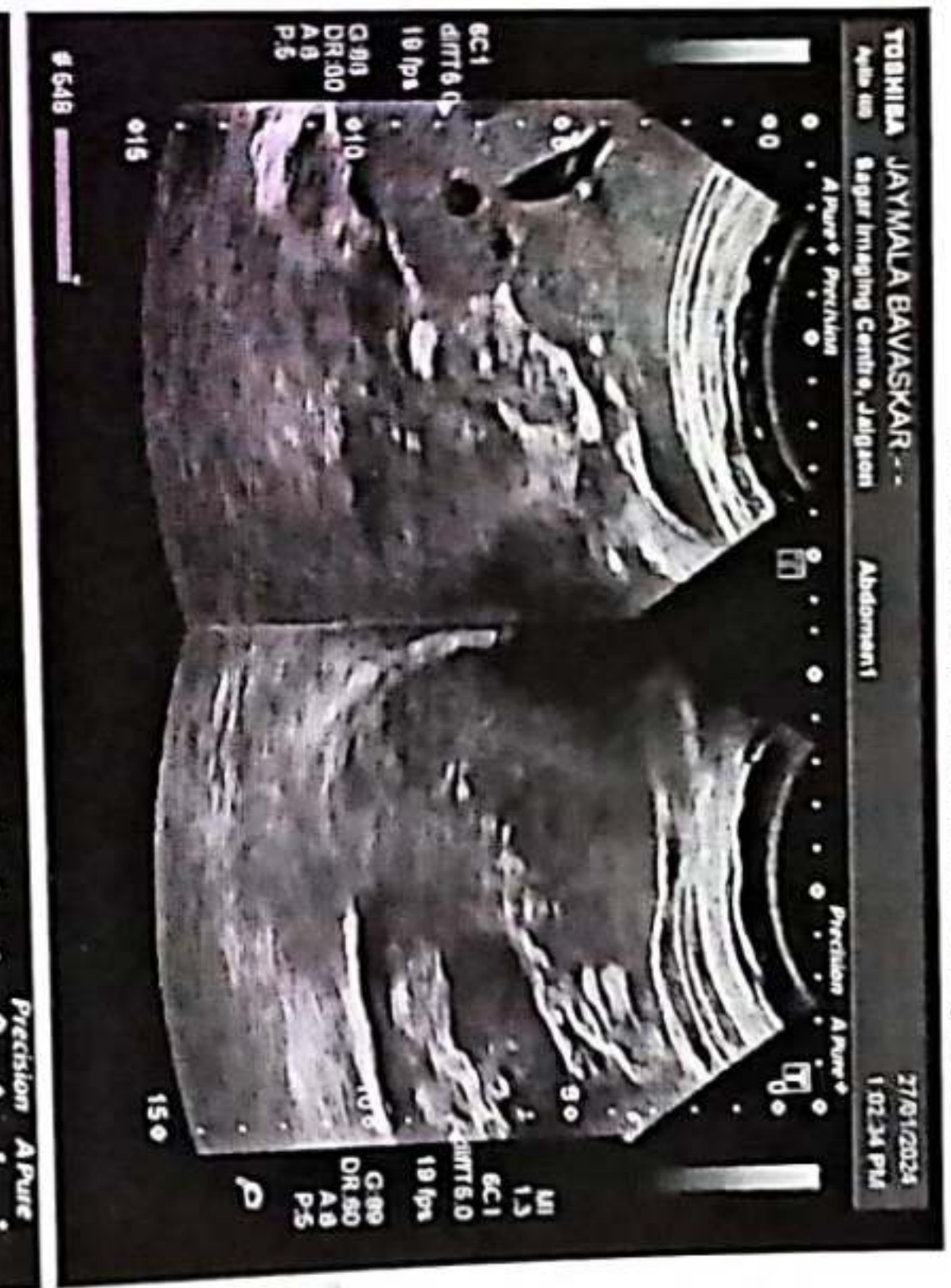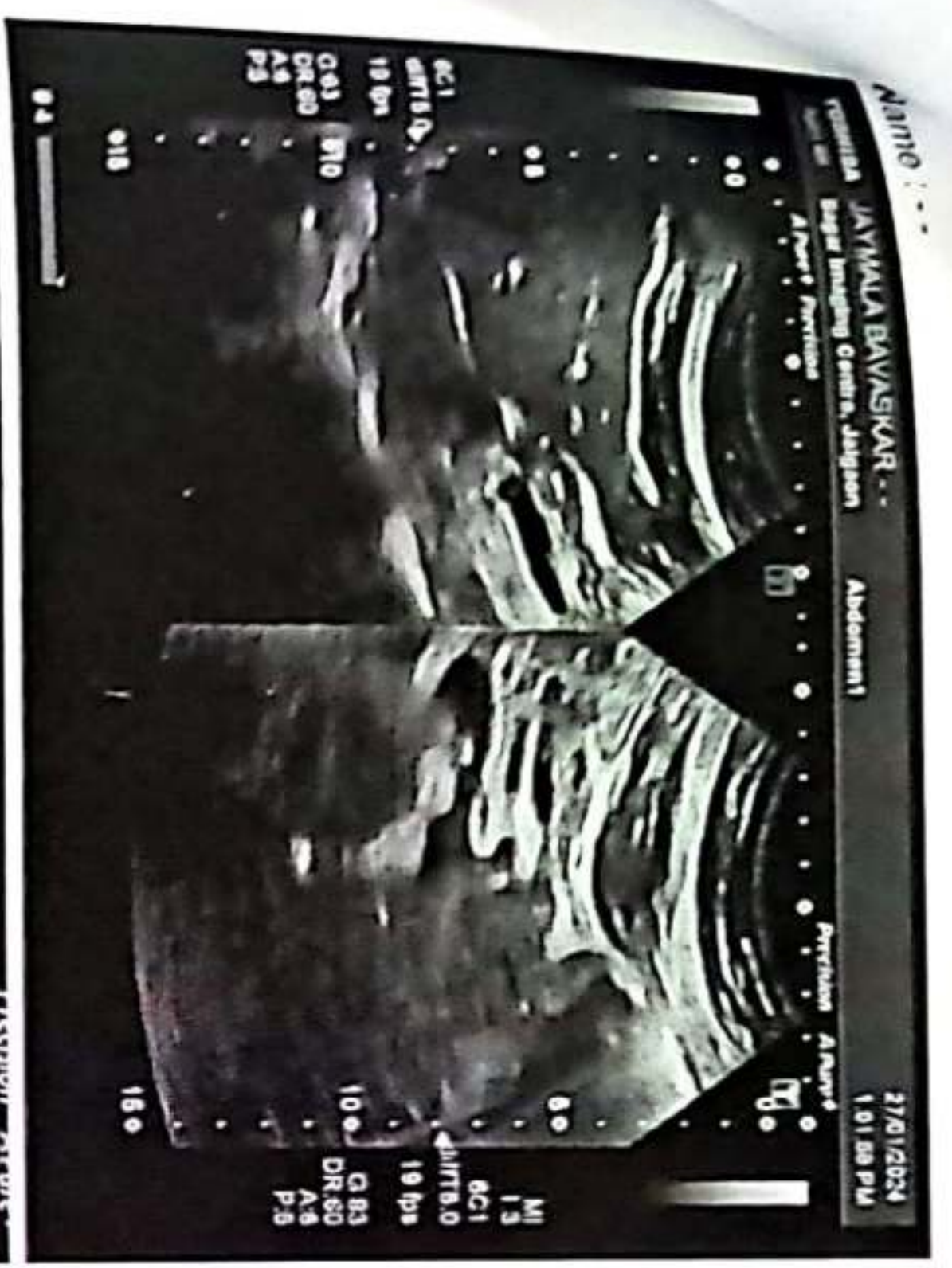Normal examination of breast.

**Histopathological correlation is suggested for confirmation
REPORT WITH THANKS.**

Clinico pathological correlation is suggested.

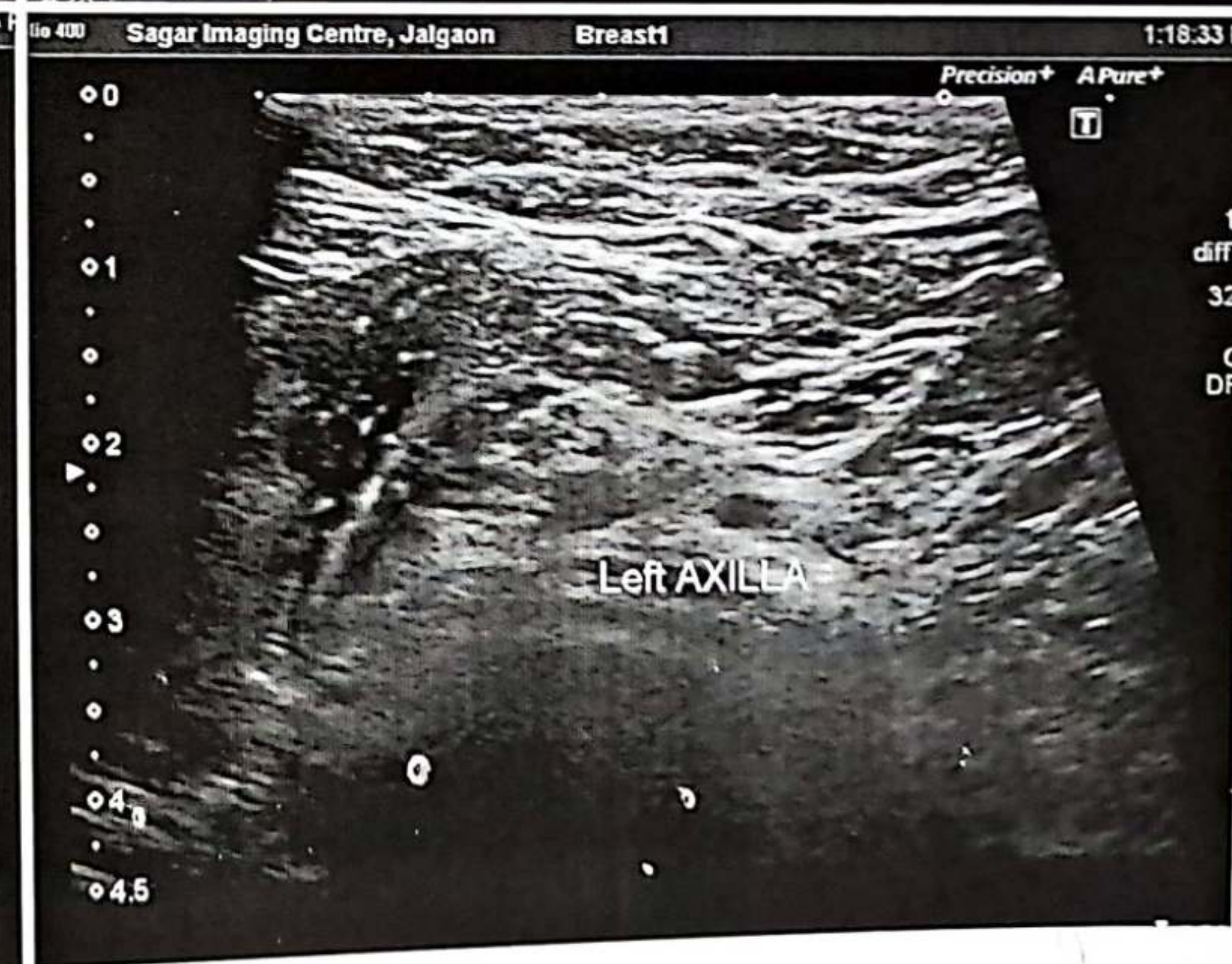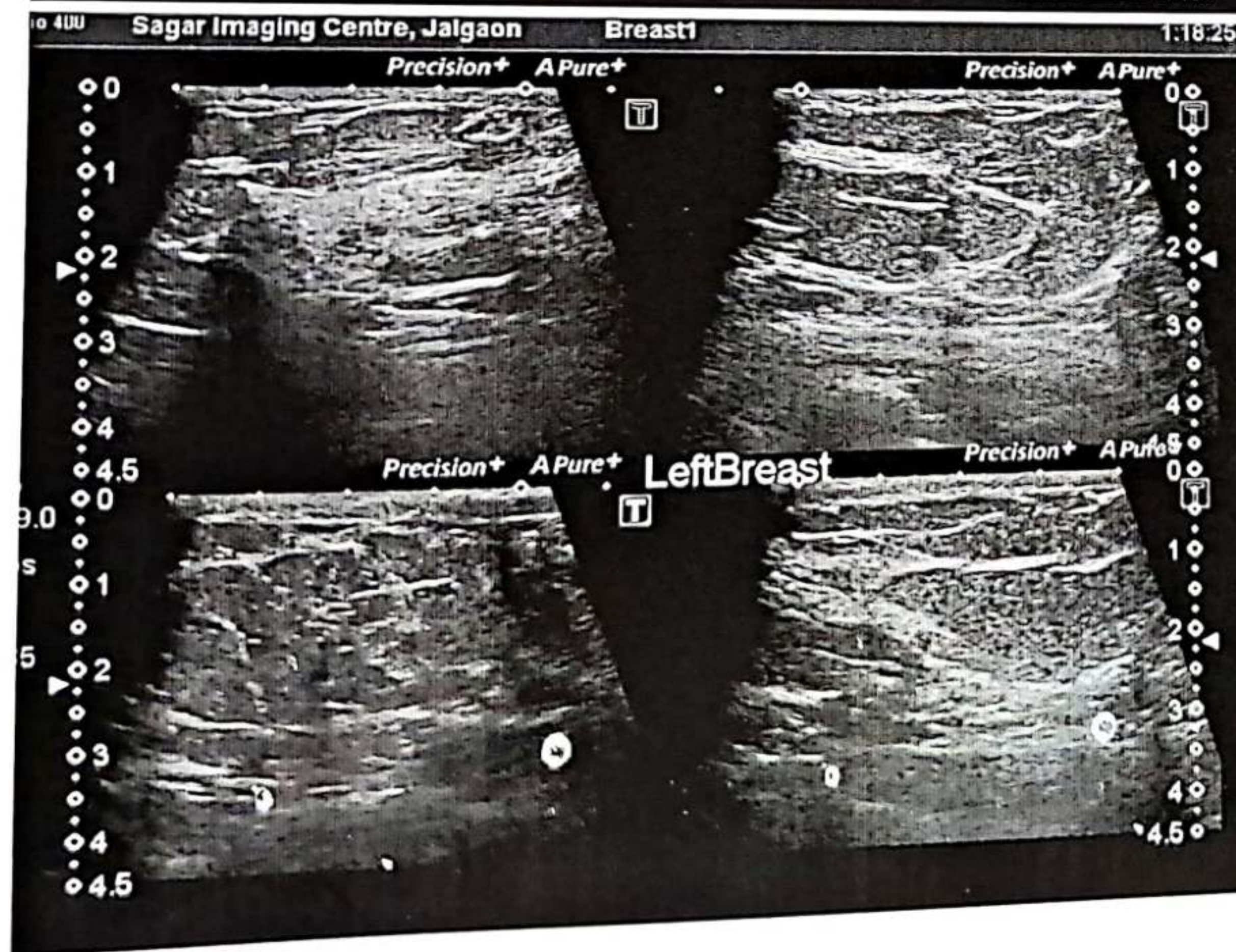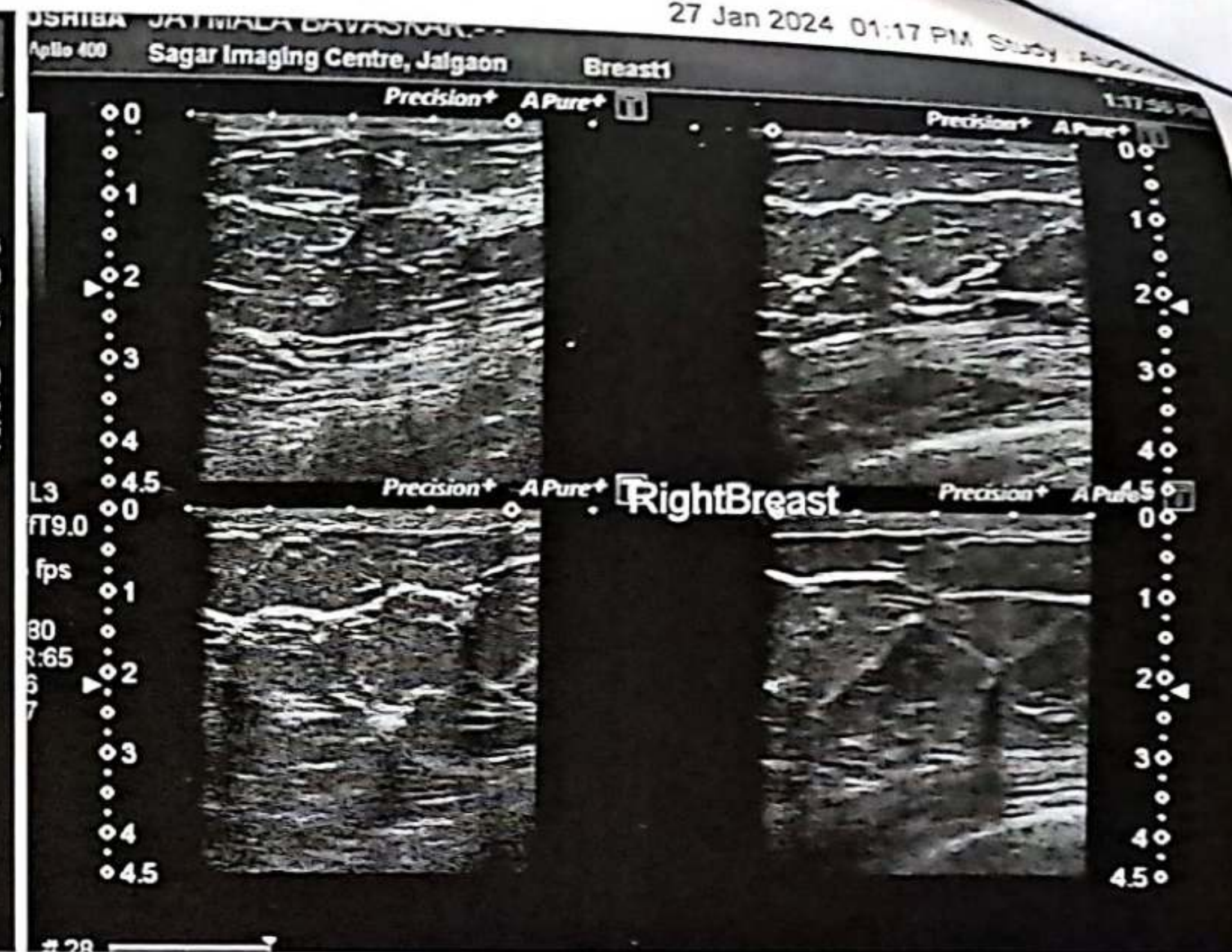
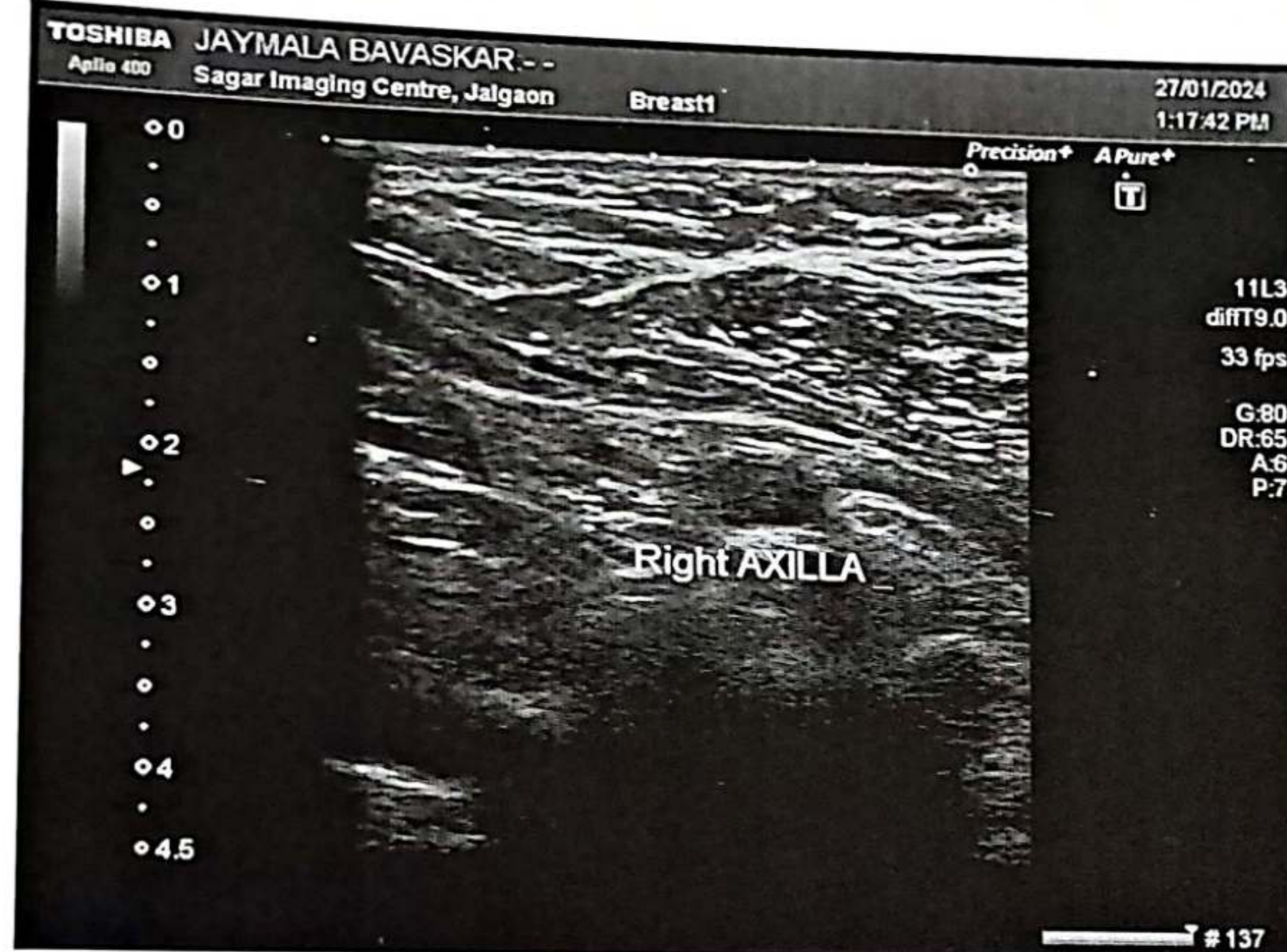
DR. CHETAN KAKLIYA





27 Jan 2024 01:01 PM Study : Abdomen

Name : --



जय हॉस्पिटल व मॅटर्निटी होम

अतिदक्षता विभाग

डॉ. सी. जयश्री सुर्यवंशी

एम.डी.
(स्त्रीरोग व प्रसूतीशास्त्र तज्ञ)
रजि.नं. 3712

डॉ. सुनिल सुर्यवंशी

एम.डी. (सेडीसीन) पुणे
कन्सल्टींग फिजिशियन
रजि.नं. 2223

पत्ता : मेन टेलिफोन एक्सचेंज समोर, पारिख
पार्क जवळ, नविन बस स्टॅन्डच्या मागे,
जळगाव. फोन : (0257) 2227821

उपलब्ध सुविधा : • एक्स-रे • सोनोग्राफी • इकोकार्डिओग्राफी • सुसज्ज ऑपरेशन थिएटर • कंप्यूटराइज्ड इ.सी.जी. • स्टेस टेस्ट • पल्समोमीटर फॅकशन टेस्ट

R

दि / / २०

2D – ECHOCARDIOGRAPHY

Name – JAYMALA VISHAL BAVASKAR


Age- 40 Yrs FEMALE

Date – 27/01/2024

IMPRESSION –

- NORMAL SIZE CARDIAC CHAMBERS.
- STRUCTURALLY NORMAL CARDIAC VALVES.
- NORMAL LV SYSTOLIC FUNCTION . EF –60 %.
- NORMAL LV DIASTOLIC FUNCTION.
- NO RWMA.
- NO CLOTS OR VEGETATION.
- IAS AND IVS INTACT.
- NORMAL PERICARDIUM.

Dr Sunil Suryawanshi


M.D Medicine,
Dr. Sunil Suryawanshi
M.D. (Medicine)
Reg No 074611

परत येतांना कागद सोबत आणावा.

सुरज्य हॉस्पिटल व मॅटर्निटी होम

अतिदक्षता विभाग

डॉ. सौ. जयश्री सुर्यवंशी

डॉ. सुनिल सुर्यवंशी

पता : मेन टेलिफोन एक्सचेंज समोर, पारिख

एम.डी.
(स्त्रीरोग व प्रसूतीशास्त्र तज्ञ)

एम.डी. (पेडियाट्री) पूर्ण
कमाल्डीग फिजिशियन

पार्क जवळ, नविन बस स्टॅण्डच्या मागे,
जळगांव. फोन : (0257) 2227821

रजि.नं. 3712

रजि.नं. 2223

उपलब्ध सुविधा : • एक्स-रे • सोनोग्राफी • इकोकार्डिओग्राफी • सुसज्ज ऑपरेशन थिएटर • कार्ड्योटांगुलर डी.सी.जी. • स्ट्रेस टेस्ट • फ्लोमॅट्री फॅक्शन टेस्ट

दि / / २०

R

X-RAY CHEST PA VIEW

NAME- JAYMALA VISHAL BAVASKAR

AGE- 40 YRS FEMALE DATE- 27.01.24

SOFT TISSUE AND SKELETON NORMAL.

BOTH HILA ARE NORMAL IN SIZE AND HAVE EQUAL DENSITY.

NORMAL CARDIAC SIZE.

NORMAL BRONCHOVASCULAR MARKINGS.


LUNGS SHADOW NORMAL.

COSTOPHRENIC AND CARDIOPHRENIC ANGLES ARE CLEAR.

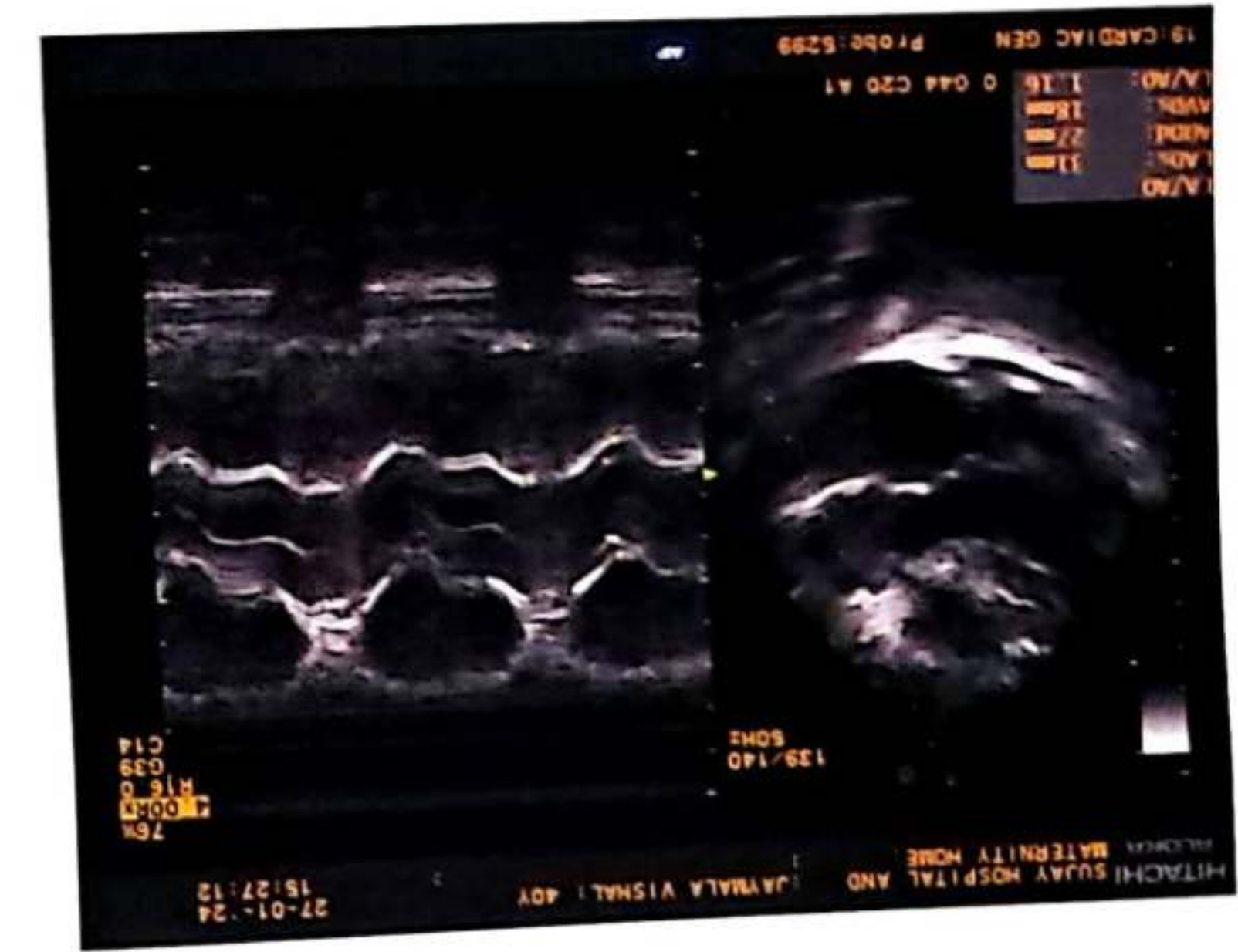
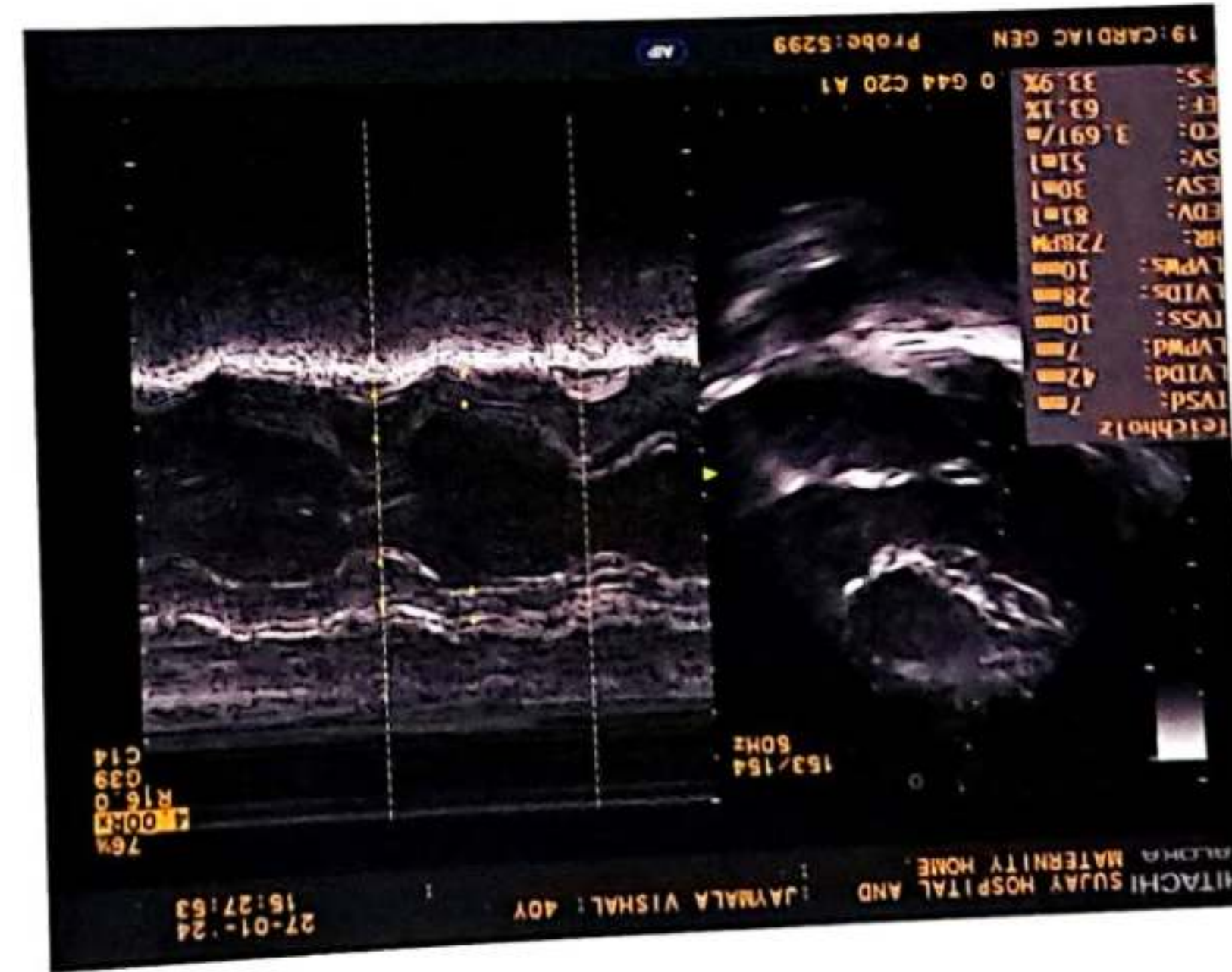
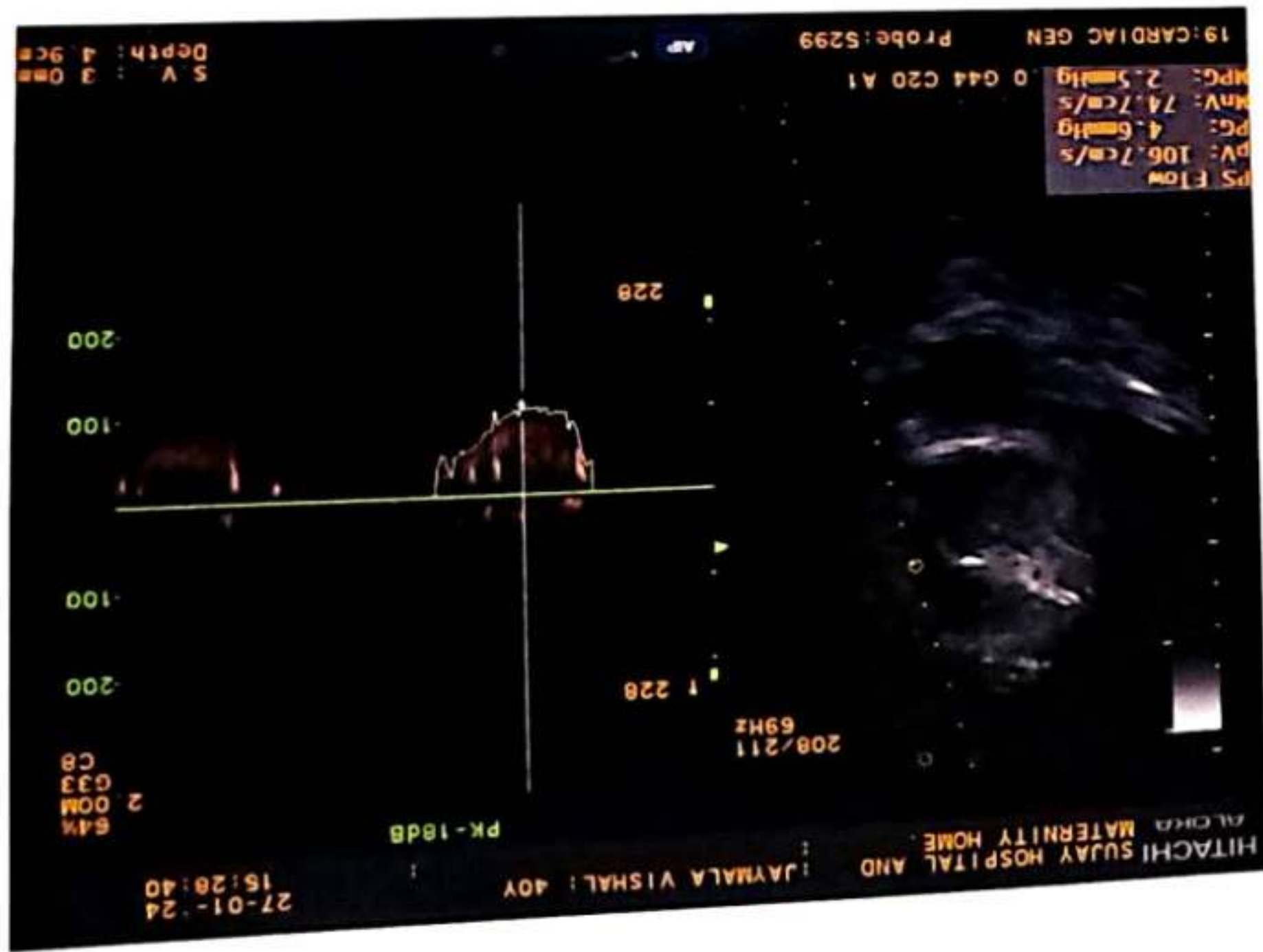
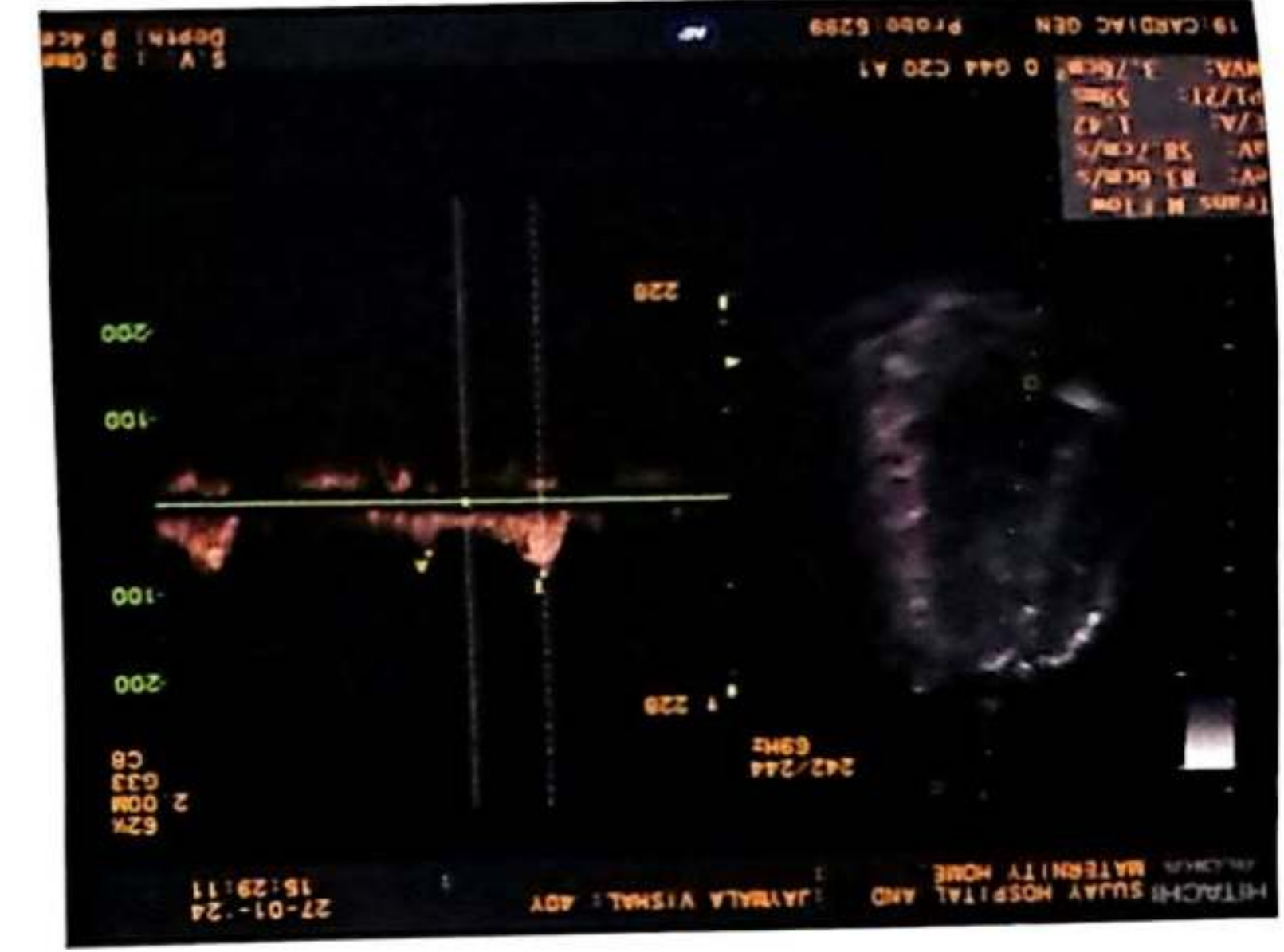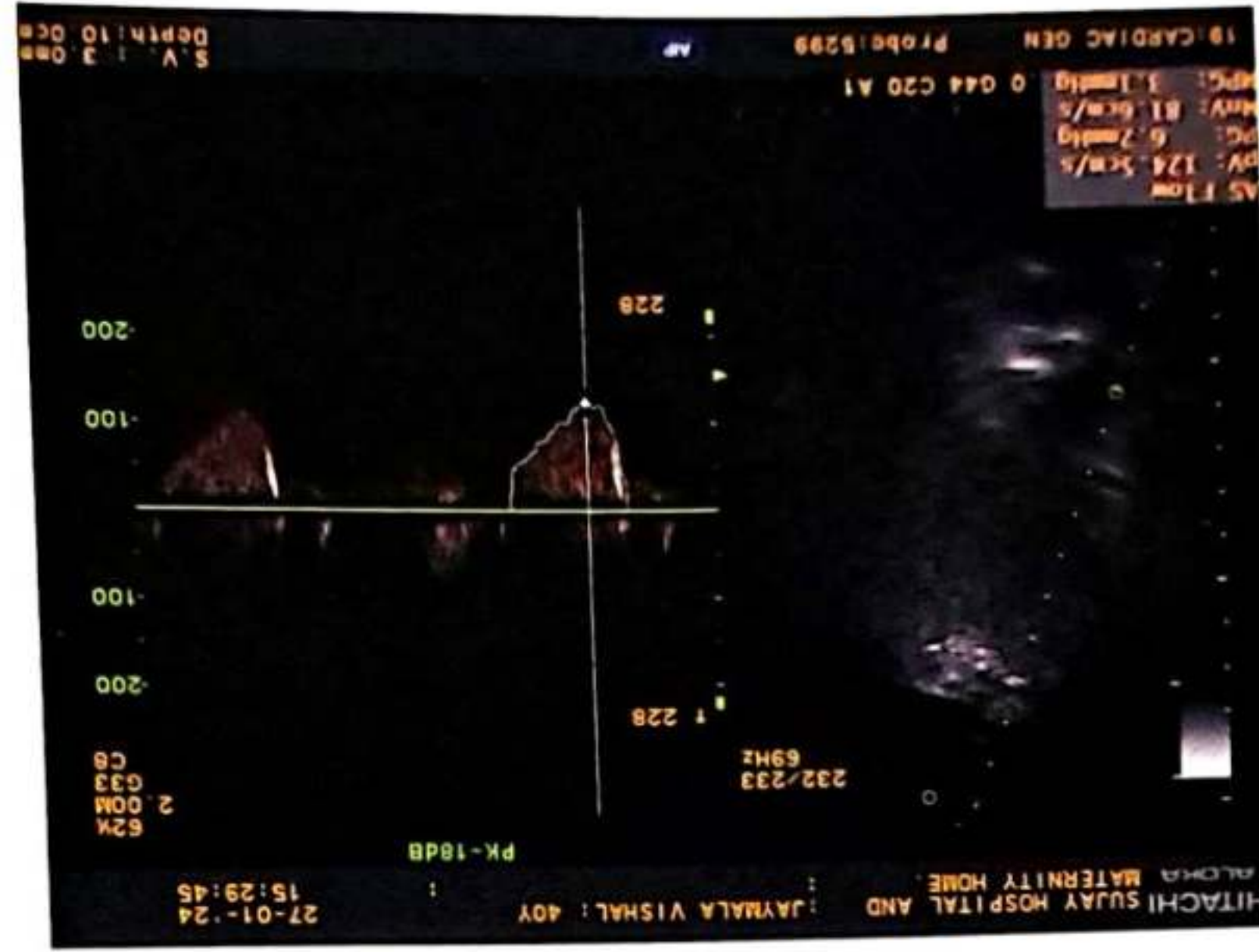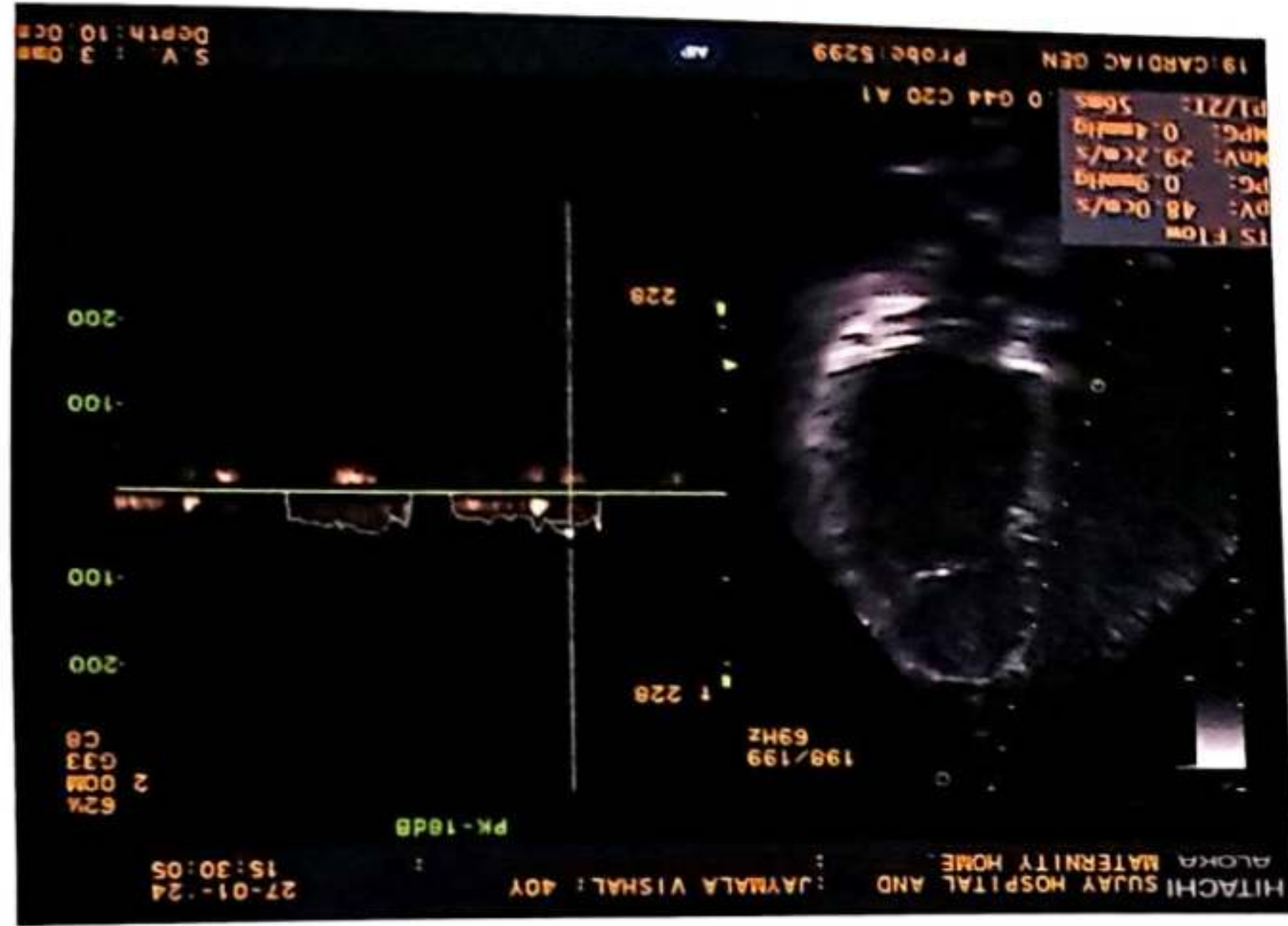
THE DOMES OF DIAPHRAGMS ARE NORMAL IN POSITION AND SHOW
SMOOTH OUTLINE.

IMPRESSION -

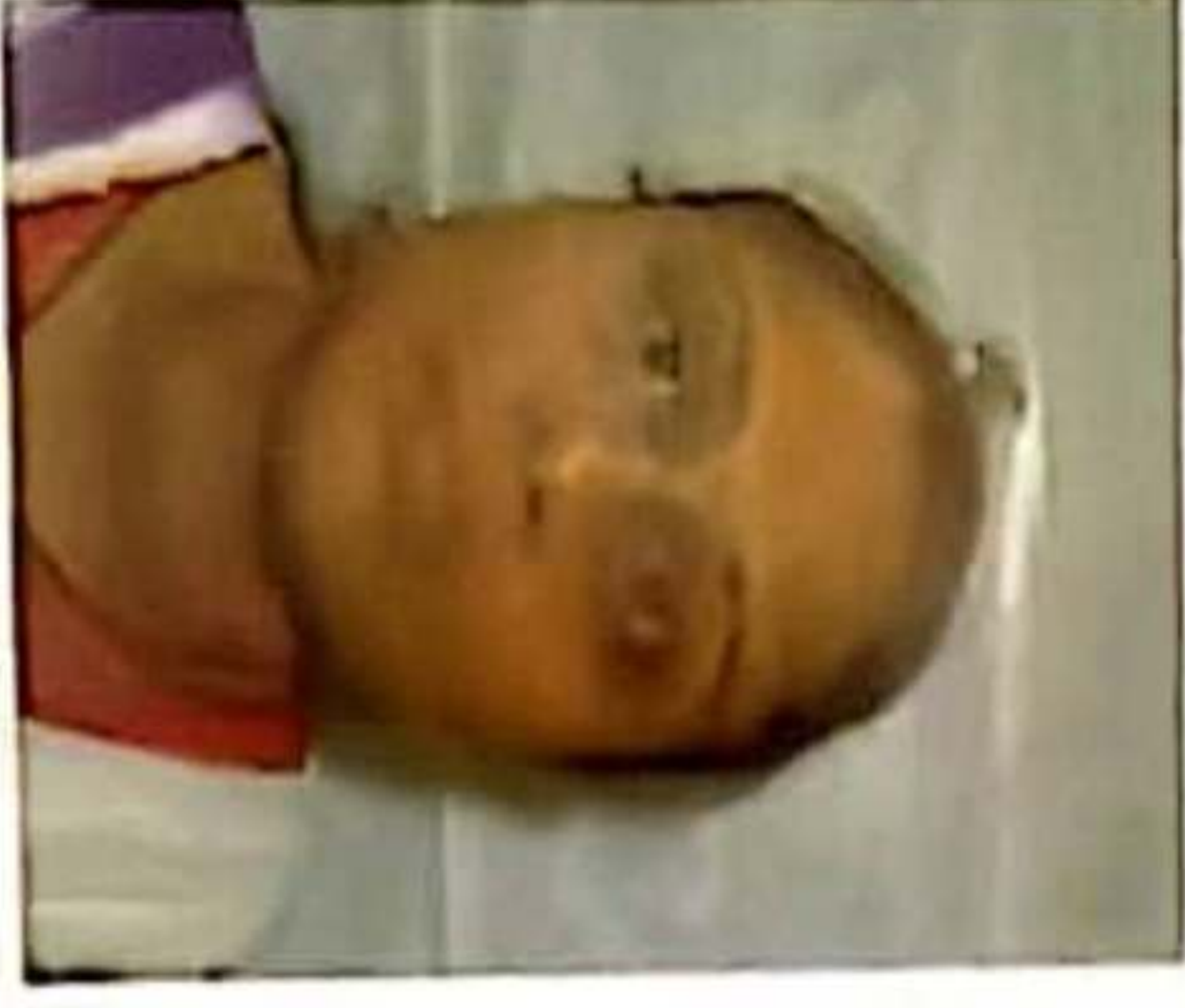NORMAL XRAY CHEST.


Dr. Sunil Suryawanshi
M.D. (Medicine)
Reg. No. 074611

परत येतांना कागद सोबत आणावा.



Issue Date: 27/04/2015



भारत सरकार
Government of India

जयमाला विशाल बावस्कर

Jayamala Vishal Bavaskar

जन्म तारीख/DOB: 31/05/1983

महिला/ FEMALE

2417 8334 7110

UID : 9129 3080 3243 8000

माझी आधार, माझी ओळख

माझी आधार

माझी ओळख

दान प्रतिबंधक
डॉक्टरांना 3 वर्ष
ची शिक्षा आहे.
दुबियांना 5 वर्ष
शिक्षा आहे.
००२३३४४७५
NDT ACT
Doctors involved
at imprisonment
fine. Patients
termination are
for 5 yrs. & Rs.
18002334475

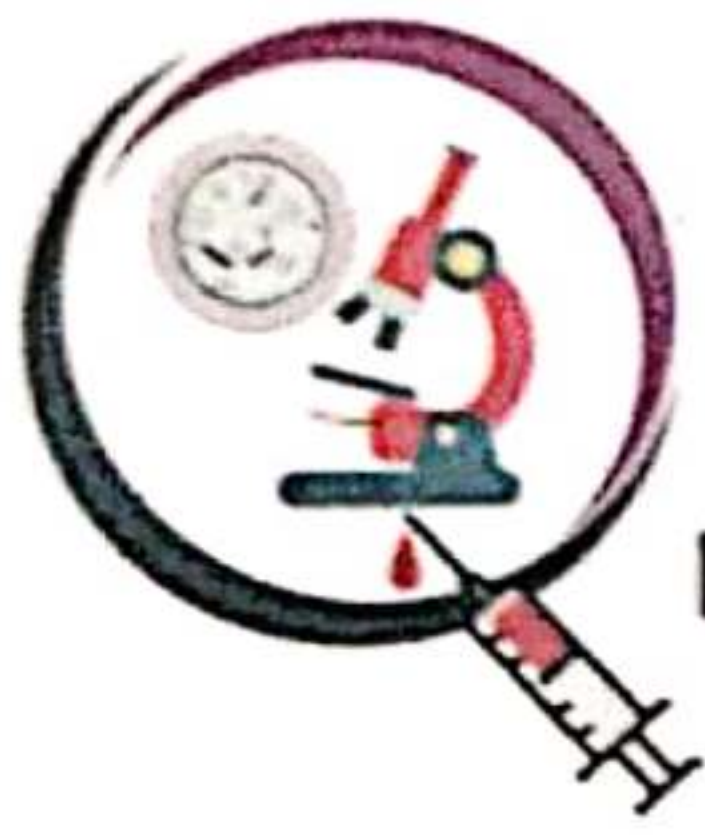बालरोग तज्ञ (एम.डी. बालरोग)



GPS Map Camera



Jalgaon, MH, India
Jaikisan Wadi, Jalgaon, 425001, MH, India
Lat 21.006527, Long 75.566752
01/27/2024 09:33 AM GMT+05:30
Note : Captured by GPS Map Camera



Manavata

Pathology & Microbiology Laboratory

Dr. Kailash B. Wagh

M.D. Microbiology D.C.P
Reg No. 2001/07/2704

REG NO. : 01-2024-OPD / 10
NAME : Mrs. JAYMALA V.BAVASKAR
REF BY : Dr . Sunil Suryavanshi (Insurance)
M.D.

AGE : 40 Years
SEX : Female
DATE : 27-Jan-2024

LOCATION :

HAEMOGRAM

| <u>TESTS</u> | <u>RESULTS</u> | <u>UNIT</u> | <u>REFERENCE RANGE</u> |
|---------------------------|-------------------------|-------------|------------------------|
| Haemoglobin | : 11.8 | g/dl | 11 - 18 |
| WBC COUNT | | | |
| Total WBC Count | : 4600 | /cmm | 4000 - 11000 |
| DIFFERENTIAL COUNT | | | |
| Neutrophil | : 64 | % | 40 - 74 |
| Lymphocyte | : 25 | % | 15 - 45 |
| Eosinophil | : 05 | % | 0 - 7 |
| Monocyte | : 06 | % | 1 - 10 |
| Basophil | : 00 | % | 0 - 1 |
| RBC INDICES | | | |
| Hct | : 34.8 | % | 33 - 60 |
| R.B.C. count | : 4.56 | mil./cmm. | 4.0 - 6.0 |
| Mcv | : 83.2 | fL | 76 - 94 |
| Mch | : 29.3 | pg | 25 - 33 |
| Mche | : 34.5 | % | 32 - 38 |
| PLATELETS INDICES | | | |
| Plt Count | : 188000 | /cmm | 150000 - 450000 |
| RBC Morphology | : Normocytic Normocytic | | |
| WBC Studies | : Normal Morphology | | |
| Platelet | : Adequate | | |
| ESR | : 15 | mm/hr | 00 - 20 |

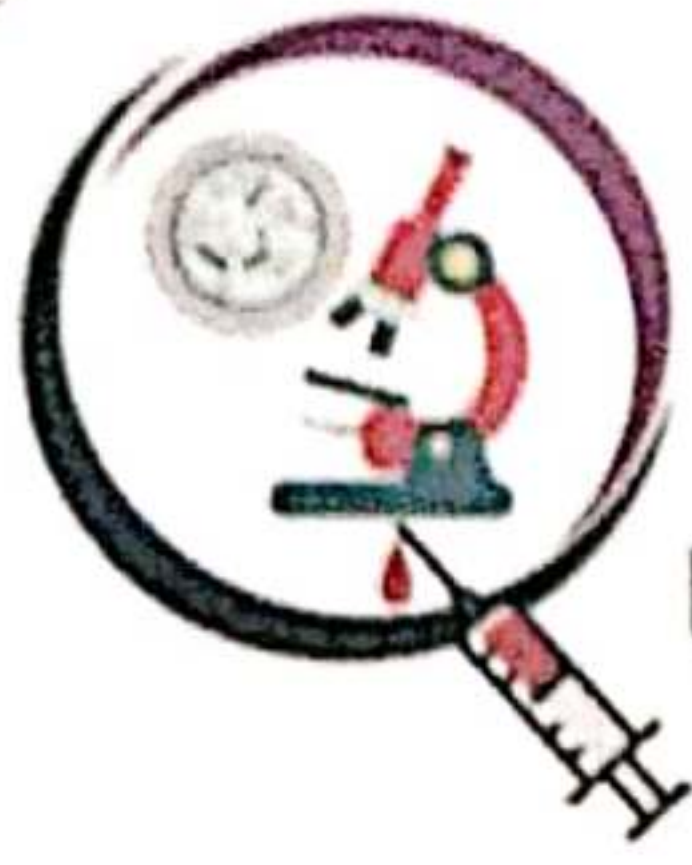KBW
Dr. Kailash B. Wagh
MD (Micro) DCP

THANKS FOR REFERRAL

Dr. Kailash B. Wagh
M.D. Microbiology D.C.P.
Reg. No. 2001/07/2704



98 Jilha Peth, Kantal Sabhagruh Road, Near Barde Medical, Jalgaon- 425001
0257-2970978, 2225322 9405887735



Manavata

Pathology & Microbiology Laboratory

Dr. Kailash B. Wagh

M.D. Microbiology D.C.P

Reg No. 2001/07/2704

REG NO. : 01-2024-OPD / 10
NAME : Mrs. JAYMALA V.BAVASKAR
REF BY : Dr. Sunil Suryavanshi (Insurance)
M.D.

AGE : 40 Years
SEX : Female
DATE : 27-Jan-2024

LOCATION :

BLOOD GROUP

TESTS

BLOOD GROUP

RESULTS : "O" Rh Positive
UNIT

NOTE

: Grouping and cross matching is compulsory before blood transfusion, as errors can occur due to irregular antibodies.

HBA1C

TESTS

HbA1C

RESULTS : 5.1
UNIT %

AVERAGE BLOOD SUGAR
(ABG)

: 100 mg/dl


Reference Range :

- Below 6.0% - Normal Value
- 6.0% - 7.0% - Good Control
- 7.0% - 8.0% - Fair Control
- 8.0% - 10% - Unsatisfactory Control
- Above 10% - Poor Control

Method : Fully Automated H.P.L.C. using Biorad Variant II Turbo, NGSP Certified.

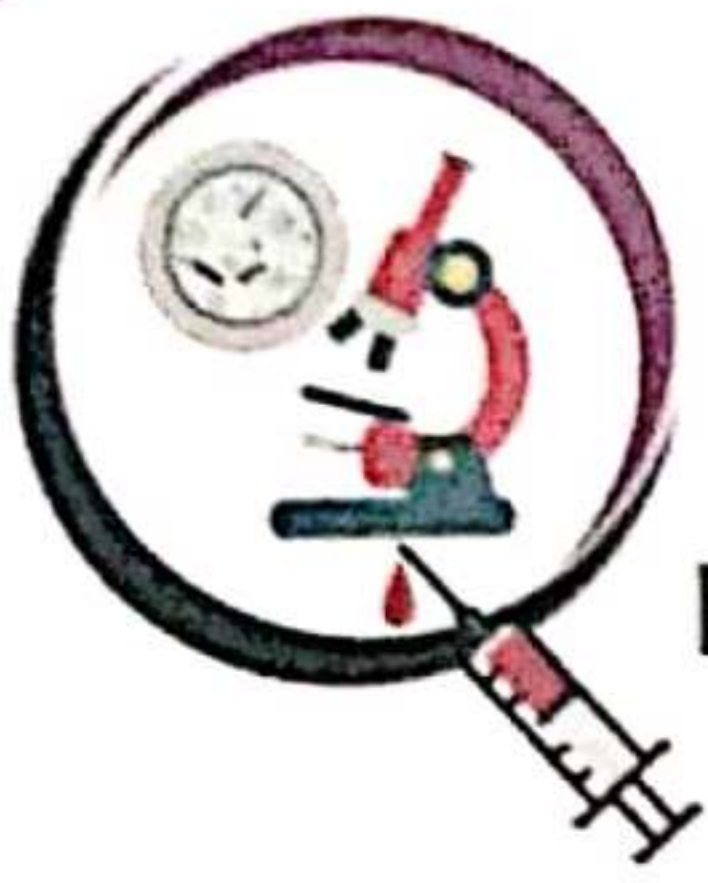Please correlate with clinical conditions.

THANKS FOR REFERRAL


Dr. Kailash B. Wagh
MD (Micro) DCP

Dr. Kailash B. Wagh
M.D. Microbiology D.C.P.
Reg No. 2001/07/2704





Manavata

Pathology & Microbiology Laboratory

Dr. Kailash B. Wagh

M.D. Microbiology D.C.P

Reg No. 2001/07/2704

REG NO. : 01-2024-OPD / 10
NAME : Mrs. JAYMALA V.BAVASKAR
REF BY : Dr . Sunil Suryavanshi (Insurance)
M.D.

AGE : 40 Years
SEX : Female
DATE : 27-Jan-2024


LOCATION :

BLOOD SUGAR FASTING & POST-PRANDIAL

| <u>TESTS</u> | <u>RESULTS</u> | <u>UNIT</u> | <u>REFERENCE RANGE</u> |
|---------------------|----------------|-------------|------------------------|
| BLOOD SUGAR FASTING | : 81 | mg/dl | 70 - 110 |
| URINE SUGAR FASTING | : Nil | | |
| BLOOD SUGAR PP | : 95 | mg/dl | 70 - 140 |
| URINE SUGAR PP | : Nil | | |

LIVER FUNCTION TEST

| <u>TESTS</u> | <u>RESULTS</u> | <u>UNIT</u> | <u>REFERENCE RANGE</u> |
|----------------------|----------------|-------------|------------------------|
| BILIRUBIN- TOTAL | : 0.94 | mg/dl | 0 - 1.0 |
| BILIRUBIN- DIRECT | : 0.23 | mg/dl | 0 - 0.3 |
| BILIRUBIN- INDIRECT | : 0.71 | mg/dl | 0.1 - 1.0 |
| SGPT | : 25 | IU/L | 0 - 40 |
| SGOT | : 31 | IU/L | 0 - 45 |
| ALKALINE PHOSPHATASE | : 286 | IU/L | 25 - 350 |
| TOTAL PROTIEN | : 6.89 | gm/dl | 6 - 8 |
| ALBUMIN | : 3.78 | gm/dl | 3.5 - 5 |
| GLOBULIN | : 3.11 | gm/dl | 2 - 3.5 |
| A/G Ratio | : 2 | | 2 - 2.5 |
| GGTP | : 16 | IU/L | 0 - 25 |


Dr. Kailash B. Wagh

Dr. MD (Micro) DCP

M.D. Microbiology D.C.P.

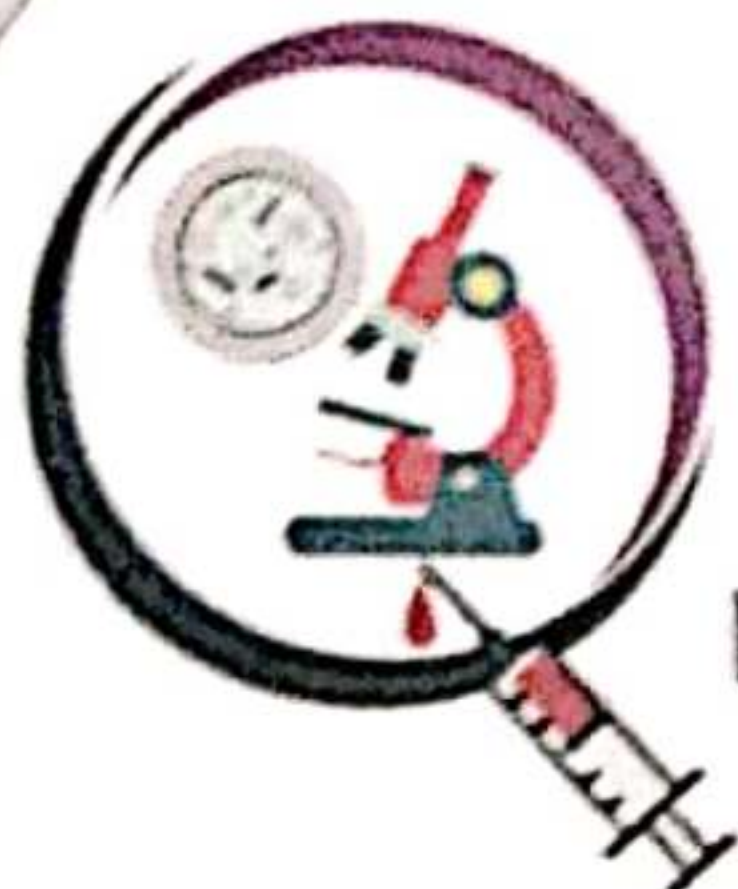Reg No. 2001/07/2704



THANKS FOR REFERRAL

98 Jilha Peth, Kantai Sabhagruh Road, Near Barde Medical, Jalgaon- 425001

0257-2970978, 2225322 9405887735



Manavata

Pathology & Microbiology Laboratory

Dr. Kailash B. Wagh

M.D. Microbiology D.C.P

Reg No. 2001/07/2704

REG NO. : 01-2024-OPD / 10
NAME : Mrs. JAYMALA V.BAVASKAR
REF BY : Dr . Sunil Suryavanshi (Insurance)
M.D.

AGE : 40 Years

SEX : Female

DATE : 27-Jan-2024

LOCATION :

THYROID TEST

| <u>TESTS</u> | <u>RESULTS</u> | <u>UNIT</u> | <u>REFERENCE RANGE</u> |
|--------------|----------------|-------------|------------------------|
| T3 | : 133 | ng/ml | 87 - 178 |
| T4 | : 9.86 | µg/dl | 6.06 - 12.23 |
| ULTRA TSH | : 2.58 | µIU/ml | 0.34 - 5.6 |

NOTE

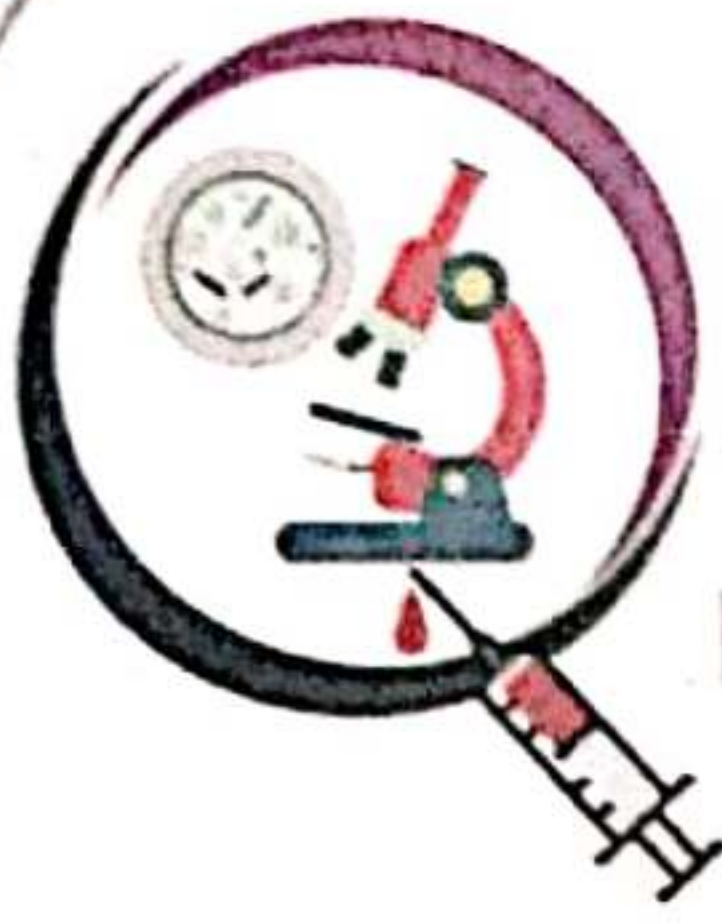: Test Done On Fully Automated Mindray CL 900i Hormone Assay BY CLIA

THANKS FOR REFERRAL

KBW
Dr. Kailash B. Wagh
MD (Micro) DCP

Dr. Kailash B. Wagh
M.D. Microbiology D.C.P
Reg. No. 2001/07/2704





Manavata

Pathology & Microbiology Laboratory

Dr. Kailash B. Wagh

M.D. Microbiology D.C.P

Reg No. 2001/07/2704


REG NO. : 01-2024-OPD / 10
NAME : Mrs. JAYMALA V.BAVASKAR
REF BY : Dr. Sunil Suryavanshi (Insurance)
M.D.

AGE : 40 Years
SEX : Female
DATE : 27-Jan-2024

LOCATION :

URINE ANALYSIS REPORT

| <u>TESTS</u> | <u>RESULTS</u> | <u>UNIT</u> | <u>REFERENCE RANGE</u> |
|--------------------------------|----------------|-------------|------------------------|
| PHYSICAL EXAMINATION | | | |
| QUANTITY | : 10 ml | | |
| COLOUR | : Pale Yellow | | |
| APPEARANCE | : Clear | | |
| DEPOSITS | : Absent | | |
| SPECIFIC GRAVITY | : 1.023 | | 1.002 - 1.030 |
| REACTION (PH) | : Acidic | | |
| CHEMICAL EXAMINATION | | | |
| PROTEINS | : Absent | | |
| SUGAR | : Absent | | |
| KETONE | : Absent | | |
| BILE SALTS/BILE PIGMENTS | : Absent | | |
| MICROSCOPIC EXAMINATION | | | |
| RBC | : Absent | /hpf | |
| PUS CELLS | : 2-3 | /hpf | |
| EPITHELIAL CELLS | : Occasional | /hpf | |
| CASTS | : Absent | | |
| CRYSTALS | : Absent | | |
| AMORPHOUS DEPOSITS | : Absent | | |


Dr. Kailash B. Wagh
MD (Micro) DCP

THANKS FOR REFERRAL

Dr. Kailash B. Wagh
M.D. Microbiology D.C.P.
Reg. No. 2001/07/2704



98 Jilha Peth, Kantai Sabhagruh Road, Near Barde Medical, Jalgaon- 425001

☎ 0257-2970978, 2225322 ☎ 9405887735