

CERTIFICATE OF MEDICAL FITNESS

This is to certify that I have conducted the clinical examination

of Mrs. Megha on 12/2/24

After reviewing the medical history and on clinical examination it has been found that he/she is

	Tick
<ul style="list-style-type: none"> • Medically Fit 	/
<ul style="list-style-type: none"> • Fit with restrictions/recommendations <p>Though following restrictions have been revealed, in my opinion, these are not impediments to the job.</p> <p>1.....<u>Serum Sodium &</u>.....</p> <p>2.....<u>U/E</u>.....</p> <p>3.....</p> <p>However the employee should follow the advice/medication that has been communicated to him/her.</p> <p>Review after _____</p>	
<ul style="list-style-type: none"> • Currently Unfit. <p>Review after _____ recommended</p>	
<ul style="list-style-type: none"> • Unfit 	

Dr. Lily Dube
Medical Officer
Apollo Clinic, Kharadi
Reg. No.: 402/04/0739

This certificate is not meant for medico-legal purposes

Date : 10-02-2024
MR NO : CWAN.0000062135

Department : GENERAL *megha manija*
Doctor : *medane*

Name : Mrs. MEGHA

Registration No :

Age/ Gender : 28 Y / Female

Qualification :

Consultation Timing: 08:59

nip 72

Height : <i>151</i>	Weight : <i>38.9</i>	BMI : <i>17</i>	Waist Circum : <i>68</i>
Temp : <i>98</i>	Pulse : <i>75</i>	Resp : <i>20</i>	B.P : <i>109/73</i>

General Examination / Allergies
History

Clinical Diagnosis & Management Plan

21/1/24

Present complains - *NiD*

Comorbidity - *NiD*

Allergies - *NiD*

Surgical H/O *NiD*

Family H/O *HTN (father)*

Addiction - *NiD*

OE

CVS-

CNS-

P/A-

Chest- *NAD*

H/O covid infection - *yes*

Vaccinated with - *both doses*

Follow up date:

[Signature]
Doctor Signature

Mrs. Megha Madane
28yrs/F;

10/02/2024

Height :	Weight :	BMI :	Waist Circum :
Temp :	Pulse :	Resp :	B.P :

General Examination / Allergies
History

Clinical Diagnosis & Management Plan

- pt-came for Routine ENT Health checkup.
- No h/o ↓ hearing loss,
 - O/E BIL EAC-clear, BIL TM-intact,
 - DNS to (R), BIL ITH (P),
 - Throat-WNL
- ↓
- Steam inhalation,



Follow up date:

Doctor Signature

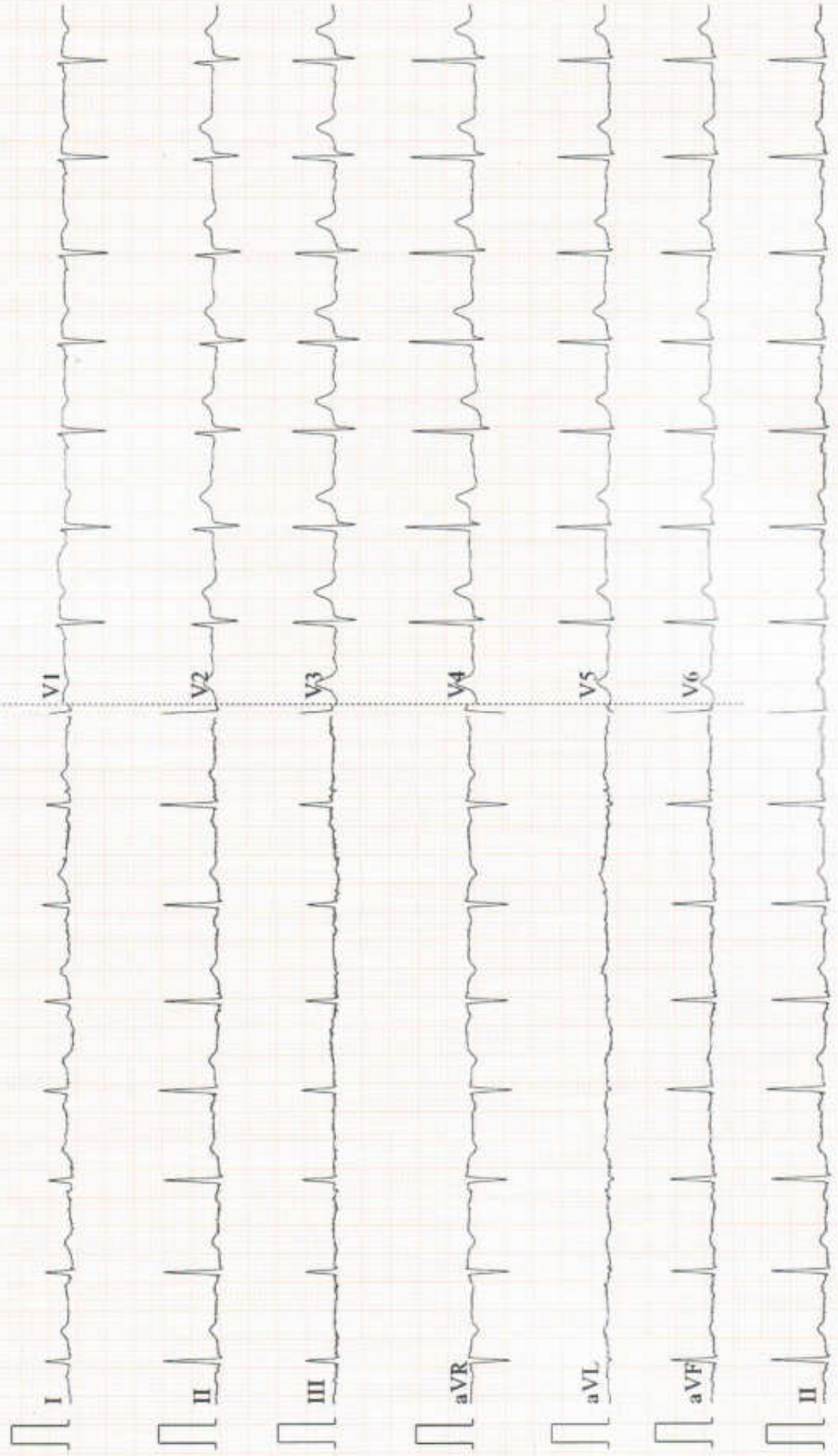
ID: 62135
megha madane
Female 28Years
kg / mmHg
Req. No. :

10-02-2024 14:38:34
HR : 90 bpm
P : 106 ms
PR : 132 ms
QRS : 80 ms
QT/QTcBz : 342/419 ms
PQRST : 16/62/15 °
RV5/SVI : 0.870/0.751 mV

Diagnosis Information:
Sinus rhythm
Inferior T wave abnormality may be age and gender related
: consider normal variant
Borderline ECG

Madane

Report Confirmed by:



POWER PRESCRIPTION

NAME: Ms Megha

GENDER: M/F

DATE: 10-2-24

AGE: 28

UHID: 62135

RIGHT EYE

LEFT EYE

	SPH	CYL	AXIS	VISION
DISTANCE	PL	.	.	6/6
NEAR				

	SPH	CYL	AXIS	VISION
DISTANCE	PL	.	.	6/6
NEAR				

INSTRUCTIONS:

SIGNATURE



Apollo Health and Lifestyle Limited

(CIN - UBS110TG2000PLC115819)

Regd. Office: 1-10-60/62, Ashoka Raghupathi Chambers, 5th Floor, Begumpet, Hyderabad, Telangana - 500 016.

Ph No: 040-4904 7777, Fax No: 4904 7744 | Email ID: enquiry@apollohl.com | www.apollohl.com

APOLLO CLINICS NETWORK MAHARASHTRA

Pune (Aundh) | Kharadi | Nigdi Pradhikaran | Viman Nagar | Wanowrie

Online appointments: www.apolloclinic.com

TO BOOK AN APPOINTMENT

 **1860 500 7788**

Patient Name	: Mrs. MEGHA	Age	: 28 Y F
UHID	: CWAN.0000062135	OP Visit No	: CKHAOPV109053
Reported on	: 10-02-2024 18:53	Printed on	: 10-02-2024 19:57
Adm/Consult Doctor	:	Ref Doctor	: SELF

DEPARTMENT OF RADIOLOGY

X-RAY CHEST PA


Both lung fields and hila are normal .
No obvious active pleuro-parenchymal lesion seen .
Both costophrenic and cardiophrenic angles are clear .
Both diaphragms are normal in position and contour .
Thoracic wall and soft tissues appear normal.

CONCLUSION :

No obvious abnormality seen

Printed on:10-02-2024 18:53

---End of the Report---




Dr. SANKET KASLIWAL
MBBS DMRE
Radiology

Patient Name : Mrs. MEGHA
UHID : CWAN.0000062135
Reported on : 10-02-2024 16:23
Adm/Consult Doctor :
Age : 28 Y F
OP Visit No : CKHAOPV109053
Printed on : 10-02-2024 19:57
Ref Doctor : SELF

(The sonography findings should always be considered in correlation with the clinical and other investigation finding where applicable.) It is only a professional opinion, Not valid for medico legal purpose.

Printed on: 10-02-2024 16:23

---End of the Report---



Dr. SANKET KASLIWAL
MBBS DMRE
Radiology

Name: Mrs. MEGHA

Age/ Sex: 28 Yrs / F

Date: 10/02/2024

2D ECHO/COLOUR DOPPLER

M - Mode values	Doppler Values		
AORTIC ROOT (mm)	19	PULMONARY VE(m/sec)	0.9
LEFT ATRIUM (mm)	23	PG (mmHg)	3.8
		AORTIC VEL (m/sec)	1.3
IVS - D (mm)	9	PG (mmHg)	7.2
LVID - D (mm)	38	MITRAL E WAVE(m/sec)	0.9
		A WAVE (m/sec)	0.6
LVPW - D (mm)	9		
EJECTION FRACTION (%)	60%		


REPORT:

Normal sized all cardiac chambers.
 No regional wall motion abnormality.
 Normal LV systolic function.
 Mitral valve Normal. No mitral regurgitation/ No Mitral stenosis.
 Aortic valve normal. No aortic regurgitation/No Aortic stenosis.
 Normal Tricuspid & pulmonary valve.
 No tricuspid regurgitation. No pulmonary hypertension.
 Intact IAS and IVS.
 No clots, vegetations, pericardial effusion noted.
 Aortic arch appears normal.

IMPRESSION:

Normal PA pressures.

Normal LV systolic function, No RWMA. LVEF 60%.



DR. VIKRANT KHESE
 MBBS, MD Medicine, DNB Medicine, DM Cardiology
 Consultant and interventional Cardiologist
 Reg No: MMC: 2015/02/0627

Apollo Health and Lifestyle Limited

ICIN - U85110TG2000PLC115819

Regd. Office: 1-10-60/62, Ashoka Raghupathi Chambers, 5th Floor, Begumpet, Hyderabad, Telangana - 500 016.

Ph. No: 040-4904 7777, Fax No: 4904 7744 | Email ID: enquiry@apollohi.com | www.apollohi.com

APOLLO CLINICS NETWORK MAHARASHTRA

Pune | Aundh | Kharadi | Nigdi Pradhikaran | Viman Nagar | Wanowrie

Online appointments: www.apolloclinic.com

TO BOOK AN APPOINTMENT

 **1860 500 7788**

भारत सरकार
Government of India

मेघा विकास मदाने
Megha Vikas Madane

जन्म तारीख / DOB: 13/05/1995

महिला / FEMALE

Mobile No.: 9763925723

8725 8477 5410

VID : 9161 4277 9430 7756

माझे आधार, माझी ओळख

S. No.	Company Name	PACKAGE NAME	Booking ID	EMP-NAME	AGE	GENDER
1	Arcofemi/Mediwheel/M ALE/FEMALE	Arcofemi Mediwheel Full Body Health Annual Plus Check - 2D ECHO	bobs7369	Megha	28 year	Female

Patient Name	: Mrs. MEGHA	Age/Gender	: 28 Y/F
UHID/MR No.	: CWAN.0000062135	OP Visit No	: CKHAOPV109053
Sample Collected on	:	Reported on	: 10-02-2024 18:53
LRN#	: RAD2231765	Specimen	:
Ref Doctor	: SELF		
Emp/Auth/TPA ID	: 68997		

DEPARTMENT OF RADIOLOGY

X-RAY CHEST PA

Both lung fields and hila are normal .

No obvious active pleuro-parenchymal lesion seen .

Both costophrenic and cardiophrenic angles are clear .

Both diaphragms are normal in position and contour .

Thoracic wall and soft tissues appear normal.

CONCLUSION :

No obvious abnormality seen



Dr. SANKET KASLIWAL
MBBS DMRE
Radiology

Patient Name	: Mrs. MEGHA	Age/Gender	: 28 Y/F
UHID/MR No.	: CWAN.0000062135	OP Visit No	: CKHAOPV109053
Sample Collected on	:	Reported on	: 10-02-2024 16:26
LRN#	: RAD2231765	Specimen	:
Ref Doctor	: SELF		
Emp/Auth/TPA ID	: 68997		

DEPARTMENT OF RADIOLOGY

ULTRASOUND - WHOLE ABDOMEN

Liver: It appears normal in size, shape and shows normal echotexture. No focal lesion is noted. No e/o IHBR dilatation is seen. Portal vein and CBD appear normal in dimensions at porta hepatis.

Gall bladder: collapsed..

Spleen : It appears normal in size, shape and echotexture. No focal lesion is noted.

Pancreas : It appears normal in size, shape and echotexture. No focal lesion / pancreatic ductal dilatation / calcification noted.

Right kidney : Normal in size ms 9.1 x 3.5 cms, shape, location with smooth outlines and normal echotexture. CM differentiation is well maintained. No calculus or hydronephrosis seen.

Left kidney : Normal in size ms 9.2 x 4.0 cms, shape, location with smooth outlines and normal echotexture. CM differentiation is well maintained. No calculus or hydronephrosis seen.

No retroperitoneal lymphadenopathy is seen. Aorta and I.V.C. appear normal.

Urinary bladder: It is partially distended and appears normal. No echoreflexive calculus or soft tissue mass noted. Both U-V junction appear normal.

Uterus: is anteverted, and measures 8.7 x 3.4 x 5.7 cms. No focal lesion seen. Endometrial thickness is 9.2 mm.

Right ovary : not visualised PA.

Left ovary : measures 2.5 x 1.7 cms.

Visualised bowel loops appear normal.

IMPRESSION :

- **NO SIGNIFICANT ABNORMALITY.**

Clinical correlation suggested.....

(The sonography findings should always be considered in correlation with the clinical and other investigation finding where applicable.) It is only a professional opinion, Not valid for medico legal purpose.



Dr. SANKET KASLIWAL
MBBS DMRE
Radiology

Certificate No: MC-5587

Patient Name : Mrs.MEGHA	Collected : 10/Feb/2024 09:17AM
Age/Gender : 28 Y 8 M 28 D/F	Received : 10/Feb/2024 12:52PM
UHID/MR No : CWAN.0000062135	Reported : 10/Feb/2024 02:26PM
Visit ID : CKHAOPV109053	Status : Final Report
Ref Doctor : Dr.SELF	Sponsor Name : ARCOFEMI HEALTHCARE LIMITED
Emp/Auth/TPA ID : 68997	

DEPARTMENT OF HAEMATOLOGY

ARCOFEMI MEDICALS FULL BODY HEALTH ANNUAL BLS CHECK FEMALE 35 FOLIO BANINDIA FY2024

PERIPHERAL SMEAR , WHOLE BLOOD EDTA

RBC's are Normocytic Normochromic
WBC's are normal in number and morphology
Platelets are Adequate
No Abnormal cells/hemoparasite seen.



DR.Sanjay Ingle
M.B.B.S,M.D(Pathology)
Consultant Pathologist



Certificate No: MC-5587

Patient Name : Mrs.MEGHA	Collected : 10/Feb/2024 09:17AM
Age/Gender : 28 Y 8 M 28 D/F	Received : 10/Feb/2024 12:52PM
UHID/MR No : CWAN.0000062135	Reported : 10/Feb/2024 02:26PM
Visit ID : CKHAOPV109053	Status : Final Report
Ref Doctor : Dr.SELF	Sponsor Name : ARCOFEMI HEALTHCARE LIMITED
Emp/Auth/TPA ID : 68997	

DEPARTMENT OF HAEMATOLOGY

ARCOFEMI - MEDIWHEEL - FULL BODY HEALTH ANNUAL PLUS CHECK - FEMALE - 2D ECHO - PAN INDIA - FY2324

Test Name	Result	Unit	Bio. Ref. Range	Method
HEMOGRAM , WHOLE BLOOD EDTA				
HAEMOGLOBIN	14.2	g/dL	12-15	Spectrophotometer
PCV	40.50	%	36-46	Electronic pulse & Calculation
RBC COUNT	4.28	Million/cu.mm	3.8-4.8	Electrical Impedance
MCV	94.6	fL	83-101	Calculated
MCH	33.2	pg	27-32	Calculated
MCHC	35.1	g/dL	31.5-34.5	Calculated
R.D.W	11.6	%	11.6-14	Calculated
TOTAL LEUCOCYTE COUNT (TLC)	4,080	cells/cu.mm	4000-10000	Electrical Impedance
DIFFERENTIAL LEUCOCYTIC COUNT (DLC)				
NEUTROPHILS	62.6	%	40-80	Electrical Impedance
LYMPHOCYTES	27.9	%	20-40	Electrical Impedance
EOSINOPHILS	1.2	%	1-6	Electrical Impedance
MONOCYTES	8.2	%	2-10	Electrical Impedance
BASOPHILS	0.1	%	<1-2	Electrical Impedance
ABSOLUTE LEUCOCYTE COUNT				
NEUTROPHILS	2554.08	Cells/cu.mm	2000-7000	Calculated
LYMPHOCYTES	1138.32	Cells/cu.mm	1000-3000	Calculated
EOSINOPHILS	48.96	Cells/cu.mm	20-500	Calculated
MONOCYTES	334.56	Cells/cu.mm	200-1000	Calculated
BASOPHILS	4.08	Cells/cu.mm	0-100	Calculated
PLATELET COUNT	188000	cells/cu.mm	150000-410000	Electrical impedance
ERYTHROCYTE SEDIMENTATION RATE (ESR)	4	mm at the end of 1 hour	0-20	Modified Westergren
PERIPHERAL SMEAR				

RBC's are Normocytic Normochromic
WBC's are normal in number and morphology
Platelets are Adequate
No Abnormal cells/hemoparasite seen.



DR.Sanjay Ingle
M.B.B.S,M.D(Pathology)
Consultant Pathologist



Certificate No: MC-5587

Patient Name : Mrs.MEGHA	Collected : 10/Feb/2024 09:17AM
Age/Gender : 28 Y 8 M 28 D/F	Received : 10/Feb/2024 12:52PM
UHID/MR No : CWAN.0000062135	Reported : 10/Feb/2024 04:56PM
Visit ID : CKHAOPV109053	Status : Final Report
Ref Doctor : Dr.SELF	Sponsor Name : ARCOFEMI HEALTHCARE LIMITED
Emp/Auth/TPA ID : 68997	

DEPARTMENT OF HAEMATOLOGY

ARCOFEMI - MEDIWHEEL - FULL BODY HEALTH ANNUAL PLUS CHECK - FEMALE - 2D ECHO - PAN INDIA - FY2324

Test Name	Result	Unit	Bio. Ref. Range	Method
BLOOD GROUP ABO AND RH FACTOR , WHOLE BLOOD EDTA				
BLOOD GROUP TYPE	A			Microplate Hemagglutination
Rh TYPE	Positive			Microplate Hemagglutination

Sneha Shah
Dr Sneha Shah
MBBS, MD (Pathology)
Consultant Pathologist



Certificate No: MC-5587

Patient Name : Mrs.MEGHA	Collected : 10/Feb/2024 09:17AM
Age/Gender : 28 Y 8 M 28 D/F	Received : 10/Feb/2024 12:58PM
UHID/MR No : CWAN.0000062135	Reported : 10/Feb/2024 01:53PM
Visit ID : CKHAOPV109053	Status : Final Report
Ref Doctor : Dr.SELF	Sponsor Name : ARCOFEMI HEALTHCARE LIMITED
Emp/Auth/TPA ID : 68997	

DEPARTMENT OF BIOCHEMISTRY

ARCOFEMI - MEDIWHEEL - FULL BODY HEALTH ANNUAL PLUS CHECK - FEMALE - 2D ECHO - PAN INDIA - FY2324

Test Name	Result	Unit	Bio. Ref. Range	Method
GLUCOSE, FASTING , NAF PLASMA	81	mg/dL	70-100	HEXOKINASE

Comment:

As per American Diabetes Guidelines, 2023

Fasting Glucose Values in mg/dL	Interpretation
70-100 mg/dL	Normal
100-125 mg/dL	Prediabetes
≥126 mg/dL	Diabetes
<70 mg/dL	Hypoglycemia

Note:

- The diagnosis of Diabetes requires a fasting plasma glucose of > or = 126 mg/dL and/or a random / 2 hr post glucose value of > or = 200 mg/dL on at least 2 occasions.
- Very high glucose levels (>450 mg/dL in adults) may result in Diabetic Ketoacidosis & is considered critical.



DR.Sanjay Ingle
M.B.B.S,M.D(Pathology)
Consultant Pathologist



Certificate No: MC-EEB7

Patient Name : Mrs.MEGHA	Collected : 10/Feb/2024 09:17AM
Age/Gender : 28 Y 8 M 28 D/F	Received : 10/Feb/2024 01:01PM
UHID/MR No : CWAN.0000062135	Reported : 10/Feb/2024 03:40PM
Visit ID : CKHAOPV109053	Status : Final Report
Ref Doctor : Dr.SELF	Sponsor Name : ARCOFEMI HEALTHCARE LIMITED
Emp/Auth/TPA ID : 68997	

DEPARTMENT OF BIOCHEMISTRY

ARCOFEMI - MEDIWHEEL - FULL BODY HEALTH ANNUAL PLUS CHECK - FEMALE - 2D ECHO - PAN INDIA - FY2324

Test Name	Result	Unit	Bio. Ref. Range	Method
GLUCOSE, POST PRANDIAL (PP), 2 HOURS , SODIUM FLUORIDE PLASMA (2 HR)	67	mg/dL	70-140	HEXOKINASE

Comment:

It is recommended that FBS and PPBS should be interpreted with respect to their Biological reference ranges and not with each other.

Conditions which may lead to lower postprandial glucose levels as compared to fasting glucose levels may be due to reactive hypoglycemia, dietary meal content, duration or timing of sampling after food digestion and absorption, medications such as insulin preparations, sulfonylureas, amylin analogues, or conditions such as overproduction of insulin.

Test Name	Result	Unit	Bio. Ref. Range	Method
HBA1C (GLYCATED HEMOGLOBIN) , WHOLE BLOOD EDTA				
HBA1C, GLYCATED HEMOGLOBIN	4.8	%		HPLC
ESTIMATED AVERAGE GLUCOSE (eAG)	91	mg/dL		Calculated

Comment:

Reference Range as per American Diabetes Association (ADA) 2023 Guidelines:

REFERENCE GROUP	HBA1C %
NON DIABETIC	<5.7
PREDIABETES	5.7 – 6.4
DIABETES	≥ 6.5
DIABETICS	
EXCELLENT CONTROL	6 – 7
FAIR TO GOOD CONTROL	7 – 8
UNSATISFACTORY CONTROL	8 – 10
POOR CONTROL	>10

Note: Dietary preparation or fasting is not required.

- HbA1C is recommended by American Diabetes Association for Diagnosing Diabetes and monitoring Glycemic Control by American Diabetes Association guidelines 2023.
- Trends in HbA1C values is a better indicator of Glycemic control than a single test.
- Low HbA1C in Non-Diabetic patients are associated with Anemia (Iron Deficiency/Hemolytic), Liver Disorders, Chronic Kidney Disease. Clinical Correlation is advised in interpretation of low Values.
- Falsely low HbA1c (below 4%) may be observed in patients with clinical conditions that shorten erythrocyte life span or decrease mean erythrocyte age. HbA1c may not accurately reflect glycemic control when clinical conditions that affect erythrocyte survival are present.
- In cases of Interference of Hemoglobin variants in HbA1C, alternative methods (Fructosamine) estimation is recommended for Glycemic Control

Sneha Shah

 Dr Sneha Shah
 MBBS, MD (Pathology)
 Consultant Pathologist



Certificate No: MC-5587

Patient Name : Mrs.MEGHA	Collected : 10/Feb/2024 09:17AM
Age/Gender : 28 Y 8 M 28 D/F	Received : 10/Feb/2024 01:01PM
UHID/MR No : CWAN.0000062135	Reported : 10/Feb/2024 03:40PM
Visit ID : CKHAOPV109053	Status : Final Report
Ref Doctor : Dr.SELF	Sponsor Name : ARCOFEMI HEALTHCARE LIMITED
Emp/Auth/TPA ID : 68997	

DEPARTMENT OF BIOCHEMISTRY

ARCOFEMI - MEDIWHEEL - FULL BODY HEALTH ANNUAL PLUS CHECK - FEMALE - 2D ECHO - PAN INDIA - FY2324

A: HbF >25%
 B: Homozygous Hemoglobinopathy.
 (Hb Electrophoresis is recommended method for detection of Hemoglobinopathy)



Sneha Shah
Dr Sneha Shah
 MBBS, MD (Pathology)
 Consultant Pathologist

Certificate No: MC-5587

Patient Name : Mrs.MEGHA	Collected : 10/Feb/2024 09:17AM
Age/Gender : 28 Y 8 M 28 D/F	Received : 10/Feb/2024 01:09PM
UHID/MR No : CWAN.0000062135	Reported : 10/Feb/2024 03:06PM
Visit ID : CKHAOPV109053	Status : Final Report
Ref Doctor : Dr.SELF	Sponsor Name : ARCOFEMI HEALTHCARE LIMITED
Emp/Auth/TPA ID : 68997	

DEPARTMENT OF BIOCHEMISTRY

ARCOFEMI - MEDIWHEEL - FULL BODY HEALTH ANNUAL PLUS CHECK - FEMALE - 2D ECHO - PAN INDIA - FY2324

Test Name	Result	Unit	Bio. Ref. Range	Method
LIPID PROFILE , SERUM				
TOTAL CHOLESTEROL	109	mg/dL	<200	CHO-POD
TRIGLYCERIDES	35	mg/dL	<150	GPO-POD
HDL CHOLESTEROL	54	mg/dL	40-60	Enzymatic Immunoinhibition
NON-HDL CHOLESTEROL	55	mg/dL	<130	Calculated
LDL CHOLESTEROL	48.21	mg/dL	<100	Calculated
VLDL CHOLESTEROL	6.91	mg/dL	<30	Calculated
CHOL / HDL RATIO	2.02		0-4.97	Calculated

Comment:

Reference Interval as per National Cholesterol Education Program (NCEP) Adult Treatment Panel III Report.

	Desirable	Borderline High	High	Very High
TOTAL CHOLESTEROL	< 200	200 - 239	≥ 240	
TRIGLYCERIDES	<150	150 - 199	200 - 499	≥ 500
LDL	Optimal < 100 Near Optimal 100-129	130 - 159	160 - 189	≥ 190
HDL	≥ 60			
NON-HDL CHOLESTEROL	Optimal <130; Above Optimal 130-159	160-189	190-219	>220

1. Measurements in the same patient on different days can show physiological and analytical variations.
2. NCEP ATP III identifies non-HDL cholesterol as a secondary target of therapy in persons with high triglycerides.
3. Primary prevention algorithm now includes absolute risk estimation and lower LDL Cholesterol target levels to determine eligibility of drug therapy.
4. Low HDL levels are associated with Coronary Heart Disease due to insufficient HDL being available to participate in reverse cholesterol transport, the process by which cholesterol is eliminated from peripheral tissues.
5. As per NCEP guidelines, all adults above the age of 20 years should be screened for lipid status. Selective screening of children above the age of 2 years with a family history of premature cardiovascular disease or those with at least one parent with high total cholesterol is recommended.
6. VLDL, LDL Cholesterol Non HDL Cholesterol, CHOL/HDL RATIO, LDL/HDL RATIO are calculated parameters when Triglycerides are below 350mg/dl. When Triglycerides are more than 350 mg/dl LDL cholesterol is a direct measurement.

Sneha Shah

 Dr Sneha Shah
 MBBS, MD (Pathology)
 Consultant Pathologist



Certificate No: MC-5587

Patient Name : Mrs.MEGHA	Collected : 10/Feb/2024 09:17AM
Age/Gender : 28 Y 8 M 28 D/F	Received : 10/Feb/2024 01:09PM
UHID/MR No : CWAN.0000062135	Reported : 10/Feb/2024 03:06PM
Visit ID : CKHAOPV109053	Status : Final Report
Ref Doctor : Dr.SELF	Sponsor Name : ARCOFEMI HEALTHCARE LIMITED
Emp/Auth/TPA ID : 68997	

DEPARTMENT OF BIOCHEMISTRY

ARCOFEMI - MEDIWHEEL - FULL BODY HEALTH ANNUAL PLUS CHECK - FEMALE - 2D ECHO - PAN INDIA - FY2324

Test Name	Result	Unit	Bio. Ref. Range	Method
LIVER FUNCTION TEST (LFT) , SERUM				
BILIRUBIN, TOTAL	0.65	mg/dL	0.3-1.2	DPD
BILIRUBIN CONJUGATED (DIRECT)	0.20	mg/dL	<0.2	DPD
BILIRUBIN (INDIRECT)	0.46	mg/dL	0.0-1.1	Dual Wavelength
ALANINE AMINOTRANSFERASE (ALT/SGPT)	13.5	U/L	<35	IFCC
ASPARTATE AMINOTRANSFERASE (AST/SGOT)	15.0	U/L	<35	IFCC
ALKALINE PHOSPHATASE	38.39	U/L	30-120	IFCC
PROTEIN, TOTAL	6.82	g/dL	6.6-8.3	Biuret
ALBUMIN	4.57	g/dL	3.5-5.2	BROMO CRESOL GREEN
GLOBULIN	2.25	g/dL	2.0-3.5	Calculated
A/G RATIO	2.03		0.9-2.0	Calculated

Comment:

LFT results reflect different aspects of the health of the liver, i.e., hepatocyte integrity (AST & ALT), synthesis and secretion of bile (Bilirubin, ALP), cholestasis (ALP, GGT), protein synthesis (Albumin)

Common patterns seen:

1. Hepatocellular Injury:

- AST – Elevated levels can be seen. However, it is not specific to liver and can be raised in cardiac and skeletal injuries.
- ALT – Elevated levels indicate hepatocellular damage. It is considered to be most specific lab test for hepatocellular injury. Values also correlate well with increasing BMI.
- Disproportionate increase in AST, ALT compared with ALP.
- Bilirubin may be elevated.
- AST: ALT (ratio) – In case of hepatocellular injury AST: ALT > 1 In Alcoholic Liver Disease AST: ALT usually >2. This ratio is also seen to be increased in NAFLD, Wilson's's diseases, Cirrhosis, but the increase is usually not >2.

2. Cholestatic Pattern:

- ALP – Disproportionate increase in ALP compared with AST, ALT.
- Bilirubin may be elevated.
- ALP elevation also seen in pregnancy, impacted by age and sex.
- To establish the hepatic origin correlation with GGT helps. If GGT elevated indicates hepatic cause of increased ALP.

3. Synthetic function impairment:

- Albumin- Liver disease reduces albumin levels.
- Correlation with PT (Prothrombin Time) helps.


Dr Sneha Shah
 MBBS, MD (Pathology)
 Consultant Pathologist



Certificate No: MC-5587

Patient Name : Mrs.MEGHA	Collected : 10/Feb/2024 09:17AM
Age/Gender : 28 Y 8 M 28 D/F	Received : 10/Feb/2024 01:09PM
UHID/MR No : CWAN.0000062135	Reported : 10/Feb/2024 03:07PM
Visit ID : CKHAOPV109053	Status : Final Report
Ref Doctor : Dr.SELF	Sponsor Name : ARCOFEMI HEALTHCARE LIMITED
Emp/Auth/TPA ID : 68997	

DEPARTMENT OF BIOCHEMISTRY

ARCOFEMI - MEDIWHEEL - FULL BODY HEALTH ANNUAL PLUS CHECK - FEMALE - 2D ECHO - PAN INDIA - FY2324

Test Name	Result	Unit	Bio. Ref. Range	Method
RENAL PROFILE/KIDNEY FUNCTION TEST (RFT/KFT) , SERUM				
CREATININE	0.47	mg/dL	0.55-1.02	Modified Jaffe, Kinetic
UREA	12.92	mg/dL	17-43	GLDH, Kinetic Assay
BLOOD UREA NITROGEN	6.0	mg/dL	8.0 - 23.0	Calculated
URIC ACID	3.03	mg/dL	2.6-6.0	Uricase PAP
CALCIUM	8.66	mg/dL	8.8-10.6	Arsenazo III
PHOSPHORUS, INORGANIC	3.01	mg/dL	2.5-4.5	Phosphomolybdate Complex
SODIUM	121.8	mmol/L	136-146	ISE (Indirect)
POTASSIUM	4.2	mmol/L	3.5-5.1	ISE (Indirect)
CHLORIDE	112.98	mmol/L	101-109	ISE (Indirect)



DR. Sanjay Ingle
M.B.B.S, M.D (Pathology)
Consultant Pathologist



Certificate No: MC-5587

Patient Name : Mrs.MEGHA	Collected : 10/Feb/2024 09:17AM
Age/Gender : 28 Y 8 M 28 D/F	Received : 10/Feb/2024 01:09PM
UHID/MR No : CWAN.0000062135	Reported : 10/Feb/2024 03:06PM
Visit ID : CKHAOPV109053	Status : Final Report
Ref Doctor : Dr.SELF	Sponsor Name : ARCOFEMI HEALTHCARE LIMITED
Emp/Auth/TPA ID : 68997	

DEPARTMENT OF BIOCHEMISTRY

ARCOFEMI - MEDIWHEEL - FULL BODY HEALTH ANNUAL PLUS CHECK - FEMALE - 2D ECHO - PAN INDIA - FY2324

Test Name	Result	Unit	Bio. Ref. Range	Method
GAMMA GLUTAMYL TRANSPEPTIDASE (GGT) , SERUM	9.93	U/L	<38	IFCC

Sneha Shah
Dr Sneha Shah
MBBS, MD (Pathology)
Consultant Pathologist



Certificate No: MC-5587

Patient Name : Mrs.MEGHA	Collected : 10/Feb/2024 09:17AM
Age/Gender : 28 Y 8 M 28 D/F	Received : 10/Feb/2024 01:02PM
UHID/MR No : CWAN.0000062135	Reported : 10/Feb/2024 01:51PM
Visit ID : CKHAOPV109053	Status : Final Report
Ref Doctor : Dr.SELF	Sponsor Name : ARCOFEMI HEALTHCARE LIMITED
Emp/Auth/TPA ID : 68997	

DEPARTMENT OF IMMUNOLOGY

ARCOFEMI - MEDIWHEEL - FULL BODY HEALTH ANNUAL PLUS CHECK - FEMALE - 2D ECHO - PAN INDIA - FY2324

Test Name	Result	Unit	Bio. Ref. Range	Method
THYROID PROFILE TOTAL (T3, T4, TSH) , SERUM				
TRI-IODOTHYRONINE (T3, TOTAL)	1.34	ng/mL	0.7-2.04	CLIA
THYROXINE (T4, TOTAL)	11.88	µg/dL	5.48-14.28	CLIA
THYROID STIMULATING HORMONE (TSH)	1.099	µIU/mL	0.34-5.60	CLIA

Comment:

For pregnant females	Bio Ref Range for TSH in uIU/ml (As per American Thyroid Association)
First trimester	0.1 - 2.5
Second trimester	0.2 – 3.0
Third trimester	0.3 – 3.0

- TSH is a glycoprotein hormone secreted by the anterior pituitary. TSH activates production of T3 (Triiodothyronine) and its prohormone T4 (Thyroxine). Increased blood level of T3 and T4 inhibit production of TSH.
- TSH is elevated in primary hypothyroidism and will be low in primary hyperthyroidism. Elevated or low TSH in the context of normal free thyroxine is often referred to as sub-clinical hypo- or hyperthyroidism respectively.
- Both T4 & T3 provides limited clinical information as both are highly bound to proteins in circulation and reflects mostly inactive hormone. Only a very small fraction of circulating hormone is free and biologically active.
- Significant variations in TSH can occur with circadian rhythm, hormonal status, stress, sleep deprivation, medication & circulating antibodies.

TSH	T3	T4	FT4	Conditions
High	Low	Low	Low	Primary Hypothyroidism, Post Thyroidectomy, Chronic Autoimmune Thyroiditis
High	N	N	N	Subclinical Hypothyroidism, Autoimmune Thyroiditis, Insufficient Hormone Replacement Therapy.
N/Low	Low	Low	Low	Secondary and Tertiary Hypothyroidism
Low	High	High	High	Primary Hyperthyroidism, Goitre, Thyroiditis, Drug effects, Early Pregnancy
Low	N	N	N	Subclinical Hyperthyroidism
Low	Low	Low	Low	Central Hypothyroidism, Treatment with Hyperthyroidism
Low	N	High	High	Thyroiditis, Interfering Antibodies
N/Low	High	N	N	T3 Thyrotoxicosis, Non thyroidal causes
High	High	High	High	Pituitary Adenoma; TSHoma/Thyrotropinoma

Sneha Shah
Dr Sneha Shah
 MBBS, MD (Pathology)
 Consultant Pathologist



Certificate No: MC-5587

Patient Name : Mrs.MEGHA	Collected : 10/Feb/2024 09:17AM
Age/Gender : 28 Y 8 M 28 D/F	Received : 10/Feb/2024 04:35PM
UHID/MR No : CWAN.0000062135	Reported : 10/Feb/2024 05:02PM
Visit ID : CKHAOPV109053	Status : Final Report
Ref Doctor : Dr.SELF	Sponsor Name : ARCOFEMI HEALTHCARE LIMITED
Emp/Auth/TPA ID : 68997	

DEPARTMENT OF CLINICAL PATHOLOGY

ARCOFEMI - MEDIWHEEL - FULL BODY HEALTH ANNUAL PLUS CHECK - FEMALE - 2D ECHO - PAN INDIA - FY2324

Test Name	Result	Unit	Bio. Ref. Range	Method
COMPLETE URINE EXAMINATION (CUE) , URINE				
PHYSICAL EXAMINATION				
COLOUR	PALE YELLOW		PALE YELLOW	Visual
TRANSPARENCY	HAZY		CLEAR	Visual
pH	<5.5		5-7.5	DOUBLE INDICATOR
SP. GRAVITY	>1.025		1.002-1.030	Bromothymol Blue
BIOCHEMICAL EXAMINATION				
URINE PROTEIN	NEGATIVE		NEGATIVE	PROTEIN ERROR OF INDICATOR
GLUCOSE	NEGATIVE		NEGATIVE	GLUCOSE OXIDASE
URINE BILIRUBIN	NEGATIVE		NEGATIVE	AZO COUPLING REACTION
URINE KETONES (RANDOM)	NEGATIVE		NEGATIVE	SODIUM NITRO PRUSSIDE
UROBILINOGEN	NORMAL		NORMAL	MODIFIED EHRlich REACTION
BLOOD	NEGATIVE		NEGATIVE	Peroxidase
NITRITE	NEGATIVE		NEGATIVE	Diazotization
LEUCOCYTE ESTERASE	POSITIVE ++		NEGATIVE	LEUCOCYTE ESTERASE
CENTRIFUGED SEDIMENT WET MOUNT AND MICROSCOPY				
PUS CELLS	18 - 20	/hpf	0-5	Microscopy
EPITHELIAL CELLS	7 - 8	/hpf	<10	MICROSCOPY
RBC	NIL	/hpf	0-2	MICROSCOPY
CASTS	NIL		0-2 Hyaline Cast	MICROSCOPY
CRYSTALS	ABSENT		ABSENT	MICROSCOPY

Sneha Shah
Dr Sneha Shah
MBBS, MD (Pathology)
Consultant Pathologist



Certificate No: MC-5587

Patient Name : Mrs.MEGHA	Collected : 10/Feb/2024 09:17AM
Age/Gender : 28 Y 8 M 28 D/F	Received : 10/Feb/2024 02:48PM
UHID/MR No : CWAN.0000062135	Reported : 10/Feb/2024 03:17PM
Visit ID : CKHAOPV109053	Status : Final Report
Ref Doctor : Dr.SELF	Sponsor Name : ARCOFEMI HEALTHCARE LIMITED
Emp/Auth/TPA ID : 68997	

DEPARTMENT OF CLINICAL PATHOLOGY

ARCOFEMI - MEDIWHEEL - FULL BODY HEALTH ANNUAL PLUS CHECK - FEMALE - 2D ECHO - PAN INDIA - FY2324

Test Name	Result	Unit	Bio. Ref. Range	Method
URINE GLUCOSE(POST PRANDIAL)	NEGATIVE		NEGATIVE	Dipstick

Test Name	Result	Unit	Bio. Ref. Range	Method
URINE GLUCOSE(FASTING)	NEGATIVE		NEGATIVE	Dipstick

Sneha Shah
Dr Sneha Shah
MBBS, MD (Pathology)
Consultant Pathologist



Patient Name : Mrs.MEGHA	Collected : 10/Feb/2024 01:58PM
Age/Gender : 28 Y 8 M 28 D/F	Received : 11/Feb/2024 02:15PM
UHID/MR No : CWAN.0000062135	Reported : 12/Feb/2024 03:51PM
Visit ID : CKHAOPV109053	Status : Final Report
Ref Doctor : Dr.SELF	Sponsor Name : ARCOFEMI HEALTHCARE LIMITED
Emp/Auth/TPA ID : 68997	

DEPARTMENT OF CYTOLOGY


ARCOFEMI MEDICALS FULL BODY HEALTH ANNUAL PHYSICIAN CHECK FEMALE 35 FOLIO BANINDIA EV0004

LBC PAP TEST (PAPSURE) , CERVICAL BRUSH SAMPLE

	CYTOLOGY NO.	2751/24
I	SPECIMEN	
a	SPECIMEN ADEQUACY	ADEQUATE
b	SPECIMEN TYPE	LIQUID-BASED PREPARATION (LBC)
	SPECIMEN NATURE/SOURCE	CERVICAL SMEAR
c	ENDOCERVICAL-TRANSFORMATION ZONE	PRESENT WITH ENDOCERVICAL CELLS
d	COMMENTS	SATISFACTORY FOR EVALUATION
II	MICROSCOPY	Superficial and intermediate squamous epithelial cells with benign morphology. Negative for intraepithelial lesion/ malignancy
III	RESULT	
a	EPITHELIAL CELL	
	SQUAMOUS CELL ABNORMALITIES	NOT SEEN
	GLANDULAR CELL ABNORMALITIES	NOT SEEN
b	ORGANISM	NIL
IV	INTERPRETATION	NEGATIVE FOR INTRAEPITHELIAL LESION OR MALIGNANCY

Pap Test is a screening test for cervical cancer with inherent false negative results. Regular screening and follow-up is recommended (Bethesda-TBS-2014) revised

*** End Of Report ***



DR. K. RAMA KRISHNA REDDY
M.B.B.S., M.D
CONSULTANT PATHOLOGIST

Page 14 of 14
CAP
ACCREDITED
COLLEGE of AMERICAN PATHOLOGISTS



APOLLO CLINICS NETWORK (CIN - UB5110TG2000PLC115810)
SIN No: CS074240
Regd. Office: 5th Floor, Begumpet, Hyderabad, Telangana - 500 016 |

Apollo Clinic (Kharadi)
Sr.No 23,31/1st Part, 1st Floor, OFFICE No. 102,
D Wing, Shops & Offices, RIL SCAPES, Opp. Reliance Mall,
Hyderabad - 500 033

1860 500 7788
www.apolloclinic.com

Telangana: Hyderabad (AS Rao Nagar | Charada Nagar | Kondapur | Nallakunta | Nizampet | Manikonda | Uppal) Andhra Pradesh: Vizag (Seethamma Peta) Karnataka: Bangalore (Banavara Nagar | Bellandur | Electronics City | Frasier Town | HSR Layout | Indira Nagar | JP Nagar | Kundalahalli | Koramangala | Sarjapur Road) Mysore (VV Mohalla) Tamil Nadu: Chennai (Anna Nagar | Kotturpuram | Mogappair | T Nagar | Valasaravakkam | Velachery) Maharashtra: Pune (Aundh) Haryana: Gurgaon (Vasant Vihar) Uttar Pradesh: Ghaziabad (Indrapuram) Gujarat: Ahmedabad (Satellite) Punjab: Amritsar (Court Road) Madhya Pradesh: Indore (Railway Station Road)