

**DAKSH HOSPITAL**

396 - 397, Gandhi Nagar, Scheme No. 8, ALWAR -301001

Ref. No.

Date.....

MEDICAL EXAMINATION REPORT

Name: Mr. Dinesh Kumar Meena

Age: 39yrs

Sex: Male

Date: 24/08/2024

General Physical Examination

Height : 180 cm  
Pulse : 90/mt  
Respiration : 18/mt

Weight : 51 kg  
BP : 100/60 mm/hg  
BMI : 15.7 kg/m<sup>2</sup>

H

Systemic Exam:- NORMALDental Check up:- NORMALEye check-up:- NORMALSkin Check up:- NORMALENT Check up:- NORMALImpression:-BN 649  
→Recommendation:-MR  
Protein  
→

MR

Dr. Mukesh Kumar Gupta  
MD Gen. Medicine  
Reg. No 5423/16262

डॉ० मुकेश गुप्ता

M.D.F.C.C.S.

किजिशिवन एवं मधुमेह रोग विशेषज्ञ

दक्ष हॉस्पिटल, अलवर

रजि० नं०-5423/16262

## Results

Run Date 24/08/2024 11:18:33 AM

Operator DAKSH

Last Name

Sample ID 15

First Name MR DINESH KUMAR

Department

Gender Male Age

Physician DR. MUKESH GUPTA M.D

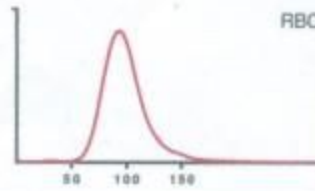
Patient ID AUTO\_PID23810

Type Man

Date of birth

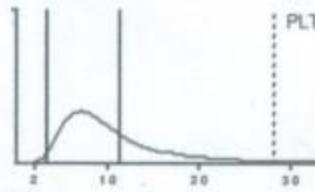
Sample comments

			Range
RBC	4.08	10 <sup>6</sup> /μL	3.80 - 5.50
HGB	13.8	g/dL	13.0 - 17.0
HCT	40.1	%	39.0 - 52.0
MCV	98.2	μm <sup>3</sup>	76.0 - 100.0
MCH	33.9	pg	26.0 - 34.0
MCHC	34.5	g/dL	32.0 - 35.0
RDW-CV	17.7	%	11.0 - 16.0
RDW-SD	67.7	μm <sup>3</sup>	37.0 - 49.0

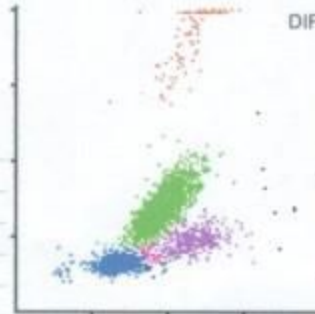


Susp. Pathologies  
Anisocytosis

			Range
PLT	172	10 <sup>3</sup> /μL	150 - 450
PCT	0.17	%	0.15 - 0.40
MPV	10.0	μm <sup>3</sup>	8.0 - 11.0
PDW	14.2	μm <sup>3</sup>	11.0 - 22.0
P-LCC	51	10 <sup>3</sup> /μL	44 - 140
P-LCR	30.0	%	18.0 - 50.0



			Range
WBC	5.51	10 <sup>3</sup> /μL	3.50 - 10.00
	#	Range	%
NEU	3.22	1.60 - 7.00	58.9
LYM	1.84	1.00 - 3.00	33.4
MON	0.19	0.20 - 0.80	3.4
EOS	0.15	0.00 - 0.50	2.7
BAS	0.09	0.00 - 0.15	1.6 h
LIC	0.02	0.00 - 0.10	0.3



*Dr. R.S. Gupta*  
**Dr. R.S. GUPTA**  
 MD (Pathology) (MAHE)  
 RMC No. 7924/19778

# दक्ष हॉस्पिटल

396-397, गाँधी नगर स्कीम नं.8, अलवर

☎0144 - 2703340, 8824692704

E-mail : drmukeshgupta@yahoo.co.in

Date :-24/08/2024

Name :- MR. DINESH KUMAR MEENA

Age & Sex : 39 Yrs' male

Refd. :- Dr Mukesh Gupta M.D.

	TEST NAME	RESULT	REFERENCE RANGE	
	ESR	30	00 -20 mm/hrs	
	Blood Group & Rh Factor	O * POSITIVE		
	HbA1C	5.0	4 - 5.6%	
	Blood Sugar (F)	-	< 140 mg/dl	
	Blood Sugar (R)	118.3	140 mg/dl	
	Urine Sugar (F)	NIL	-	
	Urine Sugar (PP)	NIL	-	
LIVER	S.Bilirubin Total	1.0	0.30 - 1.20 mg/dl	
	S.Bilirubin Direct	0.3	0.10 - 0.30 mg/dl	
	S.Bilirubin Indirect	0.7	0.30 - 0.90 mg/dl	
	S.G.O.T.	15	> 37 u/l	
	S.G.P.T.	29	> 40 u/l	
	S.Aik. Phosp.	210	80 - 306 u/l	
	Total Protein	6.8	6.5 - 8.5 gm/dl	
	Albumin	3.6	3.8 - 5.4 gm/dl	
	Globulin	3.2	2.3 - 3.5 gm/dl	
	A/G Ratio	1.1	-	
	AST/ALT Ratio	0.5	-	
KIDNEY	Blood Urea	30.2	15 -45 mg/dl	
	S.Creatinine	1.3	0.60 - 1.30 mg/dl	
	BUN	18	6 -24 mg/dl	
	S.Uric Acid	5.8	M 3.1 - 7.0, F 2.5 - 5.6 mg/dl	
	NA+	136.7	135 - 155 meq/L.	
	K+	3.5	3.60 - 5.50 meq/L.	
	CL-	100.5	98 - 107 meq/L.	
	BUN/Creatinine Ratio	13.8	-	
LIPID PROFILE	Total Cholesterol	130.0	Up to 200 mg/dl	
	S.HDL	41.0	30 - 70 mg/dl	
	S.LDL	61.0	Up to 170 mg/dl	
	S.VLDL	28.0	5.0 - 40 mg/dl	
	S. Triglycerides	140.0	Up to 170 mg/dl	
	LDL/HDL Ratio	1.4	-	
	Total Cholesterol/ HDL Ratio	3.1	-	
THYROID	T3	102.4	40 - 181 ng/dl	
	T4	8.0	4.6 - 10.5 µg/dl	
	TSH	6.49	0.30 - 5.0 mlu/l	
<b>URINE EXAMINATION</b>			<i>Microscopic Examination:</i>	
General/Chemical Examination:			RBC	Absent
	Colour	Paie Yellow	WBC	2-3
	Reaction	Acidic	Epithelial Cells	1-2
	Specific Gravity	QNS	Cast	Absent
	Appearance	Clear	Crystal	Absent
	Albumin	TRACE	Spermatozoa	Absent
	Sugar	Nil	Amorphous Sediments	Absent
			Other	Absent

*Dr. R.S. Gupta*  
**Dr. R.S. GUPTA**  
 MD (Pathology) (MAHE)  
 RMC No. 7924/19778

Doctor

**TECHNOLOGIST**

All investigation have their own limitations regarding the sensitivity & specificity of individual assay procedures, Isolated laboratory investigations never confirm the final diagnosis of the disease. They only help in arriving at a diagnosis in conjunction with clinical presentation and other related investigations. Report is not valid for medico-legal purpose subject to ALWAR jurisdiction only.



## X-RAY REPORT

Name : Mr. Dinesh Kumar Meena  
Date of X-Ray : 24/08/2024  
Part of X-Ray : Digital X-Ray Chest

Increase trans lucency lung, prominent inter costal space & tubular heart.  
Rest is normal.

Note :- Kindly correlate clinically

  
डॉ० मुखेश गुप्ता  
M. D. F. C. C. S.  
फिजिशियन एवं प्रमुख रोग विशेषज्ञ  
दक्ष हॉस्पिटल, अलवर  
फोन नं०-5423/16262

Doctor

TECHNOLOGIST

All investigation have their own limitations regarding the sensitivity & specificity of individual assay procedures, isolated laboratory investigations never confirm the final diagnosis of the disease. They only help in arriving at a diagnosis in conjunction with clinical presentation and other related investigations. Report is not valid for medico-legal purpose subject to ALWAR jurisdiction only.



# दक्ष हॉस्पिटल

396, गाँधी नगर स्कीम नं.8, अलवर (राज०) ☎ 0144-2703340

## Sonography / 2D Echo Cardiography / Doppler Report

### 2D/ ECHO REPORT

Name: - Mr DINESH KUMAR

Age: - 39 Yrs

Date: - 24-Aug-24

Reg. No.: - Alw/2009/04  
MEDIWHEEL health checkup

#### PROCEDURES:

M-MODE/2D/DOPPLER/COLOR/CONTRASTB.A.S. M<sup>2</sup>

MEASUREMENT:			DOPPLER:			
AOD	23	NORMAL (20- 37mm)	MV	0.7	NORMAL (cm/sec.)	
LA	21	(19- 40mm)	AV	1.3	(0.8- 1.3)	MR No
AVO	15	(12- 25mm)	TV	0.6	(1.2- 1.8)	AR No
RVDd.	12.9	(03- 09mm)	PV	0.8	(0.3- 0.8)	TR No
LVDd	51	(37- 56mm)	MITRAL VALVE-			
LVDs	31	(22- 40mm)	AML Normal			
IVS d	8	(06- 12mm)	PML Normal			
IVS s	14		AORTIC VALVE Normal			
PWd	7	(05- 10mm)	TV & PV are normal.			
LV FUNCTION						
M- E- S Separation		<0.9cm				
Minor		24.42%				
LV Ejection Fraction	69%	65 +/- 12%				

POOR ECHO WINDOW  
MITRAL E>A  
LV WALL MOTION: NO RWMA  
ALL CARDIAC CHAMBERS ARE NORMAL  
ALL VALVES ARE NORMAL  
NO CLOT, VEGETATION, PERICARDIAL EFFUSION

Adv: - Follow up/ review at higher center for confirmation

Note: - Please Correlate clinically. Due to technical limitations as well as inaccuracies inherent in the laboratory and statistical analysis of biological process. Diagnostic accuracy of ECHO is up to 95% only.  
Report is not valid for medico-legal purpose.

**Dr. Mukesh Kumar Gupta**  
Physician & Sonologist  
RM 5423/16262



"भ्रूण लिंग परीक्षण की शिकायत  
104 टोल फ्री सेवा पर भी की  
जा सकती है"

भ्रूण लिंग परीक्षण की शिकायत 104 टोल फ्री सेवा पर भी की जा सकती है।



# दक्ष हॉस्पिटल

396, गाँधी नगर स्कीम नं.8, अलवर (राज०) ☎ 0144-2703340

## Sonography / 2D Echo Cardiography / Doppler Report

Name: MR. DINESH KUMAR /M/39 YRS

Date: 24-Aug-24

MEDIWHEEL HEALTH CHECK UP

### U.S.G. OF ABDOMEN & PELVIS

#### LIVER

Liver is normal in size shape with normal echo-texture. Intra hepatic biliary radicals are not dilated. No evidence of focal or diffuse lesion.

#### GALL BLADDER

Gall bladder is normal dilated. Lumen clear. Wall thickness normal. CBD normal

#### PANCREAS

Pancreas is normal in size, shape & echo-texture.

#### SPLEEN

Normal in size with normal shape & echo- texture.

#### BOTH KIDNEY

Both kidney normal shape, size & echo texture. CMD maintained

PROSTATE is normal shape, size & echo texture..

URINARY BLADDER is well distended, visualized lumen appear clear.

### Advice- X Ray KUB / URINE EXAM

Please correlate clinically. USG accuracy is 95 % due to technical limitations as well as inaccuracies inherent in the laboratory and statistical analysis biological process.

This report is not valid for medico-legal cases.

**Dr. Mukesh Kumar Gupta**  
DR. MUKESH GUPTA  
Sonologist  
RM 6423/16262



"भ्रूण लिंग परीक्षण की शिकायत

104 टोल फ्री सेवा पर भी की

सकती है"

भ्रूण लिंग परीक्षण की शिकायत 104 टोल फ्री सेवा पर भी की जा सकती है।



24-08-2023 11:23:13

CARDIART

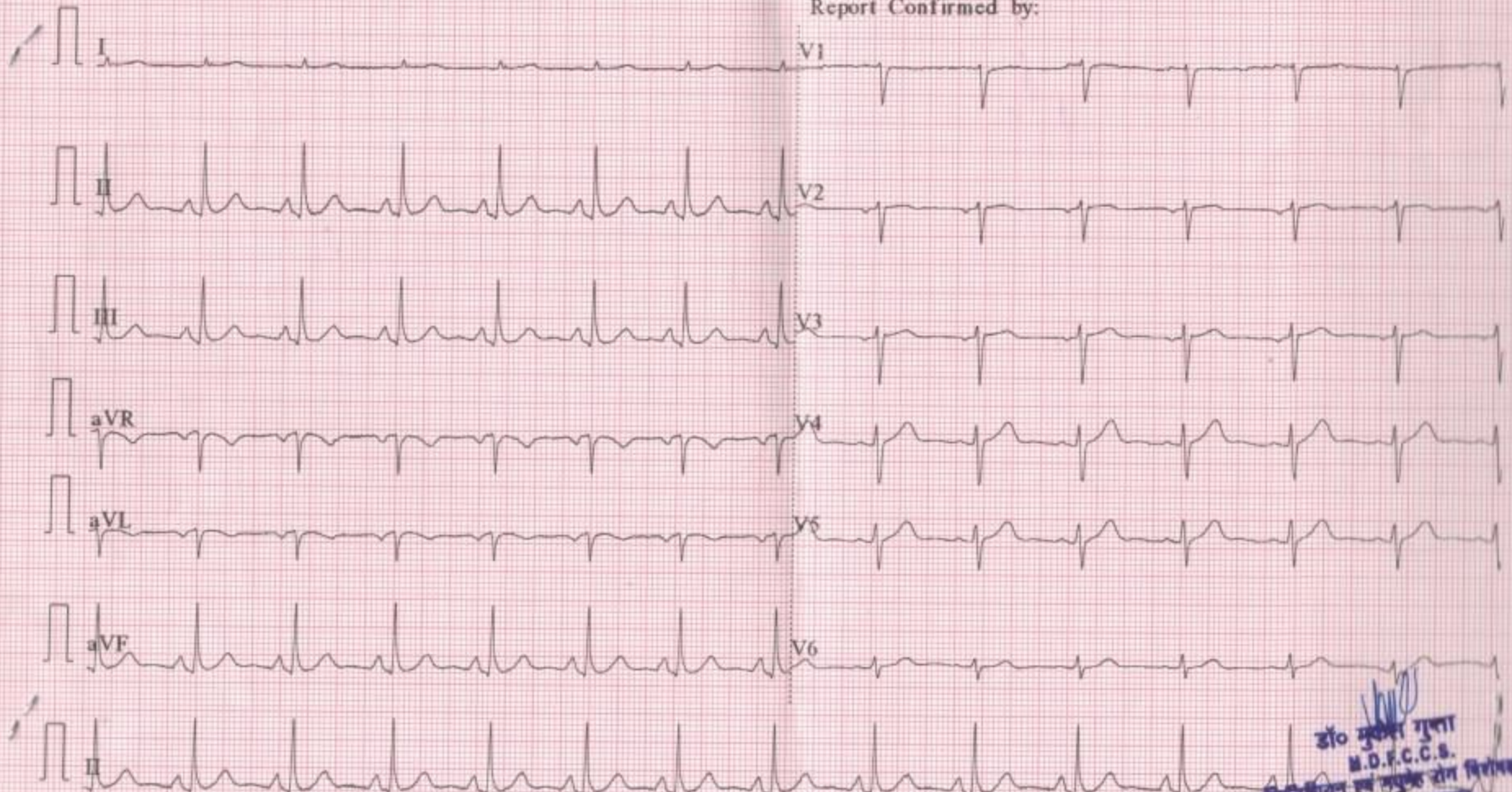
ID:

Female      Years

HR	:	84	bpm
P	:	89	ms
PR	:	127	ms
QRS	:	81	ms
QT/QTc	:	352/418	ms
P/QRS/T	:	84/82/76	°
RV5/SV1	:	0.347/0.677	mV

Diagnosis Information:  
 Sinus Rhythm  
 \*\*\*Normal ECG\*\*\*

Report Confirmed by:



डॉ० मुकुल गुप्ता  
 M.D.F.C.C.S.  
 कर्जिसीवन एवं तनुके सोन विशेषज्ञ  
 एवं कर्जिसीवन, अजमेर



AT01038207 MR DINESH KUMAR REFD BY DR MUKESH GUPTA MD CHEST 24.08.2024

R

