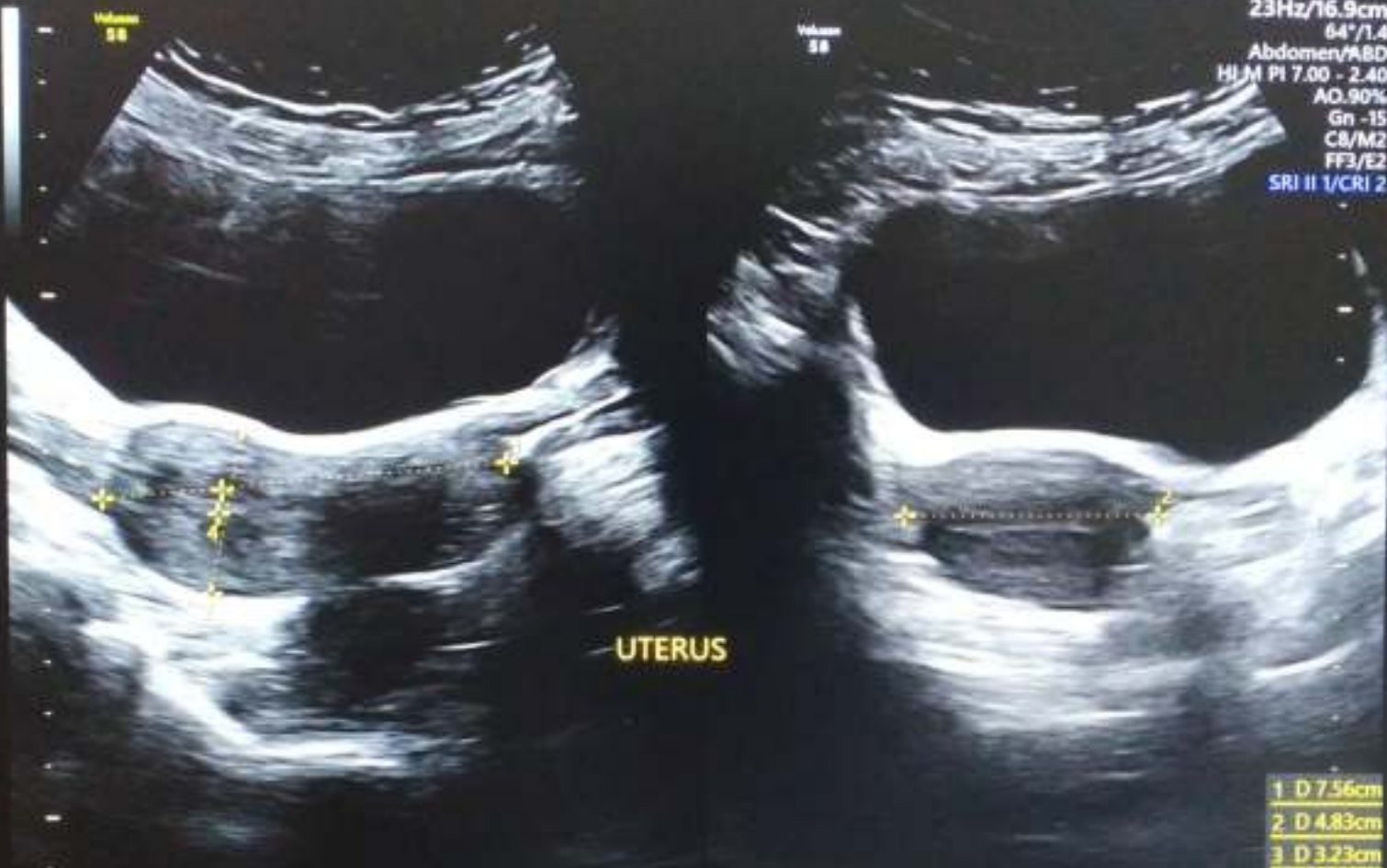



ANIMA GOND 42, *
VS8802280-24-01-13-13

ASHWINI LABORATORY

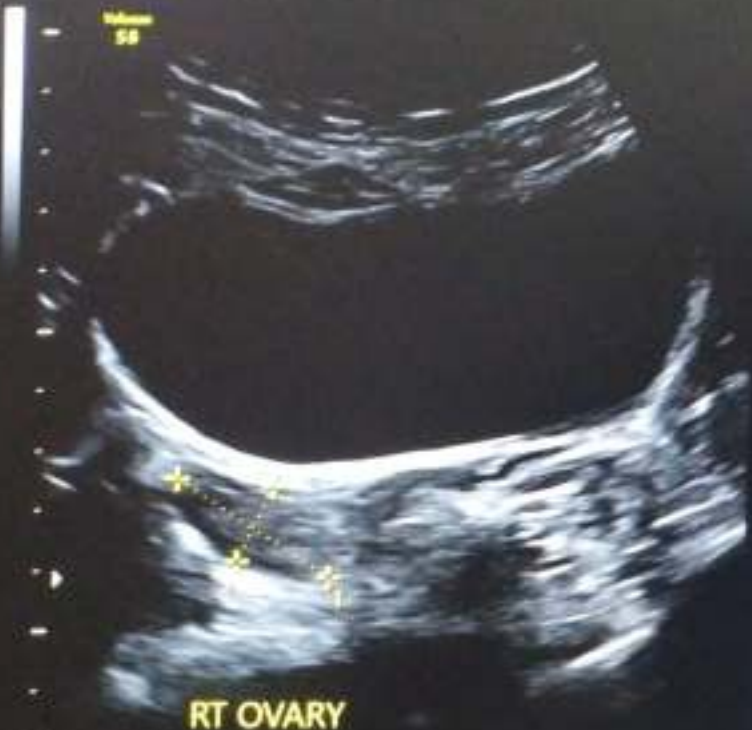TIs <0.1
Tlb <0.1
MI 0.7
13.01.2024
1:44:10 PM
C1-5-RS
23Hz/16.9cm
64°/1.4
Abdomen/ABD
HM PI 7.00 - 2.40
AD:90%
Gn -15
C8/M2
FF3/E2
SRI II 1/CRI 2



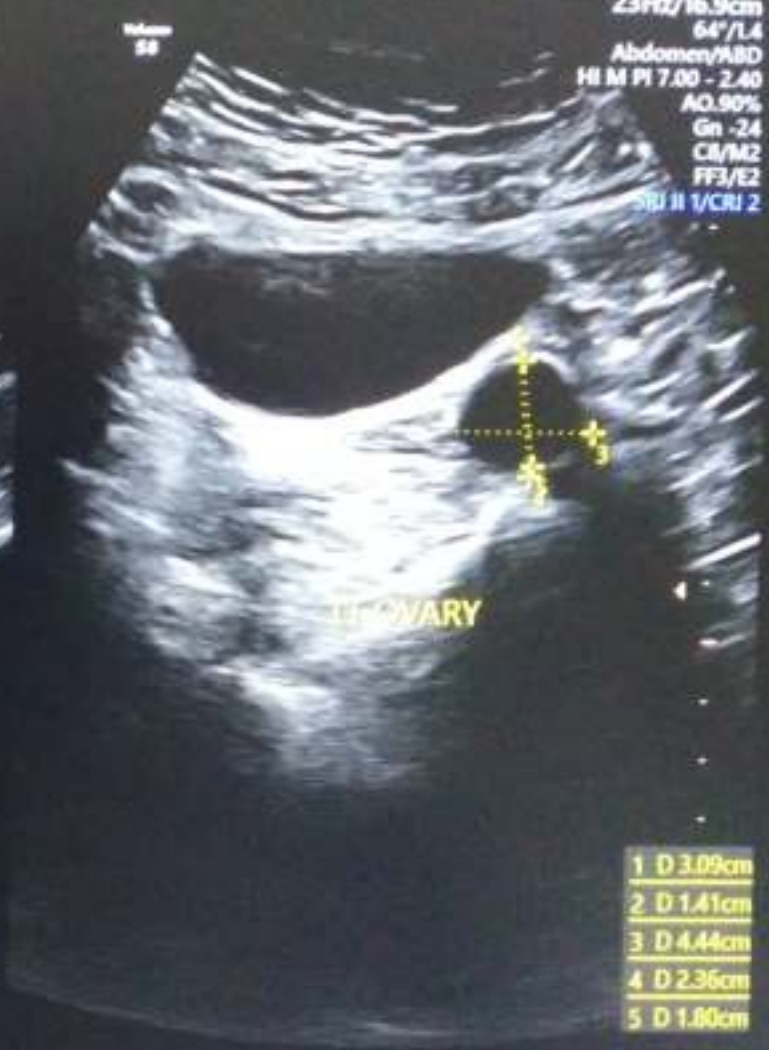UTERUS

- 1 D 7.56cm
- 2 D 4.83cm
- 3 D 3.23cm
- 4 D 0.47cm





RT OVARY



LT OVARY

- 1 D 3.09cm
- 2 D 1.41cm
- 3 D 4.44cm
- 4 D 2.36cm
- 5 D 1.80cm



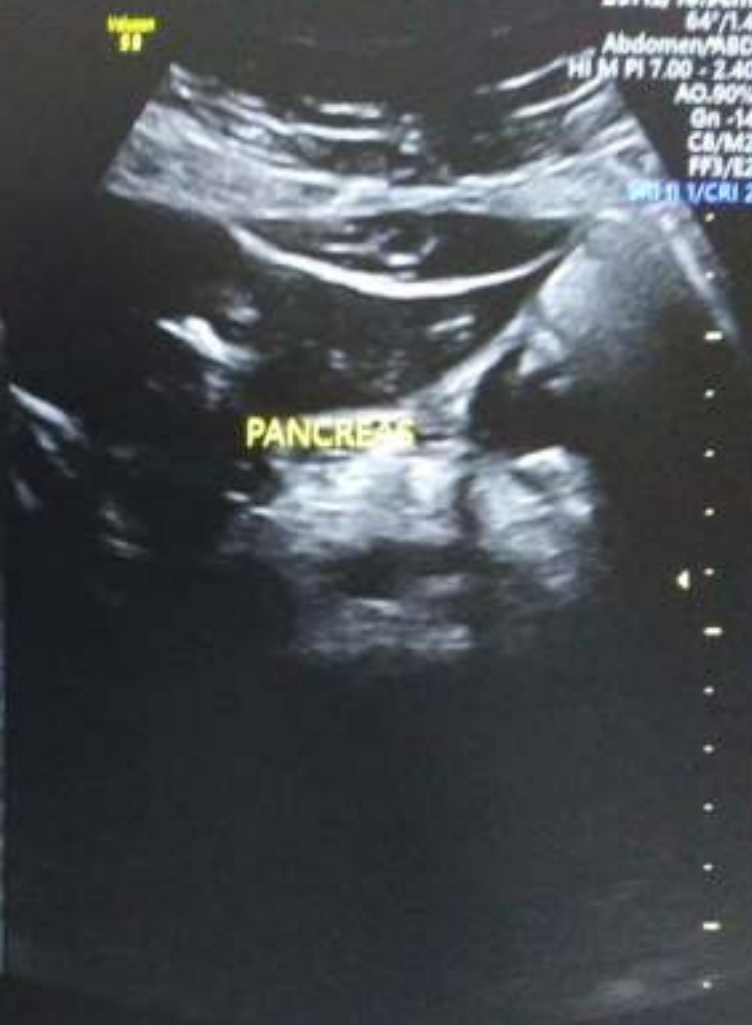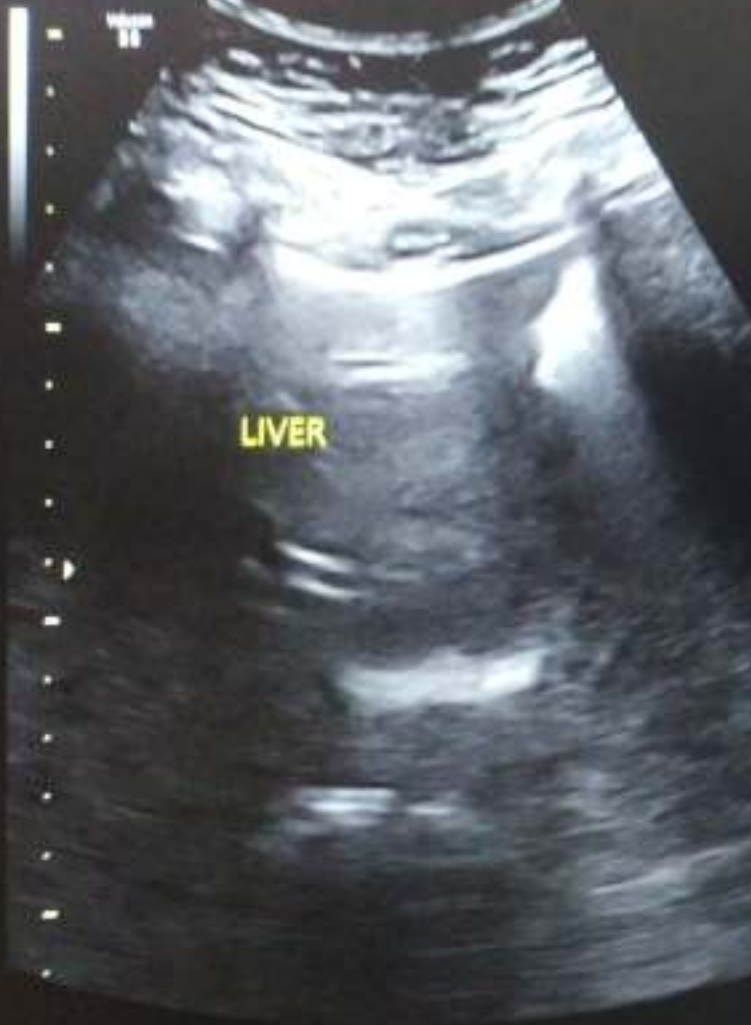ANIMA GOND 42,
V58802280-24-01-13-13

ASHWINI LABORATORY

Tis <0.1
Tib <0.1
MI 0.7

13.01.2024
1:47:45 PM
C1-5-R5
23Hz/16.8cm

64°/1.4
Abdomen/ABD
Hi M PI 7.00 - 2.40
AO.90%
On -14
C8/M2
FF3/E2
SRI II V/CRI 2

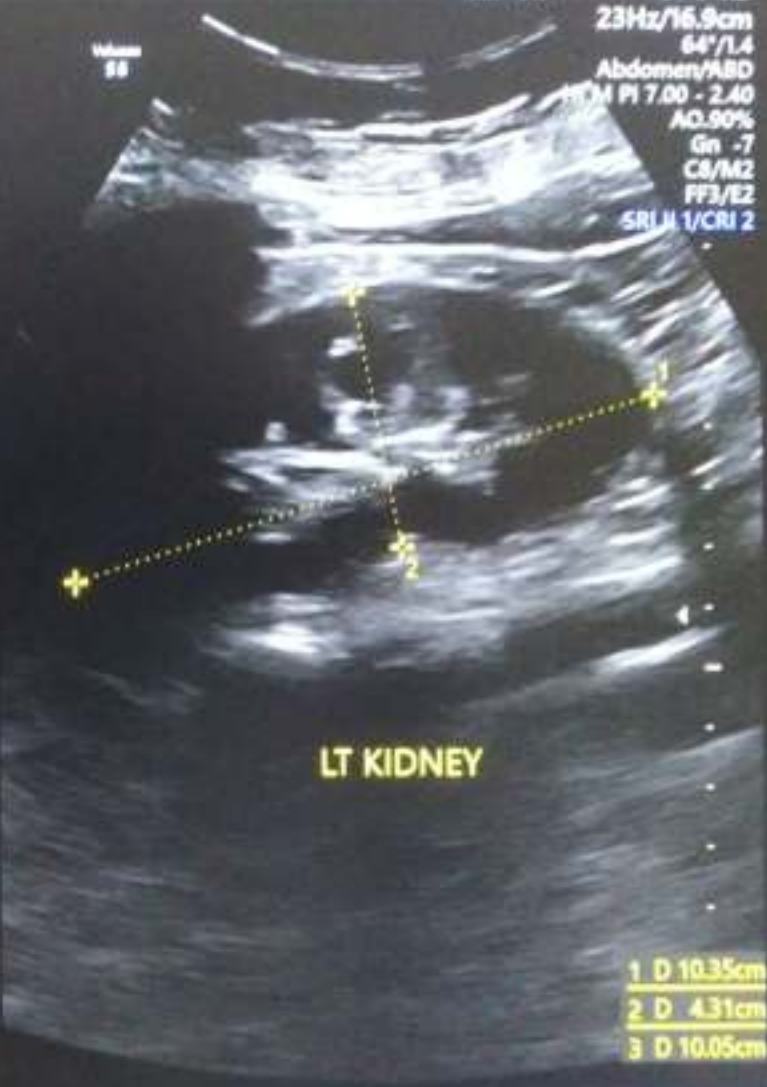
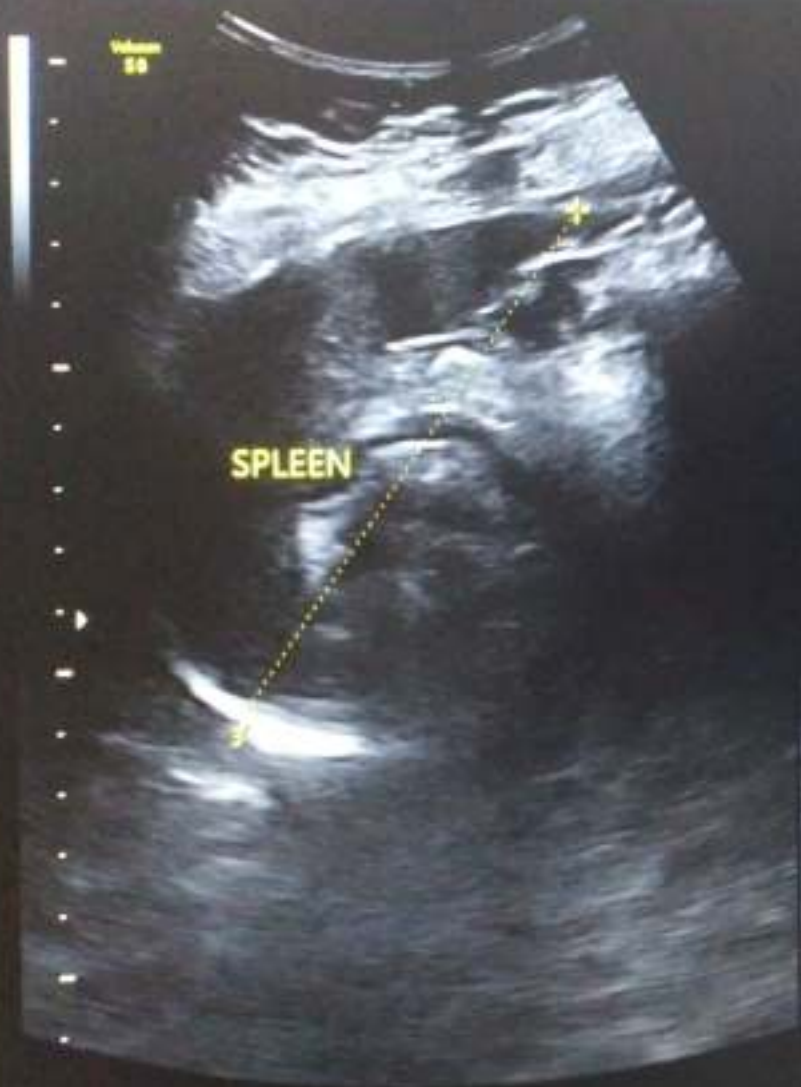


ANIMA GOND 42,
VS8802280-24-01-13-13

ASHWINI LABORATORY

TIs <0.1
Tib <0.1
MI 0.7
13.01.2024
1:48:12 PM
C1-5-RS
23Hz/16.9cm
64°/L4
Abdomen/ABD
M PI 7.00 - 2.40
AO:90%
Gn -7
C8/M2
FF3/E2
SRI II /CRI 2



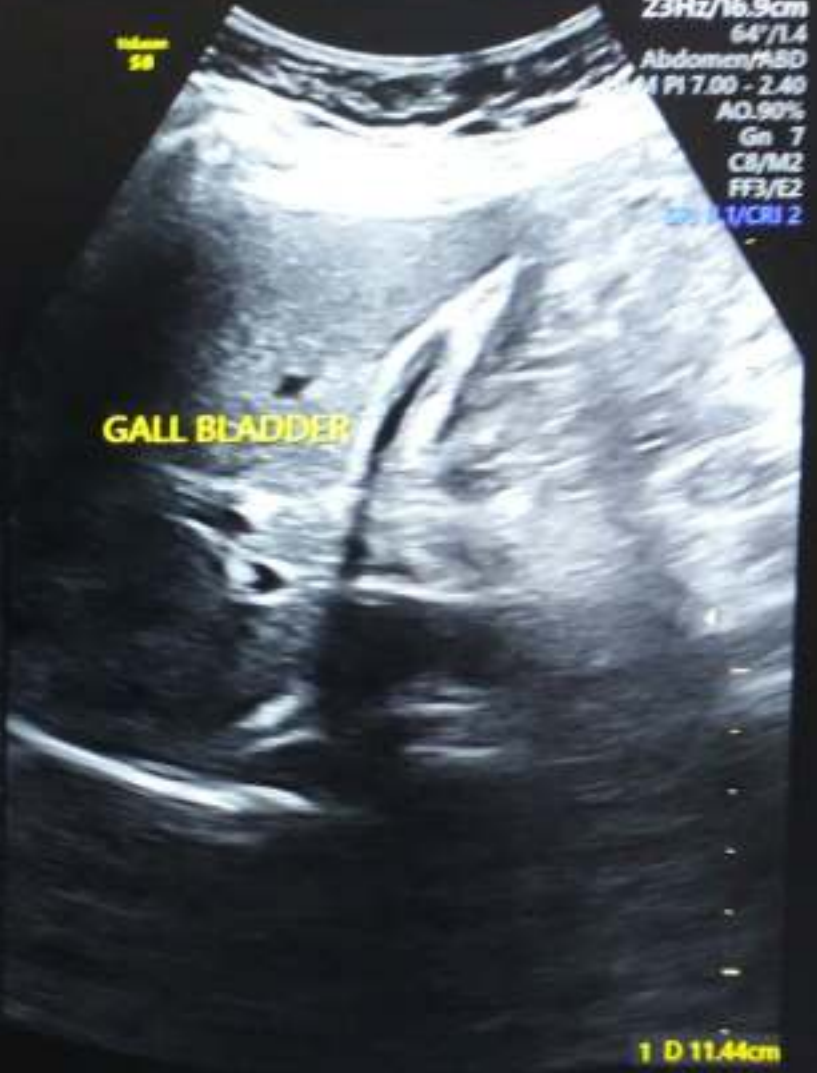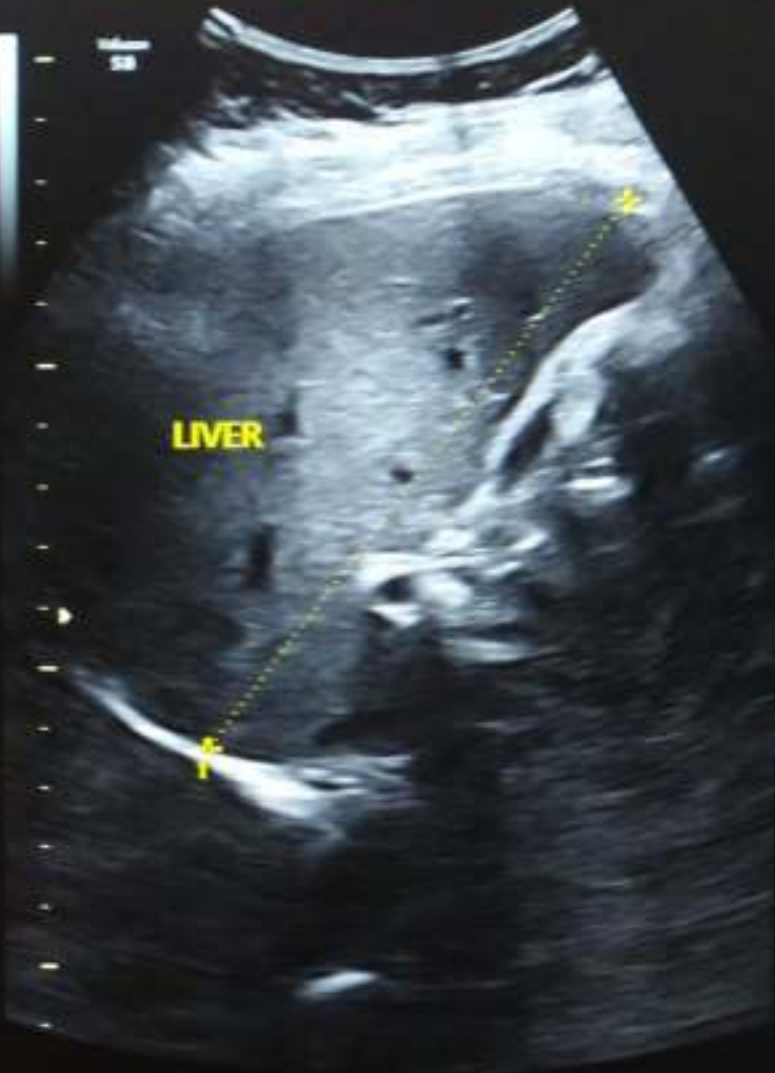1 D 10.35cm
2 D 4.31cm
3 D 10.05cm



ANIMA GOND 42, *
VS8802280-24-01-13-13

ASHWINI LABORATORY

TIs <0.1
Tib <0.1
MI 0.7
13.01.2024
1:48:55 PM
C1-5-RS
23Hz/16.9cm
64°/1.4
Abdomen/ABD
MI PI 7.00 - 2.40
AO.90%
Gn 7
C8/M2
FF3/E2
1/CRI 2





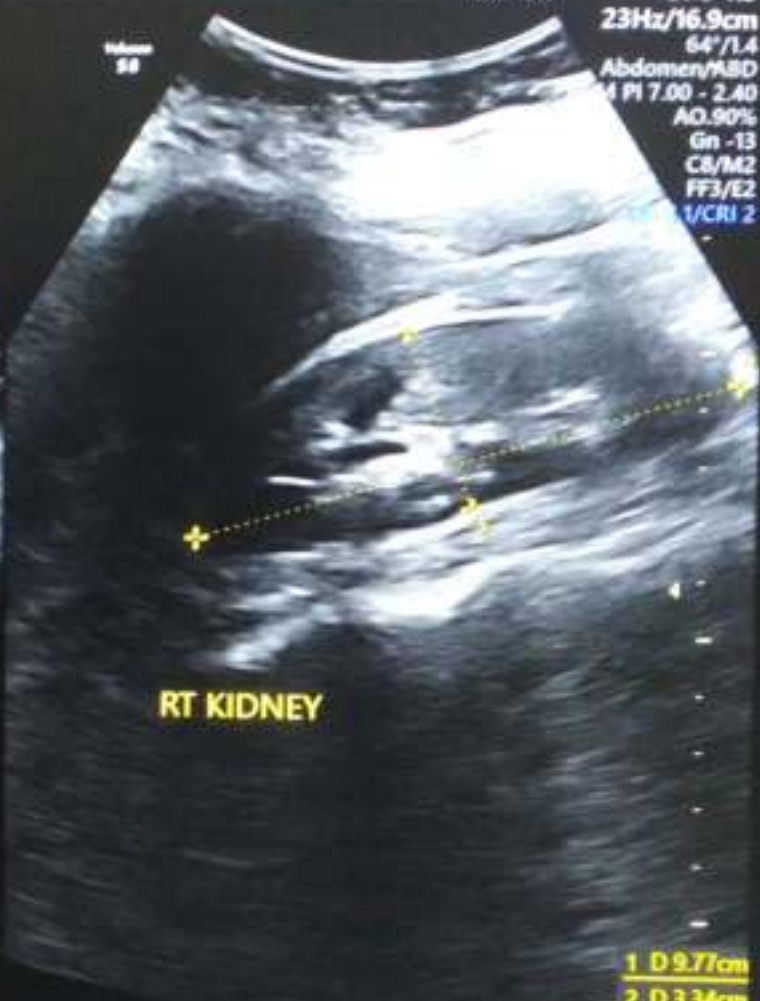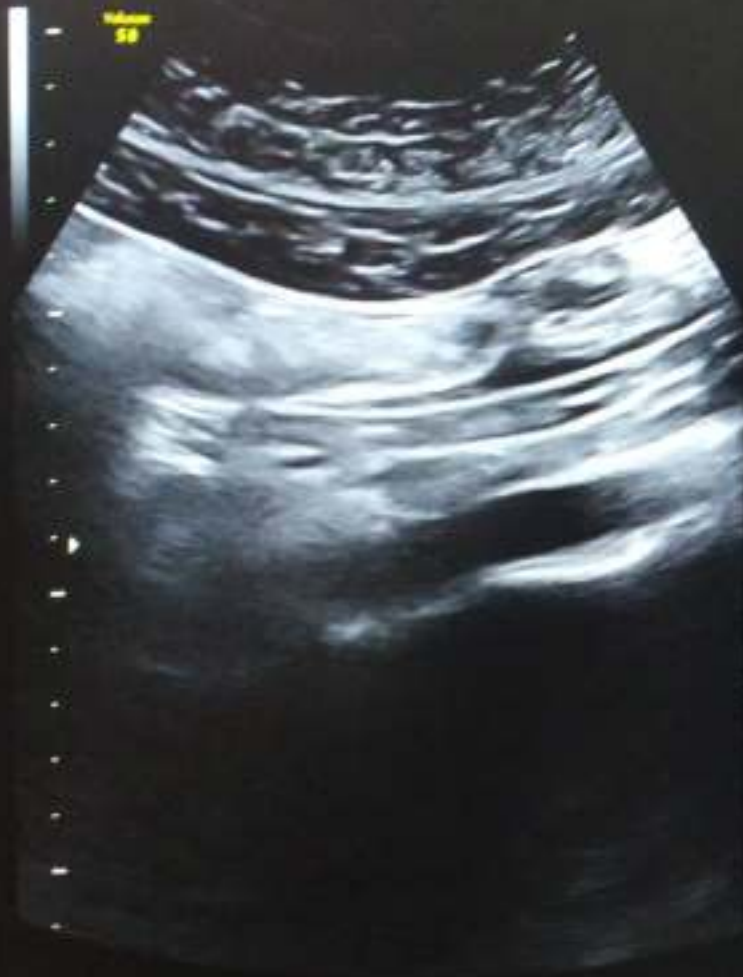ANIMA GOND 42,
VS8802280-24-01-13-13

ASHWINI LABORATORY

TIs <0.1
Tlb <0.1
MI 0.7

13.01.2024
1:49:41 PM
C1-5-RS

23Hz/16.9cm
64°/1.4
Abdomen/MSD
PI 7.00 - 2.40
AO:90%
Gn -13
C8/M2
FF3/E2
V/CRI 2



RT KIDNEY

1 D 9.77cm
2 D 3.34cm

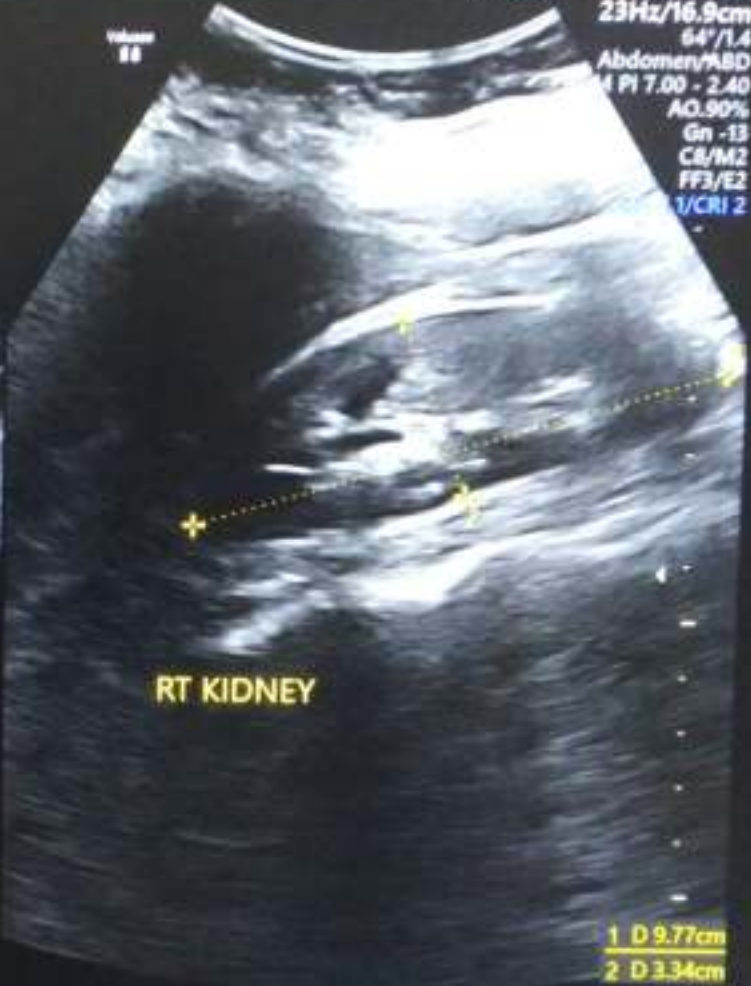
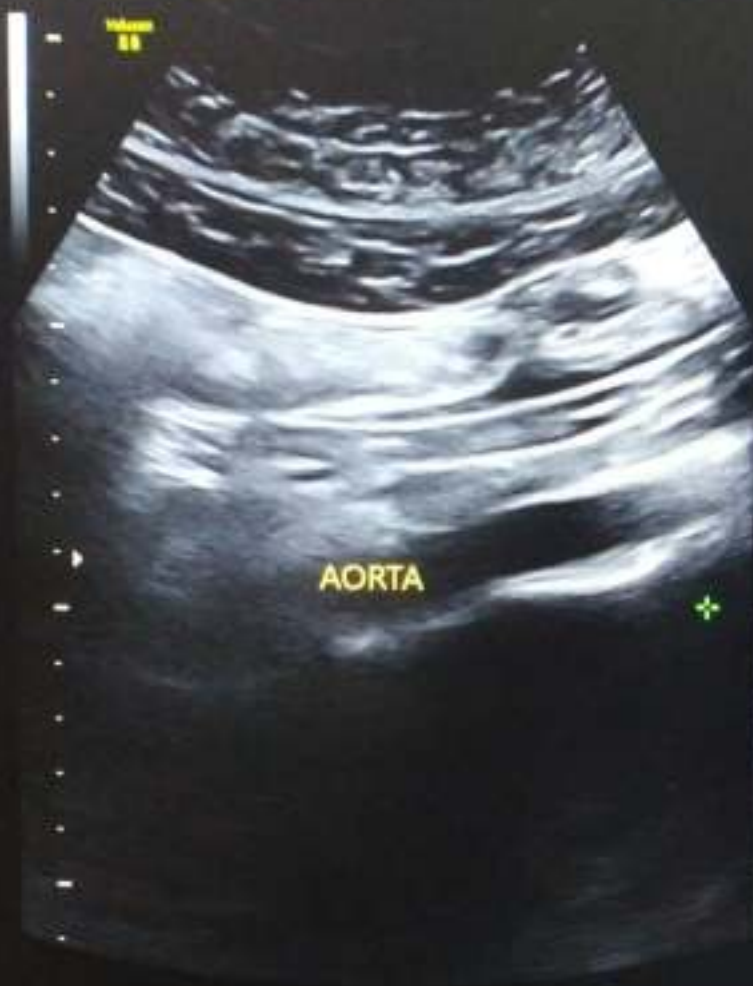
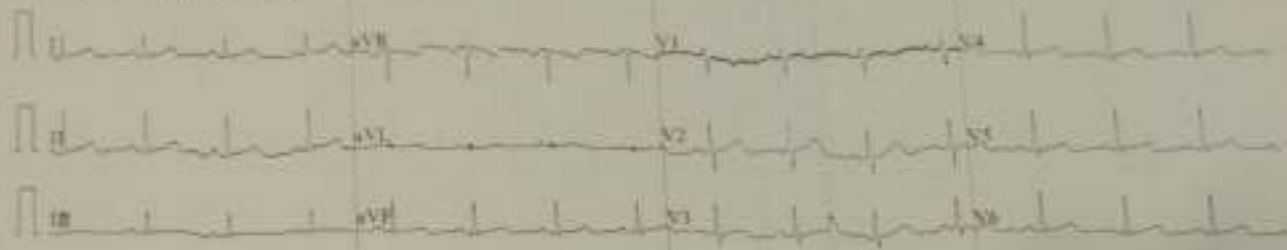
ANIMA GOND 42,
VS8802280-24-01-13-13

ASHWINI LABORATORY

TIs <0.1
Tib <0.1
MI 0.7

13.01.2024
1:49:41 PM
C1-5-R5
23Hz/16.9cm
64°/1.4
Abdomen/ABD
PI 7.00 - 2.40
AO:90%
Gn -13
C8/M2
FF3/E2
I/CRI 2





0.5-100Hz 25mm/s 10mm/mV ♡92 V10 SEMIP V17

ID 4039

Female
42 Years

weight

kg



HR	90	bpm
P	24	ms
PR	130	ms
QRS	60	ms
QT/QTc	372/405	ms
P/QRST	40/89/50	ms
RV5-SV1	0.024/0.358	mV



ELG is Normal
13/1/24

201,202,203, Rizvi Sadan, 2nd Floor, Near Municipal Market, Next to Vaidya Hospital, Panaji - Goa.
Tel : 0832 2238122 | Email : drashadevnetravalkar@gmail.com

NAME: MRS.ANIMA GOND

DATE:13/01/2024

AGE: 42/ YRS

SEX: F

REF BY DR :SELF

ULTRASONOGRAPHY OF ABDOMEN AND PELVIS

LIVER— It shows normal echotexture and size. No focal lesions are seen. Intrahepatic biliary and portal radicals appear normal. Length of liver is 11.4cm.PV -9mm.

PANCREAS— It shows normal echotexture and size. No focal lesions are seen.

GALL BLADDER—It is contracted.Grossly no calculus is seen. Pericholecystic space is normal.CBD is normal.

SPLEEN— It shows normal echotexture and size. Length of spleen is 10cm.

BOTH KIDNEYS Both kidneys show normal echotexture and size. Perirenal space is normal. Corticomedullary differentiation is seen well .No calculus or hydronephrosis is seen in both kidney.

Right kidney—measures 9.7cm x 3.3cms .

Left kidney—measures 10.3cms X 4.3cms.

Urinary Bladder is well distended .No calculus and mass is seen.Both vesicoureteric junctions are normal.

UTERUS : It is anteverted and It measures 7.5cms x4.8cms x 3.2cms.

Myometrium shows normal echotexture.No mass is seen.Endometrial thickness is 4mm.

Both ovaries show normal echotexture and size.

Right ovary—measures 3cms x 1.4cms.

Left ovary -measures 4.4cms x 2.3cms .A follicle 1.8cm is seen.

No adnexal mass is seen.No free fluid is seen in pelvis.Plenty of bowel gases are seen.

Impression : NORMAL STUDY.

With regards,

DR.ASHADEVI NETRAVALKAR,MD
RADIOLOGIST

DR. ASHADEVI NETRAVALKAR
MBBS., MD, AFH
Consultant Radiologist
2nd Floor, Rizvi Sadan Panaji
Tel: 0832-2238122 / 0832-223224

201,202,203, Rizvi Sadan, 2nd Floor, Near Municipal Market, Next to Vaidya Hospital, Panaji - Goa.
Tel: 0832 2238122 | Email: drashanetravalkar@gmail.com

NAME: MRS.ANIMA GOND

AGE: 42/ YRS

REF BY DR :SELF

DATE:13/01/2024

SEX: F

X-RAY CHEST--- PA VIEW

Prominent bronchovascular markings are seen. Otherwise lung fields are clear.

Both costophrenic angles are clear.


Cardiac size is normal

Both domes of diaphragm are normal.

Rib cage is normal.

IMPRESSION : Normal study

With regards,



RADIOLOGIST

DR.ASHADEVI NETRAVALKAR,MD

DR. ASHADEVI NETRAVALKAR

MBBS, MD, AFH

Consultant Radiologist

2nd Floor, Rizvi Sadan Panaji

Tel: 0832-2238122 / 0832-252224

201,202,203, Rizvi Sadan, 2nd Floor, Near Municipal Market, Next to Vaidya Hospital, Panaji - Goa.
Tel: 0832 2238122 | Email: drashanetravalkar@gmail.com

NAME: MRS. ANIMA GOND

AGE: 30/ YRS

REF BY DR :SELF

DATE:13/01/2024

SEX: F

USG OF BOTH BREASTS

BOTH BREASTS:

Normal fibroglandular and fatty tissue is seen in both breasts.

Both areolar and retroareolar and axillary areas are normal.

Two clear cysts measuring 5mm and 6mm are seen at 3 and 5 o'clock positions in left breast.

No mass lesion is seen.

No calcification is seen.

No Lymphnodes are seen.

IMPRESSION—Two cysts in left breast.

With regards,

DR. ASHADEVI NETRAVALKAR, MD
RADIOLOGIST

DR. ASHADEVI NETRAVALKAR
MBBS., MD, AFIH
Consultant Radiologist
2nd Floor, Rizvi Sadan Panaji
Tel: 0832-2238122 / 08322128224

DR. NETRAVALKAR'S ASHWINI PATHOLOGY LABORATORY

(For all Investigation in Histopathology, Cytopathology, Haematology, Clinical Pathology, Microbiology & Hormonal Chemistry)

Consultant Pathologist **Dr. Prasad Netravalkar** MBBS, MD (Path) BOM

(HOME COLLECTION FACILITY AVAILABLE)

Panaji : 1st, Floor, Rizvi Sadan, Above Saroj Emporium, Near Inox Theatre, Opp. Municipal Market, Panaji.
Ph.: 2229142, 8407912840, 8390242524

E-mail: ashwinilabpanaji@gmail.com, drprasadnetravalkar@gmail.com

Mapusa : F8, Ramchandra Chambers, 1st Floor, Mapusa Clinic Road, Mapusa - Bardez, Goa. Ph.: 2252320, 2250709

Sanquelim : 1st floor, Shanta Commercial Complex, Sanquelim - Goa. Ph.: 2364524, 9119574524

Pt.No. : 81 130124

Pt.Name : - Anima Gond

Ref. By : -

Age : 42 Yrs. Sex : F

Date : 13-01-2024

Normal Range

COMPLETE HEMOGRAM

Haemoglobin	: 11.0	g/dl	11.5 - 16.5 g/dl
W.B.C Count	: 8500	cells/ cu-mm	4000 - 11000 cells/ cu-mm
R.B.C Count	: 3.57	millions / cu-mm	3.8 - 4.5 millions / cu-mm
MCV	: 86.8	fL	80 - 99 fL
MCH	: 30.8	Pg	27 - 33 Pg
MCHC	: 35.6	%	32 - 37 %
PCV	: 30.9	%	37 - 47 %
Platelet Count	: 2.78	lakhs /cu mm	1.5 - 4.5 lakhs /cu mm
E.S.R (Westergren)	: 12	mm/hr	0 - 20 mm/hr

DIFFERENTIAL COUNT

Stab Cells	: 04	%	1-5 %
Neutrophils	: 64	%	40- 60 %
Lymphocytes	: 18	%	20 - 45 %
Eosinophils	: 06	%	1 - 6 %
Monocytes	: 08	%	0 - 10 %
Basophils	: 00	%	0 - 1 %
Abnormal Cells	: Nil		

SMEAR EXAMINATION

RBC Morphology	: Normocytic , Normochromic
W.B.C Morphology	: Within Normal Limits
Platelets on Smear	: Adequate
Parasites	: Absent
Blood Group	: 'O' Rh Positive



Pathologist



Dr. Prasad Netravalkar
MBBS, MD (Bom)
GMC Reg. No. 1294

We Care

All Diagnostic facilities under one roof in Panaji centre - Lab, ultrasound, X ray, ECG, TMT, ECHO

DR. NETRAVALKAR'S ASHWINI PATHOLOGY LABORATORY

(For all investigation in Histopathology, Cytopathology, Haematology, Clinical Pathology, Microbiology & Hormonal Chemistry)

Consultant Pathologist **Dr. Prasad Netravalkar** MBBS, MD (Path) BOM

(HOME COLLECTION FACILITY AVAILABLE)

Panaji : 1st, Floor, Rivvi Sadan, Above Saroj Emporium, Near Inox Theatre, Opp. Municipal Market, Panaji.
Ph.: 2229142, 8407912840, 8390242524

E-mail: ashwinilabpanaji@gmail.com, drprasadnetravalkar@gmail.com

Mapusa : FR, Ramchandra Chambers, 1st Floor, Mapusa Clinic Road, Mapusa - Bardez, Goa. Ph.: 2252320, 2250709

Sanquelim : 1st floor, Shanta Commercial Complex, Sanquelim - Goa. Ph.: 2364524, 9119574524

Pt.No. : 81 130124

Pt.Name : - Anita Gond

Age : 42 Yrs. Sex : F

Ref. By : -

Date : 13-01-2024

		Normal Range
Fasting Blood Sugar	: 99.0 mg/dl	70-110 mg/dl
2 Hrs. Blood Sugar	: 87.0 mg/dl	110-140 mg/dl

GLYCOSYLATED HAEMOGLOBIN IN BLOOD (HPLC METHOD)

HbA1C : 5.802 %

Mean Blood Glucose : 119 mg %

INTERPRETATION:

	HbA1c %
NORMAL	Below 6.5 %
GOOD DIABETIC CONTROL	6.5 % - 7.5 %
FAIR CONTROL	7.5 % - 8.0 %
UNSATISFACTORY CONTROL	8.0 % - 10.0 %
POOR CONTROL	Above 10.0 %



Pathologist

Dr. Prasad Netravalkar
MBBS, MD (Bom)
GMC Reg. No. 1294

We Care

All Diagnostic facilities under one roof in Panaji centre - Lab, ultrasound, X ray, ECG, TMT, ECHO

DR. NETRAVALKAR'S ASHWINI PATHOLOGY LABORATORY

(For all investigation in Histopathology, Cytopathology, Haematology, Clinical Pathology, Microbiology & Hormonal Chemistry)

Consultant Pathologist : **Dr. Prasad Netravalkar** MBBS, MD (Path) BOM

(HOME COLLECTION FACILITY AVAILABLE)

Panaji : 1st, Floor, Rizvi Sadan, Above Saroj Emporium, Near Inox Theatre, Opp. Municipal Market, Panaji.
Ph.: 2229142, 8407912840, 8390242524

E-mail: ashwinilabpanaji@gmail.com, drprasadnetravalkar@gmail.com

Mapusa : F8, Ramchandra Chambers, 1st Floor, Mapusa Clinic Road, Mapusa - Bardez, Goa. Ph.: 2252320, 2250709

Sanquelim : 1st floor, Shanta Commercial Complex, Sanquelim - Goa. Ph.: 2364524, 9119574524

Pt.No. : 81 130124

Pt.Name : - Anima Gond

Age : 42 Yrs. Sex : F


Ref. By : -

Date : 13-01-2024

Normal Range

LIPID PROFILE

Total Cholesterol	: 152.0 mg/dl	130 - 220 mg/dl
S. Triglycerides	: 91.0 mg/dl	35 - 170 mg/dl
HDL Cholesterol	: 46.0 mg/dl	> 45 mg/dl
LDL Cholesterol	: 88 mg/dl	< 130 mg/dl
VLDL Cholesterol	: 18 mg/dl	Upto 35 mg/dl
TC/HDL Ratio	: 3.3	< 4.5
LDL/HDL Ratio	: 1.9	2.5 - 3.5


Pathologist



Dr. Prasad Netravalkar
MBBS, MD (Bom)
GMC Reg. No. 1294

We Care

All Diagnostic facilities under one roof in Panaji centre - Lab, ultrasound, X ray, ECG, TMT, ECHO

DR. NETRAVALKAR'S ASHWINI PATHOLOGY LABORATORY

For all investigations in Histopathology, Cytopathology, Haematology, Clinical Pathology, Microbiology & Hormonal Chemistry

Consultant Pathologist - **Dr. Prasad Netravalkar** MBBS, MD (Path) DDM

(HOME COLLECTION FACILITY AVAILABLE)

Panaji : 1st, Floor, Rizvi Sadan, Above Saroj Emporium, Near Inox Theatre, Opp. Municipal Market, Panaji.
Ph.: 2229142, 8407912840, 8390242524

E-mail: ashwinilabpanaji@gmail.com, drprasadnetravalkar@gmail.com

Mapusa : F8, Ramchandra Chambers, 1st Floor, Mapusa Clinic Road, Mapusa - Bardez, Goa. Ph.: 2252320, 2250709

Sanquelim : 1st floor, Shanta Commercial Complex, Sanquelim - Goa. Ph.: 2364524, 9119574524

P.No. : 81 130124

P.Name : - Anima Gond

Age : 42 Yrs. Sex : F

Ref. By : -

Date : 13-01-2024

Normal Range

LIVER FUNCTION TEST

S. Bilirubin (Total)	: 0.46	mg/dl	0 - 1 mg/dl
S. Bilirubin (Direct)	: 0.22	mg/dl	0 - 0.25 mg/dl
S. Bilirubin (Indirect)	: 0.24	mg/dl	0 - 0.75 mg/dl
S.G.O.T	: 25.0	U/L	0 - 42 U/L
S.G.P.T	: 29.0	U/L	0 - 42 U/L
S. Alkaline Phosphatase	: 80.0	IU/L	15 - 112 IU/L
GGTP	: 23.0	U/L	9-37 U/L
Total Proteins	: 6.81	g/dl	6.0 - 10.0 g/dl
S. Albumin	: 3.74	gm%	3.2 - 5.5 gm%
S. Globulin	: 3.1	g/dl	2.3 - 3.5 g/dl
A/G Ratio	: 1.2 : 1		



[Signature]
Pathologist

Dr. Prasad Netravalkar
MBBS, MD (Bom)
GMC Reg. No. 1294

We Care

All Diagnostic facilities under one roof in Panaji centre - Lab, ultrasound, X ray, ECG, TMT, ECHO

DR. NETRAVALKAR'S ASHWINI PATHOLOGY LABORATORY

(For all investigation in Histopathology, Cytopathology, Haematology, Clinical Pathology, Microbiology & Hormonal Chemistry)

Consultant Pathologist: **Dr. Prasad Netravalkar** MBBS, MD (Path) BOM

(HOME COLLECTION FACILITY AVAILABLE)

Panaji : 1st, Floor, Rizvi Sadan, Above Saroj Emporium, Near Inox Theatre, Opp. Municipal Market, Panaji.
Ph.: 2229142, 8407912840, 8390242524

E-mail: ashwinilabpanaji@gmail.com, drprasadnetravalkar@gmail.com

Mapusa : F8, Ramchandra Chambers, 1st Floor, Mapusa Clinic Road, Mapusa - Bardez, Goa. Ph.: 2252320, 2250709

Sanquelim : 1st floor, Shanta Commercial Complex, Sanquelim - Goa. Ph.: 2364524, 9119574524

Pt.No. : 81 130124

Pt.Name : - Anima Gond

Ref. By : -

Age : 42 Yrs. Sex : F

Date : 13-01-2024

Normal Range

KIDNEY FUNCTION TESTS

Blood Urea	: 27.0 mg/dl	15 - 40 mg/dl
S. Creatinine	: 0.89 mg/dl	0.5 - 1.2 mg/dl
S. Uric Acid	: 4.60 mg/dl	1.5 - 6.0 mg/dl
S. Sodium	: 139.7 mEq/L	135 - 155 mEq/L
S. Potassium	: 4.23 mEq/L	3.5 - 5.5 mEq/L
S. Chlorides	: 102.9 mEq/L	99 - 108 mEq/L

Pathologist



Dr. Prasad Netravalkar
MBBS, MD (Bom)
GMC Reg. No. 1294

We Care

All Diagnostic facilities under one roof in Panaji centre - Lab, ultrasound, X ray, ECG, TMT, EEG

DR. NETRAVALKAR'S ASHWINI PATHOLOGY LABORATORY

(Specialty of Investigation in Histopathology, Cytopathology, Haematology, Clinical Pathology, Microbiology & Hormonal Chemistry)
Consultant Pathologist - Dr. Prasad Netravalkar MBBS, MD (Path) DCM

(HOME COLLECTION FACILITY AVAILABLE)

Panaji : 1st Floor, Rivi Sadan, Above Saroj Emporium, Near Inox Theatre, Opp. Municipal Market, Panaji.
Ph.: 2229142, 8407912840, 8390242524

E-mail: ashwinilabpanaji@gmail.com, drprasadnetravalkar@gmail.com

Mapusa : FS, Ramchandra Chambers, 1st Floor, Mapusa Clinic Road, Mapusa - Bardez, Goa. Ph.: 2252320, 2250709

Sanquelim : 1st floor, Shanta Commercial Complex, Sanquelim - Goa. Ph.: 2364524, 9119574524

Pt.No. : 81 130124

Pt.Name : - Anima Gond

Age : 42 Yrs. Sex : F

Ref. By : -

Date : 13-01-2024

EXAMINATION OF URINE

PHYSICAL EXAMINATION

Quantity : 20 ml
Colour : Pale Yellow
Appearance : Slightly Hazy
pH : 6.5
Specific Gravity : 1.010

CHEMICAL EXAMINATION

Proteins : Absent
Glucose : Absent
Ketone Bodies : Absent
Bile Salts : Absent
Bile Pigments : Absent
Occult Blood : Negative
Urobilinogen : Normal

MICROSCOPIC EXAMINATION [As per hpf]

Epithelial Cells : 40 - 50 /hpf
Pus Cells : 30 - 40 /hpf
Red Blood Cells : Absent
Casts : Absent
Crystals : Absent

OTHER FINDINGS

Bacteria : Present (Trace)



Pathologist



Dr. Prasad Netravalkar
MBBS, MD (Bom)
GMC Reg. No. 1294

We Care

All Diagnostic facilities under one roof in Panaji centre - Lab, ultrasound, X ray, ECG, TMT, ECHO

DR. NETRAVALKAR'S ASHWINI PATHOLOGY LABORATORY

(For all Investigation in Histopathology, Cytopathology, Haematology, Clinical Pathology, Microbiology & Hormonal Chemistry)

Consultant Pathologist **Dr. Prasad Netravalkar** MBBS, MD (Pw) BOM

(HOME COLLECTION FACILITY AVAILABLE)

Panaji : 1st Floor, Ravi Sadan, Above Saroj Emporium, Near Inox Theatre, Opp. Municipal Market, Panaji.
Ph.: 2229142, 8407912840, 8390242524

E-mail: ashwinilabpanaji@gmail.com, drprasadnetravalkar@gmail.com

Mapusa : FS, Ramchandra Chambers, 1st Floor, Mapusa Clinic Road, Mapusa - Bardez, Goa. Ph.: 2252320, 2250709

Sanquelim : 1st floor, Shanta Commercial Complex, Sanquelim - Goa. Ph.: 2364524, 9119574524

Pt.No. : 81 130124

Pt.Name : - Anima Gond

Ref. By : -


Age : 42 Yrs. Sex : F

Date : 13-01-2024

BIOCHEMISTRY REPORTS

Fasting Urine Glucose : Absent

2 Hrs. Urine Glucose : Absent



Pathologist



Dr. Prasad Netravalkar
MBBS, MD (Bom)
GMC Reg. No. 1294

We Care

All Diagnostic facilities under one roof in Panaji centre - Lab. ultrasound, X ray, ECG, TMT, ECHO

DR. NETRAVALKAR'S ASHWINI PATHOLOGY LABORATORY

Specialization in Histopathology, Cytopathology, Haematology, Clinical Pathology, Microbiology & Hormonal Chemistry

Consultant Pathologist - **Dr. Prasad Netravalkar** MBBS, MD (Pw) BOM

(HOME COLLECTION FACILITY AVAILABLE)

Panaji : 1st Floor, Rizvi Sadan, Above Saroj Emporium, Near Inox Theatre, Opp. Municipal Market, Panaji.
Ph.: 2229142, 8407912840, 8390242524

E-mail: ashwinilabpanaji@gmail.com, drprasadnetravalkar@gmail.com

Mapusa : FS, Ramchandra Chambers, 1st Floor, Mapusa Clinic Road, Mapusa - Bardez, Goa. Ph.: 2252320, 2250709

Sanquelim : 1st floor, Shanta Commercial Complex, Sanquelim - Goa. Ph.: 2364524, 9119574524

Patient Name : ANIMA GOND

Age / Gender : 42 / Female

Patient ID : 30058

Source : DIRECT

Referral : SELF

Reporting Time : Jan 13, 2024, 03:34 p.m.

Sample ID :



Test Description	Value(s)	Reference Range	Unit
Thyroid Profile			
T3 (Total) Method: Serum ECL	2.06	1.30 - 3.10	nmol/l
T4 (Total)* Method: Serum ECL	159.4	66.0 - 181.0	nmol/l
TSH(Ultrasensitive)* Method: Serum ECL	2.71	0.270 - 4.20	uIU/ml

END OF REPORT

Pathologist



Dr. Prasad Netravalkar
MBBS, MD (Bom)
GMC Reg. No. 1294

We Care

All Diagnostic facilities under one roof in Panaji centre - Lab, ultrasound, X ray, ECG, TMT, EEG


CERTIFICATE OF MEDICAL FITNESS

This is to certify that I have conducted the clinical examination

of Anima Grand on 13/1/24

After reviewing the medical history and on clinical examination it has been found that he/she is

	Tick
<ul style="list-style-type: none">• Medically Fit	<input checked="" type="checkbox"/>
<ul style="list-style-type: none">• Fit with restrictions/recommendations <p>Though following restrictions have been revealed, in my opinion, these are not impediments to the job.</p> <p>1 _____</p> <p>2 _____</p> <p>3 _____</p> <p>However the employee should follow the advice/medication that has been communicated to him/her.</p> <p>Review after _____</p>	<input type="checkbox"/>
<ul style="list-style-type: none">• Currently Unfit. <p>Review after _____ recommended</p>	<input type="checkbox"/>
<ul style="list-style-type: none">• Unfit	<input type="checkbox"/>


Dr. 
Medical Officer
The Apollo Clinic, (Location)

This certificate is not meant for medico-legal purposes



MER- MEDICAL EXAMINATION REPORT

Date of Examination	3/1/24		
NAME	Anima Gond		
AGE	42	Gender	F
HEIGHT(cm)	150	WEIGHT (kg)	65 kg
B.P.	130/86 mmHg		
ECG	normal		
X-Ray	normal		
Vision Checkup	Colour Vision: normal		
	Far Vision Ratio: 6/6		
	Near Vision Ratio: 6/6		
Present Ailments	-NO-		
Details of Past ailments (if Any)	-NO-		
Comments / Advice : <input checked="" type="checkbox"/> She / He is Physically Fit	she is physically Fit		



Signature with Stamp of Medical Examiner



आयकर विभाग
INCOME TAX DEPARTMENT
ANIMA GOND
SHIV SINGH GOND
18/12/1981
ALCPG5450F

भारत सरकार
GOVT. OF INDIA



Anima



**DR. NETRAVALKAR'S
ASHWINI PATHOLOGY LABORATORY**

(Investigation in Histopathology, Cytopathology, Haematology, Clinical Pathology, Microbiology & Hemisial Chemistry)
Consultant Pathologist: **Dr. Prasad Netravalkar** MBBS, MD (Path) BOM

(HOME COLLECTION FACILITY AVAILABLE)

Panaji : 1st, Floor, Rizvi Sadan, Above Saroj Emporium, Near Inox Theatre, Opp. Municipal Market, Panaji.
Ph: 2229142, 8407912840, 8390242524
E-mail: ashwinilabpanaji@gmail.com, drprasadnetravalkar@gmail.com
Mapusa : F8, Ramchandra Chambers, 1st Floor, Mapusa Clinic Road, Mapusa - Bardez, Goa. Ph.: 2252320, 2250709
Sanquelim : 1st floor, Shanta Commercial Complex, Sanquelim - Goa. Ph.: 2364524, 9119574524

Patients Name : Anima Gond , 42Y/F

Date : 16/01/24

Ref. by Dr : -

CYTOPATHOLOGY REPORT

Specimen Sent : Pap Smears.

Report : Pap smears show moderate sheets of superficial epithelial cells, few sheets of intermediate epithelial cells & occasional groups of endocervical epithelial cells.

The epithelial cells show normal nucleus:cytoplasm ratio. Their nuclear chromatin is regular and well scattered.

Occasional neutrophils & Dod .Bacilli are seen in background.

No fungi or protozoa seen.

No evidence of dysplasia or malignancy seen.

Opinion : Pap smears show no significant pathology.



Pathologist

Dr. Prasad Netravalkar
MBBS, MD (Bom)
GMC Reg. No. 1294

We Care

All Diagnostic facilities under one roof in Panaji centre - Lab, ultrasound, X ray, ECG, TMT, ECHO



GPS Map Camera



Panaji, Goa, India

B 165, New Municipal Market, Panaji, Goa 403001, India

Lat 15.498474°

Long 73.822368°

13/01/24 10:25 AM GMT +05:30