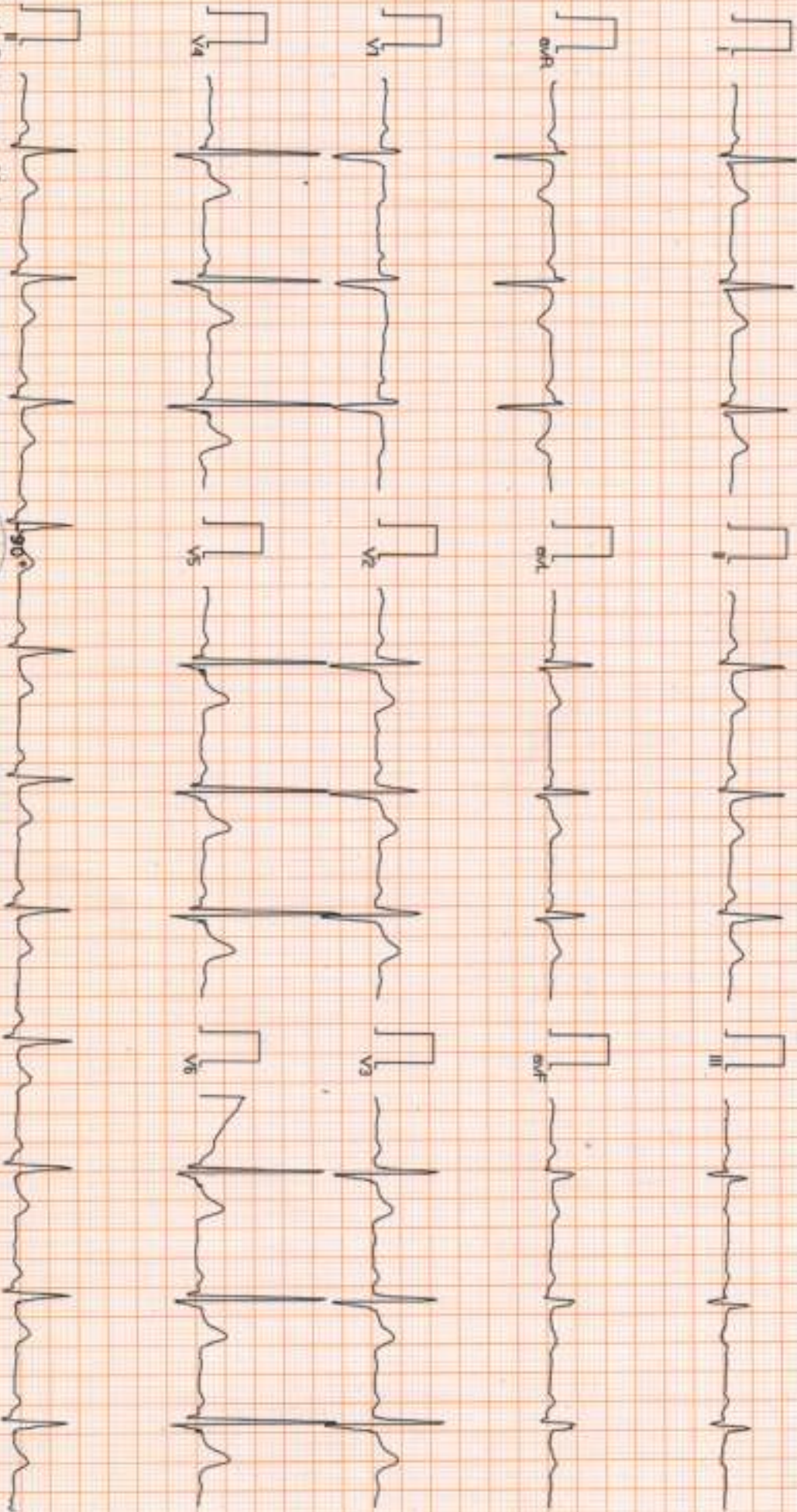
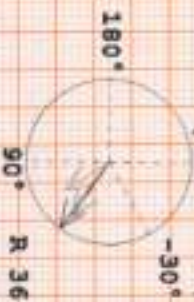
Vant Rate : 69 bpm
PR Interval : 164 ms
QRS Duration: 104 ms
QT/QTc Int : 398/414 ms
P-QRS-T axis: 57.00° 36.00° 33.00°



TW

DR. NITIZ GOYAL
M.B.B.S (M)

RMC-023



Aakriti Labs

3 Mahatma Gandhi Marg, Gandhi Nagar Mod
Tonk Road, Jaipur (Raj.) Ph.: 0141-2710661
www.aakritilabs.com
CIN NO.: U85195RJ2004PTC019563

NAME	MR MOHAMMAD SHAKEEL	AGE	40YRS	SEX	MALE
REF BY	MEDI WHEEL	DATE	20/08/2023	REG NO	

ECHOCARDIOGRAM REPORT

WINDOW- POOR/ADEQUATE/GOODVALVE

MITRAL	NORMAL	TRICUSPID	NORMAL
AORTIC	NORMAL	PULMONARY	NORMAL

2D/M-MOD

IVSD mm	9.5	IVSS mm	13.2	AORTA mm	24.7
LVID mm	42.6	LVIS mm	26.4	LA mm	29.1
LVPWD mm	9.5	LVPWS mm	13.2	EF%	60%

CHAMBERS

LA	NORMAL	RA	NORMAL
LV	NORMAL	RV	NORMAL
PERICARDIUM	NORMAL		

DOPPLER STUDY MITRAL

PEAK VELOCITY m/s E/A	0.90/0.64	PEAK GRADIANT MmHg	
MEAN VELOCITY m/s		MEAN GRADIANT MmHg	
MVA cm2 (PLANIMETERY)		MVA cm2 (PHT)	
MR			

AORTIC

PEAK VELOCITY m/s	1.10	PEAK GRADIANT MmHg	
MEAN VELOCITY m/s		MEAN GRADIANT MmHg	
AR			

TRICUSPID

PEAK VELOCITY m/s	0.53	PEAK GRADIANT MmHg	
MEAN VELOCITY m/s		MEAN GRADIANT MmHg	
TR	TRACE	PASP mmHg	

PULMONARY

PEAK VELOCITY m/s	0.82	PEAK GRADIANT MmHg	
MEAN VELOCITY m/s		MEAN GRADIANT MmHg	
PR		RVEDP mmHg	

IMPRESSION

- NORMAL LV SYSTOLIC & DIASTOLIC FUNCTION
- NO RWMA LVEF 60%
- NORMAL RV FUNCTION
- TRACE TR
- NORMAL CHAMBER DIMENSIONS
- NORMAL VALVULAR ECHO
- INTACT IAS / IVS
- NO THROMBUS, NO VEGETATION, NORMAL PERICARDIUM.
- IVC NORMAL

CONCLUSION : FAIR LV FUNCTION.


Cardiologist



DR. NARENDER SINGH SHEKHAWAT

(BDS, MIDA)

REG. - A-8664

REG. NO:

NAME: Mohammad Akhlaq

AGE: 40

GENDER: male

CHIEF COMPLAINT:

PT/CP dry
feels
dryly pty.

**PROVISIONAL
DIAGNOSIS:**

INVESTIGATION:

INSTRUCTION:

use sali
use

NEXT VISIT:

Rx

Adult - dry +
pty

	जलरत पडने पर	खाली पेट	सुबह	दोपहर	रात
MIORA-K			✓		✓
nimesgen					
Sanguel-P mouthwash			✓		✓
(1-1)					

FEE VALID UPTO 3 DAYS

162/60 SECTOR 16, OPP. ALPHA BETA SCHOOL, PRATAP NAGAR,
NEAR COACHING HUB, JAIPUR, RAJASTHAN - 302033

7976353746

dantatease@gmail.com

dant_at_ease

TIMINGS: 10-12 PM
8 AM - 12 PM
5 PM - 9 PM

SUNDAY: 8 AM - 12 PM



Aakriti Labs

3 Mahatma Gandhi Marg, Gandhi Nagar Mod
Tonk Road, Jaipur (Raj.) Ph.: 0141-2710661
www.aakritilabs.com
CIN NO.: U85195RJ2004PTC019563



Name : Mr. MOHAMMAD SHAKEEL
Age/Gender: 40 Y/Male
Patient ID : 012308200022
BarcodeNo : 10096169
Referred By : Self

Registration No: 64569
Registered : 20/Aug/2023 09:41AM
Analysed : 20/Aug/2023 02:09PM
Reported : 20/Aug/2023 02:09PM
Panel : MEDI WHEEL (ARCOFEMI
HEALTHCARE LTD)

DIGITAL X-RAY CHEST PA VIEW

Soft tissue shadow and bony cages are normal.

Trachea is central.

Bilateral lung field and both CP angle are clear.

Domes of diaphragm are normally placed.

Transverse diameter of heart appears with normal limits.

IMPRESSION:- NO OBVIOUS ABNORMALITY DETECTED.

*** End Of Report ***

Page 1 of 1



Dr. Neera Mehta
M.B.B.S., D.M.R.D.
RMCNO.005807/14853



Aakriti Labs

3 Mahatma Gandhi Marg, Gandhi Nagar Mod
Tonk Road, Jaipur (Raj.) Ph.: 0141-2710661
www.aakritilabs.com
CIN NO.: U85195RJ2004PTC019563



Name : Mr. MOHAMMAD SHAKEEL

Age/Gender: 40 Y/Male

Patient ID : 012308200022

BarcodeNo : 10096169

Referred By : Self

Registration No: 64569

Registered : 20/Aug/2023 09:41AM

Analysed : 20/Aug/2023 12:05PM

Reported : 20/Aug/2023 12:05PM

Panel : MEDI WHEEL (ARCOFEMI
HEALTHCARE LTD)

USG: WHOLE ABDOMEN (Male)

LIVER : Is normal in size, shape and echogenicity.
The IHBR and hepatic radicals are not dilated.
No evidence of focal echopoor/echorich lesion seen.
Portal vein diameter and common bile duct appear normal.

GALL : Is normal in size, shape and echotexture. Walls are smooth and
BLADDER regular with normal thickness. There is no evidence of cholelithiasis.

PANCREAS : Is normal in size, shape and echotexture. Pancreatic duct is not dilated.

SPLEEN : Is normal in size, shape and echogenicity. Splenic hilum is not dilated.

KIDNEYS : Right Kidney:-Size: 96 x 42 mm, Left Kidney:-Size: 102 x 46 mm.
Bilateral Kidneys are normal in size, shape and echotexture,
corticomedullary differentiation is fair and ratio appears normal.
Pelvi calyceal system is normal. No evidence of hydronephrosis/ nephrolithiasis.

URINARY : Bladder walls are smooth, regular and normal thickness.

BLADDER : No evidence of mass or stone in bladder lumen.

PROSTATE: Is normal in size, shape and echotexture,
measures: 41 x 29 x 21 mm, wt: 13 gms.
Its capsule is intact and no evidence of focal lesion.


SPECIFIC : No evidence of retroperitoneal mass or free fluid seen in peritoneal cavity.
No evidence of lymphadenopathy or mass lesion in retroperitoneum.
Visualized bowel loop appear normal. Great vessels appear normal.

IMPRESSION :- NORMAL STUDY.

*** End Of Report ***

Page 1 of 1




Dr. Neera Mehta
M.B.B.S., D.M.R.D.

RMCNO.005807/14853