

Name : Mrs. MEERA BAI

Age: 40 Y

UHID:CELE.0000049782

Sex: F



Address : E CITY

OP Number:CELEOPV342141

 Plan : ARCOFEMI MEDIWHEEL FEMALE AHC CREDIT PAN
 INDIA OP AGREEMENT

Bill No :CELE-OCR-55545

Date : 08.03.2024 09:16

Sno	Service Type/ServiceName	Department
1	ARCOFEMI - MEDIWHEEL - FULL BODY ANNUAL PLUS CHECK ADVANCED - FEMALE - 2D ECHO - PAN INDIA - FY2324	
1	GAMMA GLUTAMYL TRANSFERASE (GGT)	
2	D'ECHO - 11	
3	LIVER FUNCTION TEST (LFT)	
4	GLUCOSE, FASTING - 12	
5	HEMOGRAM + PERIPHERAL SMEAR	
6	GYNAECOLOGY CONSULTATION	
7	DIET CONSULTATION	
8	COMPLETE URINE EXAMINATION	
9	URINE GLUCOSE(POST PRANDIAL)	
10	PERIPHERAL SMEAR	
11	ECG - 13	
12	LBC PAP TEST- PAPSURE - 16	
13	RENAL PROFILE/RENAL FUNCTION TEST (RFT/KFT)	
14	DENTAL CONSULTATION - 15	
15	GLUCOSE, POST PRANDIAL (PP), 2 HOURS (POST MEAL)	
16	URINE GLUCOSE(FASTING)	
17	SONO MAMOGRAPHY - SCREENING	
18	HbA1c, GLYCATED HEMOGLOBIN	
19	X-RAY CHEST PA - 08	
20	ENT CONSULTATION	
21	FITNESS BY GENERAL PHYSICIAN - 25 (1)	
22	BLOOD GROUP ABO AND RH FACTOR	
23	LIPID PROFILE	
24	BODY MASS INDEX (BMI)	
25	OPHTHAL BY GENERAL PHYSICIAN - 05	
26	ULTRASOUND - WHOLE ABDOMEN - 08	
27	THYROID PROFILE (TOTAL T3, TOTAL T4, TSH)	

Audio-3, physio-14

(+) UICB12

MEDICAL FITNESS CERTIFICATE

NAME: Mr MEERA DAS **AGE/SEX:** 40YF **UHID:** **DATE:** 8/2/2024

CHIEF COMPLAINTS:
NO

PAST/FAMILY HISTORY:- NO

ALLERGIES:- NIL

GENERAL EXAMINATION:-

PULSE: 72	BP: 142/94	TEMP: 37.2	RR: 24
HT: 162	WT: 79.9	WAIST: 106	BMI: 30.9

HIP NO

SYSTEMIC EXAMINATION: -
NAD

VISION SCREENING

<u>Vision</u>	<u>Rt</u>	<u>Lt</u>	<u>With Corrections</u>
<u>DISTANT</u>			
<u>NEAR</u>			
<u>COLOUR</u>			

Chest: - DIC NASH

CVS: - S12R

P/A: - SOST

IMPRESSION:-

FINAL RECOMMENDATIONS:-

A

GENERAL PHYSICIAN

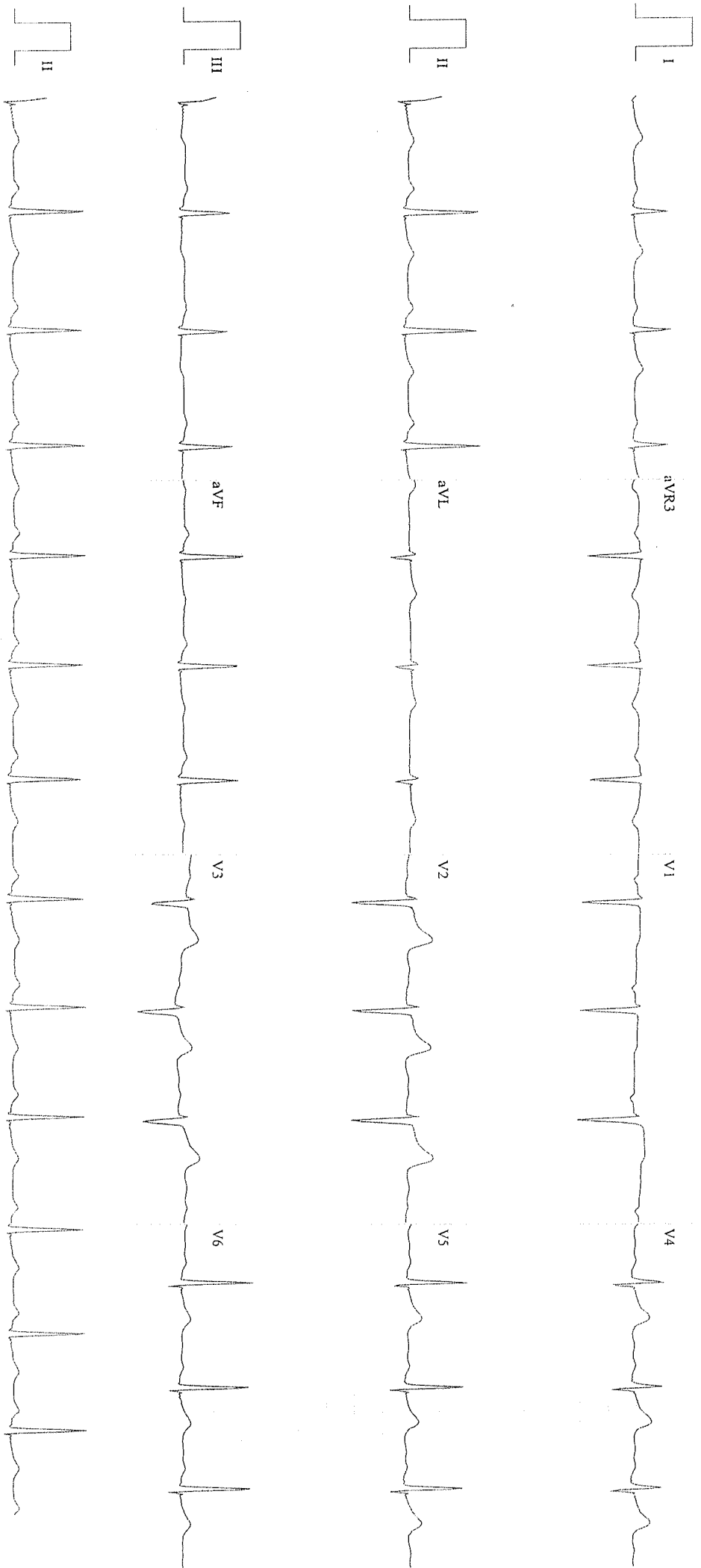
Personal Details
UHID: 00XHE1PU6TE0QJO
Patient ID: 49782
Name: Mrs Meera Bai
Age: 40
Gender: Female
Mobile: 9740698861

Pre-Existing Medical-
Conditions
Symptoms

Vitals

Measurements
HR: 76 BPM
PR: 174 ms
PD: 124 ms
QRSD: 85 ms
QRS Axis: 61 deg
QT/QTc: 394/394 ms

Report ID: AHLLP_00XHE1PU6TE0QJO_V6TE0QJA
Interpretation(Unconfirmed)
Normal Sinus Rhythm
Normal Axis



Disclaimer: ECG should be interpreted by qualified Medical Practitioners only.

Speed: 25 mm/sec F: 0.05 - 40 Hz Limb: 10 mm/mV Chest: 10 mm/mV

Patient Name : Mrs. MEERA BAI
UHID : CELE.0000049782
Reported on : 08-03-2024 14:30
Adm/Consult Doctor :

Age : 40 Y F
OP Visit No : CELEOPV342141
Printed on : 08-03-2024 14:30
Ref Doctor : SELF

DEPARTMENT OF RADIOLOGY

X-RAY CHEST PA

Both lung fields and hila are normal .

No obvious active pleuro-parenchymal lesion seen .

Both costophrenic and cardiophrenic angles are clear .

Both diaphragms are normal in position and contour .


Thoracic wall and soft tissues appear normal.

CONCLUSION :

No obvious abnormality seen

Printed on:08-03-2024 14:30

---End of the Report---


Dr. VIGNESH K
MBBS, MD Radio-Diagnosis
Radiology

Apollo Health and Lifestyle Limited

(CIN - U85110TG2000PLC115819)

Regd. Office: 1-10-60/62, Ashoka Raghupathi Chambers, 5th Floor, Begumpet, Hyderabad, Telangana - 500 016.


Ph No: 040-4904 7777, Fax No: 4904 7744 | Email ID: enquiry@apollohl.com | www.apollohl.com

APOLLO CLINICS NETWORK KARNATAKA

Bangalore (Basavanagudi | Bellandur | Electronic City | Fraser Town | HSR Layout | Indira Nagar | JP Nagar | Kundalahalli | Koramangala | Sarjapur Road) **Mysore** (VV Mohalla)

Online appointments: www.apolloclinic.com

TO BOOK AN APPOINTMENT

 **1860 500 7788**

NAME:	Mrs. MEERA BAI
AGE / SEX:	40 YRS/ FEMALE
DATE:	08/03/2024
REFERRED BY:	ARCOFEMI

BILATERAL BREAST SCAN

All four Quadrants of each breast were scanned, followed by evaluation of the subareolar region and axillary tails.

Bilateral breast parenchyma display a uniform echogenicity and echo texture of the fibrofatty and glandular components, which are in normal proportion for this age and parity.

There is no evidence of any mass lesion, cysts or calcification seen in the bilateral breast.


Both Axillary tails are also normal.

No abnormal axillary lymphnodes noted.

Impression:

- No definitive sonological abnormality detected in present scan.
- US BIRADS I (NORMAL).

*To correlate clinically & with other investigations.
Not for medico-legal purpose*



DR. VIGNESH K

CONSULTANT RADIOLOGIST

Apollo Health and Lifestyle Limited

(CIN - U85110TG2000PLC115819)

Regd. Office: 1-10-60/62, Ashoka Raghupathi Chambers, 5th Floor, Begumpet, Hyderabad, Telangana - 500 016.


Ph No: 040-4904 7777, Fax No: 4904 7744 | Email ID: enquiry@apollohi.com | www.apollohi.com

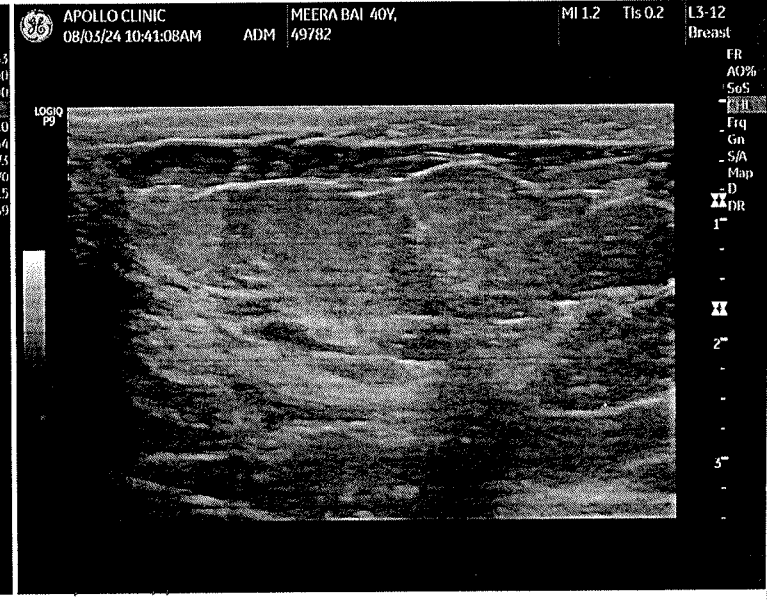
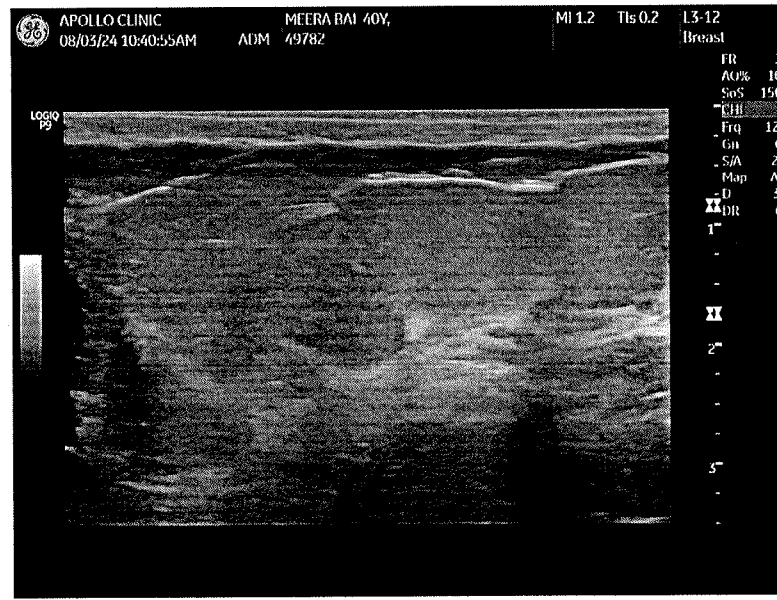
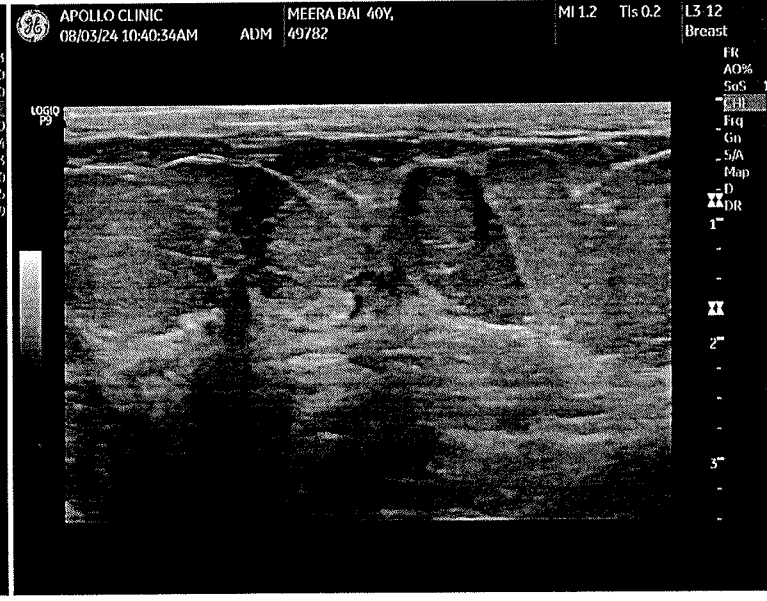
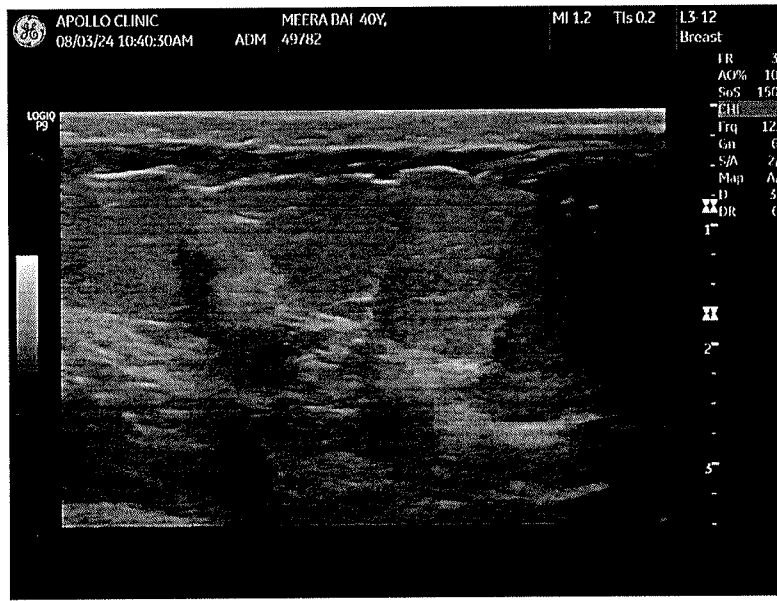
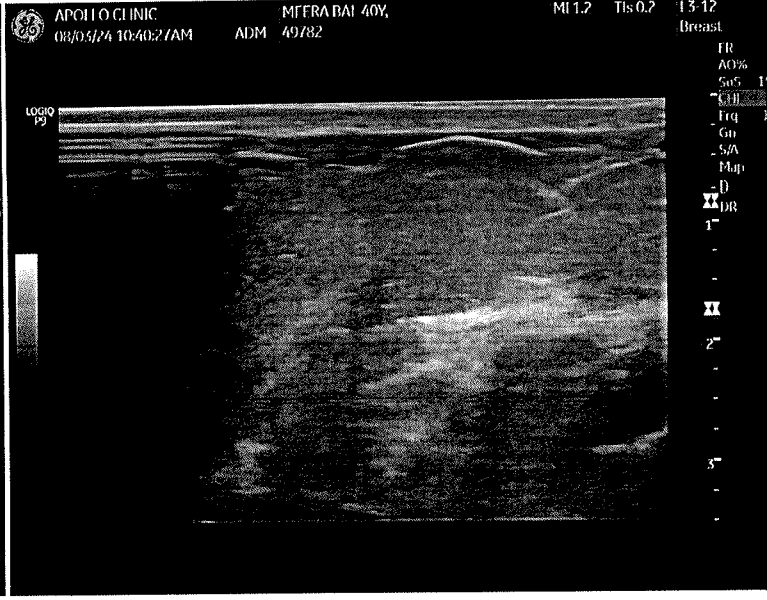
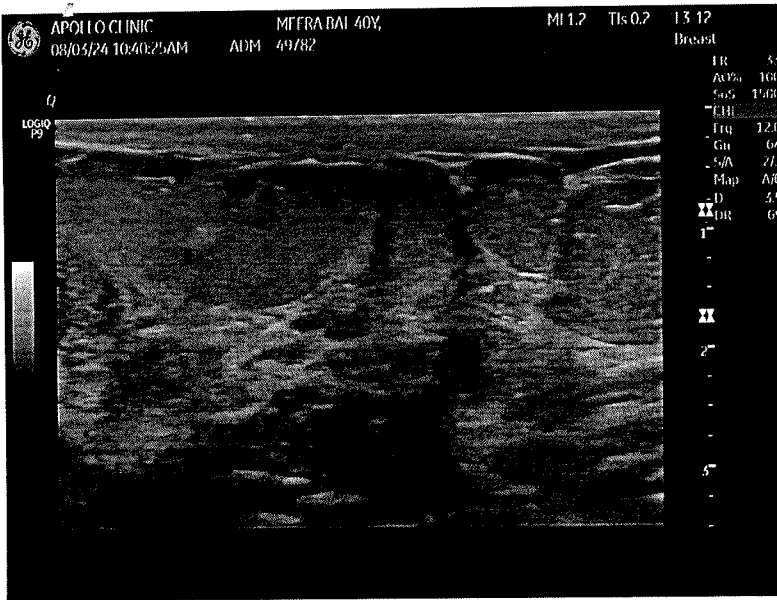
APOLLO CLINICS NETWORK KARNATAKA

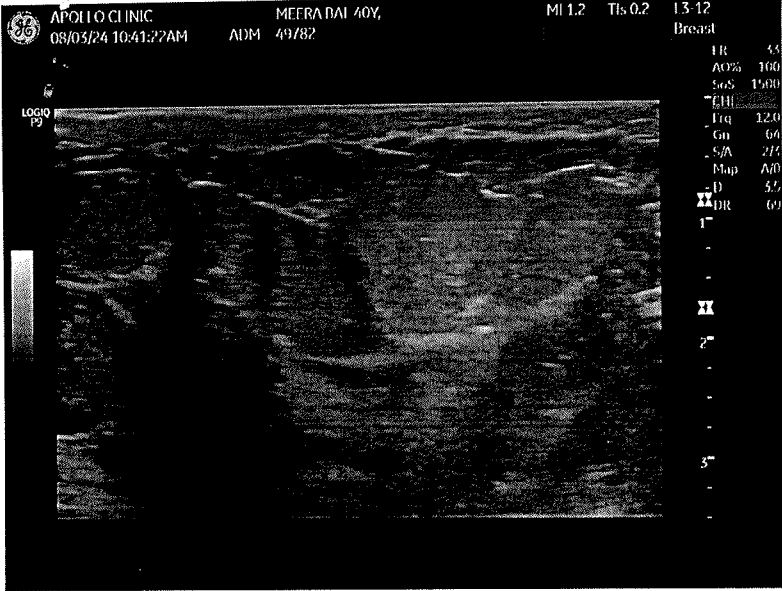Bangalore (Basavanagudi | Bellandur | Electronic City | Fraser Town | HSR Layout | Indira Nagar | JP Nagar | Kundalahalli | Koramangala | Sarjapur Road) **Mysore** (VV Mohalla)

Online appointments: www.apolloclinic.com

TO BOOK AN APPOINTMENT

 **1860 500 7788**





NAME:	<i>Mrs. MEERA BAI</i>
AGE / SEX:	40 YRS/ FEMALE
DATE:	08/03/2024
REFERRED BY:	<i>ARCOFEMI</i>

ABDOMINAL ULTRASONOGRAPHY REPORT

LIVER: Appear normal in size and echogenicity. No focal lesion seen. The intra hepatic biliary and portal venous radicals are normal. Portal vein and CBD is normal.

GALL BLADDER: moderately distended and appears normal. No abnormal wall thickening / pericholecystic fluid seen.

Pancreas: normal to the extend visualized.

SPLEEN: Normal in size and echo texture. No focal lesion noted

KIDNEYS: Both kidneys are normal in position, size and echo texture. Normal cortico-medullary differentiation is maintained. No calculus/ hydronephrosis on both sides.

PELVIC ORGANS:

Urinary bladder well distended and appears normal in size, contour and wall thickness.

Uterus appear normal in size and echo texture . Myometrial echoes appear normal.
ET measures ~ 8.5 mm.

Bilateral ovaries are normal in size, shape and echo texture.

No free fluid in the abdomen and pelvis.

IMPRESSION:

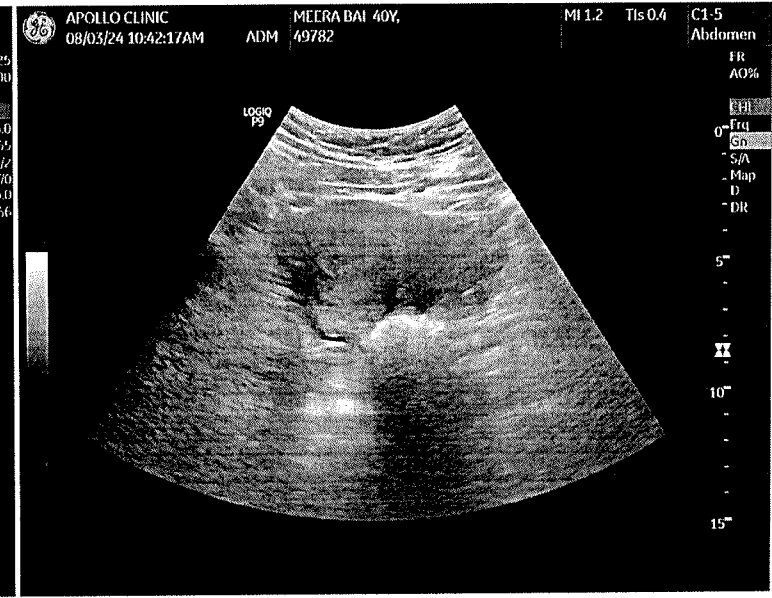
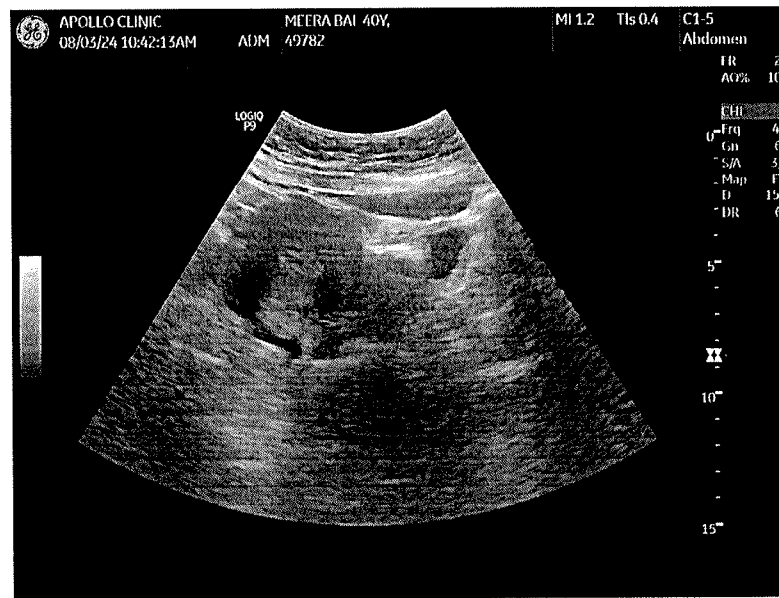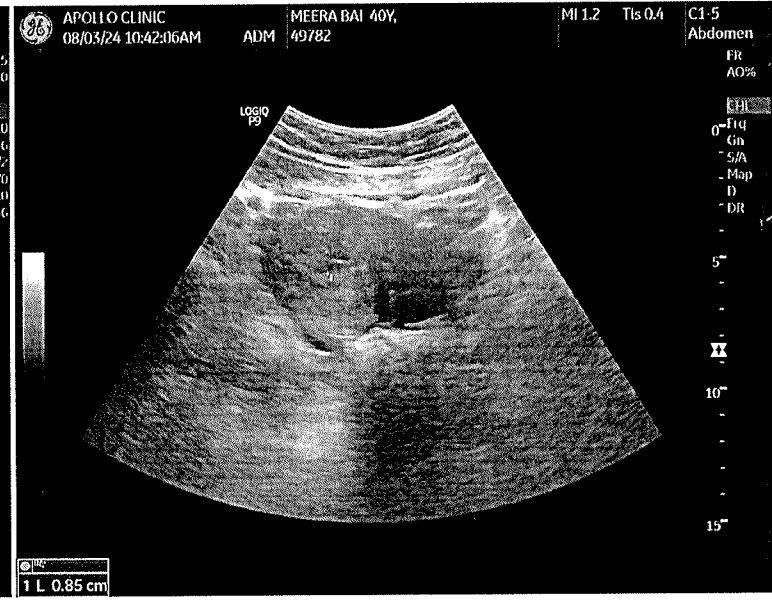
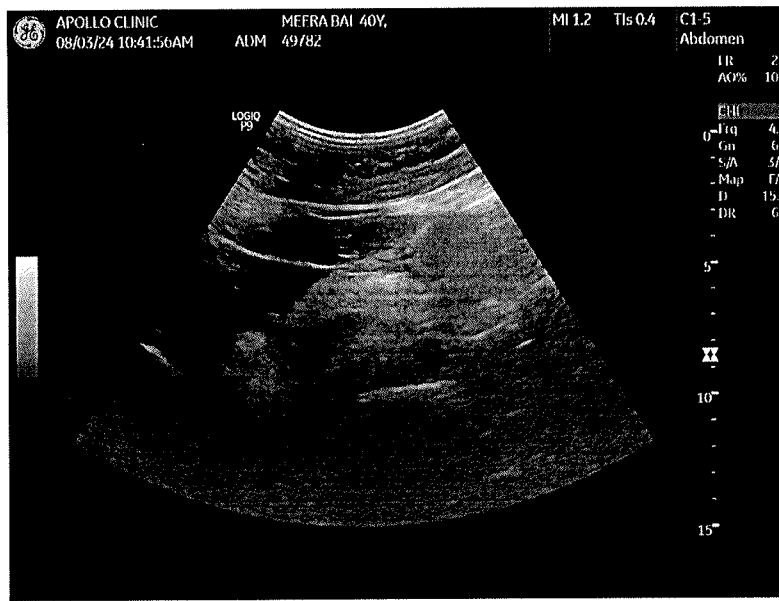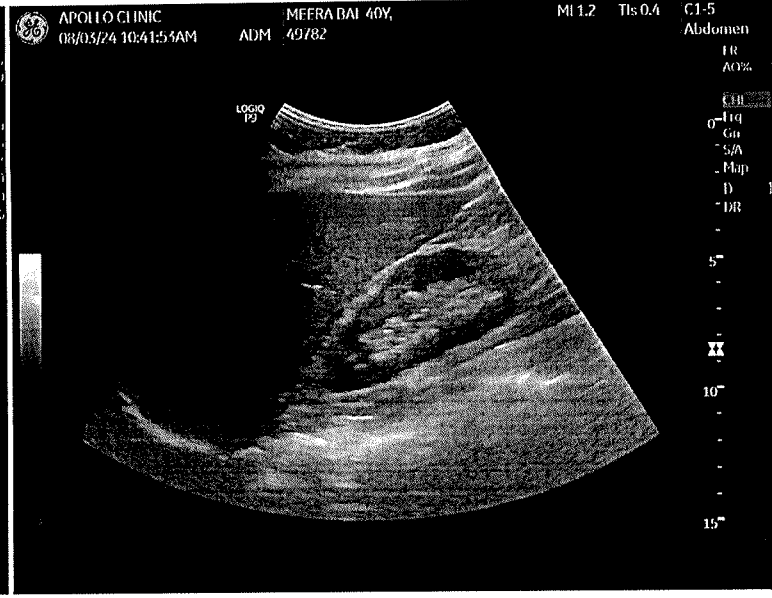
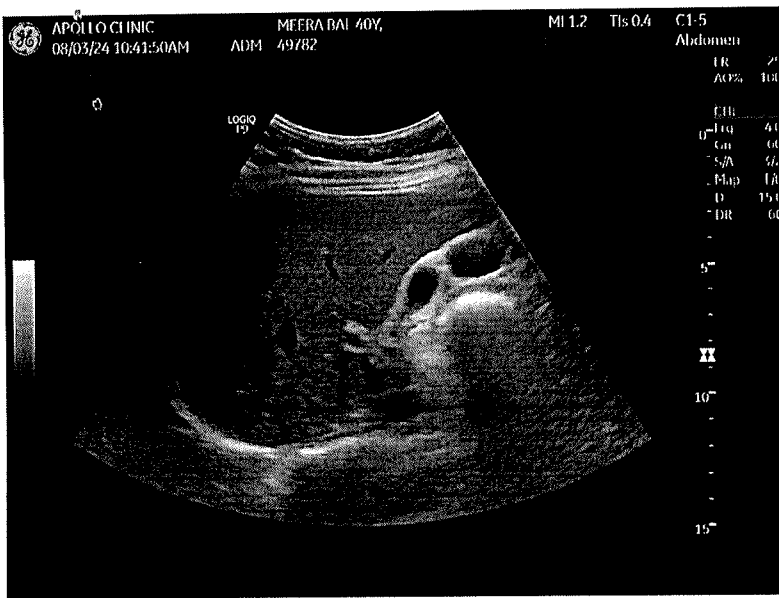
- ***No definitive sonological abnormality detected in present scan .***

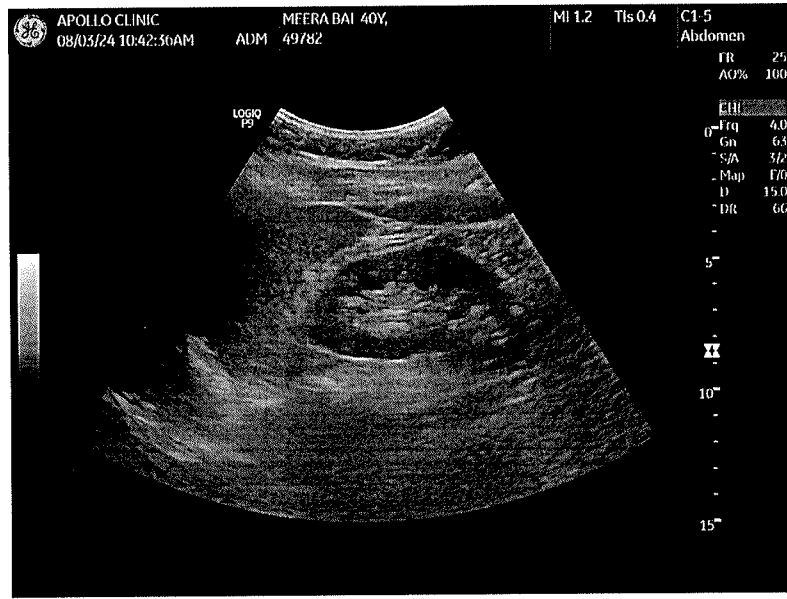
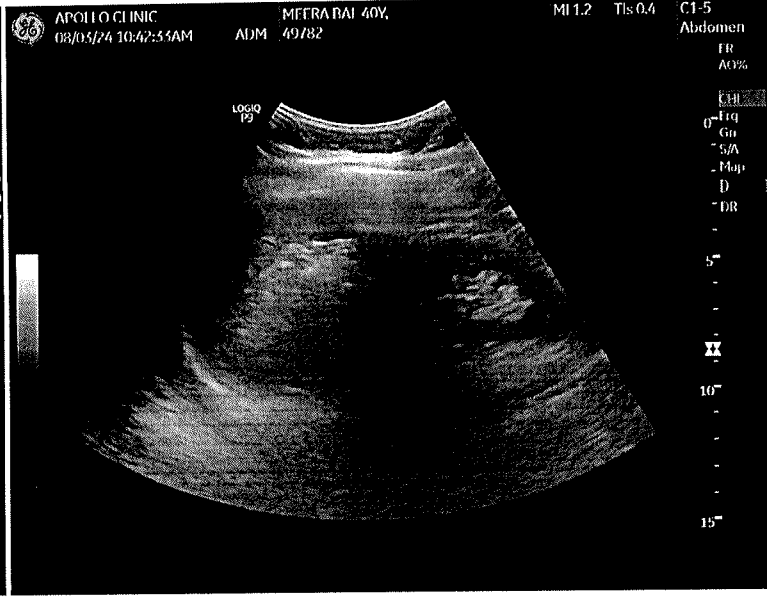
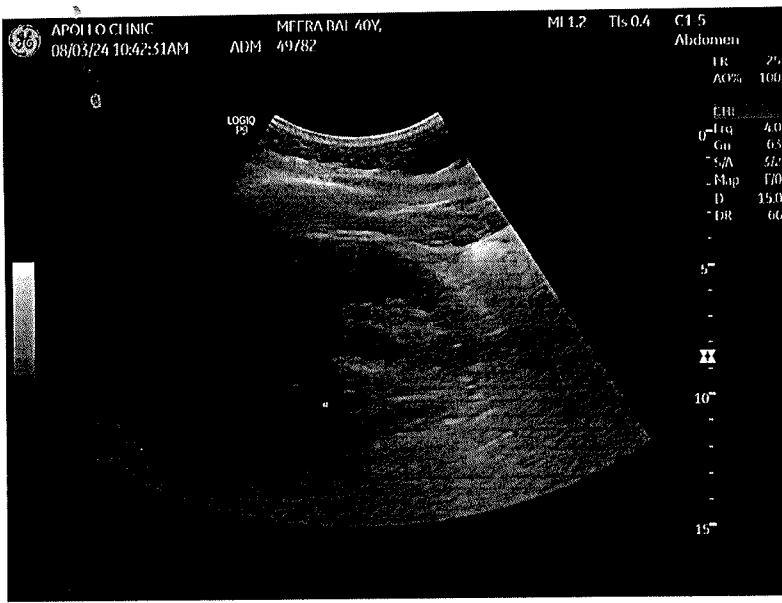
*To correlate clinically & with other investigations.
Not for medico-legal purpose*



DR. VIGNESH K

CONSULTANT RADIOLOGIST





2-D ECHO-CARDIOGRAPHY DOPPLER & COLOUR DOPPLER REPORT

NAME : MR MEERA BAI

DATE:08/03/2024

AGE/SEX: 40 Y/ F

REF : ARCOFEMI – MEDIWHEEL

UHID:49782/03/39

***** MEASUREMENTS & FLOW VELOCITIES AS DEPICTED IN IMAGES OVERLEAF.**

1. NORMAL VALVES.
2. NORMAL FLOW ACROSS ALL VALVES.
3. NO MR/ AR/ TR.
4. NORMAL GREAT VESSELS.
5. NORMAL SYSTEMIC VEINS & AT LEAST 3 PULMONARY VEINS SEEN DRAINING INTO LA.
6. NORMAL SIZED CHAMBERS.
7. NO REGIONAL WALL MOTION ABNORMALITIES.
8. INTACT SEPTAE (IVS & IAS).
9. GOOD LV & RV SYSTOLIC FUNCTION.
10. PERICARDIUM : NORMAL
11. NO OBVIOUS VEGETATION / CLOTS.



DR (CAPT.)S.V KRISHNA RAO

MD (PGI), DNB (Card)

Senior Consultant – Cardiologist

Reg No : ANP 19780000746KTK

To correlate with clinical findings & other relevant investigations .

Apollo Health and Lifestyle Limited

(CIN - U85110TG2000PLC115819)

Regd. Office: 1-10-60/62, Ashoka Raghupathi Chambers, 5th Floor, Begumpet, Hyderabad, Telangana - 500 016.


Ph No: 040-4904 7777, Fax No: 4904 7744 | Email ID: enquiry@apollohl.com | www.apollohl.com

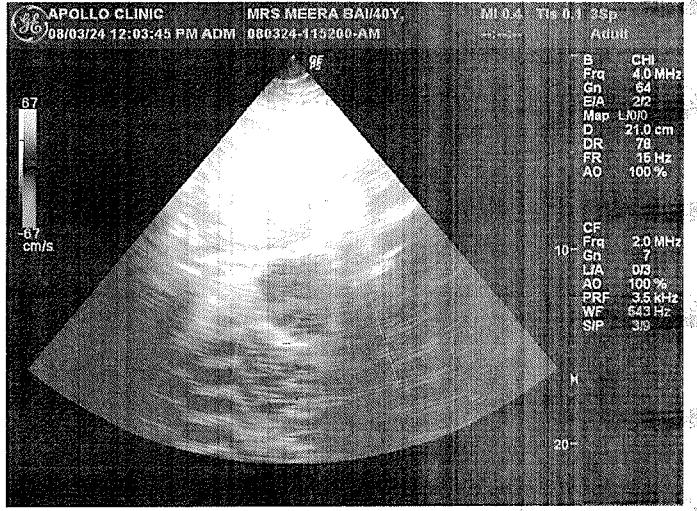
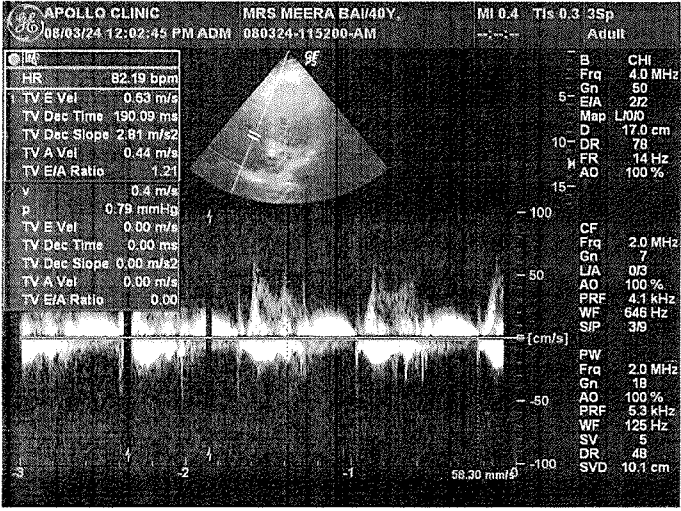
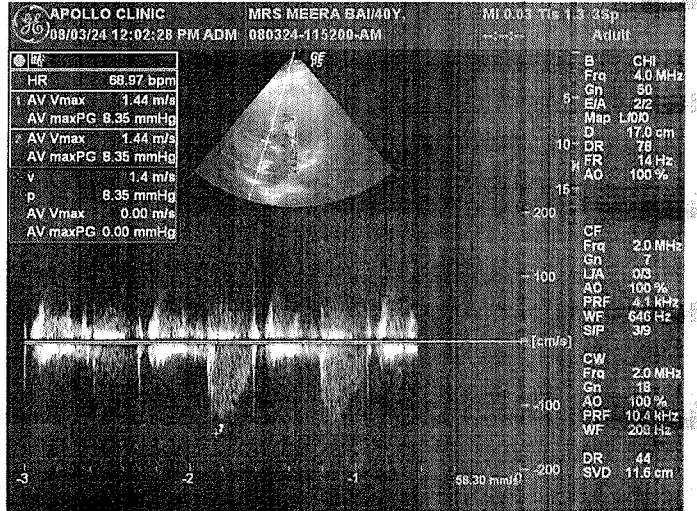
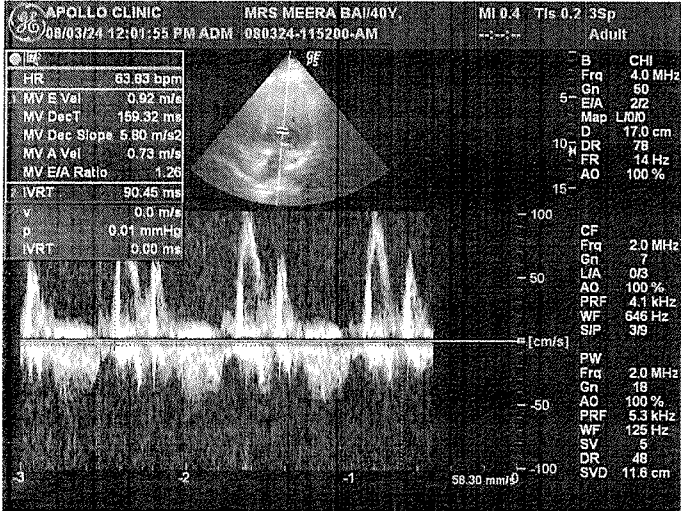
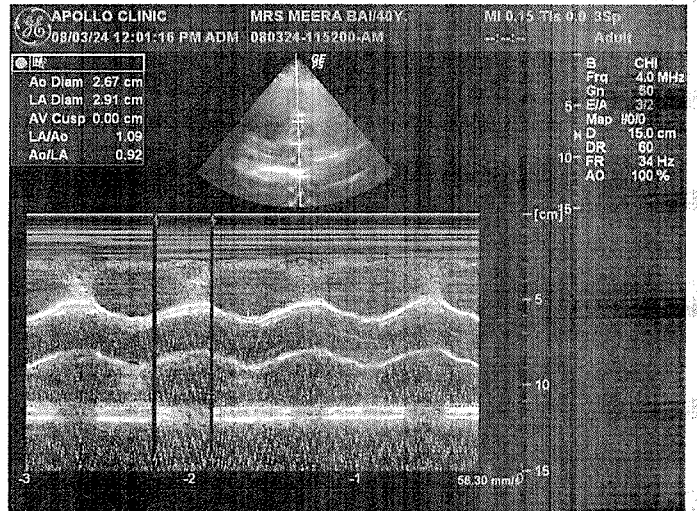
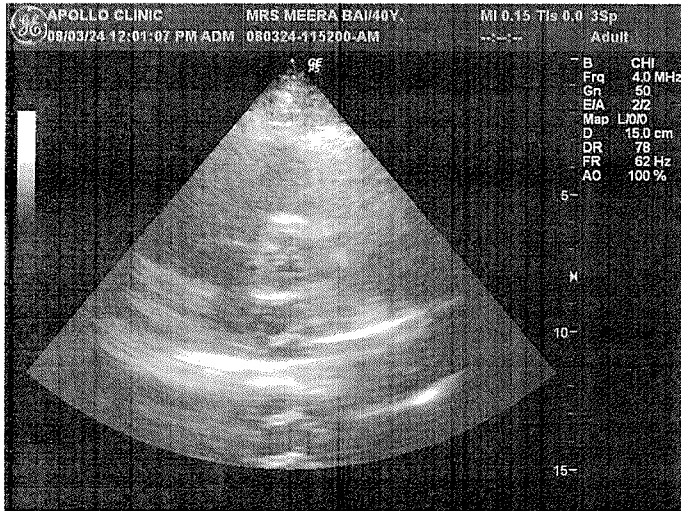
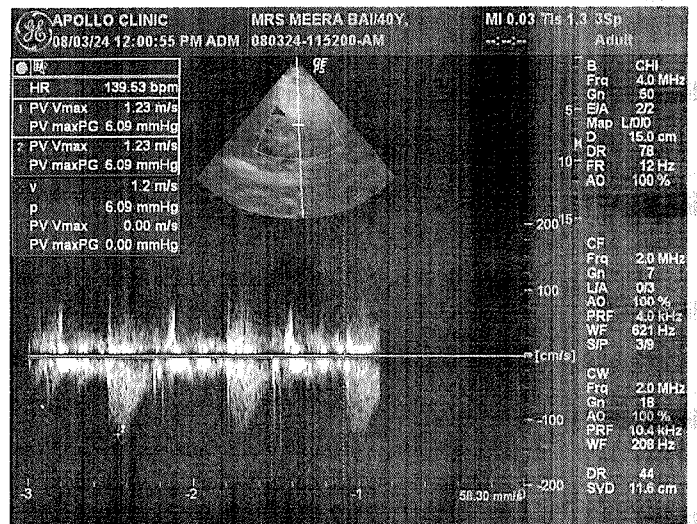
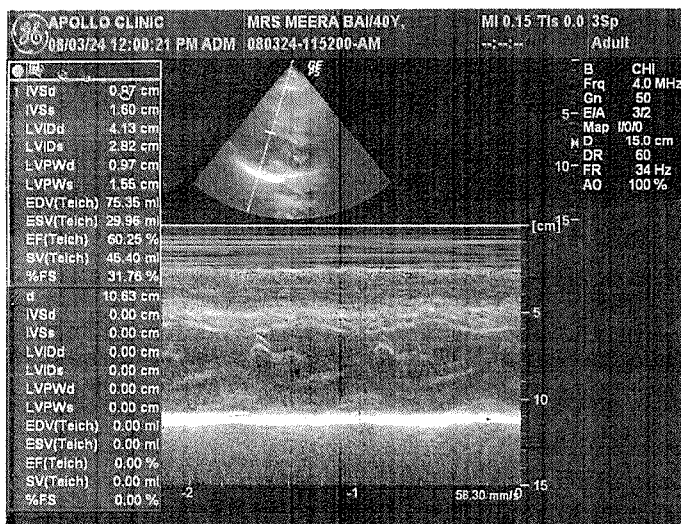
APOLLO CLINICS NETWORK KARNATAKA

Bangalore (Basavanagudi | Bellandur | Electronic City | Fraser Town | HSR Layout | Indira Nagar | JP Nagar | Kundalahalli | Koramangala | Sarjapur Road) **Mysore** (VV Mohalla)

Online appointments: www.apolloclinic.com

TO BOOK AN APPOINTMENT

 **1860 500 7788**





Apollo Clinic

Consent Form

Patient Name: Meera Bai Age: 40 yrs

UHID Number: 49783 Company Name: Arcofemi

I Mr/Mrs/Ms. Meera Bai Employee of Arcofemi

(Company) want to inform you that I am not getting the Dental, Gynaecology and diet
test done which is a part of routine health check package. and Opthal and ENT

Reason if any: Doctor not available

And I claim the above statement in my full consciousness.

Patient signature: Meera Bai Date: 08/3/2024

Apollo Clinic

CONSENT FORM

Patient Name: ms. Meera Bai Age: 40 y/f

UHID Number: 49782 Company Name: Ascobene-Mediwheel.


I Mr/Mrs/Ms. Meera Bai Employee of B. C. B. Bank

(Company) want to inform you that I am not doing LBC Pap test procedure due to Pap test which is a part of my health package.
Bgubli is not available

And I claim the above statement in my full consciousness.

Patient Signature: Meera Bai

Date: 08/03/24



LETTER OF APPROVAL / RECOMMENDATION

To,

The Coordinator,
Mediwheel (Arcofemi Healthcare Limited)
Helpline number: 011- 41195959

Dear Sir / Madam,

Sub: Annual Health Checkup for the employees of Bank of Baroda

This is to inform you that the following employee wishes to avail the facility of Cashless Annual Health Checkup provided by you in terms of our agreement.

PARTICULARS	EMPLOYEE DETAILS
NAME	MS. BAI MEERA
EC NO.	173370
DESIGNATION	SWACHHTA SAHAYAK EVAM SAHAYAK
PLACE OF WORK	BANGALORE,ELECTRONIC CITY GENN
BIRTHDATE	04-07-1983
PROPOSED DATE OF HEALTH CHECKUP	08-03-2024
BOOKING REFERENCE NO.	23M173370100096284E

This letter of approval / recommendation is valid if submitted along with copy of the Bank of Baroda employee id card. This approval is valid from **04-03-2024** till **31-03-2024** The list of medical tests to be conducted is provided in the annexure to this letter. Please note that the said health checkup is a **cashless facility** as per our tie up arrangement. We request you to attend to the health checkup requirement of our employee and accord your top priority and best resources in this regard. The EC Number and the booking reference number as given in the above table shall be mentioned in the invoice, invariably.

We solicit your co-operation in this regard.

Yours faithfully,

Sd/-

Chief General Manager
HRM Department
Bank of Baroda

(Note: This is a computer generated letter. No Signature required. For any clarification, please contact Mediwheel (Arcofemi Healthcare Limited))

SUGGESTIVE LIST OF MEDICAL TESTS

FOR MALE	FOR FEMALE
CBC	CBC
ESR	ESR
Blood Group & RH Factor	Blood Group & RH Factor
Blood and Urine Sugar Fasting	Blood and Urine Sugar Fasting
Blood and Urine Sugar PP	Blood and Urine Sugar PP
Stool Routine	Stool Routine
Lipid Profile	Lipid Profile
Total Cholesterol	Total Cholesterol
HDL	HDL
LDL	LDL
VLDL	VLDL
Triglycerides	Triglycerides
HDL / LDL ratio	HDL / LDL ratio
Liver Profile	Liver Profile
AST	AST
ALT	ALT
GGT	GGT
Bilirubin (total, direct, indirect)	Bilirubin (total, direct, indirect)
ALP	ALP
Proteins (T, Albumin, Globulin)	Proteins (T, Albumin, Globulin)
Kidney Profile	Kidney Profile
Serum creatinine	Serum creatinine
Blood Urea Nitrogen	Blood Urea Nitrogen
Uric Acid	Uric Acid
HBA1C	HBA1C
Routine urine analysis	Routine urine analysis
USG Whole Abdomen	USG Whole Abdomen
General Tests	General Tests
X Ray Chest	X Ray Chest
ECG	ECG
2D/3D ECHO / TMT	2D/3D ECHO / TMT
Stress Test	Thyroid Profile (T3, T4, TSH)
PSA Male (above 40 years)	Mammography (above 40 years) and Pap Smear (above 30 years).
Thyroid Profile (T3, T4, TSH)	Dental Check-up consultation
Dental Check-up consultation	Physician Consultation
Physician Consultation	Eye Check-up consultation
Eye Check-up consultation	Skin/ENT consultation
Skin/ENT consultation	Gynaec Consultation



Department of Revenue

Name


Moore Dal

R.O. No.

173370



without signature
Issuing Authority



Receipt

Signature of Holder