



भारत सरकार  
GOVERNMENT OF INDIA



अर्चना अग्रवाल  
Archana Aggarwal  
जन्म तिथि/DOB: 01/12/1975  
लिंग/ GENDER: FEMALE

2803 3800 4343  
VID: 9132 0010 3491 8320



मेरा आधार, मेरी पहचान

*Handwritten signature*

*Handwritten signature*  
DR. NITIN AGARWAL

P.O. Box No. 1947  
Bangalore-560 08

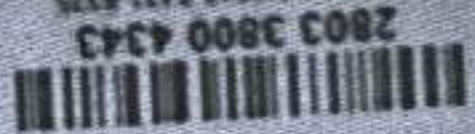
www.uidai.gov.in

help@uidai.gov.in



1947  
1800 300 1947

UIDAI  
UID: 9132 0010 3491 8320



2803 3800 4343

Address:  
C/O Manoj Kumar, C-7/152-153, Pocket C-7,  
Rohini Sector-7, North West Delhi,  
Delhi - 110085

C/O मनीष कुमार, C-7/152-153, पॉकेट सी-7, रोहिणी  
सेक्टर-7, उत्तर पश्चिम दिल्ली,  
दिल्ली - 110085



भारत सरकार  
GOVERNMENT OF INDIA

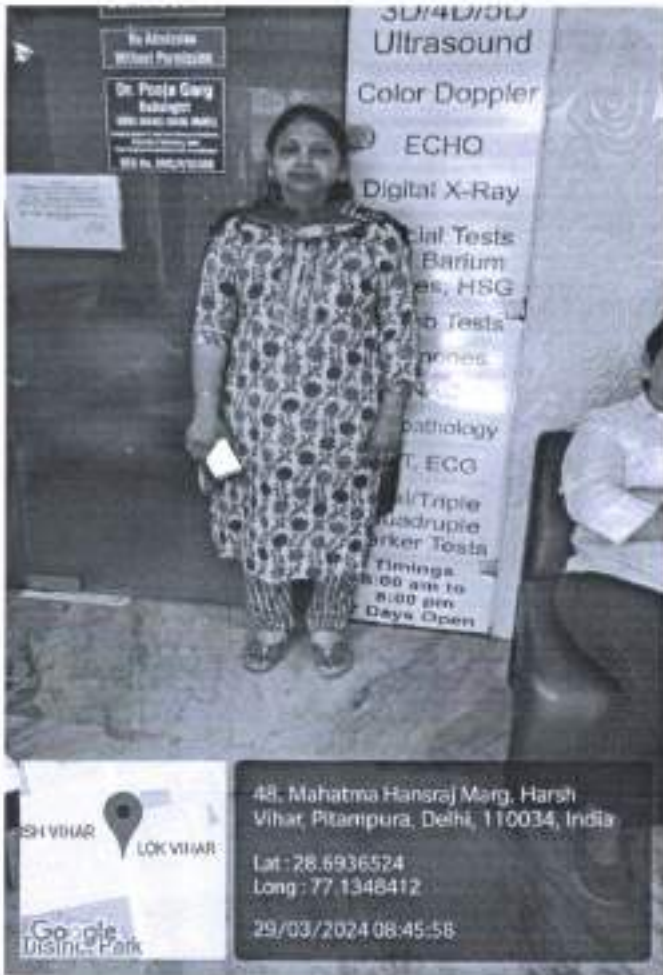

ONEPLUS ULTRASOUND 5G  
47 - Harsh Vihar, Pitam Pura,  
Delhi-110034  
1596166955  
E-mail: oneplusindia@gmail.com

11/11/11  
11/11/11

11/11/11  
11/11/11

11/11/11  
11/11/11



*Aschaw*

  
DR. NEERAJ KUMAR  
MBBS, MD  
Regn. No. DMC-R-1485

ONEPLUS ULTRASOUND LAB  
47 Harsh Vihar, Pitam Pura,  
Delhi-110034  
Ph. 011-42480101, 9599913051  
E-mail: oneplusul@gmail.com



**OnePLUS**  
Ultrasound Lab  
— QUALITY FIRST... ALWAYS! —

**Dr. Nitin Agarwal**

Pathologist & Director  
MBBS, MD, FAGE  
Ex. Chief of Lab  
Dr. Lal Path labs.

**Dr. Pooja (Garg) Agarwal**

Radiologist & Director  
MBBS (MAMC) DMRD (MAMC)  
Imaging Expert In Fetal And Maternal Medicine,  
University of Barcelona, Spain  
Fetal Medicine Foundation (UK) Accreditation

To

I. archana Agarwal has come to one plus lab  
for health check up on 29/3/2024. I will give stool  
& BSPP samples tomorrow i.e. on 30/3/2024

*Archana*

Dr. Nitin Agarwal  
MBBS, MD  
Regd. No. DMC-1085

47, Harsh Vihar, Pitampura, Delhi-34 ☎ 011-4248 0101, 9599913051

✉ Email: [oneplusul@gmail.com](mailto:oneplusul@gmail.com) 🌐 [www.oneplusul.in](http://www.oneplusul.in)

- Clinical correlation is essential for final diagnosis. • If test results are unsatisfactory please contact personally or on phone.
- This report is for perusal of doctors only. • All disputes are subject to Delhi jurisdiction only. • Not for medico legal case.
- All congenital anomalies in a foetus may not be diagnosed in routine obstetric ultrasound.



Name	: Mrs. ARCHANA AGGARWAL	Age/Sex	: 48 YRS/Female
Ref. By	: Dr. MEDIWHEEL	Lab No	: 012403290007
Date	: 29-Mar-2024	Patient ID	: LSHHI132869

### ULTRASOUND EXAMINATION---WHOLE ABDOMEN

**Liver** is normal in size (13.9 cm) and normal in outline with altered echopattern. Diffuse increase in echogenicity of liver parenchyma is noted, suggestive of fatty infiltration (grade I). No abscess or mass lesion seen. Hepatic veins, portal vein, IVC and aorta are normal. Intrahepatic biliary radicles are not dilated. CBD is normal in caliber.

**Gall bladder** is not seen (Post op).

**Both kidneys** are normal in size, shape, position, outline and echopattern. Corticomedullary differentiation is maintained. No pelvicalyceal dilation or calculus or mass lesion is seen.

**Spleen** is normal in size (7.7 cm) and echotexture. No mass lesion seen.

**Pancreas** is normal in size, outline and echotexture .

**Urinary bladder** is normal in shape and position. No evidence of intravesical stone or mass seen.

**Uterus** is normal in size (measures 7.5 x 4.6 x 3.8 cm), shape, position and echopattern. No mass seen.

**Uterine cavity** is empty. **Endometrial thickness** is 6.7 mm.

**Both ovaries** appear normal in size, shape and echopattern. No tubo-ovarian mass seen.

No abnormal bowel wall thickening seen in right iliac fossa.

No free fluid seen anywhere in abdomen.

**IMPRESSION: Fatty infiltration of liver (grade I) with no hepatomegaly.**

Dr. RASHMI BANSAL

Radiologist

Reg. No. DMC/R/10067

DR. RASHMI BANSAL

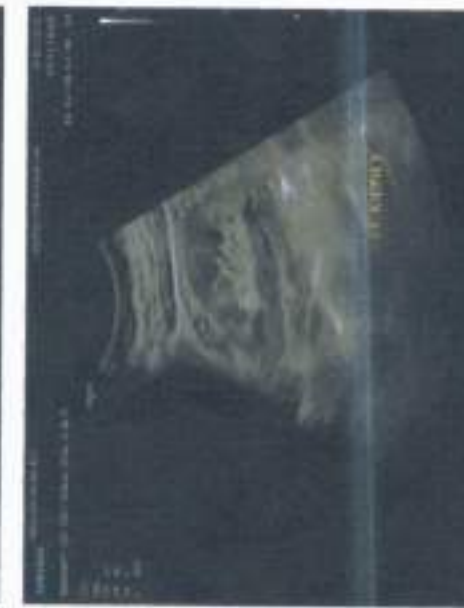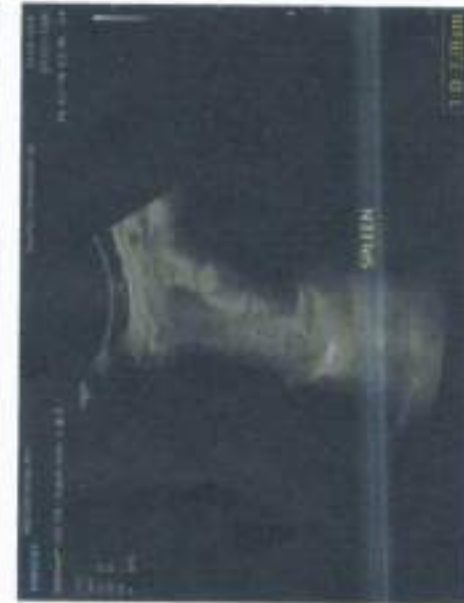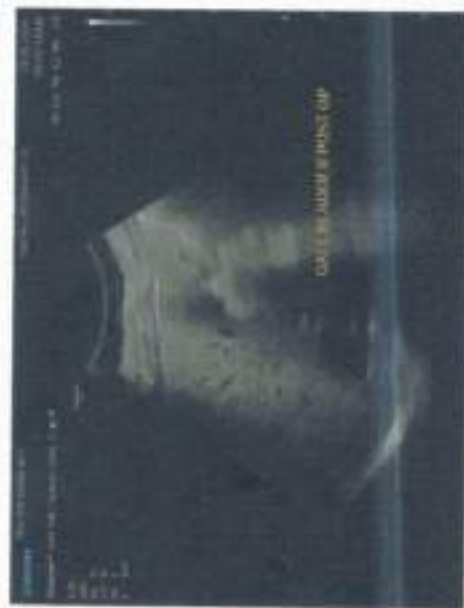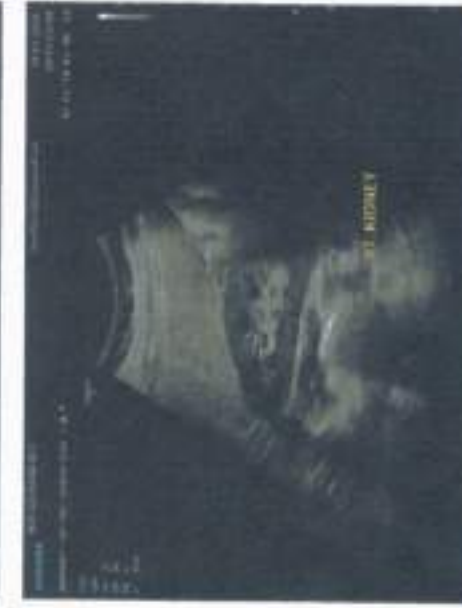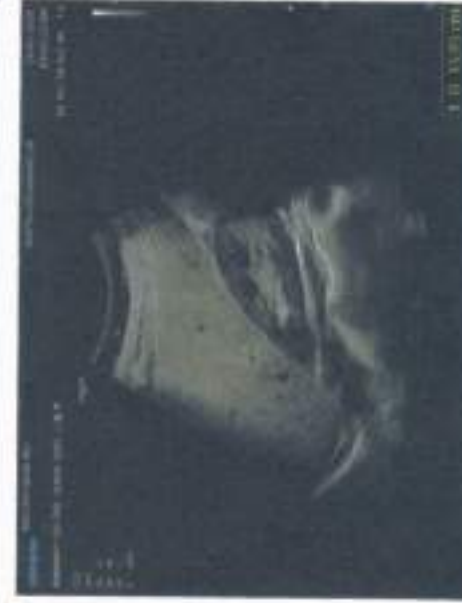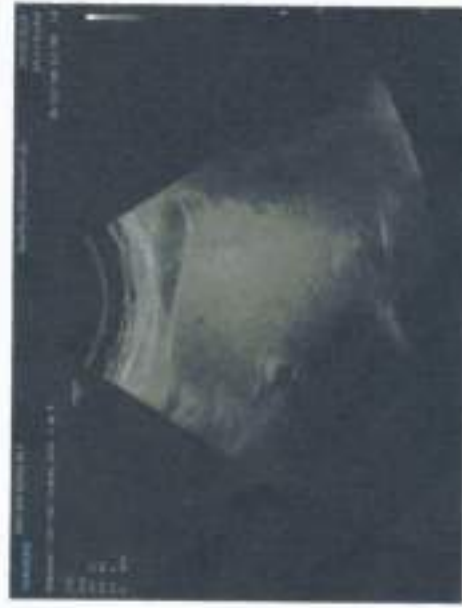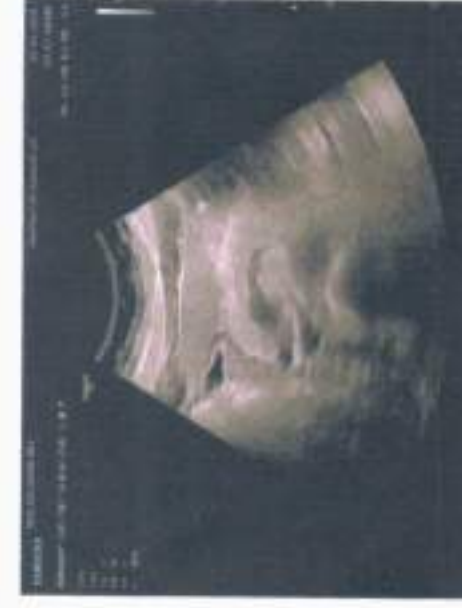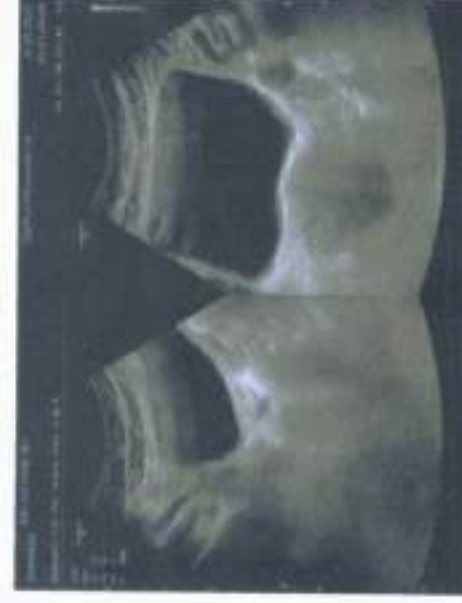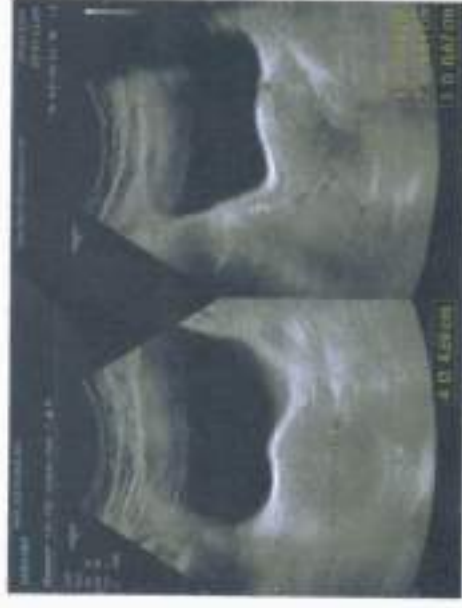RADIOLOGIST

REG. NO. DMC/R/10067

Type By : anubha

47, Harsh Vihar, Pitampura, Delhi-34 ☎ 011-4248 0101, 9599913051

✉ Email: oneplusul@gmail.com 🌐 www.oneplusul.in





NAME	:Mrs. ARCHANA AGGARWAL	Barcode No	:10168248
AGE/GENDER	:48 YRS/Female	SPECIMEN DATE	:29/Mar/2024 08:39AM
PATIENT ID	:132869	SPECIMEN RECEIVED	:29/Mar/2024 08:59AM
REFERRED BY	:Dr. MEDIWHEEL	REPORT DATE	:29/Mar/2024 03:01PM
CENTRE NAME	:ONEPLUS ULTRASOUND LAB	LAB NO.	:012403290007

Test Name	Result	Unit	Ref. Range
-----------	--------	------	------------

**HAEMATOLOGY**

**MediWheel Health Checkup >40 Female**

Sample Type:EDTA Blood

<b>ESR</b>	10	mm in 1st hr	upto 13.6
------------	----	--------------	-----------

Modified Westergrens Method

**Comments:**

**Increased**

- In most infections, anaemias, injection of foreign proteins, auto-immune disorders, conditions accompanied by hyperglobunemia and hypercholesterolaemia.
- A rising ESR suggests a progressive disease.

**Decreased**

- In polycythemia, congestive heart failure.

<b>Glycosylated Hemoglobin (HbA1c)</b>	6.0	%	Non Diabetic adults <5.7 Prediabetic (at risk) 5.7-6.4 Diabetes >6.4
--	-----	---	--

HPLC

<b>Estimated average blood glucose (eag)</b>	126
--	-----

CALCULATED

Reference range (mg/dl):


90 - 120:Excellent control, 121 - 150:Good Control, 151 - 180:Average Control, 181 - 210:Action Suggested

>211:Panix value

**Dr. NITIN AGARWAL**

MBBS, MD

Regn. No. DMC-R-1436



DR. NITIN AGARWAL  
MBBS,MD(PATHOLOGIST)

Checked By.

47, Harsh Vihar, Pitampura, Delhi-34 ☎ 011-4248 0101, 9599913051

✉ Email: [oneplusul@gmail.com](mailto:oneplusul@gmail.com) 🌐 [www.oneplusul.in](http://www.oneplusul.in)

Page 1 of 9





**OnePLUS**  
Ultrasound Lab  
— QUALITY FIRST... ALWAYS! —

**Dr. Nitin Agarwal**

Pathologist & Director  
MBBS, MD, FAGE  
Ex. Chief of Lab  
Dr. Lal Path labs.

**Dr. Pooja (Garg) Agarwal**

Radiologist & Director  
MBBS (MAMC) DMRD (MAMC)  
Imaging Expert In Fetal And Maternal Medicine,  
University of Barcelona, Spain  
Fetal Medicine Foundation (UK) Accreditation



NAME	:Mrs. ARCHANA AGGARWAL	Barcode No	:10168248
AGE/GENDER	:48 YRS/Female	SPECIMEN DATE	:29/Mar/2024 08:39AM
PATIENT ID	:132869	SPECIMEN RECEIVED	:29/Mar/2024 08:59AM
REFERRED BY	:Dr. MEDIWHEEL	REPORT DATE	:29/Mar/2024 03:01PM
CENTRE NAME	:ONEPLUS ULTRASOUND LAB	LAB NO.	:012403290007

Test Name	Result	Unit	Ref. Range
-----------	--------	------	------------

**HAEMATOLOGY**

**BLOOD GROUP (ABO)**

Forward and Reverse grouping (Slide & Tube)

A

**Rh typing**

POSITIVE

**NOTE :**

- \* Apart from major A,B,H antigens which are used for ABO grouping and Rh typing, many minor blood group antigens exist. Agglutination may also vary according to titre of antigen and antibody.
- \* So before transfusion, reconfirmation of blood group as well as cross-matching is needed.
- \* Presence of maternal antibodies in newborns, may interfere with blood grouping.
- \* Auto agglutination (due to cold antibody, falciparum malaria, sepsis, internal malignancy etc.) may also cause erroneous result.

Checked By.

**Dr. NITIN AGARWAL**

MP + MD

Regn. No. DMDA: 1436

DR. NITIN AGARWAL  
MBBS,MD(PATHOLOGIST)

47, Harsh Vihar, Pitampura, Delhi-34 ☎ 011-4248 0101, 9599913051

✉ Email: [oneplusul@gmail.com](mailto:oneplusul@gmail.com) 🌐 [www.oneplusul.in](http://www.oneplusul.in)

Page 2 of 9

- \* Clinical correlation is essential for final diagnosis. \* If test results are unsatisfactory please contact personally or on phone.
- \* This report is for perusal of doctors only. \* All disputes are subject to Delhi jurisdiction only. \* Not for medico legal case.
- \* All congenital anomalies in a foetus may not be diagnosed in routine obstetric ultrasound.



NAME	:Mrs. ARCHANA AGGARWAL	Barcode No	:10168248
AGE/GENDER	:48 YRS/Female	SPECIMEN DATE	:29/Mar/2024 08:39AM
PATIENT ID	:132869	SPECIMEN RECEIVED	:29/Mar/2024 08:59AM
REFERRED BY	:Dr. MEDIWHEEL	REPORT DATE	:29/Mar/2024 03:01PM
CENTRE NAME	:ONEPLUS ULTRASOUND LAB	LAB NO.	:012403290007

Test Name	Result	Unit	Ref. Range
<b>HAEMATOLOGY</b>			
<b>CBC</b>			
Haemoglobin Non cyanide Hb analysis	12.5	g/dl	12.0-15.0
Total Leucocyte Count Electrical Impedance	6900	/cumm	4000-10000
<b>Differential leucocyte count</b>			
Neutrophils Electrical Impedance & Microscopic	67.3	%	40-80
Lymphocyte Electrical Impedance & Microscopic	27.90	%	20-40
Monocytes Electrical Impedance & Microscopic	2.00	%	2-10
Eosinophils Electrical Impedance & Microscopic	2.0	%	1-6
Basophils Electrical Impedance & Microscopic	0.8	%	0-2
RBC Count Electrical Impedance	4.30	million/cumm	4.5 - 5.5
Hematocrit(PCV) Flow Cytometry	38.8	%	36-46
MCV Calculated	89.9	f	83-101
MCH Calculated	28.9	pg	27-32
MCHC Calculated	32.1	g/dL	31.5-34.5
RDW-CV Calculated	13.5	%	11.4-14.0
Platelet count Electrical Impedance	179000	/cumm	150000-410000

**BIOCHEMISTRY**

Sample Type:Fluoride F

<b>Blood sugar fasting</b> GOD-POD	106	mg/dl	70-100 mg/dl
---------------------------------------	-----	-------	--------------

Checked By.

**Dr. NITIN AGARWAL**  
MPH - MD  
DR. NITIN AGARWAL, DMC-R-1436  
MBBS,MD(PATHOLOGIST)

47, Harsh Vihar, Pitampura, Delhi-34 ☎ 011-4248 0101, 9599913051

✉ Email: [oneplusul@gmail.com](mailto:oneplusul@gmail.com) 🌐 [www.oneplusul.in](http://www.oneplusul.in)

Page 3 of 9



NAME	:Mrs. ARCHANA AGGARWAL	Barcode No	:10168248
AGE/GENDER	:48 YRS/Female	SPECIMEN DATE	:29/Mar/2024 08:39AM
PATIENT ID	:132869	SPECIMEN RECEIVED	:29/Mar/2024 08:59AM
REFERRED BY	:Dr. MEDIWHEEL	REPORT DATE	:29/Mar/2024 03:01 PM
CENTRE NAME	:ONEPLUS ULTRASOUND LAB	LAB NO.	:012403290007

Test Name	Result	Unit	Ref. Range
<b>Sample Type:Fluoride PP</b>			
<b>Blood sugar pp</b> GOD-POD	96	mg/dL	70.0-140.0
<b>Sample Type:Serum</b>			
<b>Bun (blood urea nitrogen)</b> Calculated	9.30	mg/dl	8.9-21.6
<b>Uric Acid, serum</b> Uricase- PAP	4.6	mg/dl	3.5-7.2
<b>Creatinine, serum</b> Enzymatic	0.6	mg/dl	0.71-1.16
<b>LFT(LIVER FUNCTION TEST)</b>			
Bilirubin Total Modified tab	0.54	mg/dl	0.1-0.9
Bilirubin Conjugated Diazotised sulfanilic acid	0.21	mg/dl	0-0.4
Bilirubin Unconjugated Calculated	0.33	mg/dl	up to 0.7
SGOT (AST) Tris buffer	28	U/L	0-46
SGPT (ALT) Tris buffer	40	U/L	0-49
Alkaline phosphatase Amp buffer	96	U/L	40-129
GAMMA GT Szasz Method	26	U/L	10-45
Total Protein Buret	7.6	gm/dl	6.60 - 8.70
Albumin serum BCG	4.5	g/dL	3.0-5.2
Globulin Calculated	3.10	gm/dl	1.8-3.4
Albumin/Globulin Ratio Calculated	1.45		1.10 - 2.50
<b>LIPID PROFILE</b>			
Cholesterol CHOD-PAP	241	mg/dl	50-200

Checked By.

**Dr. NITIN AGARWAL**  
MBBS, MD  
DR. NITIN AGARWAL  
Registration No. DMC-R-1436  
MBBS, MD (PATHOLOGIST)

47, Harsh Vihar, Pitampura, Delhi-34 ☎ 011-4248 0101, 9599913051

✉ Email: [oneplusul@gmail.com](mailto:oneplusul@gmail.com) 🌐 [www.oneplusul.in](http://www.oneplusul.in)

Page 4 of 9

• Clinical correlation is essential for final diagnosis. • If test results are unsatisfactory please contact personally or on phone.  
• This report is for perusal of doctors only. • All disputes are subject to Delhi jurisdiction only. • Not for medico legal case.  
• All congenital anomalies in a foetus may not be diagnosed in routine obstetric ultrasound.



NAME	:Mrs. ARCHANA AGGARWAL	Barcode No	:10168248
AGE/GENDER	:48 YRS/Female	SPECIMEN DATE	:29/Mar/2024 08:39AM
PATIENT ID	:132869	SPECIMEN RECEIVED	:29/Mar/2024 08:59AM
REFERRED BY	:Dr. MEDIWHEEL	REPORT DATE	:29/Mar/2024 03:01PM
CENTRE NAME	:ONEPLUS ULTRASOUND LAB	LAB NO.	:012403290007

Test Name	Result	Unit	Ref. Range
Triglycerides GPO-PAP	169	mg/dL	25-150
HDL Cholesterol Selective Inhibition	48	mg/dL	40 - 60
LDL cholesterol Calculated	159	mg/dL	<130
VLDL cholesterol Calculated	33.8	mg/dL	5-40
Cholesterol/HDL Ratio Calculated	5.0		Low Risk 3.3-4.97 Average Risk 4.4-7.1 Moderate Risk 7.1-11.0 High Risk >11.0
LDL/HDL Ratio Calculated	3.3		0 - 3.55

LDL Cholesterol	Total Cholesterol	HDL Cholesterol
<100 Optimal	<200 Desirable	<40 Low
100-129 Near optimal	200-239 Borderline high	>60 High
130-159 Borderline high	>240 High	
160-189 High		
>190 Very high		

*According to NCEP, ATP-III Guidelines*

**BUN/Creatinine ratio**

UREA UREASE-GLDH	20.00	mg/dl	15-45
Bun (blood urea nitrogen ) Calculated	9.35	mg/dl	8.9-21.6
CREATININE ENZYMATIC	0.60	mg/dl	0.30-1.10
Bun/Creatinine Ratio Calculated	15.58		10.0 - 20.0

Checked By.

**Dr. NITIN AGGARWAL**  
MBBS, MD  
DMC-R-1436  
MBBS, MD (PATHOLOGIST)

47, Harsh Vihar, Pitampura, Delhi-34 ☎ 011-4248 0101, 9599913051

✉ Email: [oneplusul@gmail.com](mailto:oneplusul@gmail.com) 🌐 [www.oneplusul.in](http://www.oneplusul.in)

Page 5 of 9

- Clinical correlation is essential for final diagnosis. • If test results are unsatisfactory please contact personally or on phone.
- This report is for perusal of doctors only. • All disputes are subject to Delhi jurisdiction only. • Not for medico legal case.
- All congenital anomalies in a foetus may not be diagnosed in routine obstetric ultrasound.



**OnePLUS**  
Ultrasound Lab  
— QUALITY FIRST... ALWAYS! —

**Dr. Nitin Agarwal**

Pathologist & Director  
MBBS, MD, FAGE  
Ex. Chief of Lab  
Dr. Lal Path labs.

**Dr. Pooja (Garg) Agarwal**

Radiologist & Director  
MBBS (MAMC) DMRD (MAMC)  
Imaging Expert in Fetal And Maternal Medicine,  
University of Barcelona, Spain  
Fetal Medicine Foundation (UK) Accreditation



NAME	:Mrs. ARCHANA AGGARWAL	Barcode No	:10168248
AGE/GENDER	:48 YRS/Female	SPECIMEN DATE	:29/Mar/2024 08:39AM
PATIENT ID	:132869	SPECIMEN RECEIVED	:29/Mar/2024 08:59AM
REFERRED BY	:Dr. MEDIWHEEL	REPORT DATE	:29/Mar/2024 03:01PM
CENTRE NAME	:ONEPLUS ULTRASOUND LAB	LAB NO.	:012403290007

Test Name	Result	Unit	Ref. Range
-----------	--------	------	------------

**ENDOCRINOLOGY**

**THYROID PROFILE(T3,T4,TSH)**

Triiodothyronine total [t3] ECLIA	1.00	ng/dl	0.52-1.9
Thyroxine total [t4] ECLIA	8.90	µg/dl	4.8-11.6
TSH (Thyroid Stimulating Hormone) Enzyme linked fluorescent assay	0.26	µIU/ml	0.25-5.0

**AGE WISE VARIATION IN TSH**

AGE	TSH(µIU/ml)	AGE	TSH(µIU/ml)
1-4 weeks	1.00 - 19.0	16-20 yrs	0.25 - 5.0
1-12 mths	1.70 - 9.1	21 - 80 yrs	0.25 - 5.0
1-5 yrs	0.80 - 8.2	I <sup>st</sup> trimester	0.25 - 5.0
6-10 yrs	0.25 - 5.0	II <sup>nd</sup> trimester	0.50 - 5.0
11-15 yrs	0.25 - 5.0	III <sup>rd</sup> trimester	0.4 - 6.0

**Reference ranges - Interpretation of Diagnostic tests - (Jacques Wallach)**

1. Primary hypothyroidism is accompanied by depressed serum T3 and T4 values and elevated serum TSH level.
2. Primary hyperthyroidism is accompanied by elevated serum T3 and T4 levels along with depressed TSH values.
3. Slightly elevated T3 levels may be found in pregnancy and estrogen therapy, while depressed levels may be encountered in severe illness, renal failure and during therapy with drugs like propranolol and propyl thiouracil.
4. Although elevated TSH levels are nearly always indicative of primary hypothyroidism, and may be seen in secondary thyrotoxicosis.

Checked By.

**Dr. NITIN AGARWAL**  
MD, MD

Regn. No. DMC-R-1434

DR. NITIN AGARWAL  
MBBS,MD(PATHOLOGIST)

47, Harsh Vihar, Pitampura, Delhi-34 ☎ 011-4248 0101, 9599913051

✉ Email: [oneplusul@gmail.com](mailto:oneplusul@gmail.com) 🌐 [www.oneplusul.in](http://www.oneplusul.in)

Page 6 of 9

- Clinical correlation is essential for final diagnosis. • If test results are unsatisfactory please contact personally or on phone.
- This report is for perusal of doctors only. • All disputes are subject to Delhi jurisdiction only. • Not for medico legal case.
- All congenital anomalies in a foetus may not be diagnosed in routine obstetric ultrasound.



NAME	:Mrs. ARCHANA AGGARWAL	Barcode No	:10168248
AGE/GENDER	:48 YRS/Female	SPECIMEN DATE	:29/Mar/2024 08:39AM
PATIENT ID	:132869	SPECIMEN RECEIVED	:29/Mar/2024 02:27PM
REFERRED BY	:Dr. MEDIWHEEL	REPORT DATE	:29/Mar/2024 04:35PM
CENTRE NAME	:ONEPLUS ULTRASOUND LAB	LAB NO.	:012403290007

Test Name	Result	Unit	Ref. Range
-----------	--------	------	------------

**CLINICAL PATHOLOGY**

**URINE ROUTINE (Strip/microscopy)**

Sample Type:Urine

**Physical examination**

Colour	PALE YELLOW	PALE YELLOW
Transparency	CLEAR	CLEAR
Sp.gravity	1.015	1.005-1.030
BROMOTHYMOLO BLUE		
pH	6.00	5.0-8.0
Double Indicators Test		
Reaction	ACIDIC	ACIDIC

**Chemical examination**

Urine protein	NIL	NIL
Protein Ionization		
Urine sugar	NIL	NIL
Oxidation Reaction		
Bilirubin, urine	NEGATIVE	NEGATIVE
Urobilinogen	NORMAL	NORMAL
P-Aminobenzoic Acid and Phenazopyndine Reaction		
Ketones	NEGATIVE	NEGATIVE
Acetoacetate and Dichlorobenzene Reaction		

**Microscopic examination**

Pus cells.	1-2	/HPF	1-2
Microscopy			
Epithelial cells	2-3	/HPF	0-5
Microscopy			
R.B.C.	NIL	/HPF	NIL
Microscopy			
Casts	NIL	/HPF	NIL
Microscopy			
Crystals	NIL	/HPF	NIL
Microscopy			
Bacteria	NIL	/HPF	NIL
Microscopy			

Checked By.

**Dr. NITIN AGARWAL**  
MEB S, MD  
Reg. No. DMC-R-1436  
MBBS,MD(PATHOLOGIST)

47, Harsh Vihar, Pitampura, Delhi-34 ☎ 011-4248 0101, 9599913051

✉ Email: [oneplusul@gmail.com](mailto:oneplusul@gmail.com) 🌐 [www.oneplusul.in](http://www.oneplusul.in)

Page 7 of 9



NABL  
MC - 6036

**Dr. Nitin Agarwal**

Pathologist & Director  
MBBS, MD, FAGE  
Ex. Chief of Lab  
Dr. Lal Path labs.

**Dr. Pooja (Garg) Agarwal**

Radiologist & Director  
MBBS (MAMC) DMRD (MAMC)  
Imaging Expert In Fetal And Maternal Medicine,  
University of Barcelona, Spain  
Fetal Medicine Foundation (UK) Accreditation



NAME	:Mrs. ARCHANA AGGARWAL	Barcode No	:10168248
AGE/GENDER	:48 YRS/Female	SPECIMEN DATE	:29/Mar/2024 08:39AM
PATIENT ID	:132869	SPECIMEN RECEIVED	:29/Mar/2024 02:27PM
REFERRED BY	:Dr. MEDIWHEEL	REPORT DATE	:29/Mar/2024 04:35PM
CENTRE NAME	:ONEPLUS ULTRASOUND LAB	LAB NO.	:012403290007

Test Name	Result	Unit	Ref. Range
Others.	NIL		NIL

**STOOL ROUTINE(MANUAL METHOD/MICROSCOPY)**

Sample Type:Stool

**Physical examination**

Colour	BROWNISH		Brownish
Consistency	SEMI LOOSE		Semi Formed
Blood	ABSENT		Absent
Mucus	ABSENT		Absent

**Chemical examination, stool**

pH	6.00		5.0-8.0
<small>Double Indicators Test</small>			

**Microscopic examination**

Pus cells	NIL	/HPF	10-11
<small>Microscopy</small>			
R.B.C.	NIL	/HPF	NIL
<small>Microscopy</small>			
Ova	ABSENT		NIL
<small>Microscopy</small>			
Cysts	NIL		NIL
<small>Microscopy</small>			
Bacteria	PRESENT	/HPF	NIL
<small>Microscopy</small>			
Others	NIL		

Checked By.

**Dr. NITIN AGARWAL**  
MD MD  
Regn. No. DMC-1436  
**DR. NITIN AGARWAL**  
MBBS,MD(PATHOLOGIST)

47, Harsh Vihar, Pitampura, Delhi-34 ☎ 011-4248 0101, 9599913051

✉ Email: [oneplusul@gmail.com](mailto:oneplusul@gmail.com) 🌐 [www.oneplusul.in](http://www.oneplusul.in)



**OnePLUS**  
Ultrasound Lab  
— QUALITY FIRST... ALWAYS! —

**Dr. Nitin Agarwal**

Pathologist & Director  
MBBS, MD, FAGE  
Ex. Chief of Lab  
Dr. Lal Path labs.

**Dr. Pooja (Garg) Agarwal**

Radiologist & Director  
MBBS (MAMC) DMRD (MAMC)  
Imaging Expert in Fetal And Maternal Medicine,  
University of Barcelona, Spain  
Fetal Medicine Foundation (UK) Accreditation



NAME	:Mrs. ARCHANA AGGARWAL	Barcode No	:10168248
AGE/GENDER	:48 YRS/Female	SPECIMEN DATE	:29/Mar/2024 08:39AM
PATIENT ID	:132869	SPECIMEN RECEIVED	:29/Mar/2024 02:27PM
REFERRED BY	:Dr. MEDIWHEEL	REPORT DATE	:30/Mar/2024 01:49PM
CENTRE NAME	:ONEPLUS ULTRASOUND LAB	LAB NO.	:012403290007

**CYTOLOGY**

**PAP SMEAR**

Sample Type: Fluid Smear

**STATEMENT OF ADEQUACY :** Satisfactory for evaluation.

**GENERAL CATEGORISATION :** Benign cellular changes.

**DESCRIPTIVE DIAGNOSIS**

1. Superficial squamous cells with intermediate and occasional metaplastic squamous cells.
2. Scanty polymorphonuclear leucocytes.
3. No epithelial cell abnormality.

**COMMENTS :**

**NEGATIVE FOR INTRAEPITHELIAL LESION/MALIGNANCY.**

P/OP/56/24

\*\*\* End Of Report \*\*\*

Checked By.

**Dr. NITIN AGARWAL**

Regn. No. *SMD-5-MPI*  
DR. NITIN AGARWAL  
MBBS, MD (PATHOLOGIST)

47, Harsh Vihar, Pitampura, Delhi-34 ☎ 011-4248 0101, 9599913051

✉ Email: [oneplusul@gmail.com](mailto:oneplusul@gmail.com) 🌐 [www.oneplusul.in](http://www.oneplusul.in)

Page 9 of 9

- Clinical correlation is essential for final diagnosis. • If test results are unsatisfactory please contact personally or on phone.
- This report is for perusal of doctors only. • All disputes are subject to Delhi jurisdiction only. • Not for medico legal case.
- All congenital anomalies in a foetus may not be diagnosed in routine obstetric ultrasound.





**OnePLUS**  
Ultrasound Lab  
— QUALITY FIRST... ALWAYS! —

**Dr. Nitin Agarwal**

Pathologist & Director  
MBBS, MD, FAGE  
Ex. Chief of Lab  
Dr. Lal Path labs.

**Dr. Pooja (Garg) Agarwal**

Radiologist & Director  
MBBS (MAMC) DMRD (MAMC)  
Imaging Expert in Fetal And Maternal Medicine,  
University of Barcelona, Spain  
Fetal Medicine Foundation (UK) Accreditation

Name	: Mrs. ARCHANA AGGARWAL	Age/Sex	: 48 YRS/Female
Ref. By	: Dr. MEDIWHEEL	Lab No	: 012403290007
Date	: 29-Mar-2024	Patient ID	: LSHHI132869

### X-ray-Chest PA view

Bony cage and soft tissues are normal.

Cardiothoracic ratio is normal.

Mediastinum is normal.


Both hila are normal.

Both costophrenic angles are clear.

Both domes of diaphragm are normal.

Lung fields are clear. No parenchymal lesion seen.

**IMPRESSION: Normal Study.**

  
**DR. POOJA GARG**  
RADIOLOGIST  
REG NO- DMIC/R/03398

**Dr. POOJA GARG**  
M.B.B.S., D.M.R.D.  
Reg No DMIC/R/03398  
Radiologist

Type By : sangeeta

47, Harsh Vihar, Pitampura, Delhi-34 ☎ 011-4248 0101, 9599913051

✉ Email: [oneplusul@gmail.com](mailto:oneplusul@gmail.com) 🌐 [www.oneplusul.in](http://www.oneplusul.in)

- Clinical correlation is essential for final diagnosis. • If test results are unsatisfactory please contact personally or on phone.
- This report is for perusal of doctors only. • All disputes are subject to Delhi jurisdiction only. • Not for medico legal case.
- All congenital anomalies in a foetus may not be diagnosed in routine obstetric ultrasound.

# ONEPLUS ULTRASOUND LAB

47, HARSH Vihar, PITAMPURA, DELHI-110034

Ms. ARCHANA AGGARWAL  
 Age : 48Y  
 Ref. by : MEDWHEEL  
 Indication 1 :  
 Indication 2 :  
 Indication 3 :  
 COMMENTS : Normal ECG

ID : 2525  
 HRWA : 155/70  
 Recorded : 29-3-2024 9:52  
 Medication 1 :  
 Medication 2 :  
 Medication 3 :

HRM : 72  
 BP : 130/55  
 P Axis : 33 deg  
 QRS Axis : 82 deg  
 T Axis : 24 deg

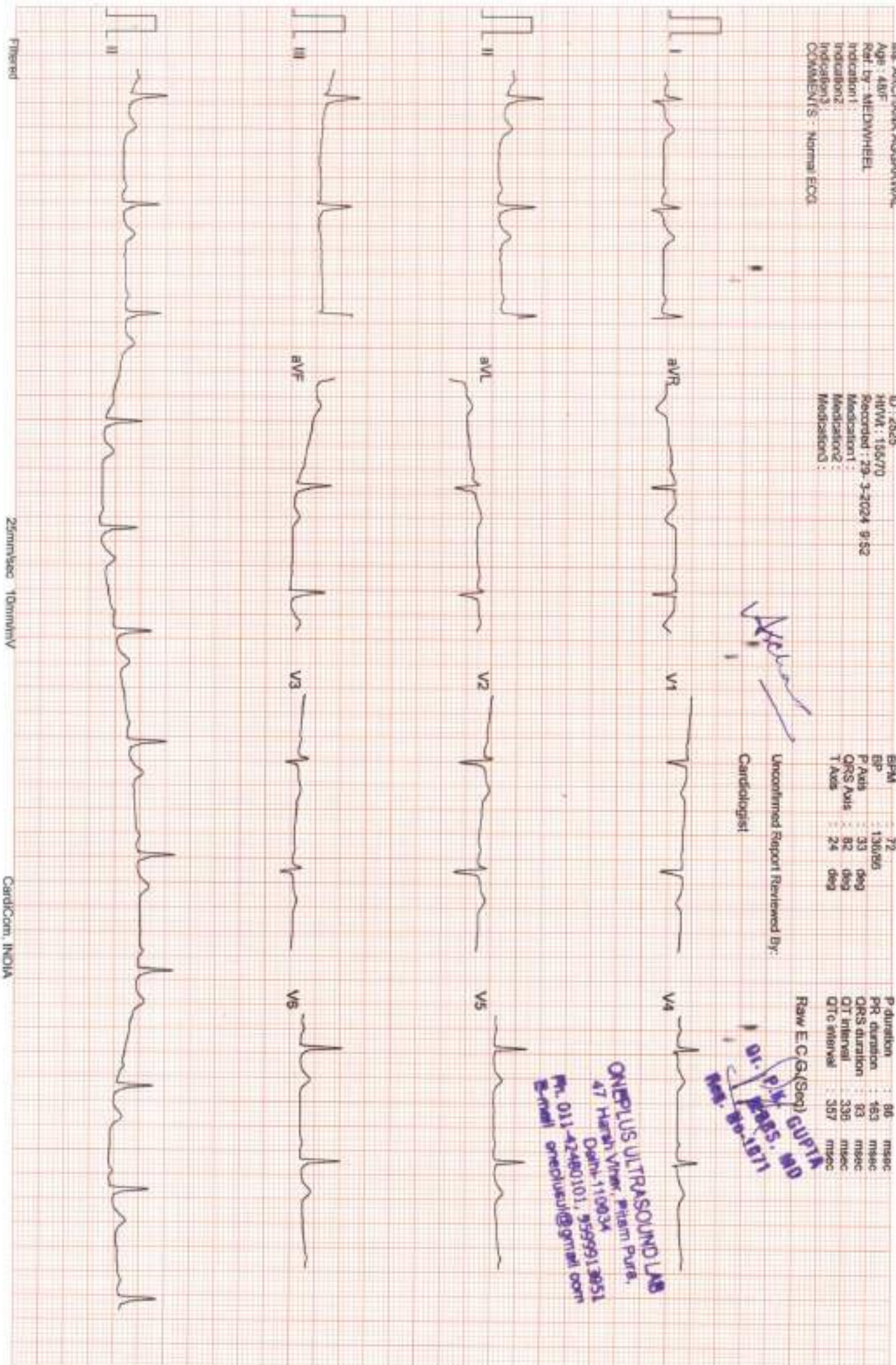
Unconfirmed Report Reviewed By:

Cardiologist

Raw ECG (Seq)  
 P duration : 86 msec  
 PR duration : 463 msec  
 QRS duration : 83 msec  
 QT interval : 338 msec  
 QTc interval : 357 msec

Dr. P.K. GUPTA  
 MBBS, MD  
 Reg. No-1571

ONEPLUS ULTRASOUND LAB  
 47 Harsh Vihar, Pitam Pura,  
 Delhi-110034  
 Ph. 011-42480101, 9599913951  
 Email oneplusul@gmail.com



Filtered

25mm/Sec 10mm/mV

CardiCam, INDIA

# ONEPLUS ULTRASOUND LAB

47, HARSH VIHAR PITAMPURA DELHI 110034

Ms. ARCHANA AGGARWAL

Age : 48/F

Ref by : MEDMHEEL

Indication1 :

Indication2 :

Indication3 :

ID : 999

HIVVI : 155770

Recorded : 29-3-2024 10:02

## TREADMILL TEST SUMMARY REPORT

Protocol: 9RUJCE

History:

Medication1 :

Medication2 :

Medication3 :

PHASE	PHASE TIME	STAGE TIME	SPEED (Km/Hr.)	GRADE (%)	H.R. (BPM)	B.P. (mmHg)	RPP X100	II	ST LEVEL (mm) V2	V5	MEETS
SUPINE					67	136/86	91	0.2	0.5	0.1	
STANDING					69	136/86	93	0.1	0.5	0.1	
STAGE 1	2:59	2:59	2.70	10.00	115	136/86	156	-0.1	0.7	0.4	4.80
STAGE 2	5:59	2:59	4.00	12.00	123	146/88	179	-0.2	0.6	0.2	7.10
STAGE 3	8:59	0:59	5.40	14.00	159	160/90	254	-0.3	0.7	0.1	8.06
PEAK EXER	7:05	1:05			155	160/90	248	-0.2	0.8	0.1	8.15
RECOVERY	2:59	2:59	0.00	0.00	72	139/88	99	0.0	0.4	0.0	

### RESULTS

Exercise Duration

Max Heart Rate

Max Blood Pressure

Max Work Load

Reason of Termination

7.05 Minutes

150 bpm 92 % of target heart rate 172 bpm

160/90 mmHg

8.15 METS

*Negative for ischemia*

Cardiologist

Dr. P. K. GUPTA  
MBBS, MD  
Reg. No. 1071

*Archana*

ONEPLUS ULTRASOUND LAB  
47 Harsh Vihar, Pitampura,  
Delhi 110034  
Ph: 011-42480101, 9399913851  
Email: oneplusul@gnl.com

10

Ms. ARCHANA AGGARWAL

I.D. : 998

AGE/SEX : 48/F

RECORDED : 29-3-2024 10:02

RATE : 67 BPM

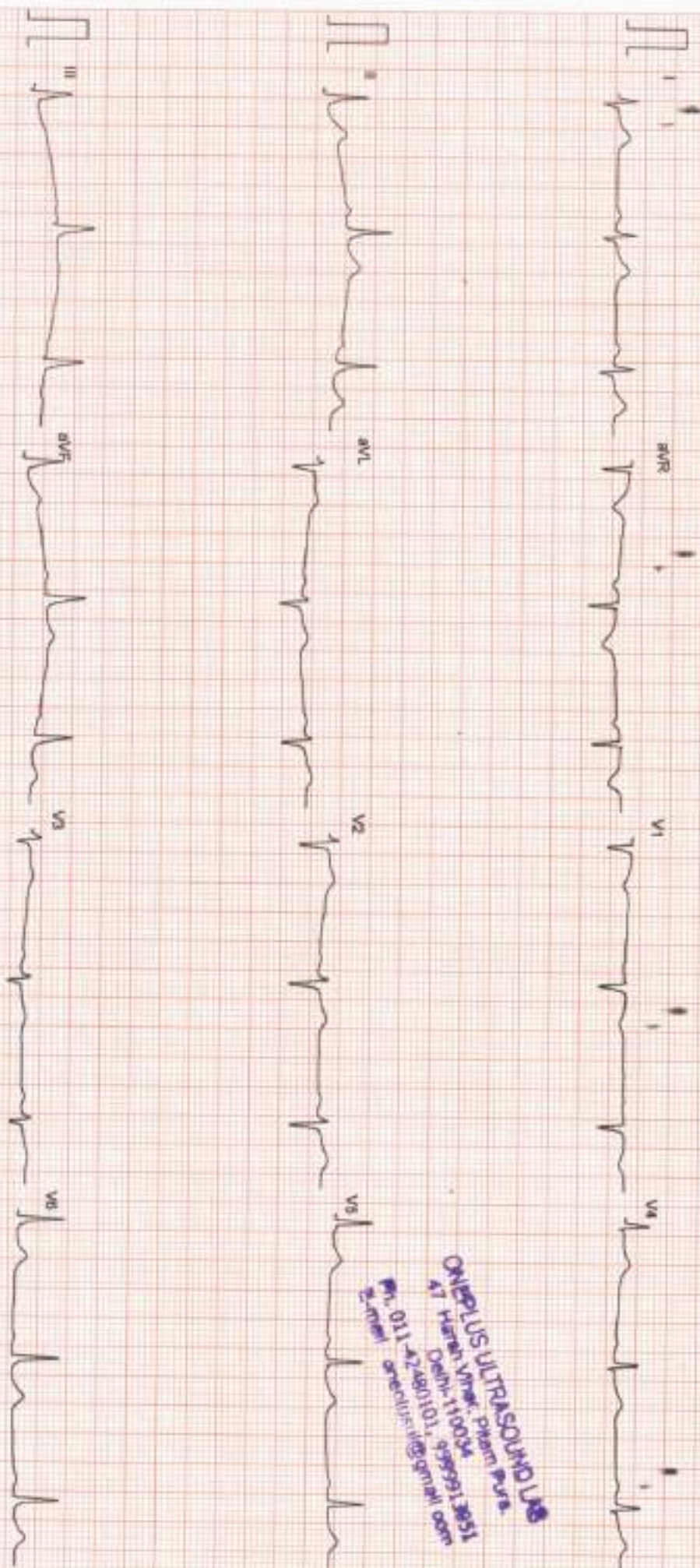
B.P. : 138/96 mmHg

# ONEPLUS ULTRASOUND LAB

SUPINE  
PRETEST

ST @ 10mm/mV  
80ms PostJ

RAW ECG



**ONEPLUS ULTRASOUND LAB**  
47 Hazrat Nizamuddin Park, New Delhi-110042  
Ph: 011-24910101, 24910102  
Email: [oneplusul@doornal.com](mailto:oneplusul@doornal.com)

Filtered

25mm/sec 10mm/mV

CardiCom, INDIA Ph: 091-731-2620740, TeleFax: 091-731-2431214



# ONEPLUS ULTRASOUND LAB

STANDING  
PRETEST

ST @ 10mm/mV  
80ms PostJ

MR. ARCHANA AGGARWAL

I.D. : 998

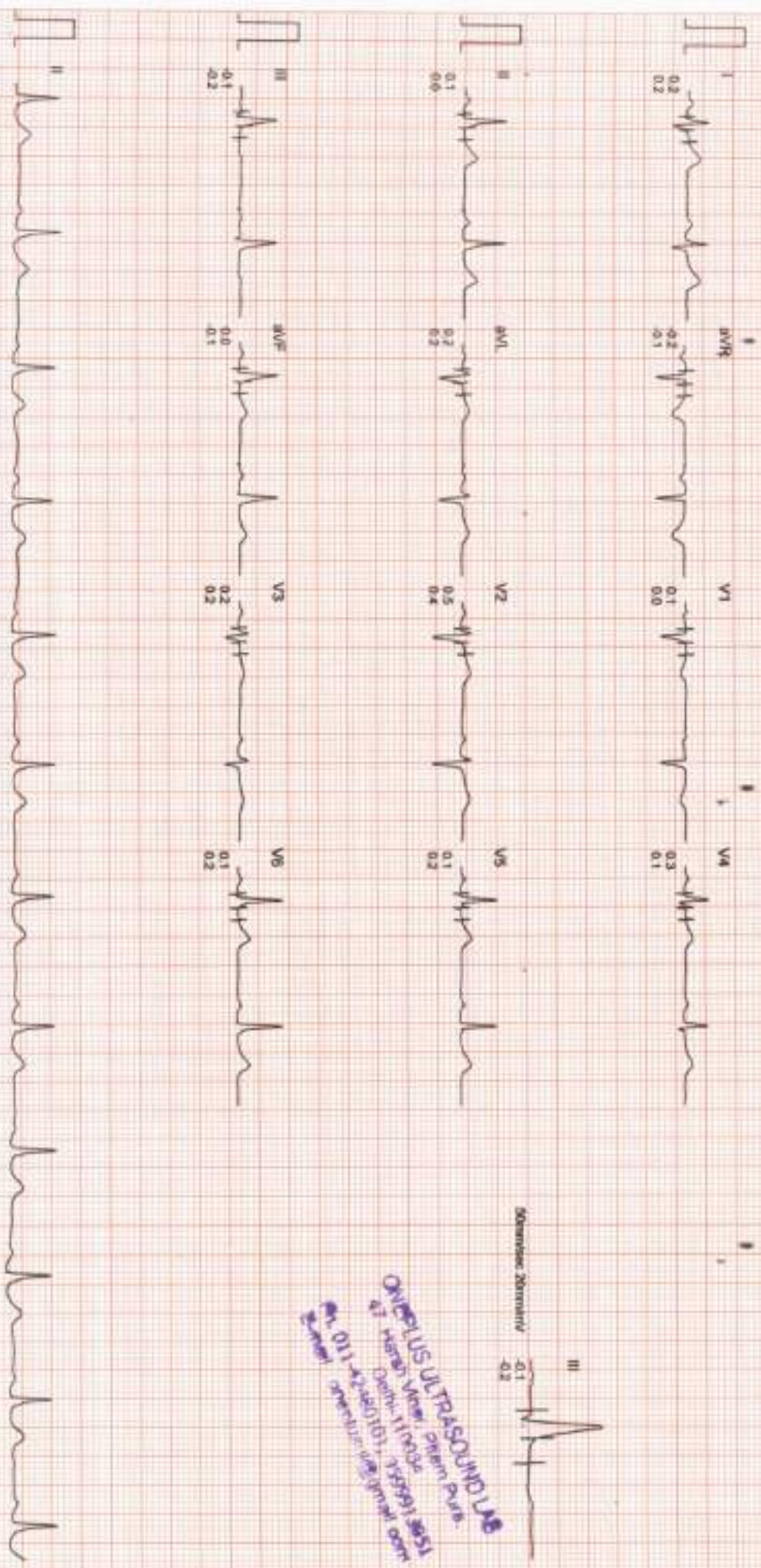
AGE/SEX : 48/F

RECORDED : 29-3-2024 10:02

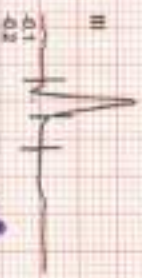RATE : 69 BPM

B.P. : 135/86 mmHg

LINKED MEDIUM



50mm/sec 20mm/mV



ONEPLUS ULTRASOUND LAB  
Hareket Vihar, Chhann Pura,  
Gurgaon, Haryana, India  
Ph: 011-22480101, 3359913851  
www.oneplusultrasound.com





MS. ARCHANA AGGARWAL

ID : 998

AGESEX : 48F

RECORDED : 29-3-2024 10:02

RATE : 115 BPM

R.P : 136/69 mmHg

# ONEPLUS ULTRASOUND LAB

BRUCE

EXERCISE 1

PHASE TIME : 2:59

STAGE TIME : 2:59

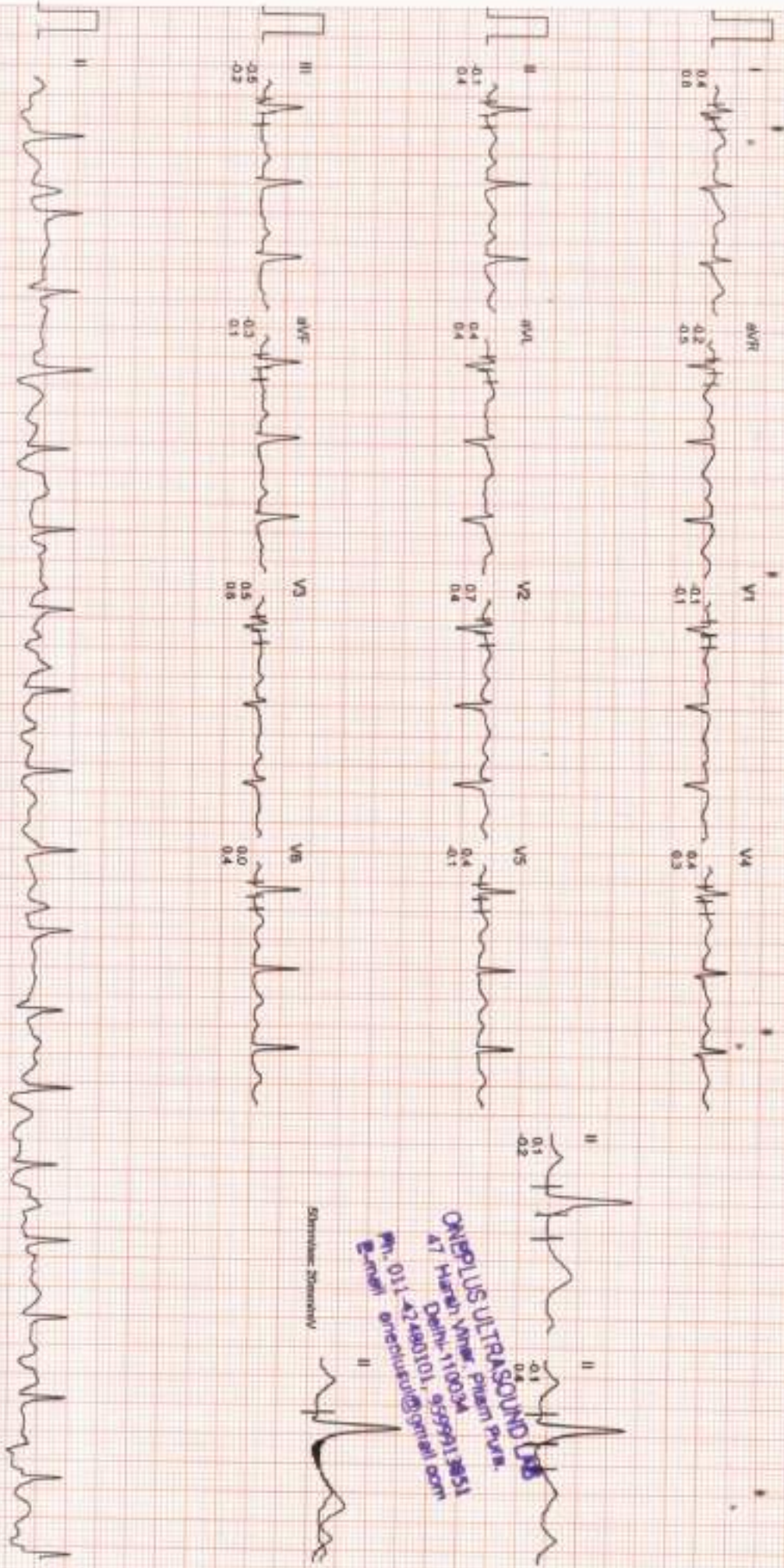
ST @ 10mm/mV

80ms PostJ

SPEED : 2.7 Km./Hr

GRADE : 10.0 %

LINKED MEDIAN



**ONEPLUS ULTRASOUND LAB**  
 47 Harek Vihar Phase 3, P.S.  
 Delhi-110034  
 Ph: 011-24980101, 9559911851  
 Email: oneplusul@oneplusul.com

Standardized Interpretation

Filtered Computer Corrected Baseline

25mm/sec 10mm/mV

CardCom, INDIA Ph: 091-731-2620740, Telefax: 091-731-2431214





# ONEPLUS ULTRASOUND LAB

Ms. ARCHANA AGGARWAL

ID : 998

AGE/SEX : 48/F

RECORDED : 29-3-2024 10:02

RATE : 155 BPM

R.P : 160/90 mmHg

BRUCE

PEAK EXER

PHASE TIME : 7:05

STAGE TIME : 1:05

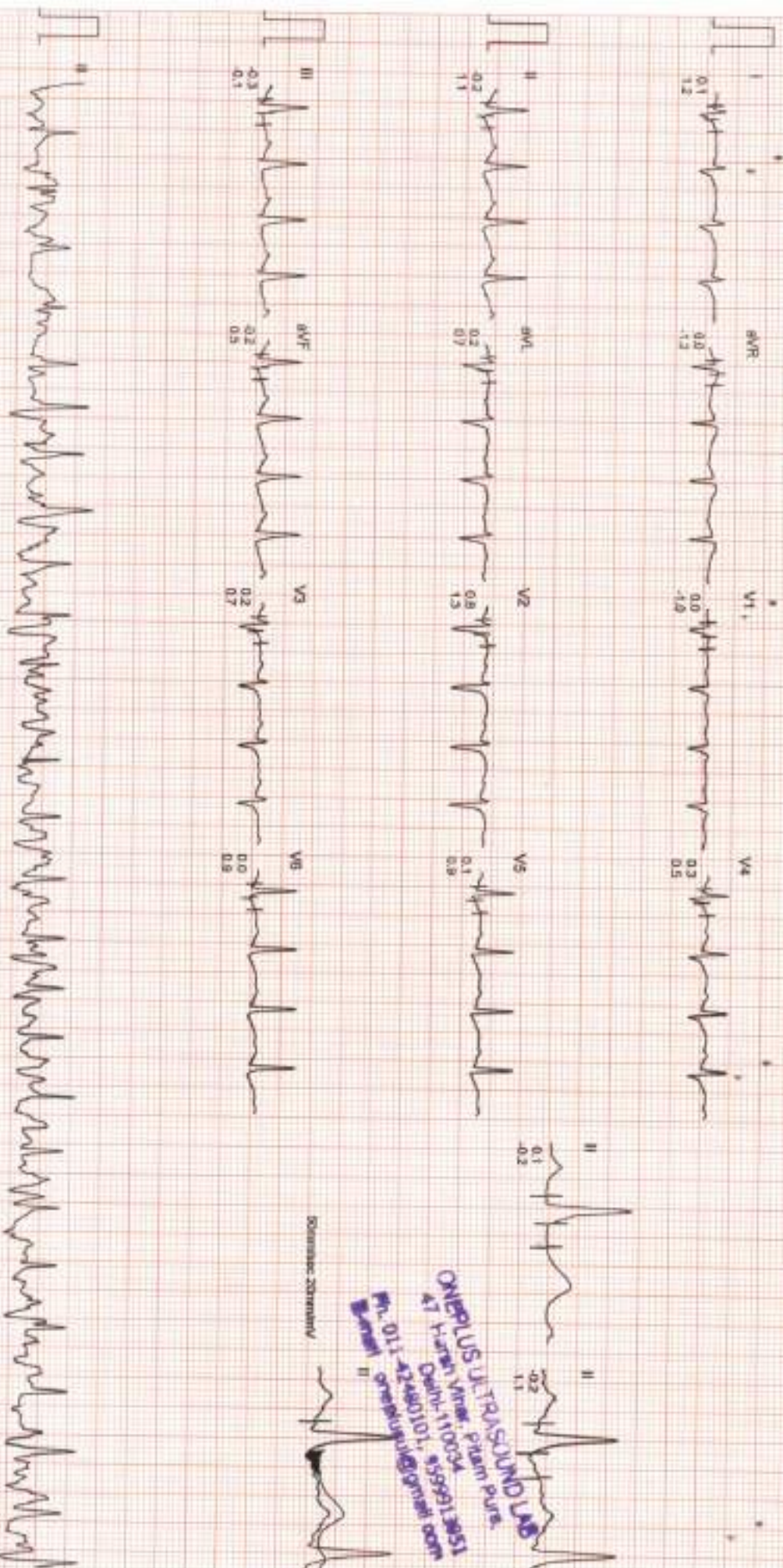
ST @ 10mm/mV

80ms PostJ

SPEED : 5.4 Km/Hr

GRADE : 14.0 %

LINKED MEDIAN



ONEPLUS ULTRASOUND LAB  
47-1, Janki Vihar, Pitampura,  
Delhi-110034  
Ph: 011-42480101, 4559918551  
Email: [oneplusultrasound@gmail.com](mailto:oneplusultrasound@gmail.com)



# ONEPLUS ULTRASOUND LAB

MS. ARCHANA AGGARWAL  
ID : 998

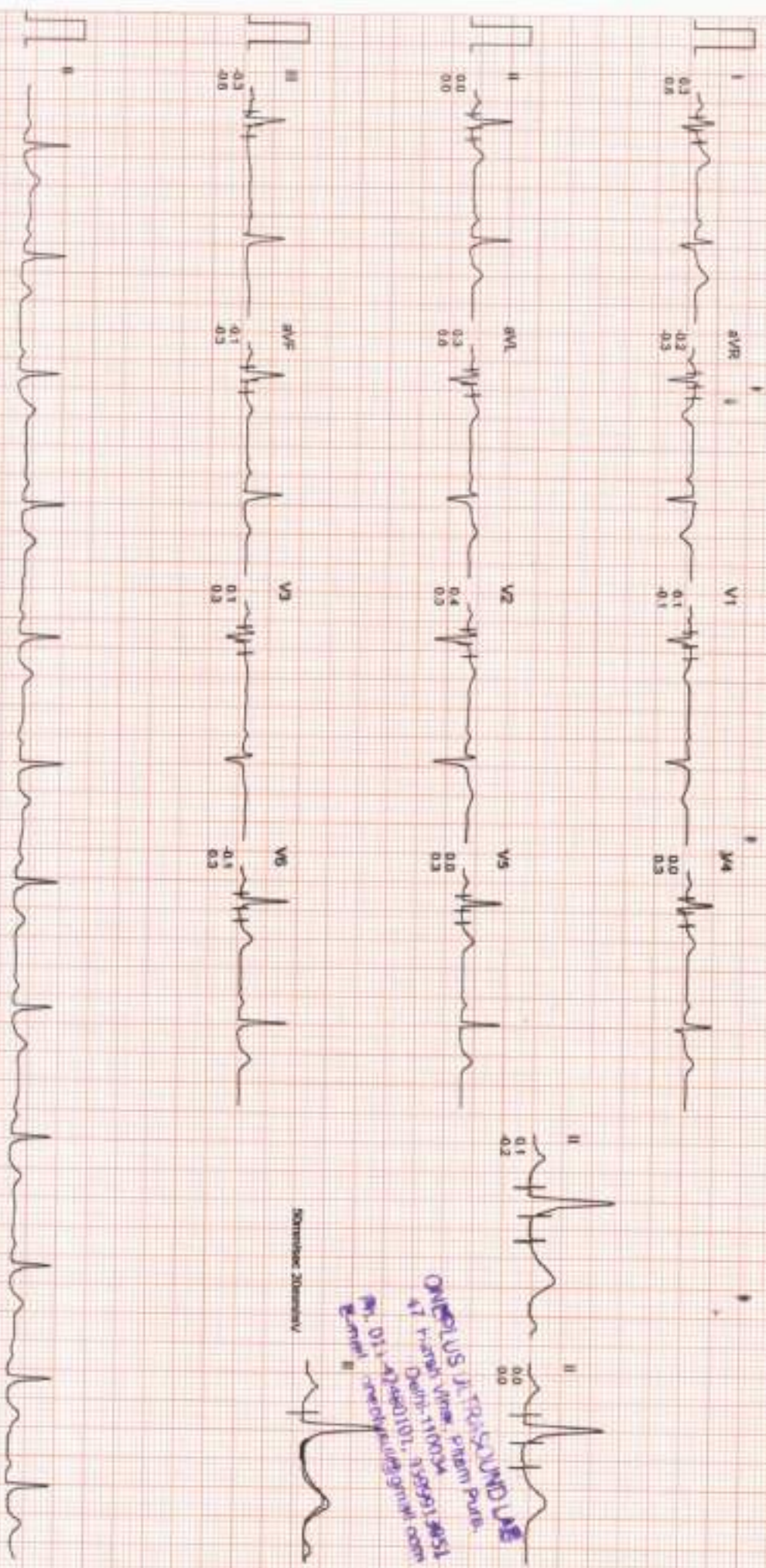
AGE/SEX : 48/F

RECORDED : 29-3-2024 10:02

RATE : 72 BPM  
R.P : 138/88 mmHg

BRUCE  
RECOVERY  
PHASE TIME : 2:59

ST @ 10mm/mV  
80ms PostJ  
SPEED : 0.0 Km/HR  
GRADE : 0.0 %  
LINKED MEDIAN



Sensitivity 20mm/mV

**ONEPLUS ULTRASOUND LAB**  
41 Transit, 1st Floor, 1st Cross, 1st Stage,  
Dharwad, Karnataka 581101, India  
Ph: 011-26460101, 1-800-91-9951  
Email: info@oneplusultrasound.com



Ms. ARCHANA AGGARWAL

ID : 998

AGE/SEX : 48/F

RECORDED : 29-3-2024 10:02

RATE : 159 BPM

R.P : 160/90 mmHg

# ONEPLUS ULTRASOUND LAB

BRUCE

EXERCISE 3

PHASE TIME : 6:59

STAGE TIME : 0:59

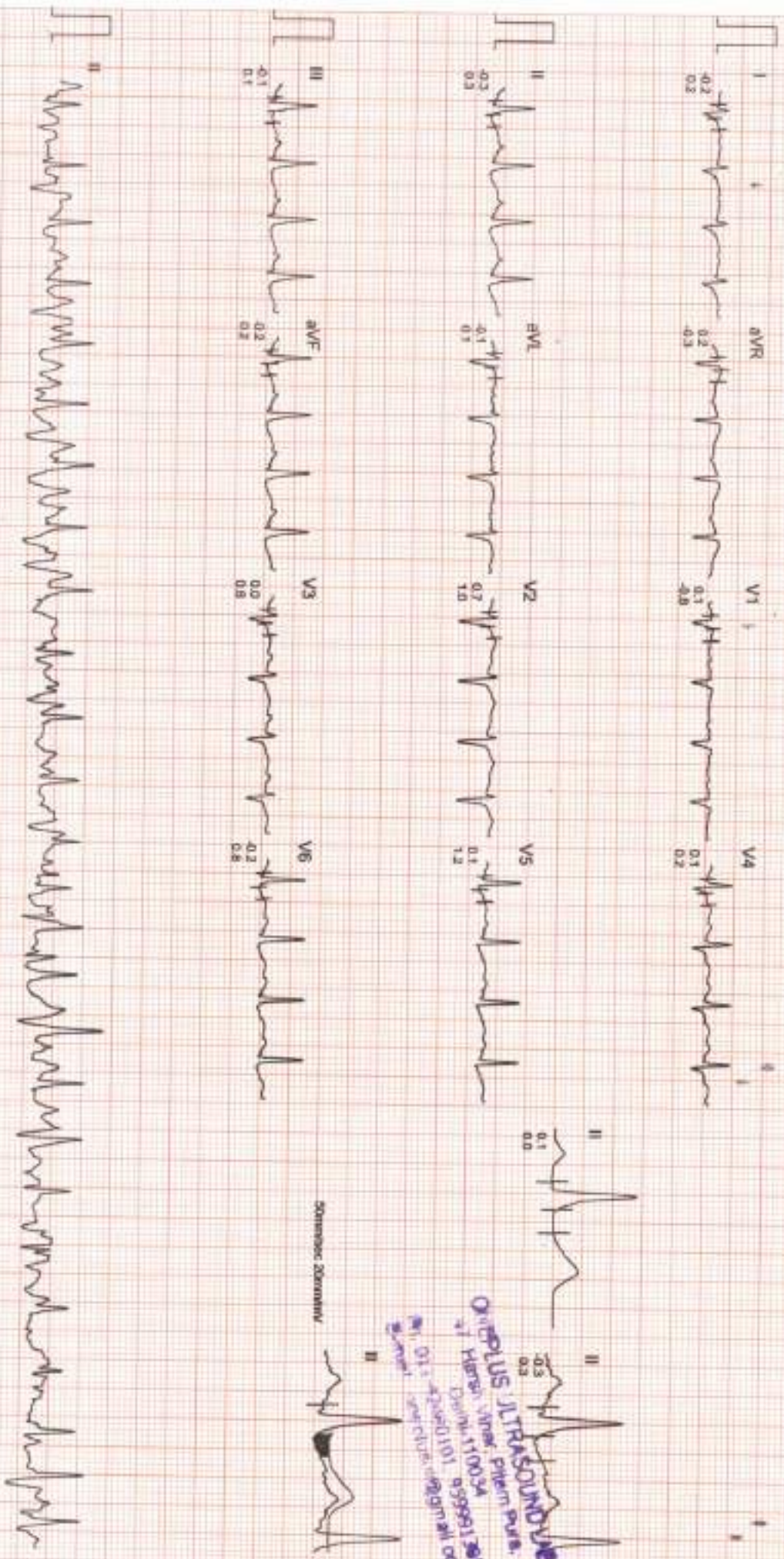
ST @ 10mm/mV

80ms PostU

SPEED : 5.4 Km/Hr

GRADE : 14.0 %

LINKED MEDIAN

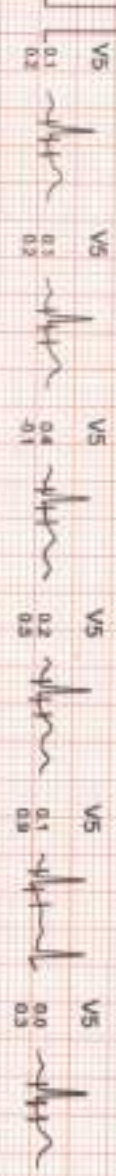
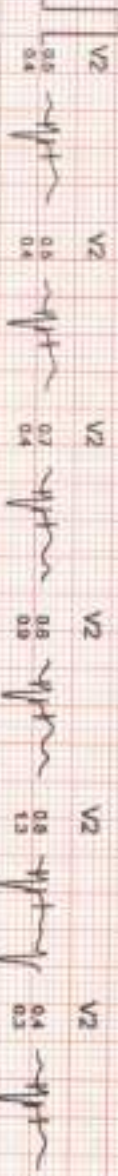
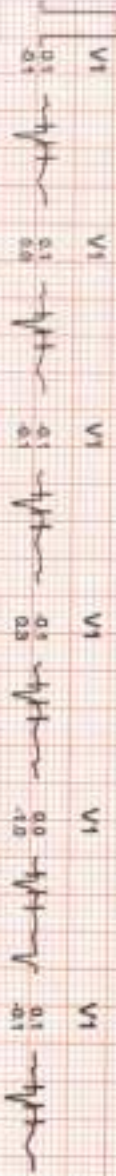
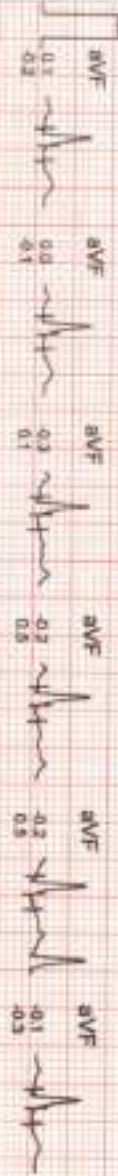
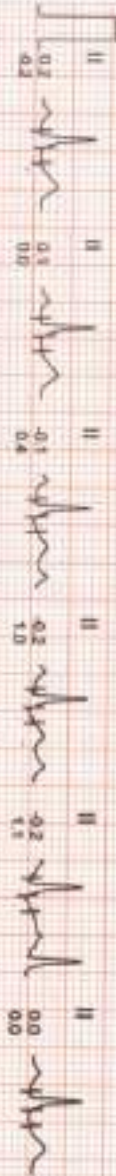
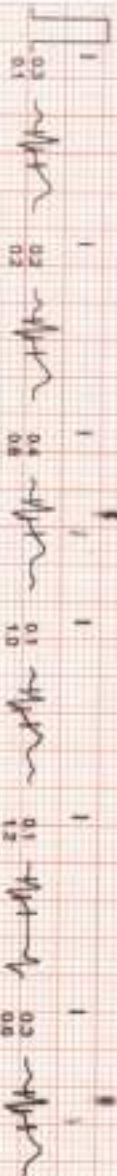


**ONEPLUS ULTRASOUND LAB**  
 Haryana Vihar, Pitampura  
 Delhi-110034  
 Phone: 110034 9399913651  
 Email: oneplusul@gmail.com





STAGE	0.0kmph 0.0%	0.6kmph 0.0%	2.50 E.Through 10.0%	4.0kmph 12.0%	7.00 D.through 14.0%	2.88
SLEEP	67 bpm B.P. 120/80 Signa Normal	68 bpm B.P. 120/80 Signa Normal	115 bpm B.P. 130/80 Signa Normal	123 bpm B.P. 140/80 Signa Normal	150 bpm B.P. 160/90 Signa Normal	0.0kmph 0.0% 72 bpm B.P. 130/80 Signa Normal
STANDING						
STAGE 1						
STAGE 2						
PEAK EXERCISE						
RECOVERY						



ONEPLUS ULTRASOUND LAB  
 41, Vardaan, Vasant Puri, New Delhi  
 Phone: 011-26207400, 011-26207401  
 Email: oneplus@oneplusultrasound.com

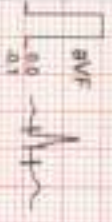
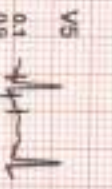
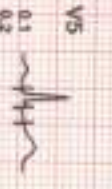
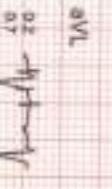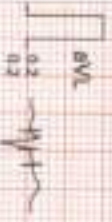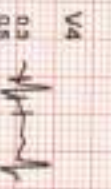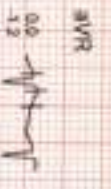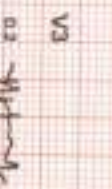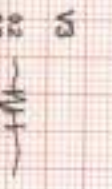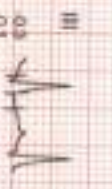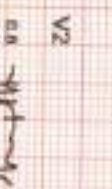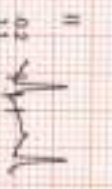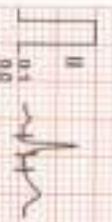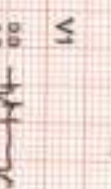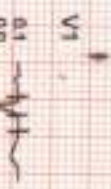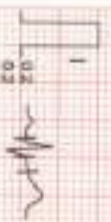STANDARD  
 0.04mV  
 0.04mV  
 80 bpm  
 B.P. 130/80  
 80mm Hg

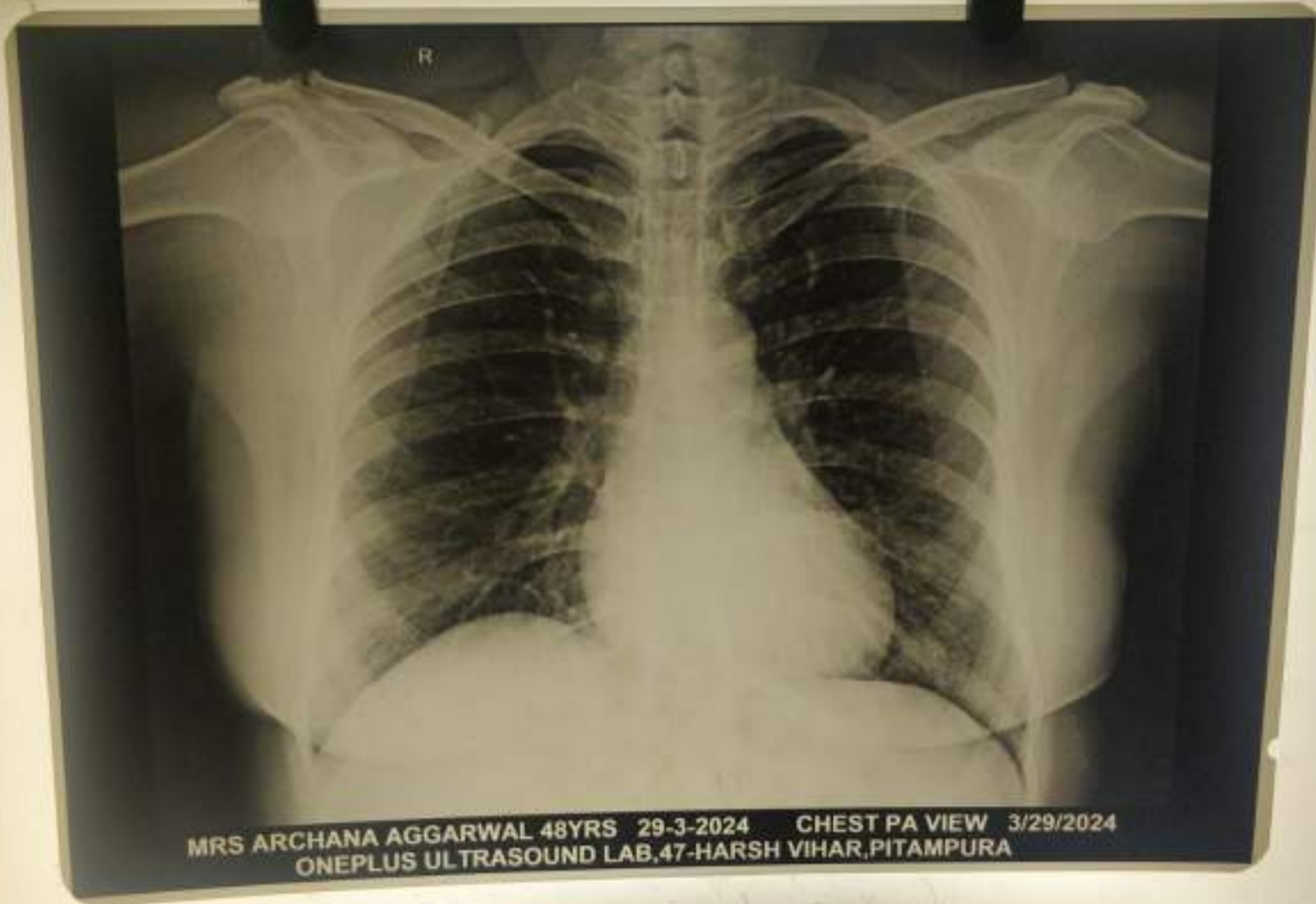PEAK EXERCISE  
 7.05  
 1.05  
 5.0mV  
 14.0%  
 150 bpm  
 B.P. 150/90  
 80mm Hg

STANDARD  
 0.04mV  
 0.04mV  
 80 bpm  
 B.P. 130/80  
 80mm Hg

PEAK EXERCISE  
 7.05  
 1.05  
 5.0mV  
 14.0%  
 150 bpm  
 B.P. 150/90  
 80mm Hg



ONEPLUS ULTRASOUND LAB  
 47 Harsh Vihar, Phase 1, Indira Nagar, Delhi-110034  
 Ph. 011-26201101, 26201102  
 Email: info@oneplusultrasound.com



MRS ARCHANA AGGARWAL 48YRS 29-3-2024 CHEST PA VIEW 3/29/2024  
ONEPLUS ULTRASOUND LAB, 47-HARSH VIHAR, PITAMPURA