



# KAPIL HOSPITAL

Multispeciality, Comprehensive & Intensive Care Centre  
 A Centre approved for Cashless Hospitalization by all Insurance Companies/TPAs/GIPSA  
 Opp. Commissioner's Office, Near New Courts, Civil Lines, Rajinder Nagar, JALANDHAR CITY (Pb.) - 144 001.



Phone : 0181-2230822, 2235822  
 Telefax : 0181-2230822 (R) 2456833  
 e-mail : guptakapil.12@gmail.com  
 Website : www.kapilhospital.in

**NABH ACCREDITED HOSPITAL**

## Page No.1

NAME	ANKIT CHAUHAN	DATE	22/05/2021
FATHER NAME	SHAILENDER	HOSPITAL ID	269/21
AGE	26/Yrs		
SEX	Male	EXAMINED BY	Dr. KAPIL GUPTA
MARITAL STATUS	Unmarried		

## PERSONAL HISTORY

HISTORY OF PRESENTING ILLNESS :	Nothing Significant
PAST HISTORY	Nothing Significant

DIET	Non-Vegetarian	BOWELS	Normal
APPETITE	Good	MICTURITION	Normal
SLEEP	Normal	HABITS	SMOKING: Nil
ALLERGY	Nil		ALCOHOL: Nil

## PHYSICAL EXAMINATION

HEIGHT	170 cm	VISION	Use spectacle for distance vision - 1.25 B/E
WEIGHT	65Kg	Chest:92/96cm	
BP	110/70 mmhg	Abdomen:78cm	COLOUR VISION - Normal
PULSE	74/mnt	Dental check up	Normal
RESP. RATE	18/mnt		
TEMP	98.2° F		
SKIN	Normal		





# KAPIL HOSPITAL

Multispeciality, Comprehensive & Intensive Care Centre

A Centre approved for Cashless Hospitalization by all Insurance Companies/TPAs/GIPSA

Opp. Commissioner's Office, Near New Courts, Civil Lines, Rajinder Nagar, JALANDHAR CITY (Pb.) - 144 001.



Phone : 0181-2230822, 2235822  
Telefax : 0181-2230822 (R) 2456833  
e-mail : guptakapil.12@gmail.com  
Website : www.kapilhospital.in

**NABH ACCREDITED HOSPITAL**

## Page No.2

	JVP	Normal
	APEX BEAT	5 <sup>th</sup> ICS mid clavicular line
CVS	THIRILLS	Absent
	HEART SOUNDS	Normal
	MURMURS	Absent

	TRACHEAL POSITION	Central
	SHAPE OF CHEST	Normal
RS	MOVEMENTS	Equal Bilateral
	BREATH SOUNDS	Vesicular
	ADVENTITIOUS SOUNDS	Absent

	TENDERNESS	Nil
	LIVER	Normal
ABDOMEN	SPLEEN	Not Palpable
	KIDNEY	Normal
	FREE FLUID	Absent
	BOWEL SOUND	Normal
	HERNIAL ORIFICES	Normal

	HIGHER MENTAL FUNCTION	Normal
	CRANIAL NERVES	Normal
CNS	SENSORY SYSTEMS	Normal
	MOTER SYSTEMS	No Abnormality
	REFLEXES	Normal


MUSCULOSKELETAL SYSTEM	Normal
------------------------	--------


**IMPRESSION: - CLINICALLY AND INVESTIGATION WISE FIT.**

DOCTOR SIGNATURE & SEAL :

DR KAPIL GUPTA  
MD





 ਭਾਰਤ ਸਰਕਾਰ  
 Government of India


 ਅੰਕਿਤ ਚੌਹਾਨ  
 Ankit Chauhan  
 ਜਨਮ ਮਿਤੀ/DOB: 22/07/1995  
 ਮਰਦ/ MALE

5335 7379 4018  
 VID: 9162 6379 7676 8865

ਮੇਰਾ ਆਧਾਰ, ਮੇਰੀ ਪਛਾਣ

*Ankit*


 ਭਾਰਤੀ ਵਿਲੱਖਣ ਪਛਾਣ ਆਧਾਰਣੀ  
 Unique Identification Authority of India

ਖਤਾ:  
 C/O ਸ਼ੈਲੇਂਦਰ, ਹਾਊਸ ਨੰ. ਈ.ਓ 126, ਪੱਕਾ ਬਾਗ਼,  
 ਲੁਧਿਆਣਾ - 1, ਜਲੰਧਰ,  
 ਪੰਜਾਬ - 144001

**Address:**  
 C/O Shalender, House No. E.Q 126,  
 Pakka Bagh, Jalandhar - I, Jalandhar,  
 Punjab - 144001

5335 7379 4018  
 VID: 9162 6379 7676 8865

QR Code with Photograph

*Hyip*



LETTER OF APPROVAL / RECOMMENDATION

To,

The Coordinator,  
Mediwheel (Arcofemi Healthcare Limited)  
Helpline number: 011- 41195959

Dear Sir / Madam,

**Sub: Annual Health Checkup for the employees of Bank of Baroda**

This is to inform you that the following employee wishes to avail the facility of Cashless Annual Health Checkup provided by you in terms of our agreement.

PARTICULARS	EMPLOYEE DETAILS
NAME	MR. CHAUHAN ANKIT
EC NO.	182059
DESIGNATION	SINGLE WINDOW OPERATOR A
PLACE OF WORK	TALHAN
BIRTHDATE	22-07-1995
PROPOSED DATE OF HEALTH CHECKUP	22-05-2021
BOOKING REFERENCE NO.	21J182059100000400E

This letter of approval / recommendation is valid if submitted along with copy of the Bank of Baroda employee id card. This approval is valid from **11-05-2021** till **31-03-2022** The list of medical tests to be conducted is provided in the annexure to this letter. Please note that the said health checkup is a **cashless facility** as per our tie up arrangement. We request you to attend to the health checkup requirement of our employee and accord your top priority and best resources in this regard. The EC Number and the booking reference number as given in the above table shall be mentioned in the invoice, invariably.

We solicit your co-operation in this regard.

Yours faithfully,

Sd/-

**Chief General Manager**  
**HRM Department**  
**Bank of Baroda**

(Note: This is a computer generated letter. No Signature required. For any clarification, please contact Mediwheel (Arcofemi Healthcare Limited))





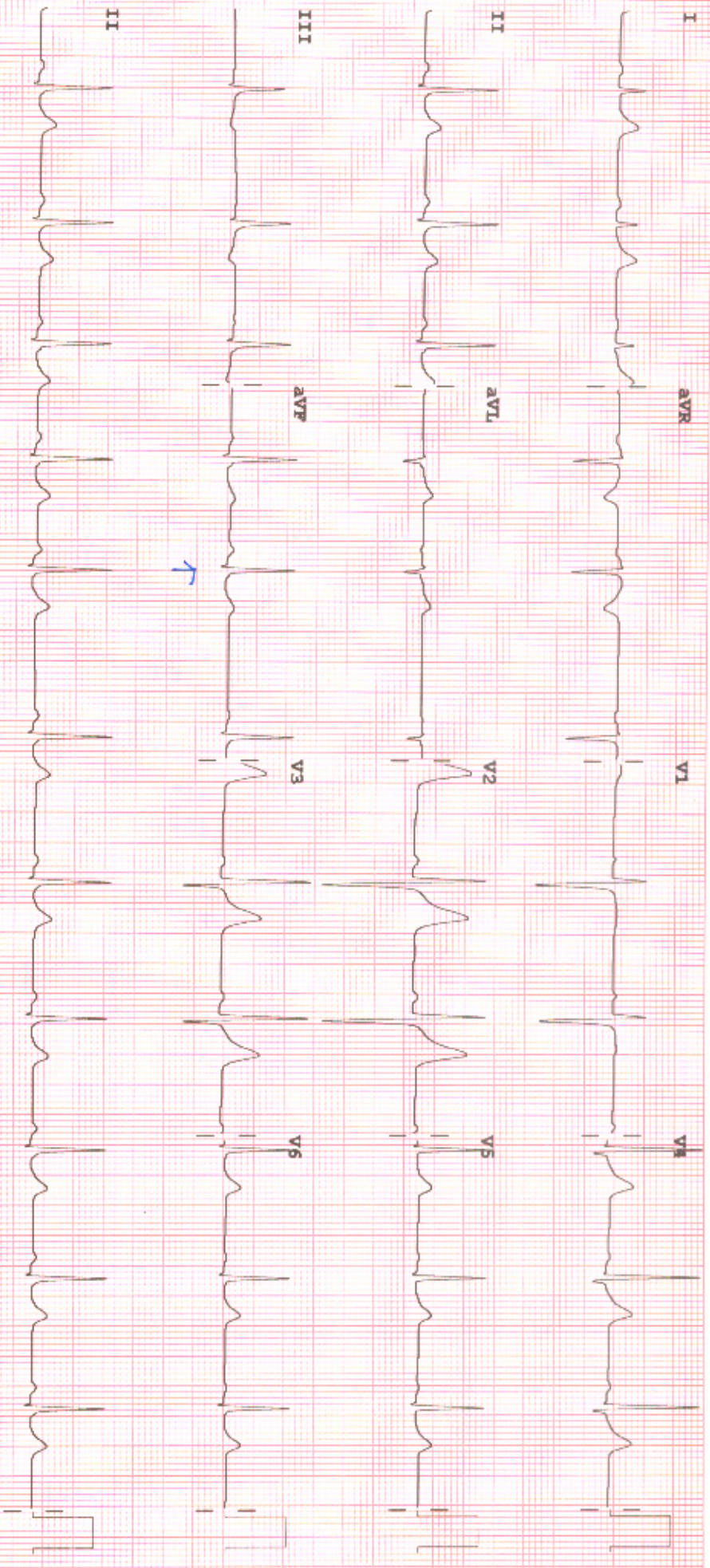
1  
26 Years  
ANKIT CHOHAN  
Male

22/05/2021 09:27:37  
KAPIL HOSPITAL JALANDHAR

Rate 69  
PR 152  
QRS 85  
QT 368  
QTc 395

--AXIS--  
P 41  
QRS 69  
T 18  
12 Lead; Standard Placement

HR 68  
P2 Normal but small No previous No ST-T changes seen except T4 Q3  
see Supraventricular ectopics seen No change in morphology  
P2 within normal limits  
GOLMAD



Device: Speed: 25 mm/sec Limb: 10 mm/mV Chest: 10.0 mm/mV F 60~0.50~40 Hz W PH10 CL P2

Ankit



# KAPIL HOSPITAL

Multispeciality, Comprehensive & Intensive Care Centre

A Centre approved for Cashless Hospitalization by all Insurance Companies/TPAs/GIPSA  
Opp. Commissioner's Office, Near New Courts, Civil Lines, Rajinder Nagar, JALANDHAR CITY (Pb.) - 144 001.



Phone : 0181-2230822, 2235822  
Telefax : 0181-2230822 (R) 2456833  
e-mail : guptakapil.12@gmail.com  
Website : www.kapilhospital.in

**NABH ACCREDITED HOSPITAL**

Client Name: Mr Ankit Chauhan	Age/Sex: 26 Yrs/Male
Date: 22/05/2021	Incharge: Dr. Kapil Gupta MD

## X-RAY, REPORT

### REPORT:

- Trachea is centrally placed.
- Heart size is normal along with all normal.
- Both costo - phrenic and cardio - phrenic angles are clear.
- Both lungs clear and no parenchymal destruction or lesion seen.
- No any Retro - sternal or mediastinal soft tissue abnormality seen.
- Both domes of diaphragms are normal with well delineated cupulae and margins.
- Normal sub - diaphragmatic stomach shadow noticed.
- Broncho - vascular shadows are normal both side.
- Hilar region both side normal.

### OPINION/IMPRESSION:-

*No cardiopulmonary lesion seen.*

*4.7.21*  
Dr KAPIL GUPTA MD  
Medical & Heart Specialist





# K.S. Clinical Lab.

## Inside Kapil Hospital

A CENTRE APPROVED FOR CASHLESS HOSPITALIZATION

Near New Courts, Jalandhar City.

E-mail : guptakapil.12@gmail.com Website : www.kapilhospital.in

(Authorised Collection Centre for Speciality Ranbaxy Lab., Dr. Lal Path Lab., Reliance, Metropolis etc.)

0181-2230822 (Fax)  
0181-2235822 (Lab.)  
0181-2456833(Resi.)


<i>Patient Name: Mr. Ankit Chauhan</i>	<i>Age/Sex: 26 Yrs/Male</i>
<i>Date: 22/05/2021</i>	<i>Incharge: Dr N K Sardana MD(Path)</i>
<i>Employee ID :-182059</i>	

<i>Haemogram</i>	<i>Patients Value</i>	<i>Normal Range</i>
Hb	12.3 gm/dl	12.0 -14.0 gm/dl
T.I.C	6500/cumm	4000-10000/cumm
<b>D.L.C</b>		
Polymorphs	72%	40-70 %
Lymphocytes	18%	20-40 %
Monocytes	06%	02-06 %
Eosinophils	04%	02-04 %
Basophils	00 %	00-01 %
P.C.V	36.5%	20-45 %
R.B.C	4.22 m/cumm	4-5.5m/cumm
M.C.V	86.7 fl	77-93 fl
M.C.H	32.0 pg	27-32 pg
M.C.H.C	33.4 g/dl	29-35 g/dl
Platelets Count	2,41,000/cumm	1,50,000-4,50,000/cumm
E.S.R	12.0 mm/1st hr	5.0-20. mm/1st hr

<i>Investigations</i>	<i>Patients Value</i>	<i>Normal Range</i>
Blood Sugar(F)	84.0 mg/dl	70-110 mg/dl
Blood Sugar(PP)	99.0 mg/dl	80-140 mg/dl

<i>Renal Function Test</i>	<i>Patients Value</i>	<i>Normal Range</i>
Blood Urea	22 mg/dl	15-45 mg/dl
S.Creatinine	0.8 mg/dl	0.4-1.2 mg/dl
S.Uric Acid	4.1 mg/dl	2.5-7.5 mg/dl

<i>Lipid Profile</i>	<i>Patients Value</i>	<i>Normal Range</i>
S.Cholesterol	156.0 mg/dl	150-190.0 mg/dl
S.H.D.L.Cholesterol	48.0 mg/dl	29-67.0 mg/dl
S.V.L.D.L.Cholesterol	27.6 mg/dl	05-23.0 mg/dl
S.L.D.L.Cholesterol	80.4 mg/dl	100-140.0 mg/dl
S.Triglycerides	138.0 mg/dl	35-160.0 mg/dl
Chol/HDL	3.2	< 5.0



**Dr. N. K. Sardana**  
M.D. (Pathology)  
Consultant Pathologist (Visiting)



# K.S. Clinical Lab.

## Inside Kapil Hospital

A CENTRE APPROVED FOR CASHLESS HOSPITALIZATION

Near New Courts, Jalandhar City.

E-mail : guptakapil.12@gmail.com Website : www.kapilhospital.in

(Authorised Collection Centre for Speciality Ranbaxy Lab., Dr. Lal Path Lab., Reliance, Metropolis etc.)

0181-2230822 (Fax)  
0181-2235822 (Lab.)  
0181-2456833(Resi.)

<i>Patient Name: Mr. Ankit Chauhan</i>	<i>Age/Sex: 26Yrs/Male</i>
<i>Date: 22/05/2021</i>	<i>Incharge: Dr N K Sardana MD(Path)</i>
<i>Employee ID :-182059</i>	

<i>Liver Function Test</i>	<i>Patients Value</i>	<i>Normal Range</i>
S.Bilirubin (Total)	0.7mg/dl	0.2-1.0 mg/dl
S.Bilirubin (Direct)	0.3 mg/dl	0.2-0.4 mg/dl
S.Bilirubin (Indirect)	0.4 mg/dl	0.2-0.6 mg/dl
S.G.O.T	20.0 Units/ml	5-35 Units/ml
S.G.P.T	23.0 Units/ml	7-40 Units/ml
S.G.G.T.P	38.0 IU/L	17-70 IU/L
S.Alkaline phosphatase	84.0 U/L	43-240 U/L
S.Total Proteins	7.1 gm/dl	6.0-8.0 gm/dl
S.Albumin	4.1 gm/dl	3.8-5.0 gm/dl
S.Globulin	3.0 gm/dl	2.3-3.5 gm/dl

<i>Serology</i>	<i>Patients Value</i>	<i>Out of Range</i>	<i>Normal Range</i>
Bloog Group	"O"Positive		



**Dr. N. K. Sardana**  
M.D. (Pathology)  
Consultant Pathologist (Visiting)





# K.S. Clinical Lab.

## Inside Kapil Hospital

A CENTRE APPROVED FOR CASHLESS HOSPITALIZATION

Near New Courts, Jalandhar City.

E-mail : guptakapil.12@gmail.com Website : www.kapilhospital.in

(Authorised Collection Centre for Speciality Ranbaxy Lab., Dr. Lal Path Lab., Reliance, Metropolis etc.)

0181-2230822 (Fax)  
0181-2235822 (Lab.)  
0181-2456833(Res.)

<i>Patient Name: Mr. Ankit Chauhan</i>	<i>Age/Sex: 26Yrs/Male</i>
<i>Date: 22/05/2021</i>	<i>Incharge: Dr N K Sardana MD(Path)</i>
<i>Employee ID :-182059</i>	

<i>Urine Analysis</i>	
Color	Pale Yellow
Sugar(F)	Nil
Sugar(PP)	Nil
Albumin	Nil
Ketones	Nil
Bilirubin	Nil
Urobilinogen	Normal
Leucocyte esterase	Negative
<i>Microscopic Examination/HPF</i>	
Leucocytes/Pus Cells	2-3
R.B.Cs.	Nil
Casts	Nil
Epithelial Cells	Nil
Significant Crystals	Nil
Specific Gravity	1.010
PH	6.0



**Dr. N. K. Sardana**  
M.D. (Pathology)  
Consultant Pathologist (Visiting)



# K.S. Clinical Lab.

## Inside Kapil Hospital

A CENTRE APPROVED FOR CASHLESS HOSPITALIZATION

Near New Courts, Jalandhar City.

E-mail : guptakapil.12@gmail.com Website : www.kapilhospital.in

(Authorised Collection Centre for Speciality Ranbaxy Lab., Dr. Lal Path Lab., Reliance, Metropolis etc.)

0181-2230822 (Fax)  
0181-2235822 (Lab.)  
0181-2456833(Resi.)

<i>Patient Name: Mr. Ankit Chauhan</i>	<i>Age/Sex: 26 Yrs/Male</i>
<i>Date: 22/05/2021</i>	<i>Incharge: Dr N K Sardana MD(Path)</i>
<i>Employee ID :-182059</i>	


### THYROID FUNCTION TEST:

<u>Investigation</u>	<u>Observed Value</u>	<u>Unit</u>	<u>Biological Reference Interval</u>
Thyroid Panel-1			
T3 (Total)	79.55	ng/dl	70-204 First Trimester: 81-190 Second Trimester: 100-260 Third Trimesters: 100-260
T4 (Total)	6.2	µg/dl	5.0-12.5
TSH (Ultrasensitive)	3.9	µIU/ML	0.45-4.5 First Trimester : 0.1-2.5 Second Trimester : 0.2-3.0 Third Trimester : 0.3-3.0

References: 1. Interpretation of thyroid function tests. Dayan et al.  
THE LANCET. Vol 357. February 24, 2001.

2. Laboratory Evaluation of Thyroid function. India Thyroid Guidelines.  
JAPI, January 2011, Vol. 59

---END OF REPORT---

  
**Dr. N. K. Sardana**  
M.D. (Pathology)  
Consultant Pathologist (Visiting)

KAPIL HOSPITAL  
JALANDHAR



# K.S. Clinical Lab.

## Inside Kapil Hospital

A CENTRE APPROVED FOR CASHLESS HOSPITALIZATION

Near New Courts, Jalandhar City.

E-mail : guptakapil.12@gmail.com Website : www.kapilhospital.in

(Authorised Collection Centre for Speciality Ranbaxy Lab., Dr. Lal Path Lab., Reliance, Metropolis etc.)

0181-2230822 (Fax)  
0181-2235822 (Lab.)  
0181-2456833(Resi.)

<i>Patient Name: Mr. Ankit Chauhan</i>	<i>Age/Sex: 26 Yrs/Male</i>
<i>Date: 22/05/2021</i>	<i>Incharge: Dr N K Sardana MD(Path)</i>
<i>Employee ID :-182059</i>	

### INTERPRETATION:-

**Fasting Blood Sugar: 84.0mg/dl** (Normal value: 70-110.0 mg/dl)

**Clients HbA1c: 4.6%** (Normal value (4.0% - 6.0 %))

HBA1C	NORMAL RANGE	
	Non Diabetic	4.0% - 6.0%
	Good Control	6.1% - 8.0%
	Poor Control	8.1% - 9.0%
	Unsatisfactory	>9%

### **Note:-**

- 1. A three monthly monitoring is recommended in diabetics.
- 2. Since HbA1c concentration represents the integrated values for blood glucose over the preceding 6-10 weeks and is not affected by daily glucose fluctuation, exercise and recent food intake, it is a more useful tool for monitoring diabetics.

### **Clinical Use:-**

- Clinical management of diabetes mellitus through routine monitoring.
- Assess compliance with therapeutic regimen.

### **Report Completed:-**

### **Test Requested:**

**GLYCOSYLATED HEMOGLOBIN/HbA1c.**



**Dr. N. K. Sardana**  
M.D. (Pathology)  
Consultant Pathologist (Visiting)



# KAPIL HOSPITAL

Multispeciality, Comprehensive & Intensive Care Centre

A Centre approved for Cashless Hospitalization by all Insurance Companies/TPAs/GIPSA  
Opp. Commissioner's Office, Near New Courts, Civil Lines, Rajinder Nagar, JALANDHAR CITY (Pb.) - 144 001.



Phone : 0181-2230822, 2235822  
Telefax : 0181-2230822 (R) 2456833  
e-mail : guptakapil.12@gmail.com  
Website : www.kapilhospital.in

**NABH ACCREDITED HOSPITAL**

## ULTRA SONOGRAPHY REPORT

<i>Clients Name : Mr Ankit Chauhan</i>	<i>Age/Sex: 26 Yrs/ Male</i>
<i>PART Scanned:- ABDOMEN</i>	<i>Sonography Window :- Good/Bad/Reasonable</i>
<i>Non fasting</i>	<i>22/05/2021</i>

**Liver** is normal in size to 11.0.cm, shape, outline and show echogenicity. No sol. is seen. I.H.B.R. are normal. Portal vein is 10.6. No pathology seen in Porta.

**Gall Bladder** is normal in size. Walls are normal. No calculus/sol. seen. The cleavage line between the liver and gall bladder is maintained. To be repeated on fasting

**Common Bile Duct** is normal in calibre. No obstruction /mass/calculus could be seen up to the length scanned.

**Pancreas** is normal in size, shape, outline and echopattern. PD is normal. No sol. seen. Peripancreatic region is normal.

**Spleen** is normal in size and echopattern. No sol. seen. Splenic vein is normal in size. No collaterals could be seen.

**Kidneys:** Both kidneys are normal in size, shape, outline and parenchymal echopattern. Cortico medullary distinction is well maintained bilaterally but right kidney few concretions/speck seen in middle calyx. Central echoes are compact. No calculi/hydronephrosis seen in left kidneys. Peri renal area is normal Rt kidney 9.7x4.6cm, Lt kidney 9.7 x4.8cm.

**Ureters:** seem to be normal upto the parts scanned.

**Urinary Bladder** is normal. No calculus/mass is seen. UB wall is normal. vesicles are Psoas muscles seem to be normal. Capacity ( Volume) is decreased

**Bowel loops:** Right iliac region seem to be grossly normal. No sol. seen. No free fluid/gross lymphadenopathy noted.

**Pleural:** spaces are normal.

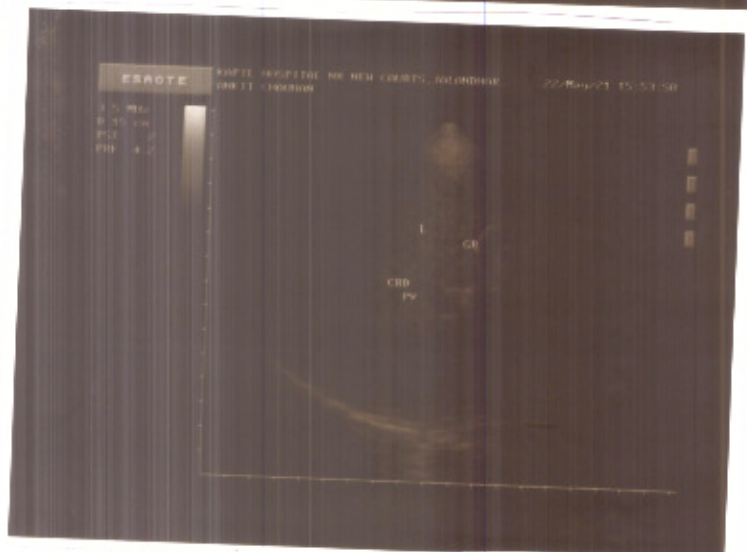
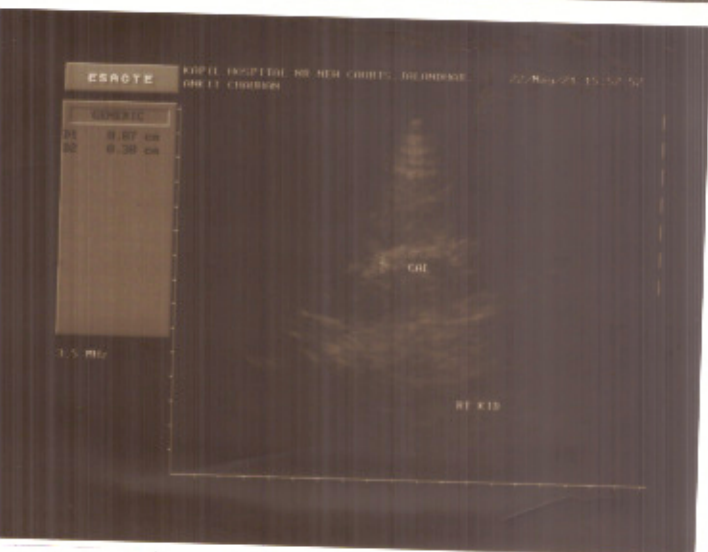

**Prostate** is normal in size. capsule intact, no nodular

**IMPRESSION:** Normal US Scan Except Few concretion seen in Right Kidney Middle Calyx.

Date: 22/05/2021

*Dr Kapil Gupta*  
MD  
KAPIL HOSPITAL  
JALANDHAR CITY

US scan of abdomen film of Ankit Chauhan



4795  
 KAPIL HOSPITAL  
 JALANDHAR CITY