

MER- MEDICAL EXAMINATION REPORT

Date of Examination	25/11/23		
NAME	Goleek kumar		
AGE	32	Gender	m
HEIGHT(cm)	180	WEIGHT (kg)	75 Bmg - 23.1
B.P.	110/72		
ECCG	normal		
X Ray	normal		
Vision Checkup	normal		
Present Ailments	none		
Details of Past ailments (If Any)	no		
Comments / Advice : She /He is Physically Fit	medicinesy Rid		



Dr. Shilpa Reddy
 MBBS, DCP
 Reg. No. 20024

Signature with Stamp of Medical Examiner



भारतीय विशिष्ट पहचान प्राधिकरण
भारत सरकार
Unique Identification Authority of India
Government of India



E-Aadhaar Letter

नामांकन क्रमांक/Enrollment No. 1007/21130/02237

Date: 25/07/2013

Omendra Kumar (ओमंन्द्र कुमार)
S/O: Vijay Prasad Singh Sanokhar Sanokhar,
Bhagaipur
Bihar, 813204

सूचना

- आधार पहचान का प्रमाण है, नागरिकता का नहीं।
- पहचान का प्रमाण ऑनलाइन ऑथेंटिकेशन द्वारा प्राप्त की
- यह एक इलेक्ट्रॉनिक प्रक्रिया द्वारा बना हुआ पत्र है।

आपका आधार क्रमांक/Your Aadhaar No.

7740 7657 6790



INFORMATION

- Aadhaar is proof of identity, not of citizenship
- To establish identity, authenticate online.
- This is electronically generated letter.



*Digitally signed by
Khandwal Anand
Date: 25/07/2013*

आधार - आम आदमी का अधिकार



1800-121-2343



info@uidai.gov.in



www.uidai.gov.in

- आधार देश भर में मान्य है।
- आधार के लिए आपको एक ही बार नामांकन दर्ज करवाने की आवश्यकता है।
- कृपया अपना नवीनतम मोबाइल नंबर तथा ई-मेल पता दर्ज कराए इससे आपको विभिन्न सुविधाएं प्राप्त करने में सहायता होगी।

- Aadhaar is valid throughout the country.
- You need to enrol only once for Aadhaar.
- Please update your mobile number and e-mail address. This will help you to avail various services in future.



भारत सरकार
GOVERNMENT OF INDIA



भारतीय विशिष्ट पहचान प्राधिकरण
UNIQUE IDENTIFICATION AUTHORITY OF INDIA



ओमंन्द्र कुमार
Omendra Kumar
जन्म तिथि: 1991
पुरुष Male



7740 7657 6790

पता
S/O विजय प्रसाद सिंह
ओमंन्द्र, सनोखर सामनपुर
बिहार 813204

Address
S/O Vijay Prasad Singh
Sanokhar Sanokhar,
Bhagaipur
Bihar, 813204

आधार - आम आदमी का अधिकार

Aadhaar - Aam Aadmi ka Adhikar

You have been informed that ent diet consultation facility is not available at our centre. If you are ready then your test can be start
2D echo test facility is not available at our center, instead we do TMT test.

Gokul Kumar





MODERN PATHOLOGY & DIAGNOSTIC CENTRE

Dr. R. P. Rastogi
M.B.B.S., M.D. (Path & Bact)



CLINIC :

1/4A, Vineet Khand, (Opp Jaipuria Management)
Gomti Nagar, Lucknow - 226 010
Ph.: 0522-4008184, 4308184 • 8112323230
Mob.: 7618884441, 9450389932, 8177063877

Date	: 25-Nov-2023	Age	: 32 Yrs.
Name	: Mr. GOKUL KUMAR	Sex	: Male
Ref.By	: APOLLO HEALTH		
Haemoglobin	15.2	gm%	14 - 17
Total Leucocyte Count	6600	Cells/cumm.	4000-11000
Differential Leucocyte Count			
Polymorphs	59	%	45 - 70
Lymphocytes	30	%	20 - 45
Eosinophils	06	%	0 - 6
Monocytes	05	%	0 - 8
Basophils	00	%	0 - 1
Erythrocyte Sedimentation Rate (Wintrobe)			
ESR	06	mm in 1st Hr.	0 - 9
PCV	32.2	cc%	40 - 52
Corrected ESR	02	mm in 1st Hr.	0 - 9
Platelet Count	2.03	lakh/cumm.	1.5 - 4.0
Red Cells Count	4.64	million/cmm	3.90 to 5.80
Absolute values			
MCV	94.1	fL	77 - 97
MCH	30.2	pg	27 - 31
MCHC	32.2	gm /dl	31 - 34

Dr. Sanjay Rastogi

M.B.B.S., DCP (OFN&B) (BARC)

Dr. Smita Rastogi

M.B.B.S., DCP

Results, adhering to W.H.O. and International Federation of Clinical Chemists Quality Control Standards.

SAMPLE COLLECTION FACILITY AVAILABLE

Report needs clinicopathological correlation ♦ Not for Medico Legal Purpose

e-mail : mpdcgn@gmail.com ♦ For online reports - www.modernpath.in

♦ Please ask for your computerized bill ♦ Pay only the printed collection charges



MODERN PATHOLOGY & DIAGNOSTIC CENTRE

CLINIC :
1/4A, Vineet Khand, (Opp Jaipuria Management)
Gomti Nagar, Lucknow - 226 010
Ph.: 0522-4008184, 4308184 • 8112323230
Mob.: 7618884441, 9450389932, 8177063877

Dr. R. P. Rastogi
M.B.B.S., M.D. (Path & Bact)



Date : 25-Nov-2023

Name : **Mr. GOKUL KUMAR**

Ref.By : APOLLO HEALTH

Age : 32 Yrs.

Sex : Male

General Blood Picture

RBCs RBCs are Normocytic & Normochromic.
No Normoblasts are seen.

WBCs TLC is within normal range.
DLC shows normal counts.
No immature cells of WBC seen.

PLATELETS Platelets are adequate in number and morphology.

OTHERS No haemoparasites are seen.

IMPRESSION Normal GBP

Dr. Sanjay Rastogi
M.B.B.S., D.C.P. (DRC) (IARC)

Dr. Smriti Rastogi
M.B.B.S., DCP

Results, adhering to W.H.O. and International Federation of Clinical Chemists Quality Control Standards.

SAMPLE COLLECTION FACILITY AVAILABLE

Report needs clinicopathological correlation ♦ Not for Medico Legal Purpose

e-mail : mpdcgn@gmail.com ♦ For online reports - www.modernpath.in

♦ Please ask for your computerized bill ♦ Pay only the printed collection charges



MODERN PATHOLOGY & DIAGNOSTIC CENTRE

CLINIC :
1/4A, Vineet Khand, (Opp Jaipuria Management)
Gomti Nagar, Lucknow - 226 010
Ph.: 0522-4008184, 4308184 • 8112323230
Mob.: 7618884441, 9450389932, 8177063877

Dr. R. P. Rastogi
M.B.B.S., M.D. (Path & Bact)



Date	: 25-Nov-2023		
Name	: Mr. GOKUL KUMAR	Age	: 32 Yrs.
Ref.By	: APOLLO HEALTH	Sex	: Male
Plasma Glucose - F GOD-POD Method	96	mg/dl	70 - 110
Plasma Glucose - PP GOD-POD Method	112	mg/dl	110 - 170
Blood Group & Rh	"A" Positive		
LFT T&D			
Total Bilirubin	0.63	mg%	0.2 - 1.0
Direct Bilirubin	0.20	mg%	0.0 to 0.40
Indirect Bilirubin	0.43	mg%	0.10 to 0.90
S.G.P.T	53	IU/L	5 - 40
S.G.O.T	48	IU/L	5 - 50
ALP	90	IU/L	40 to 129
Serum Gamma G.T.	20	IU/L	11 - 50
KFT			
UREA	20.4	mg %	15 - 50
CREATININE	0.81	mg %	0.5 - 1.5
URIC ACID	5.3	mg %	2 - 7
CALCIUM	9.8	mg %	8.8 - 10.0
Urine Sugar (Fasting)	NIL		
Urine Sugar (PP)	NIL		

Dr. Sanjay Rastogi
M.B.B.S., DCP, CRIAT (BARC)


Dr. Smita Rastogi
Contd... M.B.B.S., DCP

Results, adhering to W.H.O. and International Federation of Clinical Chemists Quality Control Standards.

SAMPLE COLLECTION FACILITY AVAILABLE

Report needs clinicopathological correlation ♦ Not for Medico Legal Purpose

e-mail : mpdcgn@gmail.com ♦ For online reports - www.modernpath.in

♦ Please ask for your computerized bill ♦ Pay only the printed collection charges



MODERN PATHOLOGY & DIAGNOSTIC CENTRE

Dr. R. P. Rastogi
M.B.B.S., M.D. (Path & Bact)



CLINIC :

1/4A, Vineet Khand, (Opp Jaipuria Management)
Gomti Nagar, Lucknow - 226 010
Ph.: 0522-4008184, 4308184 • 8112323230
Mob.: 7618884441, 9450389932, 8177063877

Date : 25-Nov-2023

Name : **Mr. GOKUL KUMAR**

Ref.By : APOLLO HEALTH

Age : 32 Yrs.

Sex : Male

LIPID PROFILE

Triglycerids	115	mg%	70 - 190
S. Cholestrol S.	201	mg%	130 - 230
S. HDL Cholestrol	44.2	mg%	35 - 75
S. LDL Cholestrol	133.8	mg%	75 - 150
VLDL	23	mg%	0 - 34
Chol / HDL factor	4.55		
LDL / HDL Factor	3.03		

COMMENTS

- * Triglycerides (TG) are the main dietary lipids. Cholesterol constitutes a small part of the dietary lipids, it is mostly synthesised in the liver. Both TG and Chol. are transported through the plasma by lipoproteins (Chylomicrons, VLDL, LDL, IDL, HDL).
- * LDL is the major cholesterol particle in plasma and high levels are strongly implicated in the formation of atheroma. An increase in the LDL leads to hypercholesterolemia, and therefore a risk factor for IHD. LDL increases with age particularly in females. Oestrogen lower LDL and raise HDL. Raised chol. in females is mostly due to disturbed thyroid function.
- * Increase in VLDL leads to hyperglyceridaemia. Raised TGs are associated with increased risk of CHD. Very high TGs increase the risk of Pancreatitis. Cholesterol is often raised due to Diabetes, Renal disease, Diuretic or Betablocker therapy.

TYPES OF HYPERLIPOPROTEINEMIAS

TYPE 1: Normal cholesterol TG greatly raised	TYPE 3: Cholesterol increased TG increased
TYPE 2a: Cholesterol increased LDL increased TG normal	TYPE 4: Cholesterol normal / increased VLDL increased TG increased
TYPE 2b: Chol. increased VLDL raised TG increased LDL increased	TYPE 5: Cholesterol increased LDL reduced VLDL increased TG greatly increased

Dr. Sanjay Rastogi
M.B.B.S., DCP, CRIAT (BARC)

Dr. Smita Rastogi
Contd., M.B.B.S., DCP

Results, adhering to W.H.O. and International Federation of Clinical Chemists Quality Control Standards.

SAMPLE COLLECTION FACILITY AVAILABLE

Report needs clinicopathological correlation ♦ Not for Medico Legal Purpose

e-mail : mpdcgn@gmail.com ♦ For online reports - www.modernpath.in

♦ Please ask for your computerized bill ♦ Pay only the printed collection charges



MODERN PATHOLOGY & DIAGNOSTIC CENTRE

CLINIC :

1/4A, Vineet Khand, (Opp Jaipuria Management)
Gomti Nagar, Lucknow - 226 010
Ph.: 0522-4008184, 4308184 • 8112323230
Mob.: 7618864441, 9450389932, 8177063877

Dr. R. P. Rastogi
M.B.B.S., M.D. (Path & Bac)



Date : 25-Nov-2023

Name : **Mr. GOKUL KUMAR**

Age : 32 Yrs.

Ref.By : APOLLO HEALTH

Sex : Male

THYROID TEST

Tri-Iodothyronine (T3)	1.90	nmol/L	0.50 to 2.50
Thyroxine (T4)	6.24	mcg/dL	5.0 to 12.5
Thyroid Stimulating Hormone (TSH)	2.08	mIU/ ml	0.3 to 6.0

COMMENTS

- 1) Primary hyperthyroidism is accompanied by elevated Serum T3 and T4 values along with depressed TSH levels.
- 2) Primary Hypothyroidism is accompanied by depressed serum T3 and T4 values and elevated serum TSH levels.
- 3) Normal T4 levels accompanied by high T3 levels are seen in patients with T3 thyrotoxicosis.
- 4) Slightly elevated T3 levels may be found in pregnancy and estrogen therapy, while depressed levels maybe encountered in severe illness, malnutrition, renal failure and during therapy with drugs like propranolol and propylthiouracil.
- 5) Elevated TSH levels may also be indicative of TSH secreting Pituitary Tumour.

Dr. Sanjay Rastogi
M.B.B.S., DCP, CRIAT (BARC)

Dr. Smity Rastogi
Contd... M.B.B.S., DCP

Results, adhering to W.H.O. and International Federation of Clinical Chemists Quality Control Standards.

SAMPLE COLLECTION FACILITY AVAILABLE

Report needs clinicopathological correlation ♦ Not for Medico Legal Purpose

e-mail : mpdcgn@gmail.com ♦ For online reports - www.modernpath.in

♦ Please ask for your computerized bill ♦ Pay only the printed collection charges



MODERN PATHOLOGY & DIAGNOSTIC CENTRE

CLINIC :
1/4A, Vineet Khand, (Opp Jaipuria Management)
Gomti Nagar, Lucknow - 226 010
Ph.: 0522-4008184, 4308184 • 8112323230
Mob.: 7618884441, 9450389932, 8177063877

Dr. R. P. Rastogi
M.B.B.S., M.D. (Path & Bact)



Date : 25-Nov-2023

Name : **Mr. GOKUL KUMAR**

Ref.By : APOLLO HEALTH

Age : 32 Yrs.

Sex : Male

Glycosylated Haemoglobin

Glycosylated Haemoglobin 5.1 % 4.5 TO 6.0

INTERPRETATION AND COMMENTS

NON DIABETIC : 4.5 to 6.0 %
GOOD CONTROL: 6.0 to 7.0
FAIR CONTROLLED 7.0 AND 8.0
UNCONTROLLED 8.0 AND ABOVE

Glycosylated haemoglobin is the adducted glucose in the haemoglobin of the red blood cells, this adduction is stable for the life time of the RBC (i.e 120 days). There fore the measure of glycosylated haemoglobin reflects the average blood glucose concentration over the preseding several weeks. The sudden change in blood glucose level would not effect the glycosylated haemoglobin level ,which serves as a better marker of long term metabolic control and the efficacy of therapy.

Dr. Sanjay Rastogi
M.B.B.S., DCP, CRIAT (BARC)

Dr. Smita Rastogi
Contd... M.B.B.S., DCP

Results, adhering to W.H.O. and International Federation of Clinical Chemists Quality Control Standards.

SAMPLE COLLECTION FACILITY AVAILABLE

Report needs clinicopathological correlation ♦ Not for Medico Legal Purpose

e-mail : mpdcgn@gmail.com ♦ For online reports - www.modernpath.in

♦ Please ask for your computerized bill ♦ Pay only the printed collection charges



MODERN PATHOLOGY & DIAGNOSTIC CENTRE

Dr. R. P. Rastogi
M.B.B.S., M.D. (Path & Bact)



CLINIC :
1/4A, Vineet Khand, (Opp Jaipuria Management)
Gomti Nagar, Lucknow - 226 010
Ph.: 0522-4008184, 4308184 • 8112323230
Mob.: 7618884441, 9450389932, 8177063877

Date : 25-Nov-2023	Age : 32 Yrs.
Name : Mr. GOKUL KUMAR	Sex : Male
Ref.By : APOLLO HEALTH	

Urine Examination

PHYSICAL		
Colour	Straw	
Turbidity	Nil	
Deposit	Nil	
Reaction	Acidic	
*Specific Gravity	1.020	
CHEMICAL		
Protein	Nil	
Sugar	Nil	
*Bile Salts	Nil	
*Bile Pigments	Nil	
Phosphate	Nil	
MICROSCOPIC		
Pus Cells	Nil	/hpf
Epithelial Cells	0-1	/hpf
Red Blood Cells	Nil	/hpf
Casts	Nil	
Crystals	Nil	
Others	Nil	

Dr. Sanjay Rastogi
M.B.B.S., DCP, CRAT (BARC)

Dr. Smriti Rastogi
M.B.B.S., DCP

Results, adhering to W.H.O. and International Federation of Clinical Chemists Quality Control Standards.

SAMPLE COLLECTION FACILITY AVAILABLE

Report needs clinicopathological correlation ♦ Not for Medico Legal Purpose

e-mail : mpdcgn@gmail.com ♦ For online reports - www.modernpath.in

♦ Please ask for your computerized bill ♦ Pay only the printed collection charges



MODERN PATHOLOGY & DIAGNOSTIC CENTRE

DIAGNOSTIC CENTRE

Dr. R. P. Rastogi
M.B.B.S., M.D. (Path & Bact)



CLINIC :

1/4A, Vineet Khand, (Opp Jaipuria Management)
Gomti Nagar, Lucknow - 226 010
Ph: 0522-4008184, 4308184 • 8112323230
Mob: 7618884441, 9450389932, 817706387



TEST REQUEST ID	:012311250015	SAMPLE DATE	:25/Nov/2023 08:53AM
NAME	:Mr. GOKUL KUMAR	SAMPLE REC. DATE	:25/Nov/2023 08:53AM
AGE/SEX	:32 YRS/MALE	REPORTED DATE	:25/Nov/2023 01:01PM
REFERRED BY	: Apollo Health and Lifestyle Limited,	BARCODE NO	:01250015

USG WHOLE ABDOMEN-MALE

Liver: is normal in size (141 mm). Parenchymal echogenicity is normal. No focal echovariant lesion is seen. Intrahepatic biliary radicles are not dilated.

Gall Bladder: is well distended. Lumen is anechoic. Wall is of normal thickness.

CBD: is normal in diameter. Portal vein is normal in diameter.

Pancreas: is normal in size, shape and echotexture. No focal echovariant lesion is seen. Pancreatic duct is not dilated.

Spleen: is normal in size (105 mm), shape and echotexture. No focal echovariant lesion is seen. Splenic vein is normal.

Both Kidneys: are normal in size (RK- 99 x 44 mm & LK -99 x 49 mm), shape, position and excursion. Parenchymal echogenicity and echotexture is normal with maintained corticomedullary differentiation. No mass, cyst or calculi is seen. Pelvicalyceal systems are not dilated. Ureters are not dilated.

Urinary bladder: is well distended. Lumen is anechoic. Wall is of normal thickness. No mass or calculus is seen.

Prostate: is normal in size (39 x 30 x 20 mms, wt = 13.0 gms), shape and echotexture. No focal echovariant lesion is seen. Prostatic capsule appears to be intact. Median lobe is not projecting in UB lumen. Both seminal vesicles appear normal.

Both iliac fossae are clear. No obvious bowel pathology is noted.
There is no free fluid in peritoneal cavity.

OPINION: NORMAL STUDY.

*** End Of Report ***

Dr. Sanjay Rastogi
M.B.B.S., DCP, CRIAT (BARC)


DR. PANKAJ UPADHYAYA
Consultant Radiologist

Dr. Smita Rastogi
M.B.B.S., DCP

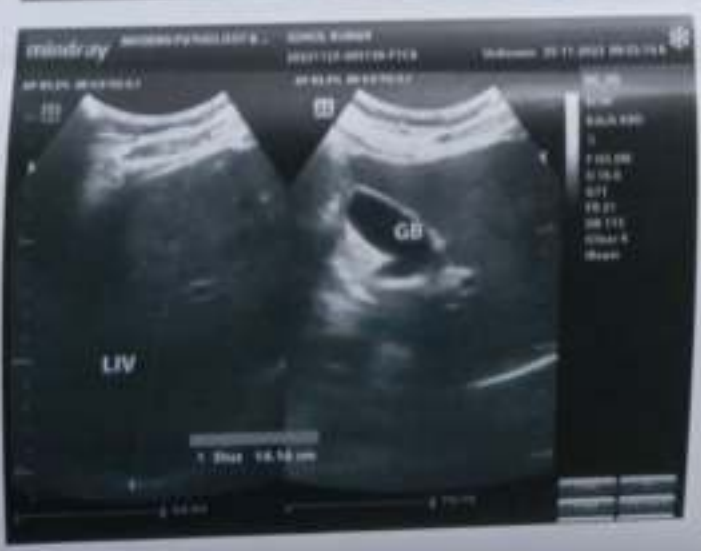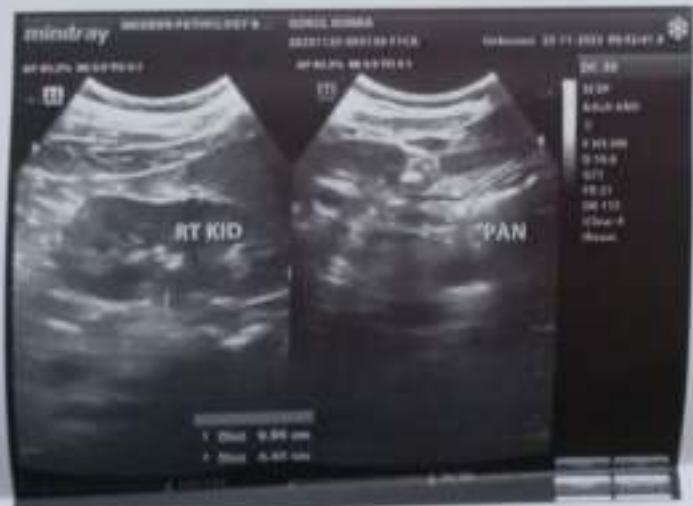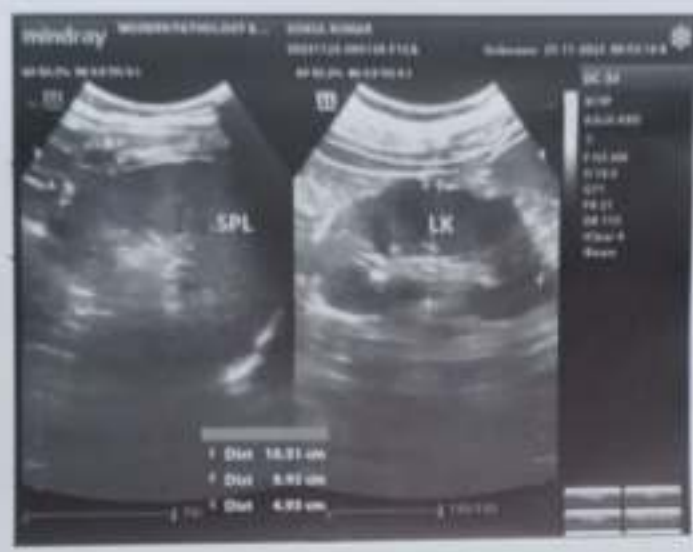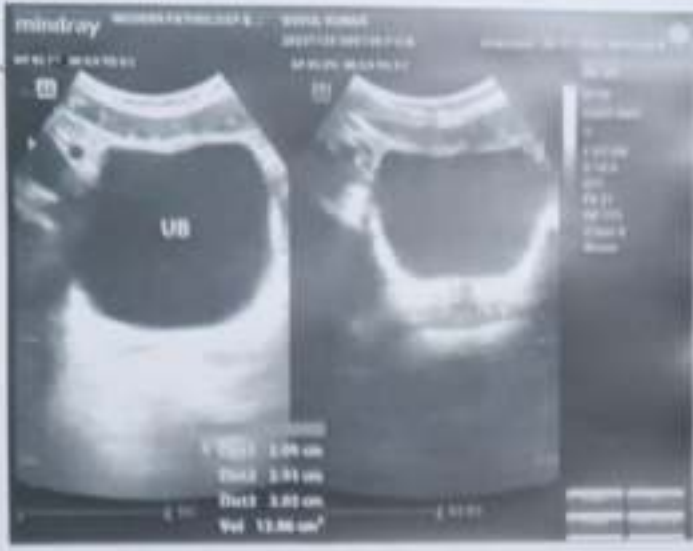Print Date: 25/11/2023 1:01 PM
Results, adhering to W.H.O. and International Federation of Clinical Chemists Quality Control Standards.

SAMPLE COLLECTION FACILITY AVAILABLE

Report needs clinicopathological correlation ♦ Not for Medico Legal Purpose

e-mail : mpdcgn@gmail.com ♦ For online reports - www.modernpath.in

♦ Please ask for your computerized bill ♦ Pay only the printed collection charges





CLINIC :
1/4A, Vineet Khand, (Opp Jaipuria Management)
Gomti Nagar, Lucknow - 226 010
Ph.: 0522-4008184, 4308184 • 8112323230
Mob.: 7618884441, 9450389932, 8177063877



TEST REQUEST ID :012311250015	SAMPLE DATE	:25/Nov/2023 08:53AM
NAME :Mr. GOKUL KUMAR	SAMPLE REC. DATE	:25/Nov/2023 08:53AM
AGE/SEX :32 YRS/MALE	REPORTED DATE	:25/Nov/2023 01:15PM
REFERRED BY : Apollo Health and Lifestyle Limited,	BARCODE NO	:01250015

XRAY CHEST PA

- Trachea is central in position.
- Bilateral lung fields are normally aerated.
- Both hilar shadows are normal.
- Both C.P. angles are clear.
- Cardiac shadow is within normal limits.
- Bony cage appears normal.

OPINION: NORMAL STUDY.

Please correlate clinically.

*** End Of Report ***

Dr. Sanjay Rastogi
M.B.B.S., DCP, CRIAT (BARC)



DR. PANKAJ UPADHYAYA

Dr. Smita Rastogi
M.B.B.S., DCP

Results, adhering to W.H.O. and International Federation of Clinical Chemists Quality Control Standards.

SAMPLE COLLECTION FACILITY AVAILABLE

Report needs clinicopathological correlation • Not for Medico Legal Purpose

e-mail : mpdcgn@gmail.com • For online reports - www.modernpath.in

• Please ask for your computerized report • Pay only the printed collection charges



MODERN PATHOLOGY & DIAGNOSTIC CENTRE

Dr. R. P. Rastogi
M.B.B.S., M.D. (Path & Bact)



CLINIC :
1/4A, Vineet Khand, (Opp Jaipuria Management)
Gomti Nagar, Lucknow - 226 010
Ph.: 0522-4008184, 4308184 • 8112323230
Mob.: 7618884441, 9450389932, 8177063877

Registration Date 25/11/2023

Age : 32 Sex: M

Name : Mr Gokul Kumar

Ref By: Apollo Health

EYES EXAMINATION REPORT

EYE SIGHT	DISTANT VISION		NEAR VISION	
	RIGHT	LEFT	RIGHT	LEFT
WITHOUT GLASSES	6/6	6/6	N-6	N-6
WITH GLASSES				
POWER OF GLASSES IF USED				
FUNDUS	NORMAL			
COLOR VISION	Present Normal according to ISHIHARA'S CHART			
PUPILS	Normally reacting to light and accommodation			

Dr. H. B. Kholia
M.B.B.S., D.O.M.S.



Dr. Sanjay Rastogi
M.B.B.S., DCP, CRIAT (BARC)

Dr. Smita Rastogi
M.B.B.S., DCP

Results, adhering to W.H.O. and International Federation of Clinical Chemists Quality Control Standards.

SAMPLE COLLECTION FACILITY AVAILABLE

Report needs clinicopathological correlation ♦ Not for Medico Legal Purpose

e-mail : mpdcgn@gmail.com ♦ For online reports - www.modernpath.in

♦ Please ask for your computerized bill ♦ Pay only the printed collection charges

Patient name: **Mr Gokul Kumar**
Ref By. **Apollo Health**


Age/Sex **32/M**
25/11/2023

E.C.G. REPORT

1. Rhythm	:	Sinus, Regular
2. Atrial Rate	:	68/mt
3. Ventricular Rate	:	68/mt
4. P – Wave	:	Normal
5. P R Interval	:	Normal
6. Q R S	:	
Axis	:	Normal
R/S Ratio	:	Normal
Configuration	:	Normal
7. Q T c Interval	:	Normal
8. S-T Segment	:	Normal
9. T-Wave	:	Normal

FINAL IMPRESSION

E.C.G. is within normal limits.


Dr. AMIT MOHAN
MD
Signature of Doctor 4559

Dr. Sanjay Rastogi
M.B.B.S., DCP, CRIAT (BARC)

Dr. Smita Rastogi
M.B.B.S., DCP

Results, adhering to W.H.O. and International Federation of Clinical Chemists Quality Control Standards.

SAMPLE COLLECTION FACILITY AVAILABLE

Report needs clinicopathological correlation ♦ Not for Medico Legal Purpose

e-mail : mpdcgn@gmail.com ♦ For online reports - www.modernpath.in

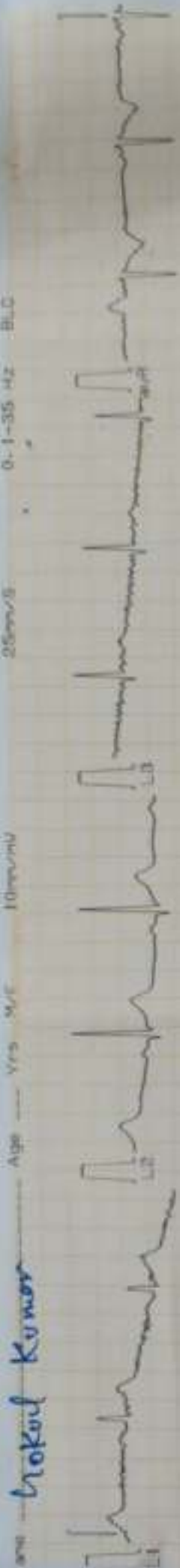♦ Please ask for your computerized bill ♦ Pay only the printed collection charges

Age --- Yrs M/F

10mm/mV

25mm/s

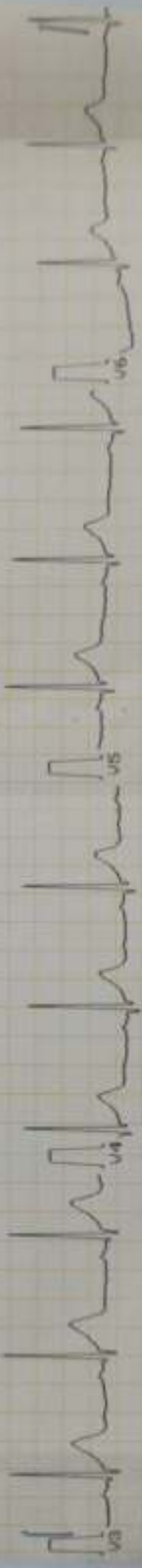

0.1-35 Hz BLD




Gokul Kumar

LAPSAKUMAR FERRUCO-114

Date




 J. AMIT MOHAN
 MD
 Reg. No. 44659

MODERN PATHOLOGY AND DIAGNOSTIC CENTER

Gomti Nagar Lucknow.

Report



GOKUL KUMAR / 31 Yrs / M / 180 Cms / 75 Kg.

Date: 25 - 11 - 2023 Refd By : APOLLO HEALTH Examined By: _____

Stage	Time	Duration	Speed(Kmph)	Elevation	METs	Rate	%THR	BP	HRP	ECG	Comments
Supine	00:04	0:04	00.0	00.0	01.0	090	48%	110/72	089	00	
Standing	00:09	0:05	00.0	00.0	01.0	090	48%	110/72	089	00	
Standing	00:13	0:04	00.0	00.0	01.0	090	48%	110/72	089	00	
HV	00:17	0:04	00.0	00.0	01.0	084	50%	110/72	102	00	
ExStart	00:28	0:09	00.0	00.0	01.0	104	55%	110/72	114	00	
BRUCE Stage 1	03:28	3:00	02.7	10.0	04.7	145	77%	110/72	159	00	
BRUCE Stage 2	06:28	3:00	04.0	12.0	07.1	169	89%	124/80	209	00	
PeakEx	06:35	0:08	05.5	14.0	07.3	169	89%	132/84	223	00	
Recovery	07:35	1:00	00.0	00.0	01.1	139	74%	132/84	183	00	
Recovery	08:35	2:00	00.0	00.0	01.0	119	63%	124/80	147	00	
Recovery	09:35	3:00	00.0	00.0	01.0	108	56%	122/80	129	00	
Recovery	09:41	3:05	00.0	00.0	01.0	088	52%	122/80	119	00	

FINDINGS :

Exercise Time : 06:09
Max HR Attained : 169 bpm 89% of Target 189
Max BP Attained : 136/88 (mm/Hg)
Max Work/Load Attained : 7.3 Fair response to induced stress
Test End Reasons : Test Complete

REPORT :

CONCLUSIONS:

1. STRESS TEST IS NEGATIVE FOR EXERCISE INDUCED ISCHAEMIC HEART DISEASE.

Dr. Anil Kumar Mishra
 Reg. No. 44559

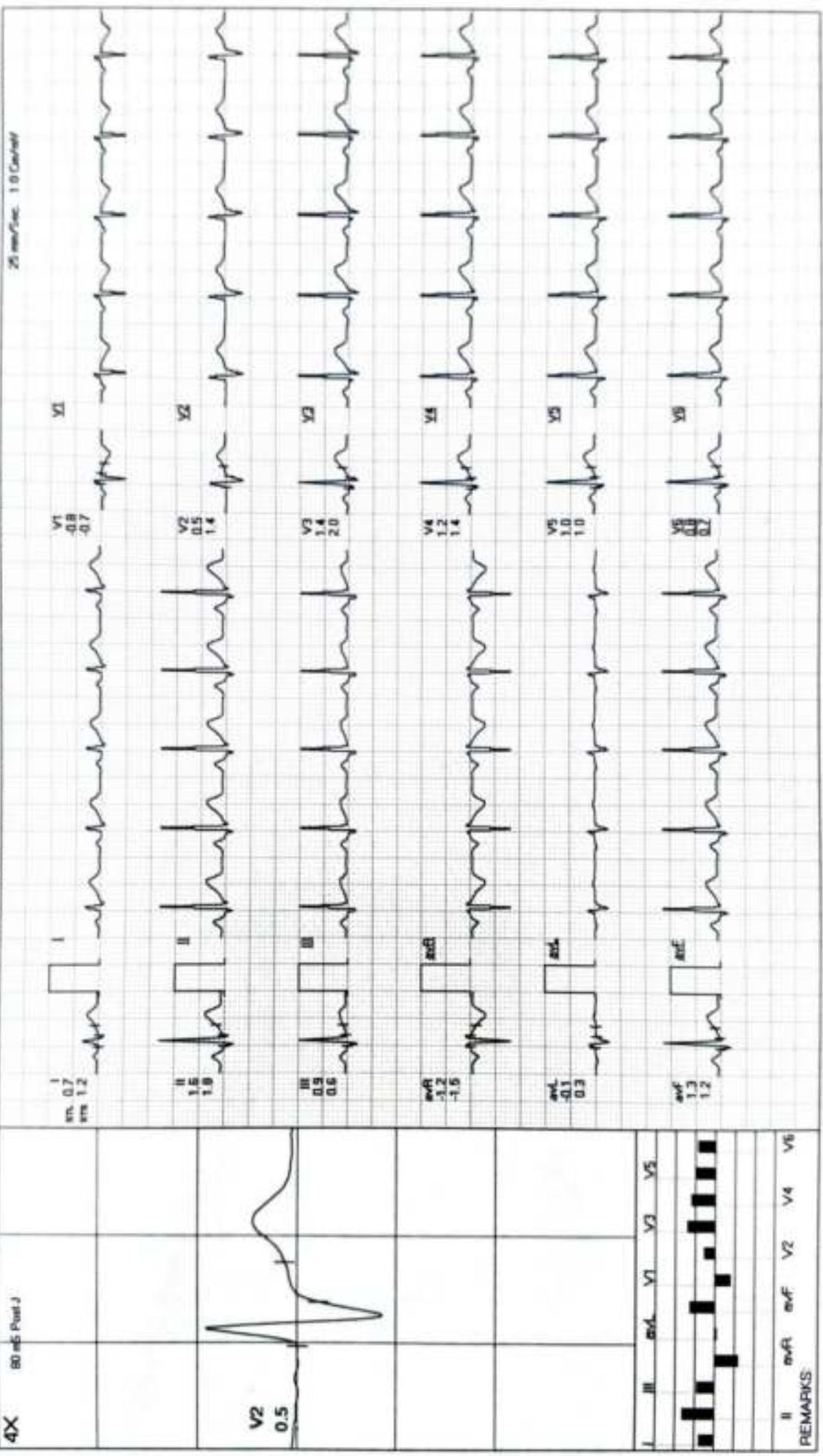
MODERN PATHOLOGY AND DIAGNOSTIC CENTER

GOKUL KUMAR / 31 Yrs / M / 160 Cms / 75 Kg / HR . 90

BRUCE:Supine(0:07)



Date: 25-11-2023 METS: 1.0/30 bpm 48% of THR BP: 110/72 mmHg Combined Medians/ BLC On/ Notch On/ HF 0.05 Hz/F 35 Hz



25 mm/sec 1.0 Cal/cm

ExtTime 00:00 0.0 Emph. 0.0%

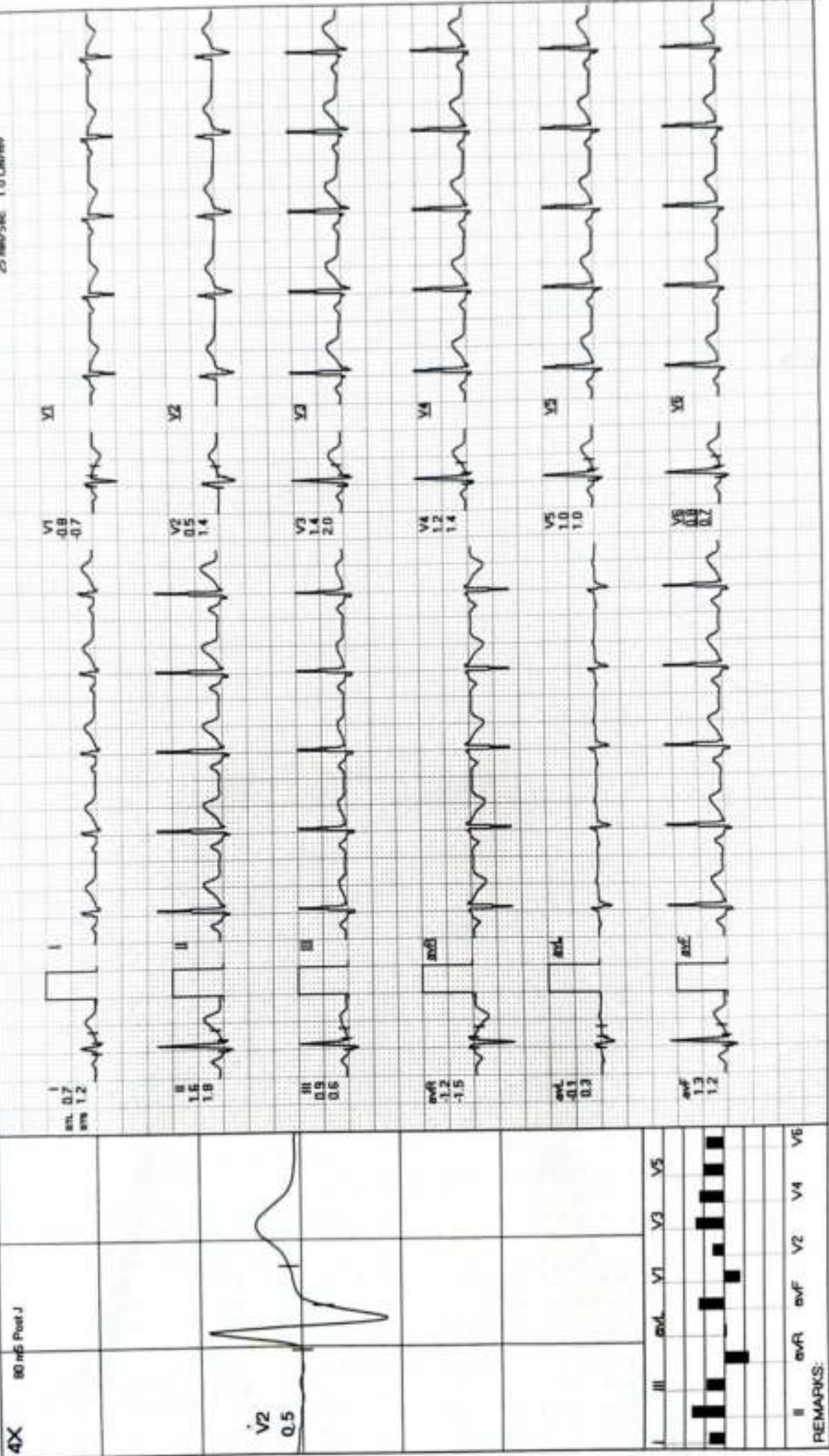
MODERN PATHOLOGY AND DIAGNOSTIC CENTER

GOKUL KUMAR / 31 Yrs / M / 180 Cms / 75 Kg / HR : 90

BRUCE: Standing(0:06)



Date: 25-11-2023 METS: 1.0/90 bpm 48% of THR BP: 110/72 mmHg Combined Mediens/BLC On/ HF 0.05 Hz/LF 35 Hz ExTime 00:00 0.0 Kmph. 0.0%
 25 mm/Sec 1.0 Cm/mV



REMARKS:

MODERN PATHOLOGY AND DIAGNOSTIC CENTER

GOKUL KUMAR / 31 Yrs / M / 180 Cms / 75 Kg / HR : 90

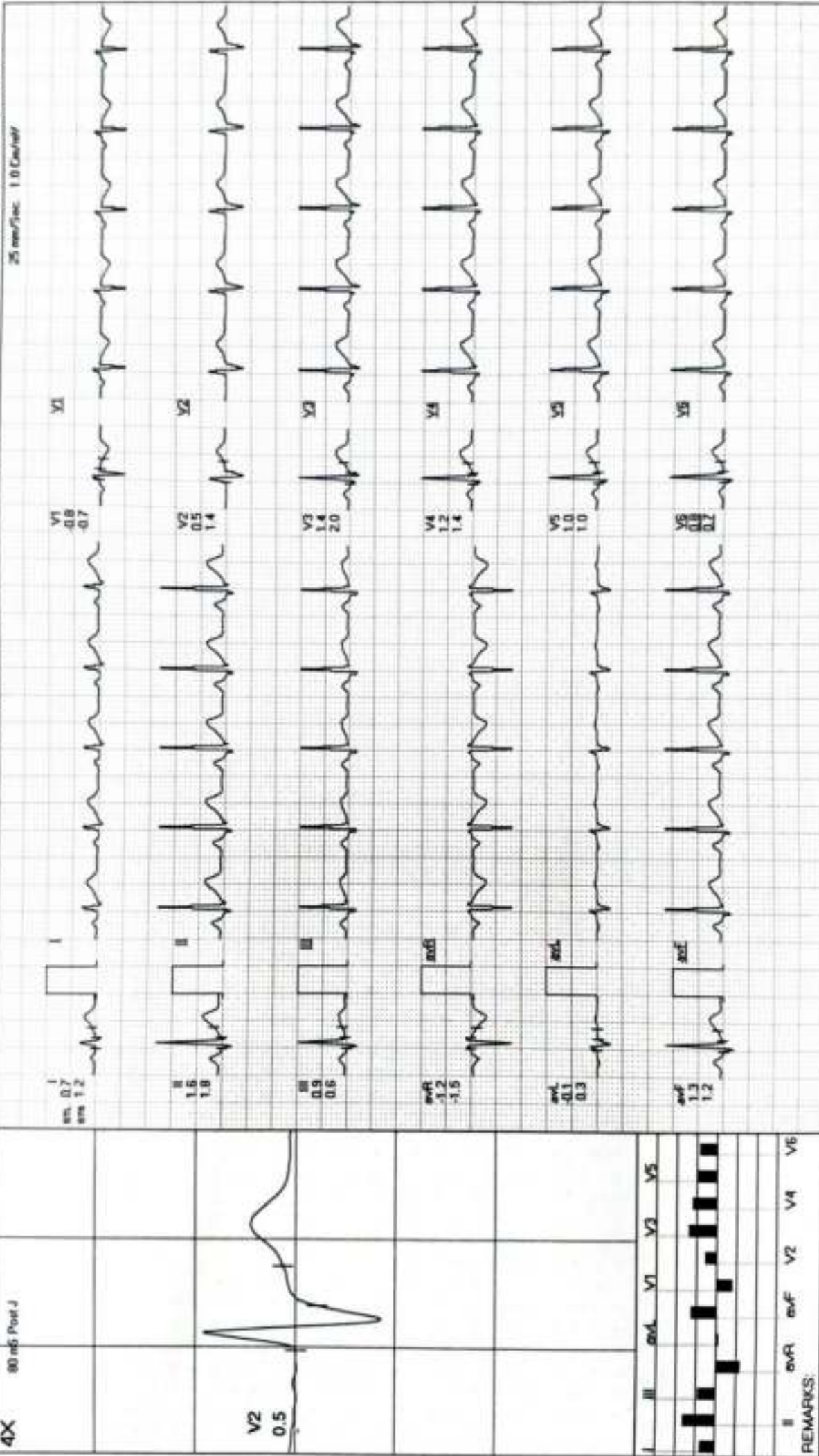
BRUCE: Standing(0:06)



Date: 25-11-2023

METS: 1.0/ 90 bpm 48% of THR BP: 110/72 mmHg Combined Medians/ BLC On/ Notch On/ HF 0.65 Hz/ LF 35 Hz

ExTime 00:00 0.0 Kmph 0.0%



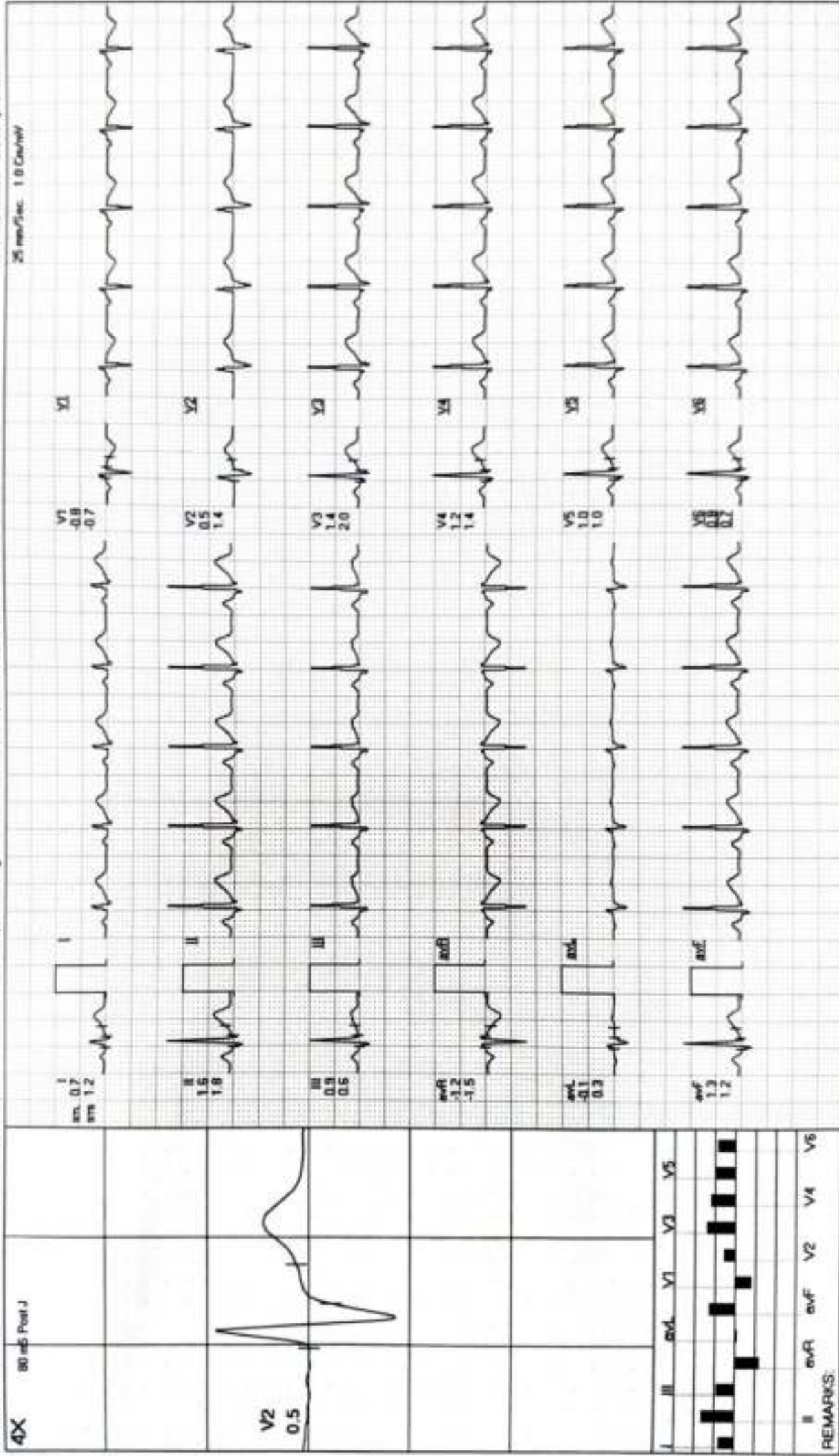
MODERN PATHOLOGY AND DIAGNOSTIC CENTER

GOKUL KUMAR / 31 Yrs / M / 180 Cms / 75 Kg / HR : 94

BRUCE:HV(0:07)



Date: 25-11-2023 METS: 1.0/94 bpm 50% of THR BP: 110/72 mmHg Combined Medians/BLC On/Notch On/HF 0.05 Hz/LF 35 Hz ExTime 00:00 0.0 Kmph 0.0%




MODERN PATHOLOGY AND DIAGNOSTIC CENTER

GOKUL KUMAR / 31 Yrs / M / 180 Cms / 75 Kg / HR - 104

ExStart



Date: 25-11-2023 METS: 1.0/104 bpm 55% of THR BP: 110/72 mmHg Combined Medians/BLC Oxy/Notch Oxy/HF 0.05 H/L/F 35 Hz
 4X 80 mS Post J 25 mm/sec 1.0 Cm/mV ExTime 00:00 0.0 Kmph 0.0%

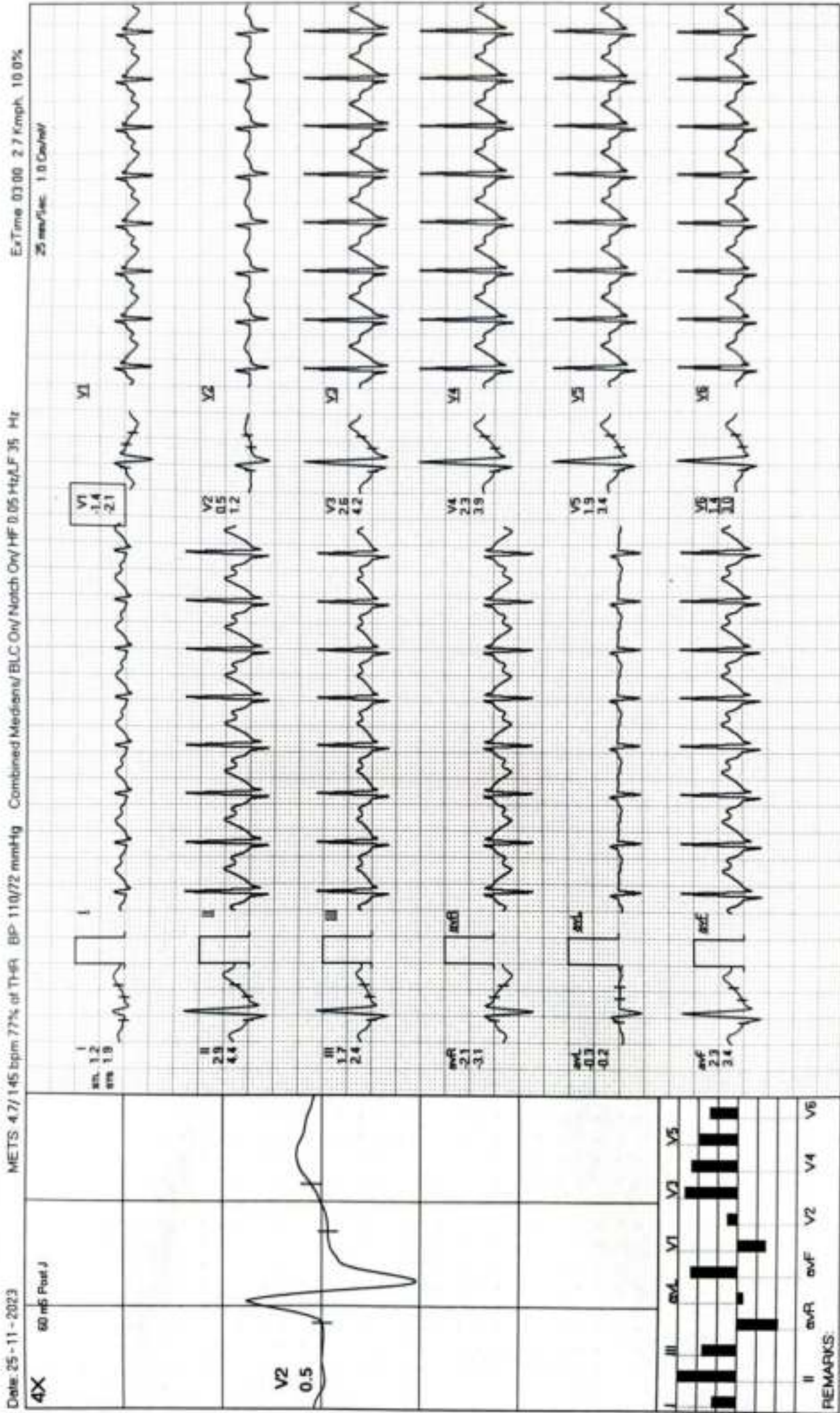


REMARKS: II avR avF V2 V4 V6

MODERN PATHOLOGY AND DIAGNOSTIC CENTER

GOKUL KUMAR / 31 Yrs / M / 180 Cms / 75 Kg / HR : 145

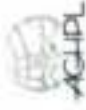
BRUCE: Stage 1 (3:00)



MODERN PATHOLOGY AND DIAGNOSTIC CENTER

GOKUL KUMAR / 31 Yrs / M / 180 Cms / 75 Kg / HR : 169

BRUCE: Stage 2(3:00)




MODERN PATHOLOGY AND DIAGNOSTIC CENTER

GOKUL KUMAR / 31 Yrs / M / 180 Cms / 75 Kg / HR : 169

PeakEx



Date: 25-11-2023 METS: 7.3/169 bpm 89% of THR BP: 132/84 mmHg Combined Medians/BLC On/ Notch On/ HF 0.05 Hz/LF 35 Hz



ExTime 06:09 5.5 Km/Ph 14.0%

25 mm/sec 1.0 Cm/mV

MODERN PATHOLOGY AND DIAGNOSTIC CENTER

GOKUL KUMAR / 31 Yrs / M / 180 Cms / 75 Kg / HR : 139

Recovery(1:00)

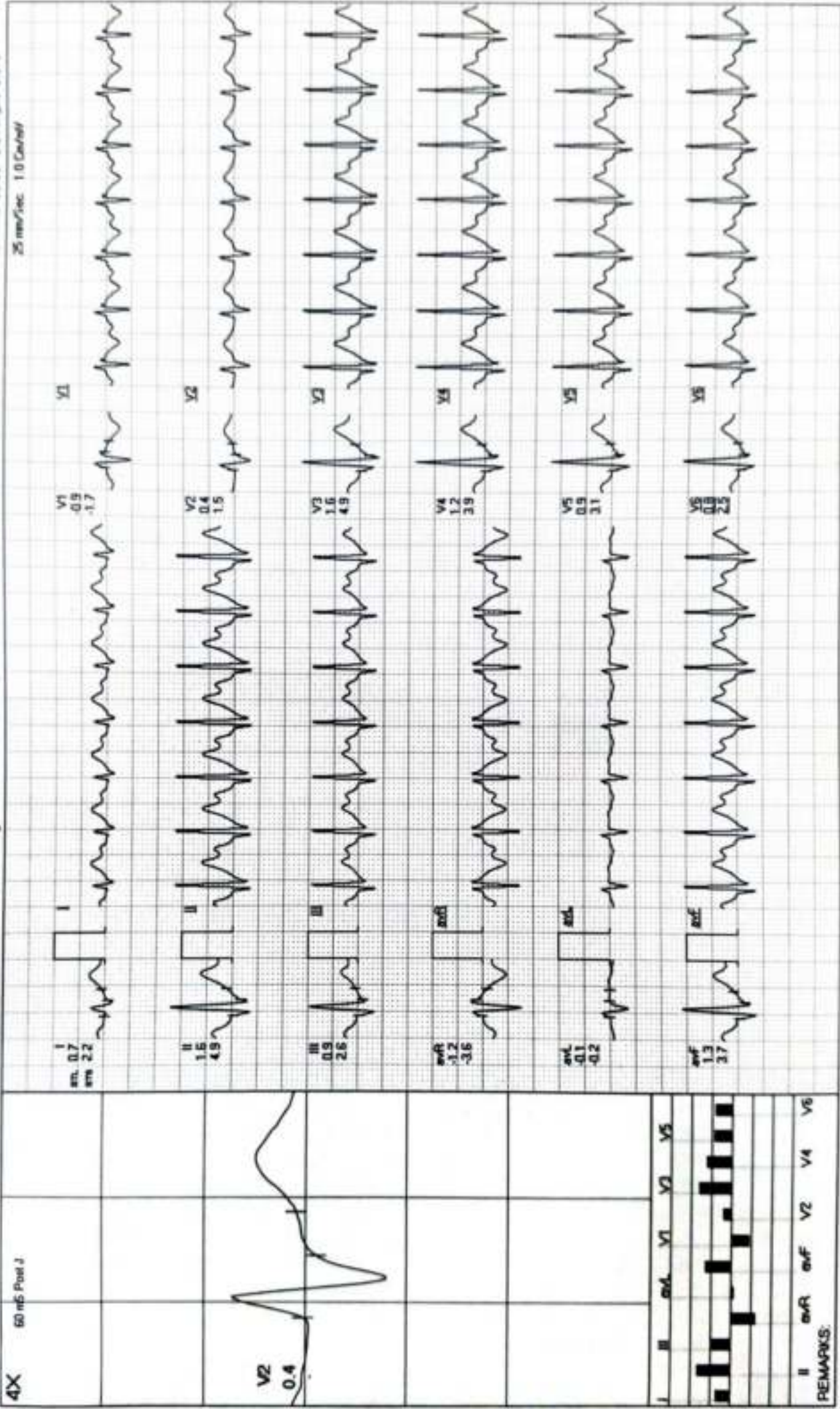


Date: 25-11-2023

METS: 1.1 / 139 bpm 74% of THR BP: 132/84 mmHg Combined Medians/EKG Only/Notch On/HF 0.05 Hz/LF 35 Hz

ExTime 06:09 0.0 Km/h 0.0%

4X 60 mS Post J



REMARKS:

MODERN PATHOLOGY AND DIAGNOSTIC CENTER

GOKUL KUMAR / 31 Yrs / M / 180 Cms / 75 Kg / HR : 119

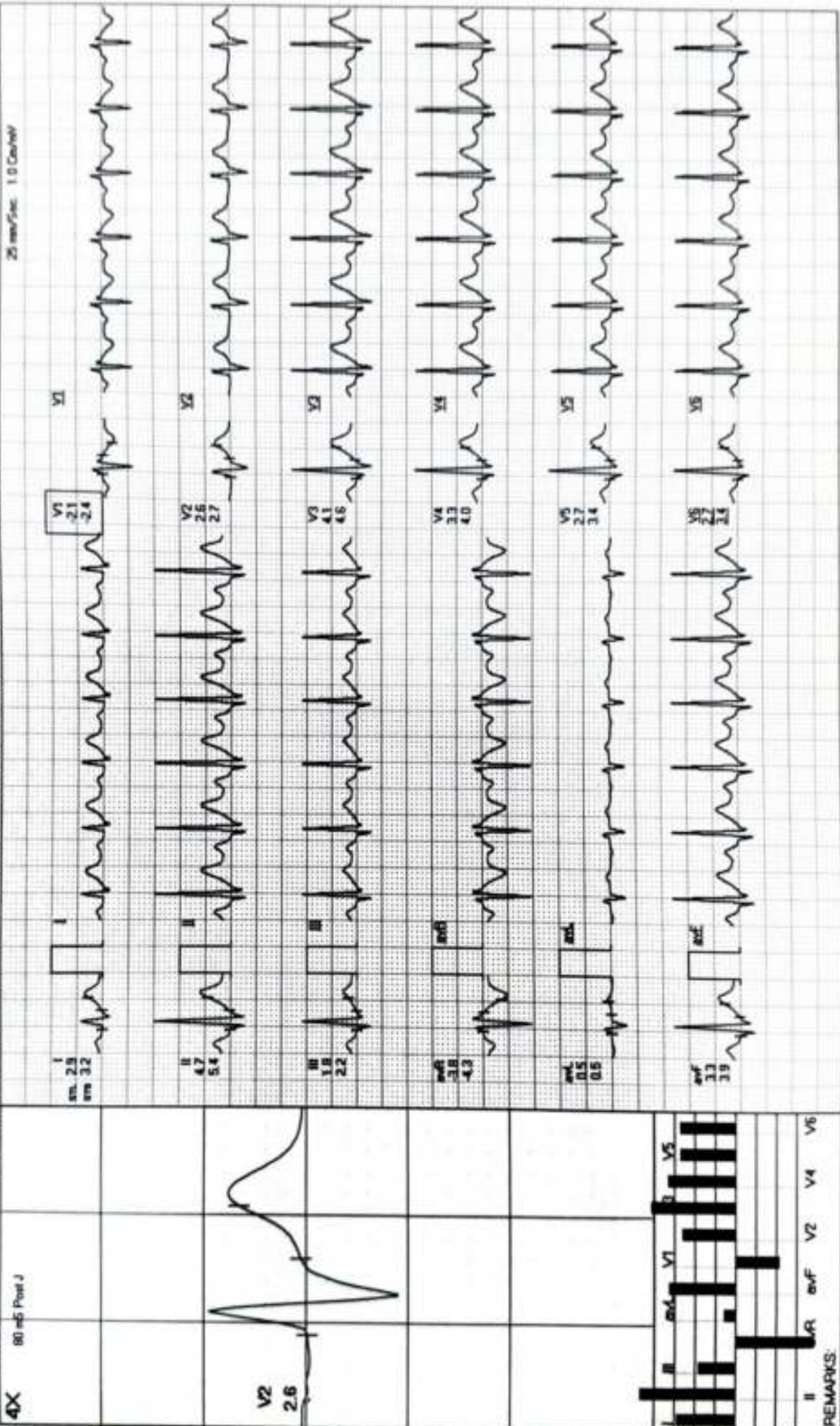Recovery(2:00)



Date: 25-11-2023 METS: 1.0/119 bpm 63% of THR BP: 124/80 mmHg Combined Mediana/ BLC On/ HF 0.05 Hz/ LF 35 Hz

ExTime: 06:09 0.0 Kmph 0.0%

25 mm/Sec 1.0 Cm/mV



REMARKS:


MODERN PATHOLOGY AND DIAGNOSTIC CENTER

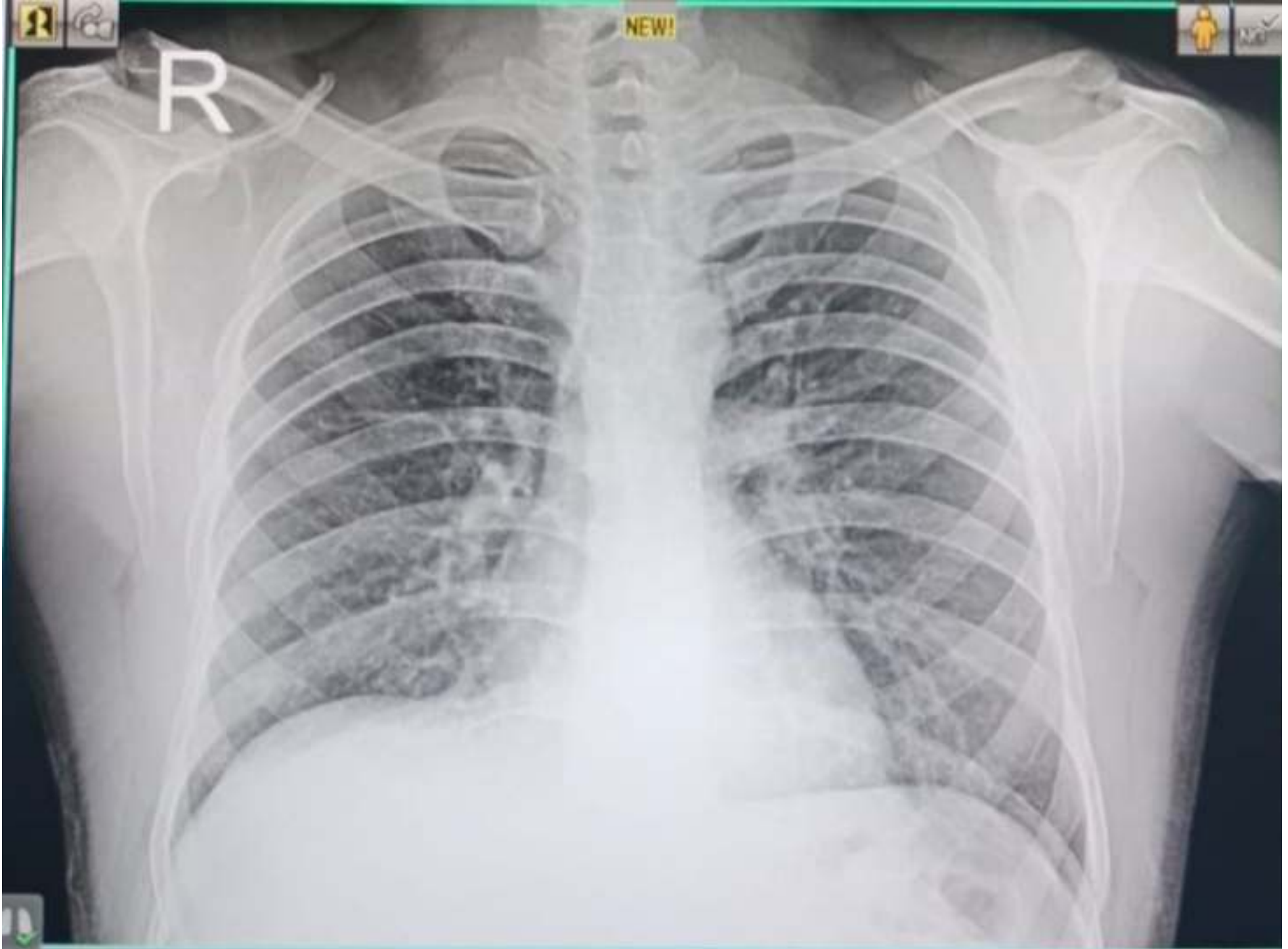GOKUL KUMAR / 31 Yrs / M / 180 Cms / 75 Kg / HR : 106

Recovery(3:00)



Date: 25-11-2023 METS: 1.0/106 bpm 56% of THR BP: 122/80 mmHg Combined Medians/BLC On/Notch On/HF 0.05 Hz/LF 35 Hz ExTime 06:09 0.0 Km/Ph. 0.0%





23112502648 MR GOKUL KUMAR 32 YRS M DR SELF CHEST PA
11/25/2023 MODERN PATHOLOGY & DIAGNOSTIC CENTRE GOMTI NAGAR LUCKNOW