

MYSORE-BALLAL CIRCLE



H - 163 cms

W - 62.4 kgs

BP - 120/80

Pulse - 68 bpm

Hif - 34 cms

Weight - 31 cms

--- A MEDALL COMPANY ---

Date 28-May-2022 9:11 AM

Customer Name : MR. P NARAYANAN

DOB : 04 Jul 1988

Ref Dr Name : MediWheel

Age : 33Y/MALE

Customer Id : MED111123150

Visit ID : 712216188

Email Id :

Phone No : 9952809697

Corp Name : MediWheel

Address :

Package Name : Mediwheel Full Body Health Checkup Male Below 40

S.No	Modality	Study	Accession No	Time	Seq	Signature
1	LAB	URINE GLUCOSE - FASTING				
2	LAB	URINE GLUCOSE - POSTPRANDIAL (2 Hrs)				
3	LAB	COMPLETE BLOOD COUNT WITH ESR				
4	LAB	THYROID PROFILE/ TFT(T3, T4, TSH)				
5	LAB	STOOL ANALYSIS - ROUTINE				
6	LAB	BLOOD UREA NITROGEN (BUN)				
7	LAB	GLUCOSE - FASTING				
8	LAB	GLUCOSE - POSTPRANDIAL (2 HRS)				
9	LAB	GLYCOSYLATED HAEMOGLOBIN (HbA1c)				
10	LAB	LIPID PROFILE				
11	LAB	LIVER FUNCTION TEST (LFT)				
12	LAB	URIC ACID				
13	LAB	URINE ROUTINE				
14	LAB	CREATININE				
15	LAB	BLOOD GROUP & RH TYPE (Forward Reverse)				

Patient Details Print Page

		BUN/CREATININE RATIO			
	OTHERS	physical examination	MYS2680891102651		
	JS	ULTRASOUND ABDOMEN	MYS2680891103462	Ground Floor	
	OTHERS	Treadmill / 2D Echo ECHO	MYS2680891127528	1st floor W/O	
20	OTHERS	EYE CHECKUP	MYS2680891135592		
21	X-RAY	X RAY CHEST ✓	MYS2680891145199		
22	OTHERS	Consultation Physician	MYS2680891148004	1st Floor	
23	ECHO	ELECTROCARDIOGRAM ECG	MYS2680891149333		

done

9

Registered By

(R.SUNILKUMAR)

MEDICAL



NETHRADHAMA SUPER SPECIALITY EYE HOSPITAL

(A Unit of Nethradhama Hospitals Pvt. Ltd.)

OPD SHEET

Date : 28/05/2020

Patient's Name : Mr. Narayanan P

OP No. 1195890

33/m

1140PM

Dr. Roopashree. C.R
MBBS, MS, FPRS
Consultant-Phaco & Refractive
KMC No : 105152

for Medical Certificate
(BE)

13
IOP 11

of E, A/S, BE WNL

6/6 N6
BCVA 6/6 N6

Fundus: BE CD R O.S
(PP) FR (+)

38/38

Adv.
- R/W SOS / 2yrs
R

Color Vision 38/38

FITNESS CERTIFICATE


NAME: P. Narayanan	AGE: 33	
Ht: 163 CMS	Wt: 62 KGS	SEX: Male

PARAMETERS	MEASUREMENTS
PULSE / BP (supine)	68 / mt / /mmHg 120/80
INSPIRATION	35 in
EXPIRATION	34 in
CHEST CIRCUMFERENCE	35 in
PREVIOUS ILLNESS	none
VISION	
FAMILY HISTORY	FATHER: / MOTHER: /

REPORTS: Within normal limits

DATE: 29/05/2022

PLACE: Mysuru



CONSULTANT PHYSICIAN

Dr. NIKHIL. B.

M.D., D.M.(Cardiologist)
Interventional Cardiologist
KMC Reg. No.: 90111

(P. Narayanan)

Customer Name	MR. P NARAYANAN	Customer ID	MED111123150
Age & Gender	33Y/MALE	Visit Date	28/05/2022
Ref Doctor	MediWheel		

2 D ECHOCARDIOGRAPHIC STUDY

M mode measurement:

AORTA	:	2.6cms
LEFT ATRIUM	:	2.7cms
LEFT VENTRICLE (DIASTOLE)	:	4.3cms
(SYSTOLE)	:	2.6cms
VENTRICULAR SEPTUM (DIASTOLE)	:	0.8cms
(SYSTOLE)	:	1.0cms
POSTERIOR WALL (DIASTOLE)	:	0.8cms
(SYSTOLE)	:	1.1cms
EDV	:	71ml
ESV	:	28ml
FRACTIONAL SHORTENING	:	37%
EJECTION FRACTION	:	61%
RVID	:	1.5cms

DOPPLER MEASUREMENTS:

MITRAL VALVE	:	'E' - 0.77m/s	'A' - 0.26 m/s	NO MR
AORTIC VALVE	:	1.01m/s		NO AR
TRICUSPID VALVE	:	'E' - 0.71m/s	'A' - 0.45m/s	NO TR
PULMONARY VALVE	:	0.75m/s		NO PR

Customer Name	MR. P NARAYANAN	Customer ID	MED111123150
Age & Gender	33Y/MALE	Visit Date	28/05/2022
Ref Doctor	MediWheel		

2D ECHOCARDIOGRAPHY FINDINGS:

Left ventricle : Normal size, Normal systolic function.
No regional wall motion abnormalities.

Left Atrium : Normal.

Right Ventricle : Normal.

Right Atrium : Normal.

Mitral valve : Normal, No mitral valve prolapsed.

Aortic valve : Normal, Trileaflet.

Tricuspid valve : Normal.

Pulmonary valve : Normal.


IAS : Intact.

IVS : Intact.

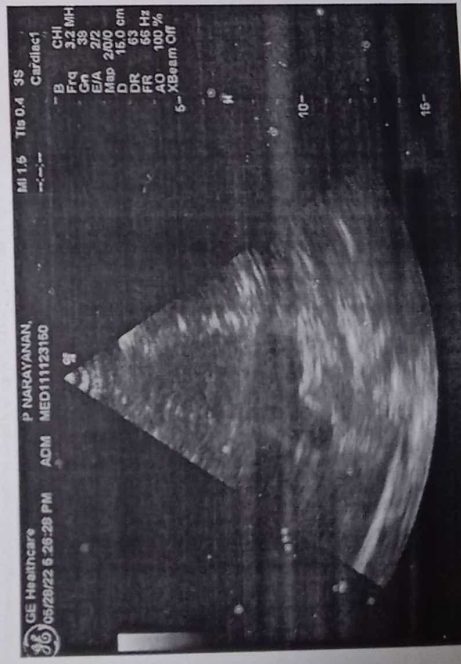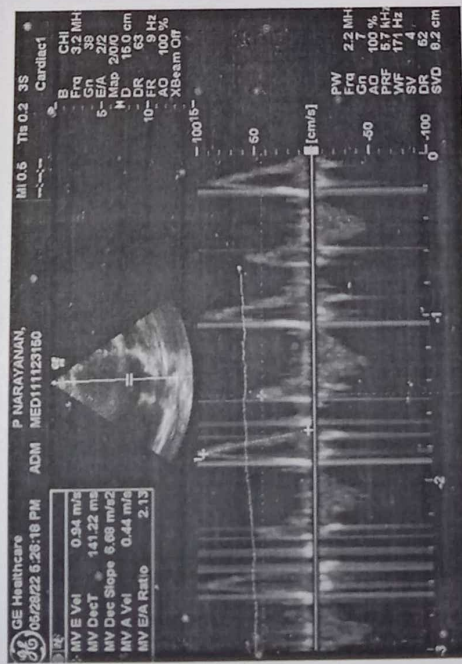
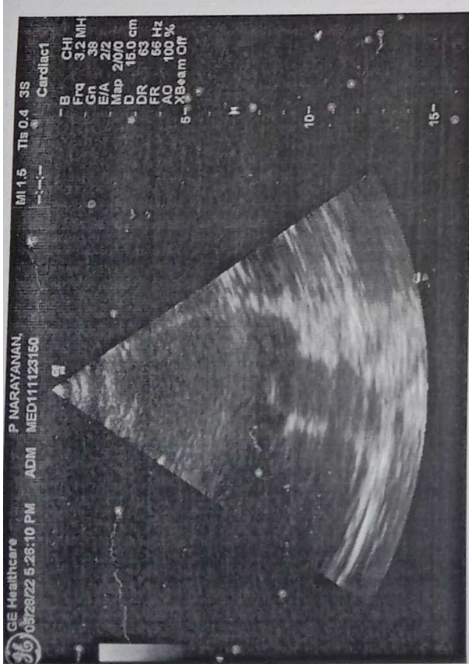
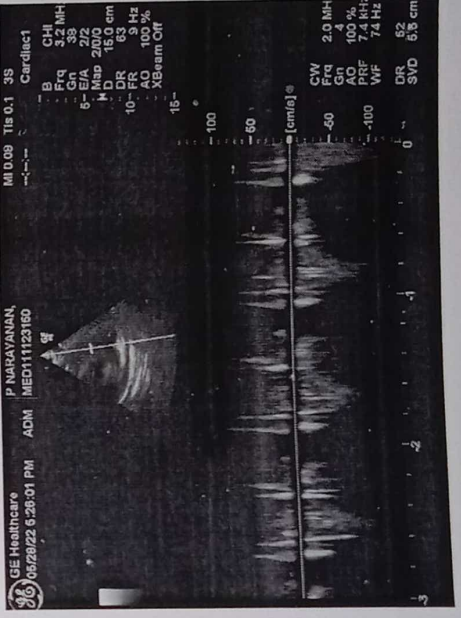
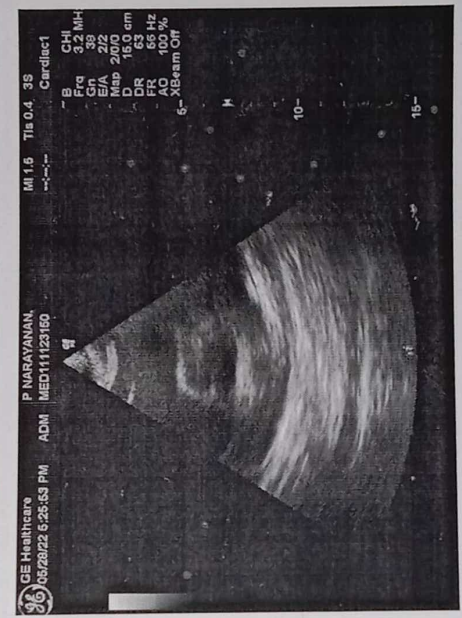
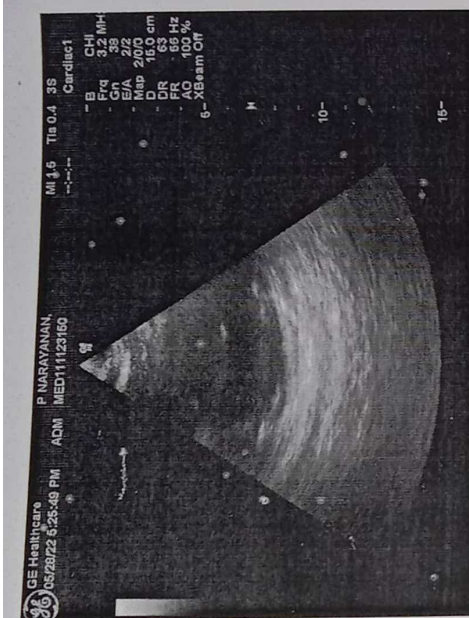
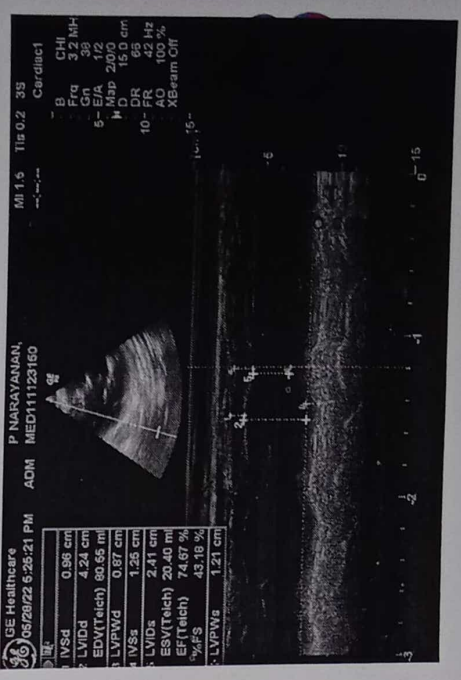
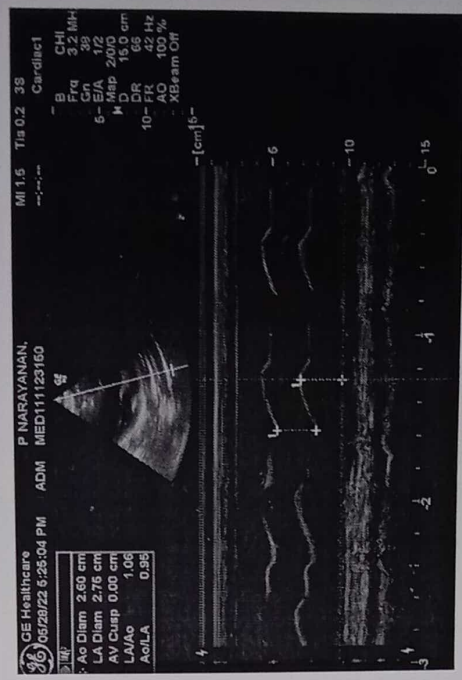
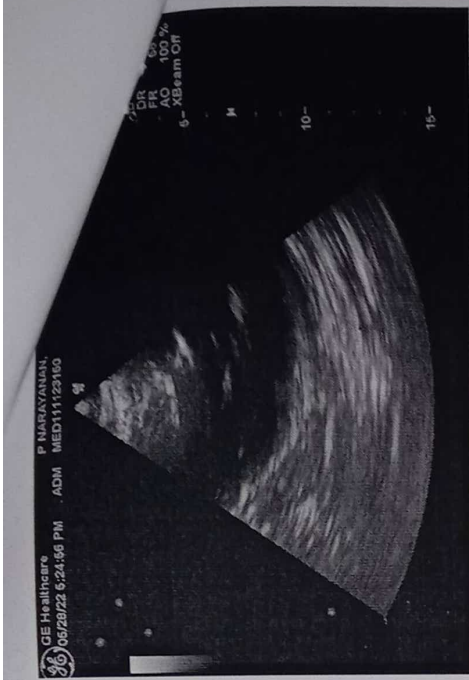Pericardium : No pericardial effusion.

IMPRESSION:

- NORMAL SIZED CARDIAC CHAMBERS.
- NORMAL LV SYSTOLIC FUNCTION. EF:61%.
- NO REGIONAL WALL MOTION ABNORMALITIES.
- NORMAL VALVES.
- NO CLOTS/ PERICARDIAL EFFUSION VEGETATION.



DR. NIKHIL B
INTERVENTIONAL CARDIOLOGIST
NB/SA



Customer Name	MR. P NARAYANAN	Customer ID	MED111123150
Age & Gender	33Y/MALE	Visit Date	28/05/2022
Ref Doctor	MediWheel		

ABDOMINO-PELVIC ULTRASONOGRAPHY

LIVER is normal in shape, size and has uniform echopattern.

No evidence of focal lesion or intrahepatic biliary ductal dilatation.

Hepatic and portal vein radicals are normal.

GALL BLADDER show normal shape and has clear contents.

Gall bladder wall is of normal thickness. CBD is of normal calibre.

PANCREAS has normal shape, size and uniform echopattern.

No evidence of ductal dilatation or calcification.

SPLEEN show normal shape, size and echopattern.

KIDNEYS move well with respiration and have normal shape, size and echopattern.

Cortico- medullary differentiations are well madeout.

No evidence of calculus or hydronephrosis.

	Bipolar length (cms)	Parenchymal thickness (cms)
Right Kidney	8.7	1.6
Left Kidney	9.3	1.6

URINARY BLADDER show normal shape and wall thickness.

It has clear contents. No evidence of diverticula.

PROSTATE shows normal shape, size and echopattern.

No evidence of ascites.


IMPRESSION:

➤ **ESSENTIALLY NORMAL STUDY.**

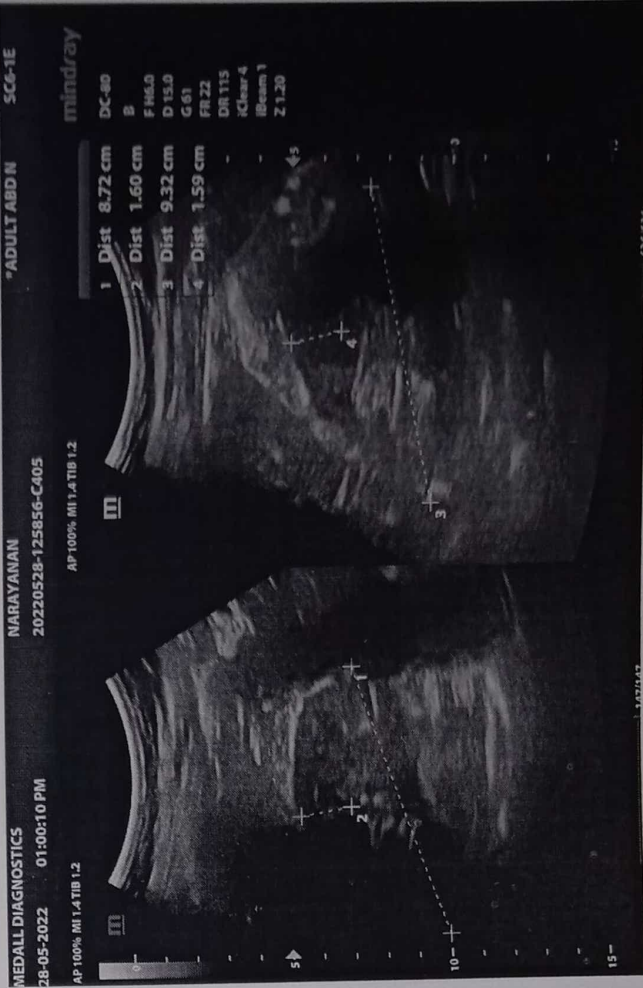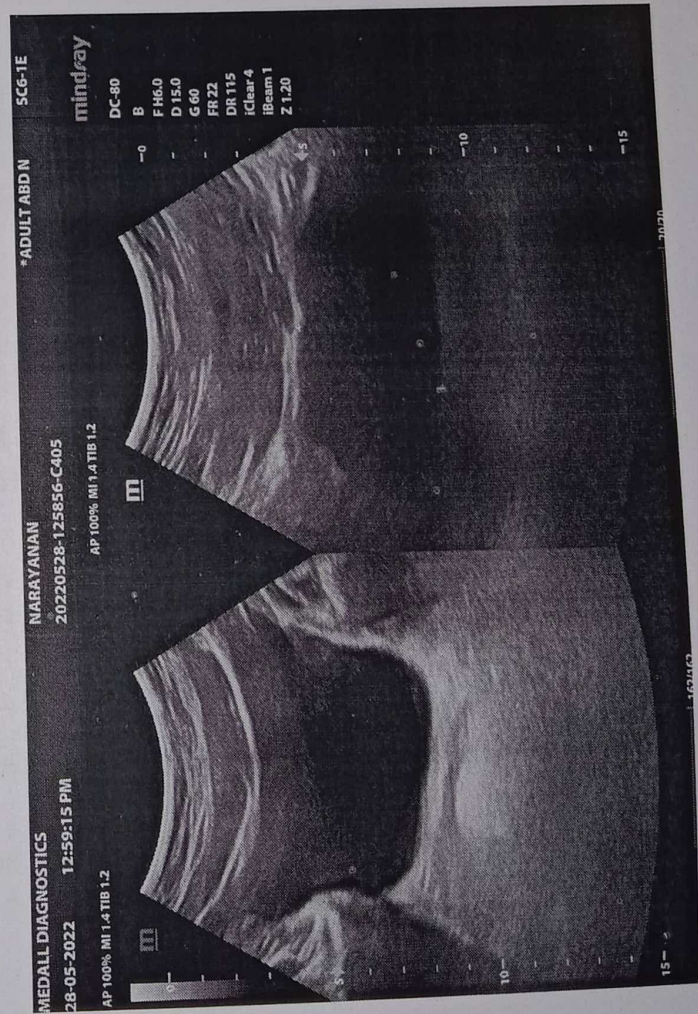
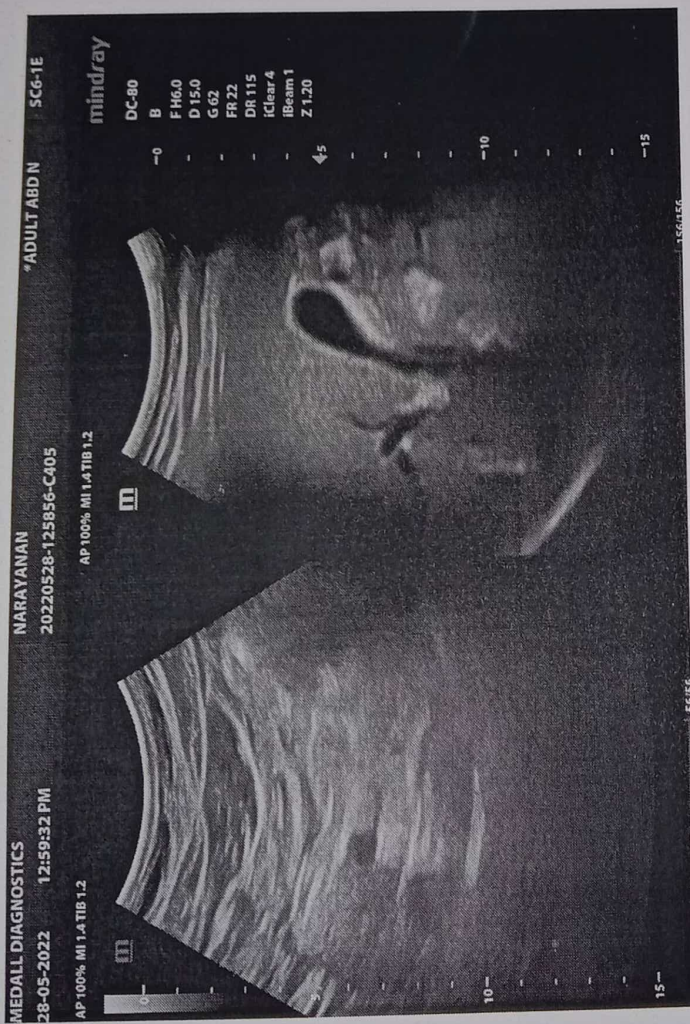
CONSULTANT RADIOLOGISTS

DR. ANITHA ADARSH

MB/sv

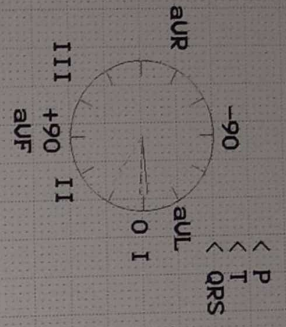


DR. MOHAN B



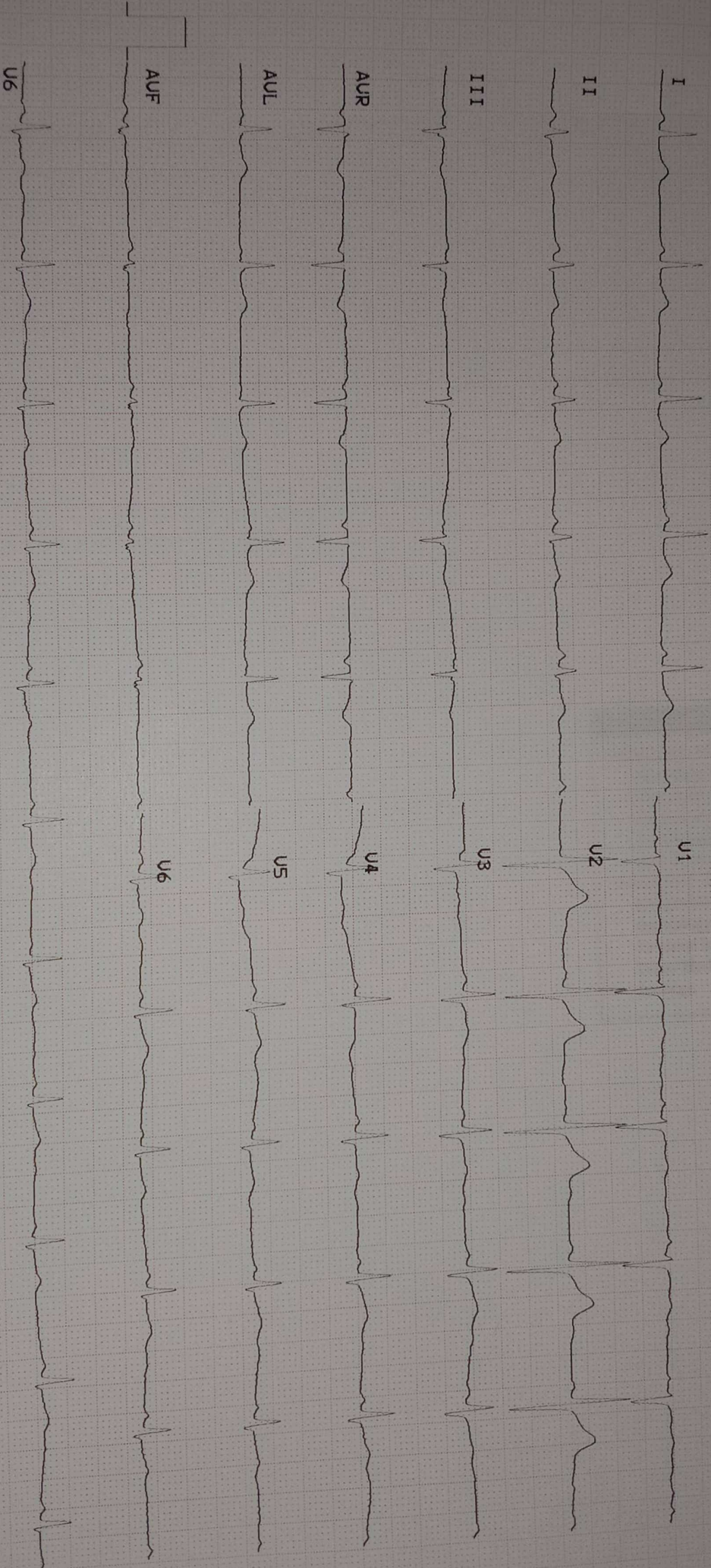
Male

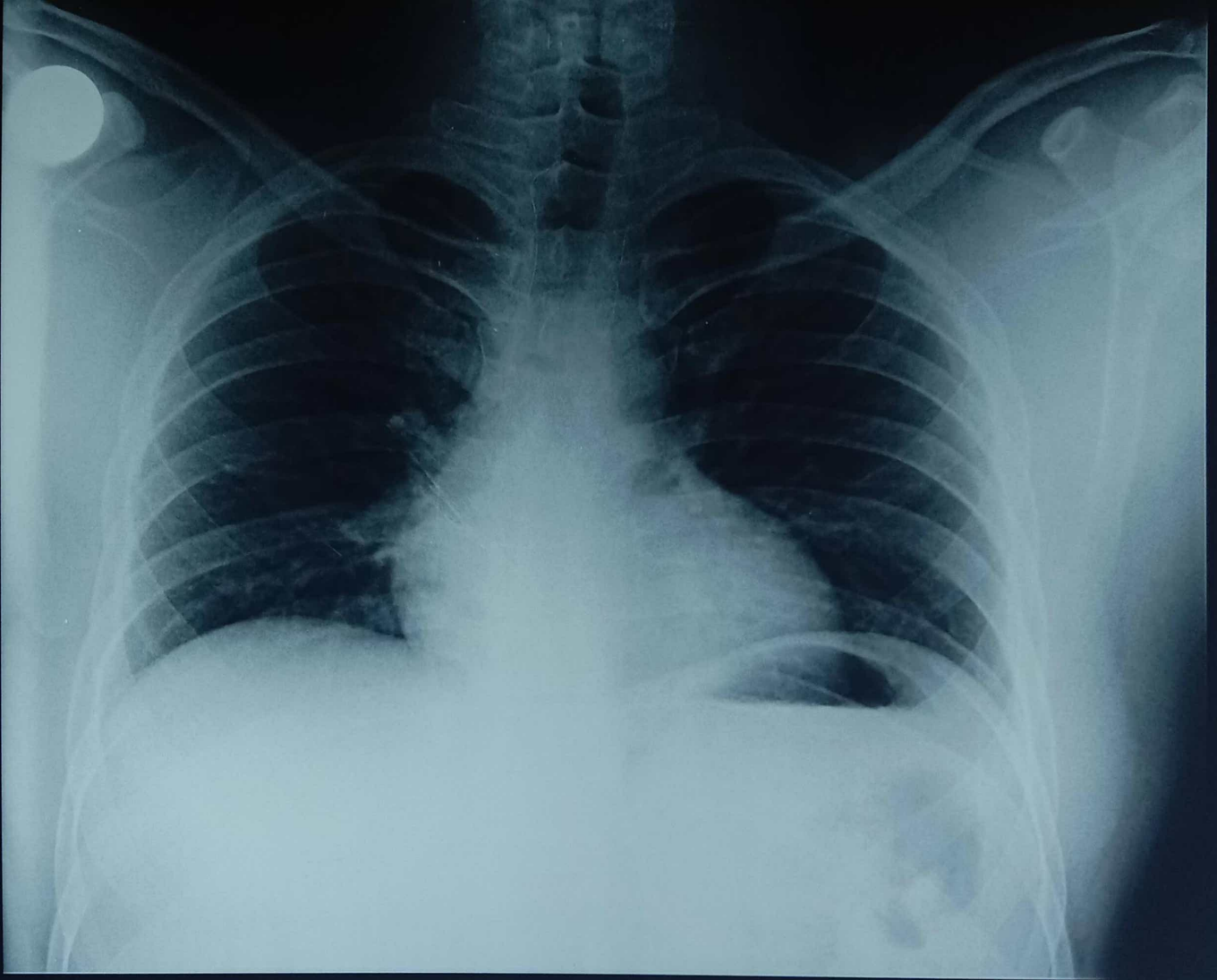
AGE: 33
 Measurement Results:
 QRS : 90 ms
 QT/QTcB : 400 / 417 ms
 PR : 132 ms
 P : 102 ms
 RR/PP : 922 / 925 ms
 P/QRS/T : 35 / -5 / 5 degrees
 QTd/QTcBD : 26 / 27 ms
 Sokolow : 1.2 mV
 NK : 9



Interpretation: *Normal sinus rhythm*
 minor left axis deviation
 R/S inversion area between U1 and U2
 probably normal ECG
Whe

Unconfirmed report.





P NARAYANAN 33 MED111123150 M CHEST PA 5/28/2022 10:50 AM
MEDALL CLUMAX DIAGNOSTIC