



Rakhi 53/F.

11/3/23

Vitals :

Chief Complaints :

For. Routine Gynae check up.

Menopausal for 1 yr.

No H/o Bleed'g P/V.

H/O Present Illness :

GH - 2 FTLSCS.
Last child. 2003.

Past History :

P/A Self

P/S ~~CA~~

Investigation :

Drug Allergies : (if any)

P/V. All Rvns fine for
PAP. Smear
taken

Treatment :



Date - 11/3/23



ophthal

MR No - 673587
 Pt - Rakhi Jaitly
 Age - 53 Y/F

Health checkup

Vitals :

Chief Complaints :

Routine checkup

BP:- 120/80 mmHg

Wt:- 91.6 Kg

Height:- 5'6" inch

H/O Present Illness :

Vu / 6/6
 Vu / 6/6

Past History :

NV / - N6
 - N6 glasses

Investigation :

Drug Allergies : (if any)

Treatment :

Colour Vision - NCT /
 Normal (BE)

fundus Examination - WNL



Gurgaon

Q Block South City 11, Sohna Road, Main Sector-47, Gurgaon, Haryana Ph: 0124-4500000 Fax: 0124-2218733
 E-mail: parkmedicenters@gmail.com

• West Delhi • South Delhi • Faridabad • Panipat • Karnal



Dr. PRIYANKA



Park Hospital

GROUP SUPER SPECIALITY HOSPITAL

RAKHI/53/F

11/3/23

S/B DERMATOLOGY

Adv:

? LICHENIFIED
DERMATITIS
? PSORIASIFORM
DERMATITIS

full legs EXCELA MAX
LOTION
2 3 week

Skin Biopsy

XERINA Cream
(2/A) (M) 2 3 weeks

TOPICAL 6%
Ointment
(2/A) (N) 2 10 days

Cap. HH Omega
once daily

Rp. eye 2 15 days
10 days



(This is only professional opinion and not the diagnosis, please correlate clinically)



Cert No. H-2019-0369 Cert No. MC-4830

Q Block, South City -II, Sohna Road, Sector-47, Gurgaon, Haryana
Ph.: 0124-4900000 (100 Lines), Toll Free No.: 1800-102-6767, Mob.: 62 62 82 82 35, Email: customercare@parkhospital.in

PARK GROUP OF HOSPITALS : West Delhi / Gurugram / Faridabad / Sonapat / Panipat / Karnal / Ambala / Patiala / Behror / Jaipur

the health care providers

the health care providers



Ear (L) ear wax (+)
TM not seen.



Vitals :

Chief Complaints :

Ear - wax

H/O Present Illness :

Nose - Bilateral turbinate hypertrophy

Past History :

Septum - midline

Investigation :

Drug Allergies : (if any)

Treatment :

~~Ado~~

~~PTA~~

Ado

• Clearwax ear drops 4-4-4-4 x 5 day.



[Signature]
11/3/23

Gurgaon

Q Block South City 11, Sohna Road, Main Sector-47, Gurgaon, Haryana Ph.: 0124-49000000 Fax : 0124-2218733
E-mail : parkmedicenters@gmail.com

• West Delhi • South Delhi • Faridabad • Panipat • Karnal





Miss Rakhi Gargely, 53/F.

Pt Has come for routine health check up

Now H10 T2DM, HTN, Hypothyroidism

H10 Fatty liver in previous scans.

Pt is vaccinated with
covid - 2 doses.

O/E

Patient is conscious, alert

P^oJ^oC Xanthelasma (+)

Chest - B/L vesicular B/s

CVS - S1S2 (+)

BP - 116/90 mm of Hg

ECG - Sinus Bradycardia

Adv

1. Anti TPO Antibody.



Cert No. N-2016-0369 Cert No. MC-4870

(This is only professional opinion and not the diagnosis, please correlate clinically)

O Block, South City -II, Sohna Road, Sector-47, Gurgaon, Haryana

Ph.: 0124-4900000 (100 Lines), Toll Free No. : 1800-102-6767, Mob.: 62 62 82 82 35, Email: customercare@parkhospital.in

PARK GROUP OF HOSPITALS : West Delhi - Gurugram - Faridabad - Sonapat - Panipat - Karnal - Ambala - Patiala - Behror - Jaipur

the **health** care providers

the **health** care providers





DEPARTMENT OF PATHOLOGY

| | |
|---|---|
| Patient Name : Mrs. RAKHI JAITLEY | Bill Date : 11/03/2023 9.11 AM |
| MR No : 673587 | Sample Col Dt/Tm : 11/03/2023 09:59 am |
| Age/Sex : 53 Years 7 Months 21 Days / Female | Sample Rec Dt/Tm : 11/03/2023 09:47 am |
| Type : OPD | Reporting Date : 2023-03-11 00:28:08-01 11:22: |
| TPA/Corporate : MEDIWHEEL PVT LTD | Sample ID : 109707 |
| Ref Doctor : Dr.RMO | Bill/Req. No. : 24055502 |

| Test | Result | Bio. Ref. Interval | Units | Method |
|----------------------------|--------|--------------------|-------|--------------|
| BLOOD SUGAR FASTING | | | | |
| PLASMA GLUCOSE FASTING | 97 | 60 - 110 | mg/dl | GOD TRINDERS |

***** END OF THE REPORT *****



Dr. PRADIP KUMAR
Consultant (Microbiology)

Dr. SONIA KUMARI
MD Pathology (Gold Medalist)

Dr. NISHA TIWARI
MBBS, MD (Microbiology)

USER NM AMIT1



(This is only professional opinion and not the diagnosis, please correlate clinically)
Page 1 of 1

Q Block, South City -II, Sohna Road, Sector-47, Gurgaon, Haryana
Ph.: 0124-4900000 (100 Lines), Toll Free No. : 1800-102-6767, Mob.: 62 62 82 82 35, Email: customercare@parkhospital.in

PARK GROUP OF HOSPITALS : West Delhi - Gurugram - Faridabad - Sonapat - Panipat - Kamal - Ambala - Patiala - Behror - Jaipur

the health care providers **the health care providers**





DEPARTMENT OF PATHOLOGY

Patient Name : Mrs. RAKHI JAITLEY
MR No : 673587
Age/Sex : 53 Years 7 Months 21 Days / Female
Type : OPD
TPA/Corporate : MEDIWHEEL PVT LTD

Bill Date : 11/03/2023
Reporting Date : 11/03/2023
Sample ID : 109707
Bill/Req. No. : 24055502
Ref Doctor : Dr.RMO

| Test | Result | Bio. Ref. Interval | Units | Method |
|------|--------|--------------------|-------|--------|
|------|--------|--------------------|-------|--------|

BLOOD SUGAR 2 HR. PP

| | | | | |
|------------------|-----|----------|-------|--|
| BLOOD SUGAR P.P. | 107 | 80 - 150 | mg/dl | |
|------------------|-----|----------|-------|--|

***** END OF THE REPORT *****



Sample no.

Dr. SONIA KUMARI
MBBS, MD (PATHOLOGY) Gold medalist

Dr. PRADIP KUMAR
Consultant (Microbiology)

Dr. NISHA TIWARI
MBBS, MD (Microbiology)

USER NM AMIT1



Cert. No. H-2016-0369 Cert. No. MC - 4830

(This is only professional opinion and not the diagnosis, please correlate clinically)
Q Block, South City -II, Sohna Road, Sector-47, Gurgaon, Haryana
Ph.: 0124-4900000 (100 Lines), Toll Free No. : 1800-102-6767, Mob.: 62 62 82 82 35, Email: customercare@parkhospital.in

PARK GROUP OF HOSPITALS : West Delhi - Gurugram - Faridabad - Sonapat - Panipat - Karnal - Ambala - Patiala - Behror - Jaipur

the **health** care providers

the **health** care providers





DEPARTMENT OF PATHOLOGY

Patient Name : Mrs. RAKHI JAITLEY
MR No : 673587
Age/Sex : 53 Years 7 Months 21 Days / Female
Type : OPD
TPA/Corporate : MEDIWHEEL PVT LTD

Bill Date : 11/03/2023
Reporting Date : 11/03/2023
Sample ID : 109707
Bill/Req. No. : 24055502
Ref Doctor : Dr.RMO

| Test | Result | Bio. Ref. Interval | Units | Method |
|-------------------------------------|-------------|--------------------|-----------|-------------------------|
| URINE ROUTINE AND MICROSCOPY | | | | |
| PHYSICAL CHARACTERSTICS | | | | |
| QUANTITY | 30ml | 5 - 100 | ml | |
| COLOUR | Pale Yellow | Pale Yellow | | Vishal |
| TURBIDITY | Clear | clear | | |
| SPECIFIC GRAVITY | 1.020 | 1.000-1.030 | | urinometer |
| PH | Acidic | Acidic/Alkaline | | PH PAPER |
| CHEMICAL EXAMINATION-1 | | | | |
| UROBILINOGEN | NIL | NIL | | Ehrlich |
| URINE PROTEIN | NIL | NIL | mg/dl | Protein error indicator |
| BLOOD | NIL | NIL | | |
| URINE BILIRUBIN | NIL | NIL | | |
| GLUCOSE | NIL | NIL | mg/dL | GOD-POD/Benedicts |
| URINE KETONE | NIL | NIL | | SOD. |
| MICRO EXAMINATION | | | | |
| PUS CELL | 2-3 | 0-5 | cells/hpf | Microscopic |
| RED BLOOD CELLS | Nil | 0-2 | cells/hpf | |
| EPITHELIAL CELLS | 2-4 | 0-5 | cells/hpf | |
| CASTS | NIL | NIL | /lpf | |
| CRYSTALS | NIL | NIL | /hpf | |

***** END OF THE REPORT *****



Sample no.

Dr. SONIA KUMARI
MBBS, MD (PATHOLOGY) Gold medalist

Dr. PRADIP KUMAR
Consultant (Microbiology)

Dr. NISHA TIWARI
MBBS, MD (Microbiology)

USER NM AMIT1



(This is only professional opinion and not the diagnosis, please correlate clinically) Page 1 of 1

Cert. No. H-2016-0369 Cert. No. MC-4830

Q Block, South City -II, Sohna Road, Sector-47, Gurgaon, Haryana
Ph.: 0124-4900000 (100 Lines), Toll Free No. : 1800-102-6767, Mob.: 62 62 82 82 35, Email: customercare@parkhospital.in

PARK GROUP OF HOSPITALS : West Delhi - Gurugram - Faridabad - Sonapat - Panipat - Karnal - Ambala - Patiala - Behror - Jaipur

the **health** care providers

the **health** care providers





DEPARTMENT OF PATHOLOGY

Patient Name : Mrs. RAKHI JAITLEY

MR No : 673587

Age/Sex : 53 Years 7 Months 21 Days / Female

Type : OPD

TPA/Corporate : MEDIWHEEL PVT LTD

Bill Date : 11/03/2023

Reporting Date : 11/03/2023

Sample ID : 109707

Bill/Req. No. : 24055502

Ref Doctor : Dr.RMO

| Test | Result | Bio. Ref. Interval | Units | Method |
|-------------------------------------|-------------------|--------------------|-------|------------|
| BLOOD GROUPING AND RH FACTOR | | | | |
| BLOOD GROUP | " O " RH POSITIVE | | | MATRIX GEL |

***** END OF THE REPORT *****



Sample no.

Dr. SONIA KUMARI
MBBS, MD (PATHOLOGY) Gold medalist

Dr. PRADIP KUMAR
Consultant (Microbiology)

Dr. NISHA TIWARI
MBBS, MD (Microbiology)

USER NM AMIT1



(This is only professional opinion and not the diagnosis, please correlate clinically) Page 1 of 1

Cert No. H-2016-0369 Cert No. MC - 4830 Q Block, South City -II, Sohna Road, Sector-47, Gurgaon, Haryana
Ph.: 0124-4900000 (100 Lines), Toll Free No. : 1800-102-6767, Mob.: 62 62 82 82 35, Email: customercare@parkhospital.in

PARK GROUP OF HOSPITALS : West Delhi - Gurugram - Faridabad - Sonapat - Panipat - Karnal - Ambala - Patiala - Behror - Jaipur

the **health** care providers

the **health** care providers





DEPARTMENT OF PATHOLOGY

Patient Name : Mrs. RAKHI JAITLEY
 MR No : 673587
 Age/Sex : 53 Years 7 Months 21 Days / Female
 Type : OPD
 TPA/Corporate : MEDIWHEEL PVT LTD

Bill Date : 11/03/2023
 Reporting Date : 11/03/2023
 Sample ID : 109707
 Bill/Req. No. : 24055502
 Ref Doctor : Dr.RMO

| Test | Result | Bio. Ref. Interval | Units | Method |
|------------------------------|--------|--------------------|-------------------|----------------|
| CBC | | | | |
| HAEMOGLOBIN | 12.4 | 12 - 15 | gm/dL | COLORIMETRY |
| TOTAL LEUCOCYTE COUNT | 7300 | 4000-11000 | / μ L | ELECTRICAL |
| DIFFERENTIAL COUNT | | | | |
| NEUTROPHILS | 59 | 40.0 - 80.0 | % | FLOW CYTOMETRY |
| LYMPHOCYTES | 31 | 20.0 - 40.0 | % | FLOW CYTOMETRY |
| MONOCYTES | 08 | 2.0 - 10.0 | % | FLOW CYTOMETRY |
| EOSINOPHILS | 02 | 0.0 - 5.0 | % | FLOW CYTOMETRY |
| BASOPHILS | 00 | 0.0 - 2.0 | % | FLOW CYTOMETRY |
| RED BLOOD CELL COUNT | 4.4 | 3.5 - 5.5 | millions/ μ L | ELECTRICAL |
| PACKED CELL VOLUME | 41.7 | 35.0 - 50.0 | % | ELECTRICAL |
| MEAN CORPUSCULAR VOLUME | 93.2 | 83 - 101 | fL | ELECTRICAL |
| MEAN CORPUSCULAR HAEMOGLOBIN | 27.7 | 27 - 31 | Picogrames | CALCULATED |
| MEAN CORPUSCULAR HB CONC | 29.7 | L 33 - 37 | g/dl | CALCULATED |
| PLATELET COUNT | 194 | 150 - 450 | thou/ μ L | ELECTRICAL |
| RDW | 15.3 | H 11.6 - 14.5 | % | CALCULATED |

***** END OF THE REPORT *****



Sample no.

Dr. SONIA KUMARI
 MBBS, MD (PATHOLOGY) Gold medalist

Dr. PRADIP KUMAR
 Consultant (Microbiology)

Dr. NISHA TIWARI
 MBBS, MD (Microbiology)

USER NM AMIT1



Cert No. H-2018-0369 Cert No. MC - 4930

(This is only professional opinion and not the diagnosis, please correlate clinically)

Q Block, South City -II, Sohna Road, Sector-47, Gurgaon, Haryana
 Ph.: 0124-4900000 (100 Lines), Toll Free No. : 1800-102-6767, Mob.: 62 62 82 82 35, Email: customercare@parkhospital.in

PARK GROUP OF HOSPITALS : West Delhi - Gurugram - Faridabad - Sonapat - Panipat - Karnal - Ambala - Patiala - Behror - Jaipur

the health care providers

the health care providers





DEPARTMENT OF PATHOLOGY

Patient Name : Mrs. RAKHI JAITLEY

MR No : 673587

Age/Sex : 53 Years 7 Months 21 Days / Female

Type : OPD

TPA/Corporate : MEDIWHEEL PVT LTD

Bill Date : 11/03/2023

Reporting Date : 11/03/2023

Sample ID : 109707

Bill/Req. No. : 24055502

Ref Doctor : Dr.RMO

| Test | Result | Bio. Ref. Interval | Units | Method |
|-------------------------|--------|--------------------|-----------|------------|
| ESR (WESTERGREN) | | | | |
| E.S.R. - II HR. | 35 | | mm II Hr. | Westergren |

***** END OF THE REPORT *****



Sample no.

Dr. SONIA KUMARI
MBBS, MD (PATHOLOGY) Gold medalist

Dr. PRADIP KUMAR
Consultant (Microbiology)

Dr. NISHA TIWARI
MBBS, MD (Microbiology)

USER NM AMIT1



Cert. No. H-2016-0369 Cert. No. MC - 4830

(This is only professional opinion and not the diagnosis, please correct clinically) Page 1 of 1

Q Block, South City -II, Sohna Road, Sector-47, Gurgaon, Haryana

Ph.: 0124-4900000 (100 Lines), Toll Free No. : 1800-102-6767, Mob.: 62 62 82 82 35, Email: customer@parkhospital.in

PARK GROUP OF HOSPITALS : West Delhi - Gurugram - Faridabad - Sonapat - Panipat - Karnal - Ambala - Patiala - Behror - Jaipur

the **health** care providers

the **health** care providers





DEPARTMENT OF PATHOLOGY

Patient Name : Mrs. RAKHI JAITLEY
MR No : 673587
Age/Sex : 53 Years 7 Months 21 Days / Female
Type : OPD
TPA/Corporate : MEDIWHEEL PVT LTD

Bill Date : 11/03/2023
Reporting Date : 12/03/2023
Sample ID : 109707
Bill/Req. No. : 24055502
Ref Doctor : Dr.RMO

| Test | Result | Bio. Ref. Interval | Units | Method |
|---------------------------------------|--------|--------------------|--------|-------------------|
| THYROID PROFILE | | | | |
| TRI-IODOTHYRONINE (T3) | 1.42 | 0.60 - 1.81 | ng/ml | Chemiluminescence |
| THYROXINE (T4) | 9.79 | 5.01 - 12.45 | µg/dL | Chemiluminescence |
| THYROID STIMULATING HORMONE | 4.08 | 0.5-5.50 | µIU/ml | |
| SPECIMEN TYPE | SERUM | | | |
| Method : chemiluminescent immunoassay | | | | |

Note : Clinical Significance:

Thyroid function tests (TFTs) is a collective term for blood tests used to check the function of the thyroid. TFTs may be requested if a patient is thought to suffer from hyperthyroidism (overactive thyroid) or hypothyroidism (underactive thyroid), or to monitor the effectiveness of either thyroid-suppression or hormone replacement therapy. It is also requested routinely in conditions linked to thyroid disease, such as atrial fibrillation and anxiety disorder. A TFT panel typically includes thyroid hormones such as thyroid-stimulating hormone (TSH, thyrotropin) and thyroxine (T4), and triiodothyronine (T3) depending on local laboratory policy.

Note: Please correlate with clinical condition

***** END OF THE REPORT *****



Sample no.

Dr. SONIA KUMARI
MBBS, MD (PATHOLOGY) Gold medalist

Dr. PRADIP KUMAR
Consultant (Microbiology)

Dr. NISHA TIWARI
MBBS, MD (Microbiology)

USER NM DINESH



Cert No. H-2016-0369 Cert No. NC-4830

(This is only professional opinion and not the diagnosis, please correlate clinically)

Q Block, South City -II, Sohna Road, Sector-47, Gurgaon, Haryana
Ph.: 0124-4900000 (100 Lines), Toll Free No. : 1800-102-6767, Mob.: 62 62 82 82 35, Email: customercare@parkhospital.in

PARK GROUP OF HOSPITALS : West Delhi - Gurugram - Faridabad - Sonapat - Panipat - Karnal - Ambala - Patiala - Behror - Jaipur

the health care providers

the health care providers





DEPARTMENT OF PATHOLOGY

Patient Name : Mrs. RAKHI JAITLEY
 MR No : 673587
 Age/Sex : 53 Years 7 Months 21 Days / Female
 Type : OPD
 TPA/Corporate : MEDIWHEEL PVT LTD

Bill Date : 11/03/2023
 Reporting Date : 11/03/2023
 Sample ID : 109707
 Bill/Req. No. : 24055502
 Ref Doctor : Dr.RMO

| Test | Result | Bio. Ref. Interval | Units | Method |
|----------------------------------|------------|--------------------|-------|---------------|
| LFT (LIVER FUNCTION TEST) | | | | |
| LFT | | | | |
| TOTAL BILIRUBIN | 0.4 | 0 - 1.2 | mg/dL | DIAZO |
| DIRECT BILIRUBIN | 0.2 | 0 - 0.4 | mg/dL | DIAZO |
| INDIRECT BILIRUBIN | 0.2 | 0.10 - 0.6 | mg/dL | CALCULATED |
| SGOT (AST) | 34 | 0 - 45 | U/L | IFCC WITHOUT |
| SGPT (ALT) | 26 | 0 - 45 | U/L | IFCC WITHOUT |
| ALKALINE PHOSPHATASE | 150 | 30 - 170 | IU/L | MODIFIED IFCC |
| TOTAL PROTEINS | 6.3 | L 6.4 - 8.0 | g/dL | BIURET |
| ALBUMIN | 3.7 | 3.3 - 5.5 | g/dL | BCG DYE |
| GLOBULIN | 2.6 | 2.3 - 4.5 | g/dL | CALCULATED |
| A/G RATIO | 1.42 | 1.1 - 2.2 | | CALCULATED |

***** END OF THE REPORT *****



Sample no.

Dr. SONIA KUMARI
 MBBS, MD (PATHOLOGY) Gold medalist

Dr. PRADIP KUMAR
 Consultant (Microbiology)

Dr. NISHA TIWARI
 MBBS, MD (Microbiology)

USER NM AMIT1



(This is only professional opinion and not the diagnosis, please correct if clinically)

Cert. No. 15-2016-3369 Cert. No. MC-4830

Q Block, South City -II, Sohna Road, Sector-47, Gurgaon, Haryana
 Ph.: 0124-4900000 (100 Lines), Toll Free No. : 1800-102-6767, Mob.: 62 62 82 82 35, Email: customercare@parkhospital.in

PARK GROUP OF HOSPITALS : West Delhi - Gurugram - Faridabad - Sonapat - Panipat - Karnal - Ambala - Patiala - Behror - Jaipur

the health care providers

the health care providers





DEPARTMENT OF PATHOLOGY

Patient Name : Mrs. RAKHI JAITLEY
 MR No : 673587
 Age/Sex : 53 Years 7 Months 21 Days / Female
 Type : OPD
 TPA/Corporate : MEDIWHEEL PVT LTD

Bill Date : 11/03/2023
 Reporting Date : 11/03/2023
 Sample ID : 109707
 Bill/Req. No. : 24055502
 Ref Doctor : Dr.RMO

| Test | Result | Bio. Ref. Interval | Units | Method |
|----------------------------|--------|--------------------|--------|-----------------|
| KFT (RENAL PROFILE) | | | | |
| KFT | | | | |
| SERUM UREA | 24 | 10 - 45 | mg/dL | UREASE-GLDH |
| SERUM CREATININE | 1.0 | 0.4 - 1.4 | mg/dL | MODIFIED JAFFES |
| SERUM URIC ACID | 4.1 | 2.5 - 7.0 | mg/dL | URICASE |
| SERUM SODIUM | 138 | 136 - 148 | mmol/L | ISE |
| SERUM POTASSIUM | 3.7 | 3.5 - 5.5 | meq/l | ISE |
| SERUM CALCIUM | 8.5 | 8.5 - 10.5 | mg/dL | ARSENAZO III |
| SERUM PHOSPHORUS | 5.3 | H 2.5 - 4.5 | mg/dL | AMMONIUM |

***** END OF THE REPORT *****



Sample no.

Dr. SONIA KUMARI
 MBBS, MD (PATHOLOGY) Gold medalist

Dr. PRADIP KUMAR
 Consultant (Microbiology)

Dr. NISHA TIWARI
 MBBS, MD (Microbiology)

USER NM AMIT1



(This is only professional opinion and not the diagnosis, please consult a doctor) Page 1 of 1 (Total)

Q Block, South City -II, Sohna Road, Sector-47, Gurgaon, Haryana
 Ph.: 0124-4900000 (100 Lines), Toll Free No. : 1800-102-6767, Mob.: 62 62 82 82 35, Email: customercare@parkhospital.in

PARK GROUP OF HOSPITALS : West Delhi - Gurugram - Faridabad - Sonapat - Panipat - Karnal - Ambala - Patiala - Behror - Jaipur



DEPARTMENT OF PATHOLOGY

Patient Name : Mrs. RAKHI JAITLEY

MR No : 673587

Age/Sex : 53 Years 7 Months 21 Days / Female

Type : OPD

TPA/Corporate : MEDIWHEEL PVT LTD

Bill Date : 11/03/2023

Reporting Date : 11/03/2023

Sample ID : 109707

Bill/Req. No. : 24055502

Ref Doctor : Dr.RMO

| Test | Result | Bio. Ref. Interval | Units | Method |
|-----------------------------|--------|--------------------|-------|---------------|
| LIPID PROFILE | | | | |
| LIPID PROFILE | | | | |
| TOTAL CHOLESTEROL | 205 | 0 - 250 | mg/dL | CHOD -Trinder |
| SERUM TRIGLYCERIDES | 226 | H 60 - 165 | mg/dl | GPO-TRINDER |
| HDL-CHOLESTEROL | 52 | 30 - 70 | mg/dl | DIRECT |
| VLDL CHOLESTEROL | 45 | H 6 - 32 | mg/dL | calculated |
| LDL | 108 | 50 - 135 | mg/dl | calculated |
| LDL CHOLESTEROL/HDL RATIO | 2.0 | 1.0 - 3.0 | mg/dL | calculated |
| TOTAL CHOLESTEROL/HDL RATIO | 3.9 | 2.0 - 5.0 | mg/dl | calculated |

***** END OF THE REPORT *****



Sample no.

Dr. SONIA KUMARI
MBBS, MD (PATHOLOGY) Gold medalist

Dr. PRADIP KUMAR
Consultant (Microbiology)

Dr. NISHA TIWARI
MBBS, MD (Microbiology)

USER NM AMIT1



Cert. No. H-2019-0360 Cert. No. MC-4830

(This is only professional opinion and not the diagnosis, please consult a clinician)
Q Block, South City -II, Sohna Road, Sector-47, Gurgaon, Haryana

Ph.: 0124-4900000 (100 Lines), Toll Free No. : 1800-102-6767, Mob.: 62 62 82 82 35, Email: customercare@parkhospital.in

PARK GROUP OF HOSPITALS : West Delhi - Gurugram - Faridabad - Sonapat - Panipat - Karnal - Ambala - Patiala - Behror - Jaipur

the health care providers the health care providers





DEPARTMENT OF RADIOLOGY

| | | | | |
|--------------|-----------------------------------|-------------------|--------------|---------|
| Patient Name | Mrs. RAKHI JAITLEY | Billed Date | : 11/03/2023 | 9.11 AM |
| Reg No | 673587 | Reported Date | : 11/03/2023 | |
| Age/Sex | 53 Years 7 Months 21Days / Female | Req. No. | : 24055502 | |
| Type | OPD | Consultant Doctor | : Dr. RMO | |

X-RAY CHEST AP/PA

X-RAY CHEST P.A. VIEW

Bilateral lungs appears normal.

No focal lung lesion seen.

No evidence of free fluid is seen.

Both hila are normal in size, have equal density and bear normal relationship.

The heart and trachea are central in position and no mediastinal abnormality is visible.

The cardiac size is normal for patient age and view.

The domes of the diaphragms are normal in position, and show smooth outline.

To be correlated clinically



Dr. ANSHU K. SHARMA
MBBS, MD
CONSULTANT RADIOLOGIST

Dr. MANJEET SEHRAWAT
MBBS, MD, PDCC
CONSULTANT RADIOLOGIST

Dr. NEENA SIKKA
MBBS, DNB
CONSULTANT RADIOLOGIST



(This is only professional opinion and not the diagnosis, please correlate clinically)

Q Block, South City -II, Sohna Road, Sector-47, Gurgaon, Haryana

Ph.: 0124-4900000 (100 Lines), Toll Free No. : 1800-102-6767, Mob.: 62 62 82 82 35, Email: customercare@parkhospital.in

PARK GROUP OF HOSPITALS : West Delhi - Gurugram - Faridabad - Sonapat - Panipat - Karnal - Ambala - Patiala - Behror - Jaipur

the **health** care providers

the **health** care providers





DEPARTMENT OF RADIOLOGY

| | | | | |
|--------------|-----------------------------------|-------------------|--------------|---------|
| Patient Name | Mrs. RAKHI JAITLEY | Billed Date | : 11/03/2023 | 9.11 AM |
| Reg No | 673587 | Reported Date | : 11/03/2023 | |
| Age/Sex | 53 Years 7 Months 21Days / Female | Req. No. | : 24055502 | |
| Type | OPD | Consultant Doctor | : Dr. RMO | |

USG WHOLE ABDOMEN

The real time, B mode, gray scale sonography of the abdominal organs was performed.

LIVER : The liver is **enlarged in size 17.5cm with fatty infiltration**. No evidence of any focal lesion. IHBR is not dilated.

GALL BLADDER : The gall bladder is well distended . No evidence any calculus or mass seen.GB wall thickness with in normal limits.No evidence of pericholecystic fluid is seen.

BILE DUCT :The common bile duct is normal in caliber. No evidence of calculus is noted in common bile duct.

SPLEEN :The spleen is normal in size 8.5cm and shape.Its echotexture is homogeneous.No evidence of focal lesion is noted.

PANCREAS :The pancreas is normal in size, shape, contours and echotexture.No evidence of solid or cystic mass lesion is noted.MPD is not dilated. No evidence of peripancreatic collection.

KIDNEYS : The bilateral kidneys are normal in size and echotexture. Cortico-medullary differentiation is maintained.There is no evidence of obvious calculus or hydronephrosis.

URINARY BLADDER :The urinary bladder is well distended.It shows uniformly thin walls and sharp mucosa.No evidence of calculus is seen. No evidence of mass or diverticulum is noted.

UTERUS: The uterus is anteverted. It measures 5x4.4x4.2 cms. in the longitudinal, anteroposterior and transverse dimensions respectivelyThe uterine margins is smooth and does not reveal any contour abnormalities.

The uterine myometrium shows homogeneous echotexture.

No evidence of leiomyoma is noted. No solid or cystic mass lesion is noted.

The endometrial echo is in the midline and measures 5.6mm.

The ovaries on the either side show normal echotexture.

No adnexal mass is seen.No cyst is seen in ovaries.

No evidence of ascites or interbowel free fluid is seen.

No evidence of obvious retroperitoneal or mesentric lymphadenopathy is seen.

Bowel loop distended with gas.

IMPRESSION- Hepatomegaly with fatty liver grade-I

To be correlated clinically.

Dr. ANSHU K. BHARMA
MBBS,MD
CONSULTANT RADIOLOGIST

Dr. MANJEET SEHRAWAT
MBBS,MD,PDCC
CONSULTANT RADIOLOGIST

Dr. NEENA SIKKA
MBBS,DNB
CONSULTANT RADIOLOGIST



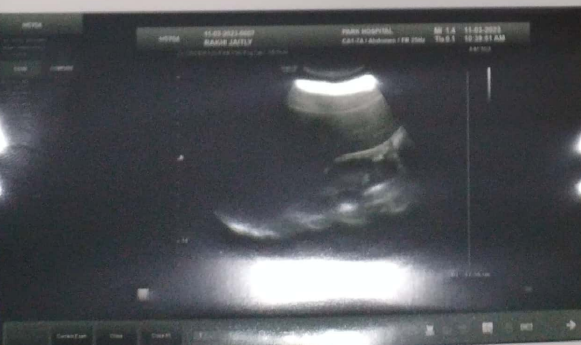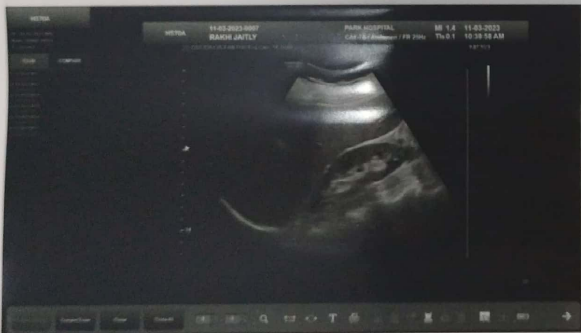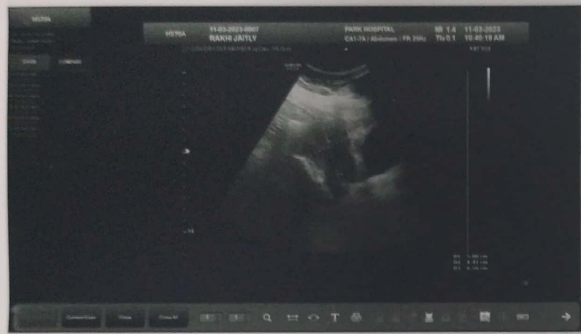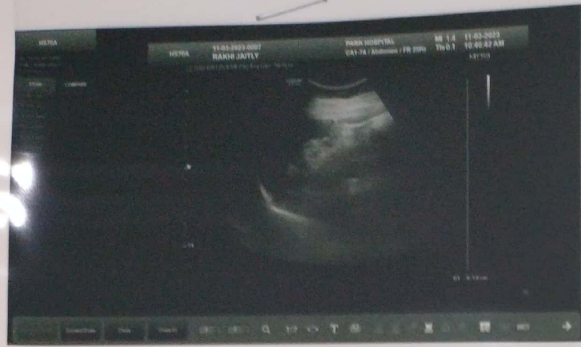Cert. No. H-2016-0369 Cert. No. MC-4830

(This is only professional opinion and not the diagnosis, please correlate clinically)

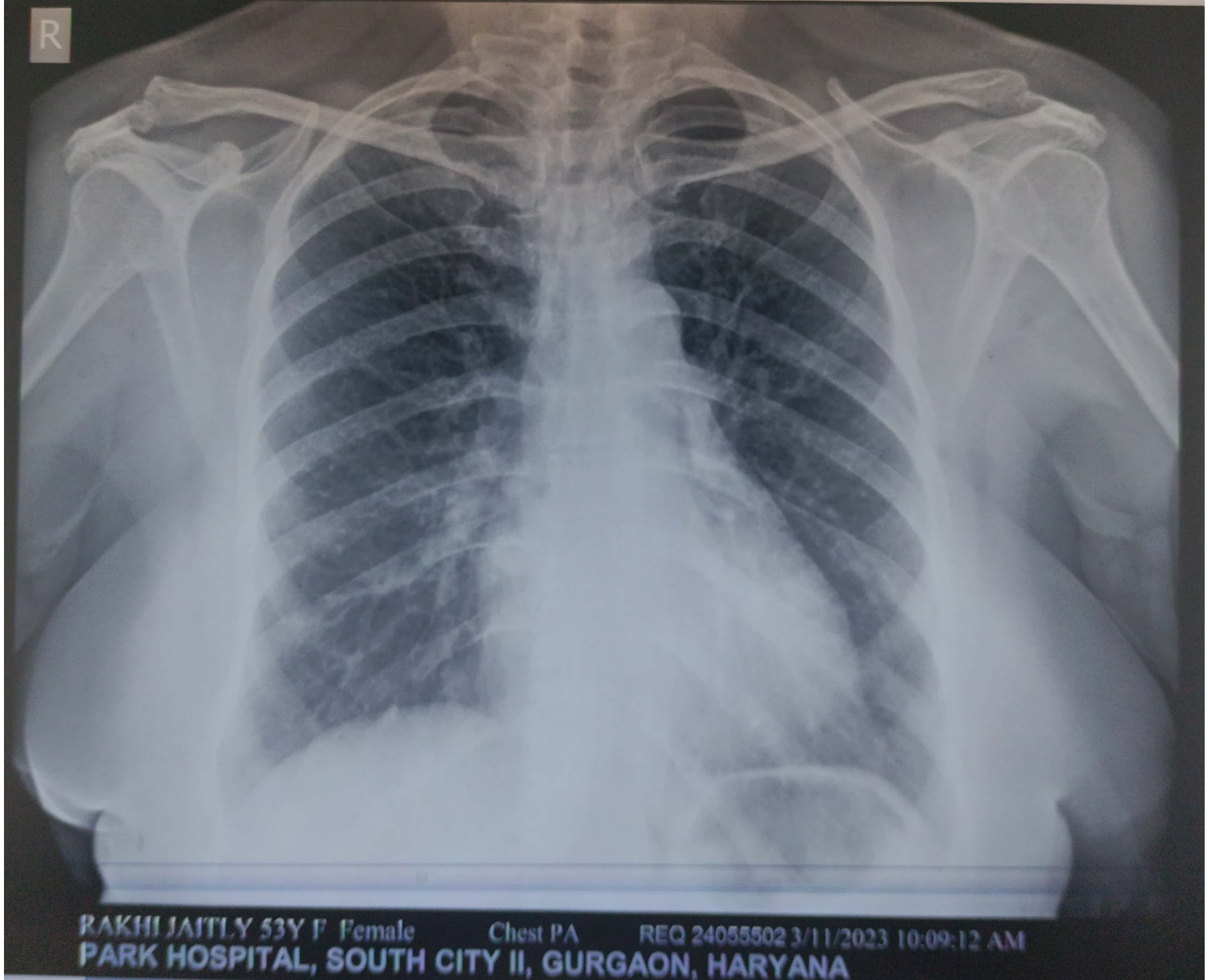
Q Block, South City -II, Sohna Road, Sector-47, Gurgaon, Haryana
Ph.: 0124-4900000 (100 Lines), Toll Free No. : 1800-102-6767, Mob.: 62 62 82 82 35, Email: customercare@parkhospital.in

PARK GROUP OF HOSPITALS : West Delhi - Gurugram - Faridabad - Sonipat - Panipat - Karnal - Ambala - Patiala - Behror - Jaipur





R



RAKHI JAITLEY 53Y F Female Chest PA REQ 24055502 3/11/2023 10:09:12 AM
PARK HOSPITAL, SOUTH CITY II, GURGAON, HARYANA

10mm/mV

10mm/mV

ID : 0002

HR : 49

bpm

R-R : 1217

ms

P-R : 198

ms

QRS : 86

ms

QT/QTc : 430/389

ms

P/QTc/T : 59/68/37

ms

RV5/SVI : 0.690/0.400 mV

RV5+SVI : 1.090 mV

Name: Rakhi

Sex : Female

Age : 53 years

11/3/23

9:20 Am

Unconfirmed report Verified by:

- Sinus Bradycardia
- Low Voltage (Chest leads)
- Poor R-Progression
- T Abnormality (Flat T)

00:00 00-00-9102 (100-1A:AMP:000-0A:SO18)000-7A E021-5A

10mm/mV

10mm/mV

10mm/mV

245Hz ~ 5.0 s/msec

SYNC V2

SYNC

SYNC

V1

aVL

II

aVF

III

aVR

I

SYNC V6

V5

- Sinus Bradycardia
- Low Voltage (Chest leads)
- Poor R-Progression
- T Abnormality (Flat T)