

CHECK LIST

NAME	A. Malu Blandi		PATHOLOGY/PP
OP	2202341		ECG/PFT
AGE			ECHO/TMT
DATE			USG / CXR
PACKAGE			URINE / STOOL
REFERRED BY			MAMMO/ PAP
HT	151cm.		EYE/ DENTAL
WT	44cm		GP CONSULTATION
BP	110/80mmHg.		DIETITION
PULSE	81bpm		CARDIOLOGIST
WAIST	88cm		GYNECOLOGIST
HIP	80cm		DENTAL
RESPIRATORY RATE			
CHEST (INHALE)	79cm		
CHEST (EXHALE)	72cm		
ABDOMEN	83cm		

SpO₂ 100%

1001
1002
1003
1004
1005
1006
1007
1008
1009
1010
1011
1012
1013
1014
1015
1016
1017
1018
1019
1020

1001
1002
1003

1001
1002
1003




LABORATORY INVESTIGATION REPORT

Patient Name : Mrs. Archana Bharti	Age/Sex : 32 Year(s)/Female
UHID : NMHK.2203341	Order Date : 11/03/2023 10:03
Episode : OP	Mobile No : 9917564002
Ref. Doctor : NMH	DOB : 01/01/1991
Address : DIAMOND PARK , Diamond Park ,Kolkata,West Bengal ,700104	Facility : NARAYAN MEMORIAL HOSPITAL

Biochemistry

INVESTIGATION	RESULTS	UNITS	BIOLOGICAL REF RANGE
Sample No : 07H0106067 Collection Date : 11/03/23 10:13 Ack Date : 11/03/2023 12:03 Report Date : 13/03/23 13:07			
SERUM CREATININE			
SAMPLE : SERUM			
SERUM CREATININE	0.5	mg/dl	0.5 - 0.9
<i>Jaffe Gen2 Compensated</i>			
BLOOD UREA NITROGEN			
BLOOD UREA NITROGEN	06	mg/dl	6 - 20
<i>Calculated</i>			
URIC ACID			
SAMPLE : SERUM			
URIC ACID	3.7	mg/dl	2.4 - 5.7
<i>Enzymatic Colorimetric</i>			
SAMPLE : SERUM			
RESULT	12.0		
Sample No : 07H0106067B Collection Date : 11/03/23 10:13 Ack Date : 11/03/2023 12:03 Report Date : 13/03/23 13:07			
BLOOD SUGAR(F)			
SAMPLE : PLASMA			
BLOOD SUGAR FASTING	89	mg/dl	70 - 109
<i>Hexokinase</i>			
Sample No : 07H0106131B Collection Date : 11/03/23 14:21 Ack Date : 11/03/2023 15:59 Report Date : 13/03/23 13:07			
BLOOD SUGAR(PP)			
SAMPLE : PLASMA			
BLOOD SUGAR PP	95	mg/dl	70.00 - 140.00
<i>Hexokinase</i>			

End of Report






LABORATORY INVESTIGATION REPORT

Patient Name	: Mrs. Archana Bharti	Age/Sex	: 32 Year(s)/Female
UHID	: NMHK.2203341	Order Date	: 11/03/2023 10:03
Episode	: OP	Mobile No	: 9917564002
Ref. Doctor	: NMH	DOB	: 01/01/1991
Address	: DIAMOND PARK , Diamond Park ,Kolkata,West Bengal ,700104	Facility	: NARAYAN MEMORIAL HOSPITAL

Dr.S. Chatterjee
MD, MBBS, FAACC
(CONSULTANT BIOCHEMIST)

Checked By







LABORATORY INVESTIGATION REPORT

Patient Name : Mrs. Archana Bharti	Age/Sex : 32 Year(s)/Female
UHID : NMHK.2203341	Order Date : 11/03/2023 10:03
Episode : OP	
Ref. Doctor : NMH	Mobile No : 9917564002
	DOB : 01/01/1991
Address : DIAMOND PARK , Diamond Park ,Kolkata,West Bengal ,700104	Facility : NARAYAN MEMORIAL HOSPITAL

Biochemistry

INVESTIGATION	RESULTS	UNITS	BIOLOGICAL REF RANGE
Sample No : 07H0106067	Collection Date : 11/03/23 10:13	Ack Date : 11/03/2023 12:03	Report Date : 13/03/23 13:07

LIVER FUNCTION TEST (LFT)

SAMPLE : SERUM

TOTAL BILIRUBIN <i>Diazo Method</i>	0.5	mg/dl	0 - 1.1
DIRECT BILIRUBIN <i>Diazo Method</i>	0.3 ▲	mg/dl	0 - 0.2
INDIRECT BILIRUBIN <i>Calculated</i>	0.2	mg/dl	0.2 - 0.9
SGPT (ALT) <i>IFCC Without Pyridoxal Phosphate</i>	10	U/L	0 - 34
SGOT (AST) <i>IFCC Without Pyridoxal Phosphate</i>	15	U/L	0 - 31
ALKALINE PHOSPHATASE <i>IFCC</i>	98	U/L	53 - 128
TOTAL PROTEIN <i>Biuret</i>	7.4	g/dl	6.4 - 8.2
ALBUMIN <i>Bromocresol Green</i>	4.6	gm/dl	3.5 - 5.2
GLOBULIN <i>Calculated</i>	2.8	g/dl	2 - 3.5
ALBUMIN:GLOBULIN <i>Calculated</i>	1.6	-	1.1 - 2.5
GGT <i>Enzymatic colorimetric assay</i>	10	U/L	5 - 36




LABORATORY INVESTIGATION REPORT

Patient Name	: Mrs. Archana Bharti	Age/Sex	: 32 Year(s)/Female
UHID	: NMHK.2203341	Order Date	: 11/03/2023 10:03
Episode	: OP	Mobile No	: 9917564002
Ref. Doctor	: NMH	DOB	: 01/01/1991
Address	: DIAMOND PARK , Diamond Park ,Kolkata,West Bengal ,700104	Facility	: NARAYAN MEMORIAL HOSPITAL

End of Report

Dr.S. Chatterjee
MD, MBBS, FAACC
(CONSULTANT BIOCHEMIST)

Checked By







LABORATORY INVESTIGATION REPORT

Patient Name : Mrs. Archana Bharti
UHID : NMHK.2203341
Episode : OP
Ref. Doctor : NMH
Address : DIAMOND PARK , Diamond Park ,Kolkata,West Bengal ,700104

Age/Sex : 32 Year(s)/Female
Order Date : 11/03/2023 10:03
Mobile No : 9917564002
DOB : 01/01/1991
Facility : NARAYAN MEMORIAL HOSPITAL

Biochemistry

INVESTIGATION	RESULTS	UNITS	BIOLOGICAL REF RANGE
Sample No : 07H0106067	Collection Date : 11/03/23 10:13	Ack Date : 11/03/2023 12:03	Report Date : 13/03/23 13:07

LIPID PROFILE

SAMPLE : SERUM

TOTAL CHOLESTEROL	166	mg/dl	Desirable <200 Borderline 200-239 High >=240
<i>CHOD-PAP</i>			
HDL CHOLESTEROL	75 ▲	mg/dl	40 - 60
<i>Homogenous Enzymatic Colorimetric</i>			
LDL CHOLESTEROL	81	mg/dl	Optimal < 100 Borderline 130
<i>Homogenous Enzymatic Colorimetric</i>			
VLDL	10	mg/dl	0 - 30
<i>CALCULATED</i>			
CHOLESTEROL-HDL RATIO	2.21	-	
LDL-HDL RATIO	1.09	-	
TRIGLYCERIDES	63	mg/dl	Desirable <150 Borderline 150 - 200 High >200

Enzymatic Colorimetric

End of Report

Dr.S. Chatterjee
MD, MBBS, FAACC
(CONSULTANT BIOCHEMIST)

Checked By



LABORATORY INVESTIGATION REPORT

Patient Name : Mrs. Archana Bharti
UHID : NMHK.2203341
Episode : OP
Ref. Doctor : NMH
Address : DIAMOND PARK , Diamond Park ,Kolkata,West Bengal ,700104

Age/Sex : 32 Year(s)/Female
Order Date : 11/03/2023 10:03
Mobile No : 9917564002
DOB : 01/01/1991
Facility : NARAYAN MEMORIAL HOSPITAL

Hematology

INVESTIGATION	RESULTS	UNITS	BIOLOGICAL REF RANGE
Sample No : 07H0106067	Collection Date : 11/03/23 10:13	Ack Date : 11/03/2023 11:17	Report Date : 11/03/23 14:07

COMPLETE HAEMOGRAM (CBC)

SAMPLE : EDTA BLOOD

HAEMOGLOBIN (HB) <i>Colorimetric method (Cyn Meth)</i>	11.7 ▼	gm/dl	12 - 15
RBC COUNT <i>Electrical Impedance Method</i>	3.8	x10 ⁶ /ul	3.8 - 4.8
TOTAL WBC COUNT <i>Electrical Impedance Method</i>	3.1 ▼	10 ³ /cmm	4 - 10
PLATELET COUNT <i>Electrical Impedance Method</i>	195	10 ³ /cmm	150 - 410
PCV <i>RBC pulse ht. detection method</i>	35 ▼	%	36 - 46
MCV <i>calculated</i>	93	fl	83 - 101
MCH <i>Calculated</i>	31	pg	27 - 32
MCHC <i>Calculated</i>	33	gm/dl	31.5 - 34.5
ESR <i>Modified Westergren Method</i>	25 ▲	%	0 - 12
<u>DIFFERENTIAL COUNT</u>			
NEUTROPHILS <i>Microscopy</i>	59	%	40 - 80
LYMPHOCYTES <i>Microscopy</i>	35	%	20 - 40
MONOCYTES <i>Microscopy</i>	04	%	2 - 10





LABORATORY INVESTIGATION REPORT

Patient Name : Mrs. Archana Bharti	Age/Sex : 32 Year(s)/Female
UHID : NMHK.2203341	Order Date : 11/03/2023 10:03
Episode : OP	Mobile No : 9917564002
Ref. Doctor : NMH	DOB : 01/01/1991
Address : DIAMOND PARK , Diamond Park ,Kolkata,West Bengal ,700104	Facility : NARAYAN MEMORIAL HOSPITAL

EOSINOPHILS 02 % 1 - 6
Microscopy

BASOPHILS 00 % 0 - 2
Microscopy

PERIPHERAL BLOOD SMEAR

RBC Normocytic normochromic.
WBC Leukopenia.
PLATELET Adequate.

End of Report

Angkita K. Ghosh

Dr. ANGKITA K. GHOSH
MBBS, MD(PATH)
(CONSULTANT PATHOLOGIST)

RegNo: 82734

Checked By



LABORATORY INVESTIGATION REPORT

Patient Name : Mrs. Archana Bharti
UHID : NMHK.2203341
Episode : OP
Ref. Doctor : NMH
Address : DIAMOND PARK , Diamond Park ,Kolkata,West Bengal ,700104

Age/Sex : 32 Year(s)/Female
Order Date : 11/03/2023 10:03
Mobile No : 9917564002
DOB : 01/01/1991
Facility : NARAYAN MEMORIAL HOSPITAL

Immunology

INVESTIGATION	RESULTS	UNITS	BIOLOGICAL REF RANGE
Sample No : 07H0106067	Collection Date : 11/03/23 10:13	Ack Date : 11/03/2023 11:17	Report Date : 11/03/23 15:44

BLOOD GROUPING & Rh TYPING

SAMPLE : EDTA BLOOD

BLOOD GROUP

Agglutination forward & Reverse

RH TYPE

'O'

POSITIVE

End of Report

Angkita K. Ghosh

Dr. ANGKITA K. GHOSH
MBBS, MD(PATH)
(CONSULTANT PATHOLOGIST)

RegNo: 82734

Checked By



DIAGNOSTICS REPORT

Patient Name	: Mrs. Archana Bharti	Order Date	: 11/03/2023 10:03
Age/Sex	: 32 Year(s)/Female	Report Date	: 11/03/2023 17:30
UHID	: NMHK.2203341	IP No	:
Ref. Doctor	: NMH	Facility	: NARAYAN MEMORIAL HOSPITAL
Address	: DIAMOND PARK, Diamond Park, Kolkata, West Bengal, 700104	Mobile	: 9917564002

USG REPORT OF WHOLE ABDOMEN (SCREENING)

LIVER : Liver is normal in size and parenchymal echotexture. Intrahepatic biliary radicles are not dilated. No focal mass lesion is seen.

PORTA :PV : Normal. PV measures 0.9 cm.

CD : Normal . CD measures 0.4 cm.

GALL BLADDER : Gall bladder is normal in size, contour, outline and position. No calculus is seen. Wall thickness is normal.

PANCREAS : Pancreas is normal in size and parenchymal echogenicity. Pancreatic duct is not dilated.

SPLEEN : Spleen is not enlarged and parenchyma shows normal homogeneous pattern.

KIDNEYS : Both kidneys are normal in size, shape, outline, position and parenchymal echogenicity. Cortico medullary differentiation maintained. No evidence of any calculus/ mass / hydronephrosis is seen. Right kidney measures : 10.3 cm & Left kidney measures :10.2 cm.

URINARY BLADDER : Urinary bladder is normal in contour, outline and distension. No vesical lesion is seen.

UTERUS : Anteverted normal in size, shape, outline, position and parenchymal echogenicity. Cavity is empty. Uterus measures 8.4 cm x 4.4 cm x 3.8 cm.



DIAGNOSTICS REPORT

Patient Name	: Mrs. Archana Bharti	Order Date	: 11/03/2023 10:03
Age/Sex	: 32 Year(s)/Female	Report Date	: 11/03/2023 17:30
UHID	: NMHK.2203341	IP No	:
Ref. Doctor	: NMH	Facility	: NARAYAN MEMORIAL HOSPITAL
Address	: DIAMOND PARK, Diamond Park, Kolkata, West Bengal, 700104	Mobile	: 9917564002

OVARIES : Both ovaries are normal in size, shape and echopattern. Right ovary : measures 2.9 cm x 1.9 cm. Left ovary : measures 2.9 cm x 1.7 cm.

PERITONEUM : :No free fluid is noted.

RETROPERITONEUM : IVC and aorta appear normal. No lymphadenopathy is seen.

IMPRESSION : Normal study.

Dr.MADHUSHREE RAY NASKAR ,
MBBS,DMRD
Consultant Radiologist
RegNo: 57032



DIAGNOSTICS REPORT

Patient Name	: Mrs. Archana Bharti	Order Date	: 11/03/2023 10:03
Age/Sex	: 32 Year(s)/Female	Report Date	: 11/03/2023 14:57
UHID	: NMHK.2203341	IP No	:
Ref. Doctor	: NMH	Facility	: NARAYAN MEMORIAL HOSPITAL
Address	: DIAMOND PARK, Diamond Park, Kolkata, West Bengal, 700104	Mobile	: 9917564002

ELECTROCARDIOGRAM REPORT (ECG)

HR	: 67 bpm
Rhythm	: Sinus
P wave	: Normal
PR Interval	: 120 msec
QRS axis	: Normal (52 Degree)
QRS duration	: 74 msec
QRS configuration	: Incomplete RBBB
T wave	: Non specific changes
ST segment	: Non specific changes
QTc	: 398 msec
QT	: 374 msec

IMPRESSION:

- Sinus rhythm. Normal QRS axis.
 - Incomplete Right Bundle Branch Block (RBBB).
 - Non specific ST-T changes.
- Clinical correlation please.

Dr.INDIRA BANERJEE ,
MD,DNB,MRCPC (UK)

Board Certified Comprehensive
Echocardiographer (USA)

ARCHANA BHARTI

2203341

Female

32 years

cm / kg

HR 67/min

Intervals:

RR 896 ms

P 88 ms

PR 110 ms

QR5 74 ms

QT 374 ms

QTc 398 ms

(Bazett)

10 mm/mV

Axis:

P 36 °

QR5 52 °

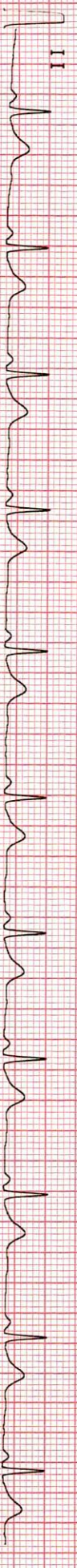
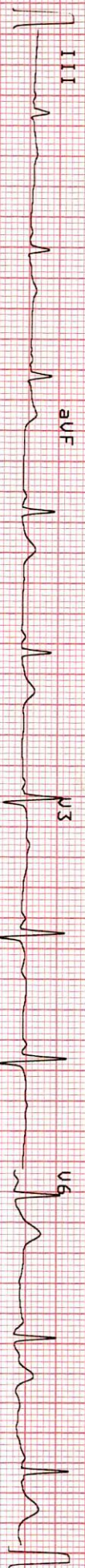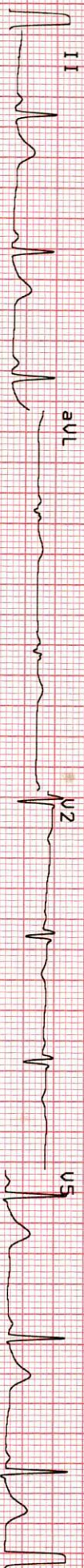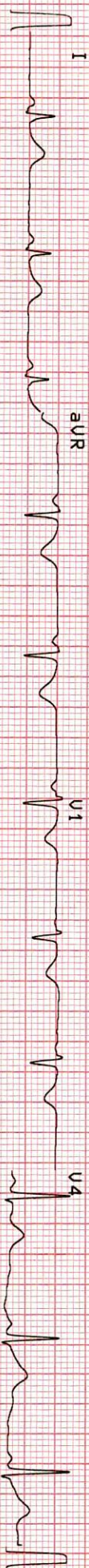T 42 °

SINUS RHYTHM
NORMAL ECG

6.02

UNCONFIRMED REPORT

10 mm/mV



10 mm/mV

25 mm/s

0.05-25 Hz

FS0

SSF 585

11.03.2023

12:28:06

NARAYAN MEMORIAL
HOSPITAL, BEHALA

AT-1020111111





DIAGNOSTICS REPORT

Patient Name	: Mrs. Archana Bharti	Order Date	: 11/03/2023 10:03
Age/Sex	: 32 Year(s)/Female	Report Date	: 11/03/2023 13:39
UHID	: NMHK.2203341	IP No	:
Ref. Doctor	: NMH	Facility	: NARAYAN MEMORIAL HOSPITAL
Address	: DIAMOND PARK, Diamond Park, Kolkata a, West Bengal, 700104	Mobile	: 9917564002

CHEST X-RAY REPORT OF PA VIEW

Lung fields are clear. No focal parenchymal opacity is seen.
No appreciable pleural thickening / calcification is noted.
Costo-phrenic angles are normal.
Cardiac shadow appears normal.
Bilateral hilar shadows are normal.
No obvious bony abnormality is seen.

Dr. Sayani Mahal, MD Radiology (AIIMS), PDCC (AIIMS)

RegNo: 74369



DIAGNOSTICS REPORT

Patient Name	: Mrs. Archana Bharti	Order Date	: 11/03/2023 10:03
Age/Sex	: 32 Year(s)/Female	Report Date	: 11/03/2023 14:27
UHID	: NMHK.2203341	IP No	:
Ref. Doctor	: NMH	Facility	: NARAYAN MEMORIAL HOSPITAL
Address	: DIAMOND PARK, Diamond Park, Kolkata, West Bengal, 700104	Mobile	: 9917564002

ECHOCARDIOGRAPHY (SCREENING)

Status of Patient :

- * No regional wall motion abnormality at rest.
- * Good LV systolic function (EF = 65%).
- * Good RV systolic function (TAPSE = 22 mm).
- * Mild TR. TR gradient = 25 mmHg.
- * Normal valve morphology.
- * Normal LV diastolic function.
- * No pericardial effusion.
- * No pulmonary arterial hypertension.
- * IVC normal diameter & > 50% respiratory variation.
- * No thrombus, mass, vegetation seen.

Dr.INDIRA BANERJEE ,
MD,DNB,MRCPC (UK)

Board Certified Comprehensive
Echocardiographer (USA)

