



Mees Kumari Laxmi
36y/f

Routine eyes checkup

Vitals :

BP 100/60
wt - 70 kg
HT 5.6 feet

Chief Complaints :

VM { 6/6 = glasses
6/6

H/O Present Illness :

MV { NG
NG

NCT { 12
12

Past History :


Colour vision - Normal (BE)

Investigation :

Drug Allergies : (if any)

fundus - Normal

Treatment :





LAKSHMI

Health checkup

Vitals :

Chief Complaints :

Adv

H/O Present Illness :

No reports

Past History :

Investigation :

Drug Allergies : (if any)

bagampres

Treatment :



NABL
Cert. No. MC - 4830



NABH
Cert. No. H-2015-0369

DEPARTMENT OF PATHOLOGY

Patient Name : Mrs. KUMARI LAKSHMI
MR No : 670712
Age/Sex : 36 Years 2 Months 28 Days / Female
Type : OPD
TPA/Corporate : MEDIWHEEL PVT LTD

Bill Date : 28/01/2023
Reporting Date : 28/01/2023
Sample ID : 93062
Bill/Req. No. : 24031731
Ref Doctor : Dr.RMO

Test	Result	Bio. Ref. Interval	Units	Method
BLOOD SUGAR 2 HR. PP				
BLOOD SUGAR P.P.	105	80 - 150	mg/dl	

***** END OF THE REPORT *****



Sample no.

Dr. SONIA KUMARI
MBBS, MD (PATHOLOGY) Gold medalist

Dr. PRADIP KUMAR
Consultant (Microbiology)

Dr. NISHA TIWARI
MBBS, MD (Microbiology)

USER NM SONU

(This is only professional opinion and not the diagnosis, Please correlate clinically) Page 1 of 1

Q Block South City 11, Sohna Road, Main Sector-47, Gurgaon, Haryana
Ph.: 0124-4900000 (100 Lines) Fax : 0124-2218733 E-mail : parkmedicenters@gmail.com

PARK GROUP OF HOSPITALS : West Delhi • South Delhi • Gurgaon • Karnal • Panipat • Hodal • Ambala • Behror

the **health** care providers

the **health** care providers





DEPARTMENT OF PATHOLOGY

Patient Name : Mrs. KUMARI LAKSHMI	Bill Date : 28/01/2023 10:31 AM
MR No : 670712	Sample Col Dt/Tm : 28/01/2023 04:07 pm
Age/Sex : 36 Years 2 Months 28 Days / Female	Sample Rec Dt/Tm : 28/01/2023 04:07 pm
Type : OPD	Reporting Date : 2023-01-28 00:28:00-01 16:27:
TPA/Corporate : MEDIWHEEL PVT LTD	Sample ID : 93062
Ref Doctor : Dr.RMO	Bill/Req. No. : 24031731

Test	Result	Bio. Ref. Interval	Units	Method
BLOOD SUGAR FASTING				
PLASMA GLUCOSE FASTING	81	60 - 110	mg/dl	GOD TRINDERS

***** END OF THE REPORT *****



Dr. PRADIP KUMAR
Consultant (Microbiology)

Dr. SONIA KUMARI
MD Pathology (Gold Medalist)

Dr. NISHA TIWARI
MBBS, MD (Microbiology)
USER NM SONU

(This is only professional opinion and not the diagnosis, Please correlate clinically)

Page 1 of 1

Q Block South City 11, Sohna Road, Main Sector-47, Gurgaon, Haryana
Ph.: 0124-4900000 (100 Lines) Fax : 0124-2218733 E-mail : parkmedicenters@gmail.com

PARK GROUP OF HOSPITALS : West Delhi • South Delhi • Gurgaon • Karnal • Panipat • Hodal • Ambala • Behror

the **health** care providers the **health** care providers



DEPARTMENT OF PATHOLOGY

Patient Name : Mrs. KUMARI LAKSHMI
MR No : 670712
Age/Sex : 36 Years 2 Months 28 Days / Female
Type : OPD
TPA/Corporate : MEDIWHEEL PVT LTD
Bill Date : 28/01/2023
Reporting Date : 28/01/2023
Sample ID : 93062
Bill/Req. No. : 24031731
Ref Doctor : Dr.RMO

Test	Result	Bio. Ref. Interval	Units	Method
BLOOD GROUPING AND RH FACTOR				
BLOOD GROUP	" O " RH POSITIVE			MATRIX GEL

***** END OF THE REPORT *****



Sample no.

Dr. SONIA KUMARI
MBBS, MD (PATHOLOGY) Gold medalist

Dr. PRADIP KUMAR
Consultant (Microbiology)

Dr. NISHA TIWARI
MBBS, MD (Microbiology)

USER NM SONU

(This is only professional opinion and not the diagnosis, Please correlate clinically) Page 1 of 1

Q Block South City 11, Sohna Road, Main Sector-47, Gurgaon, Haryana
Ph.: 0124-4900000 (100 Lines) Fax : 0124-2218733 E-mail : parkmedicenters@gmail.com

PARK GROUP OF HOSPITALS : West Delhi • South Delhi • Gurgaon • Karnal • Panipat • Hodal • Ambala • Behror

the **health** care providers

the **health** care providers





DEPARTMENT OF PATHOLOGY

Patient Name : Mrs. KUMARI LAKSHMI
 MR No : 670712
 Age/Sex : 36 Years 2 Months 28 Days / Female
 Type : OPD
 TPA/Corporate : MEDIWHEEL PVT LTD

Bill Date : 28/01/2023
 Reporting Date : 28/01/2023
 Sample ID : 93062
 Bill/Req. No. : 24031731
 Ref Doctor : Dr.RMO

Test	Result	Bio. Ref. Interval	Units	Method
CBC				
HAEMOGLOBIN	12.0	12 - 15	gm/dL	COLORIMETRY
TOTAL LEUCOCYTE COUNT	5200	4000-11000	/ μ L	ELECTRICAL
DIFFERENTIAL COUNT				
NEUTROPHILS	65	40.0 - 80.0	%	FLOW CYTOMETRY
LYMPHOCYTES	30	20.0 - 40.0	%	FLOW CYTOMETRY
MONOCYTES	03	2.0 - 10.0	%	FLOW CYTOMETRY
EOSINOPHILS	02	0.0 - 5.0	%	FLOW CYTOMETRY
BASOPHILS	00	0.0 - 2.0	%	FLOW CYTOMETRY
RED BLOOD CELL COUNT	4.4	3.5 - 5.5	millions/ μ L	ELECTRICAL
PACKED CELL VOLUME	36.5	35.0 - 50.0	%	ELECTRICAL
MEAN CORPUSCULAR VOLUME	82.2	L 83 - 101	fL	ELECTRICAL
MEAN CORPUSCULAR HAEMOGLOBIN	27.0	27 - 31	Picograms	CALCULATED
MEAN CORPUSCULAR HB CONC	32.9	L 33 - 37	g/dl	CALCULATED
PLATELET COUNT	195	150 - 450	thou/ μ L	ELECTRICAL
RDW	14.2	11.6 - 14.5	%	CALCULATED

***** END OF THE REPORT *****



Sample no.

Dr. SONIA KUMARI
MBBS, MD (PATHOLOGY) Gold medalist

Dr. PRADIP KUMAR
Consultant (Microbiology)

Dr. NISHA TIWARI
MBBS, MD (Microbiology)

USER NM SONU

(This is only professional opinion and not the diagnosis, Please correlate clinically) Page 1 of 1

Q Block South City 11, Sohna Road, Main Sector-47, Gurgaon, Haryana
Ph.: 0124-4900000 (100 Lines) Fax : 0124-2218733 E-mail : parkmedicenters@gmail.com

PARK GROUP OF HOSPITALS : West Delhi • South Delhi • Gurgaon • Karnal • Panipat • Hodal • Ambala • Behror

the health care providers

the health care providers





DEPARTMENT OF PATHOLOGY

Patient Name	: Mrs. KUMARI LAKSHMI	Bill Date	: 28/01/2023
MR No	: 670712	Reporting Date	: 28/01/2023
Age/Sex	: 36 Years 2 Months 28 Days / Female	Sample ID	: 93062
Type	: OPD	Bill/Req. No.	: 24031731
TPA/Corporate	: MEDIWHEEL PVT LTD	Ref Doctor	: Dr.RMO

Test	Result	Bio. Ref. Interval	Units	Method
ESR (WESTERGREN)				
E.S.R. - II HR.	30		mm II Hr.	Westergren

***** END OF THE REPORT *****



Sample no.

Dr. SONIA KUMARI
MBBS, MD (PATHOLOGY) Gold medalist

Dr. PRADIP KUMAR
Consultant (Microbiology)

Dr. NISHA TIWARI
MBBS, MD (Microbiology)

USER NM SONU

(This is only professional opinion and not the diagnosis, Please correlate clinically) Page 1 of 1

Q Block South City 11, Sohna Road, Main Sector-47, Gurgaon, Haryana
Ph.: 0124-4900000 (100 Lines) Fax : 0124-2218733 E-mail : parkmedicenters@gmail.com

PARK GROUP OF HOSPITALS : West Delhi • South Delhi • Gurgaon • Karnal • Panipat • Hodal • Ambala • Behror

the **health** care providers the **health** care providers





DEPARTMENT OF PATHOLOGY

Patient Name : Mrs. KUMARI LAKSHMI
 MR No : 670712
 Age/Sex : 36 Years 2 Months 28 Days / Female
 Type : OPD
 TPA/Corporate : MEDIWHEEL PVT LTD

Bill Date : 28/01/2023
 Reporting Date : 28/01/2023
 Sample ID : 93062
 Bill/Req. No. : 24031731
 Ref Doctor : Dr.RMO

Test	Result	Bio. Ref. Interval	Units	Method
LFT (LIVER FUNCTION TEST)				
LFT				
TOTAL BILIRUBIN	0.4	0 - 1.2	mg/dL	DIAZO
DIRECT BILIRUBIN	0.2	0 - 0.4	mg/dL	DIAZO
INDIRECT BILIRUBIN	0.2	0.10 - 0.6	mg/dL	CALCULATED
SGOT (AST)	18	0 - 45	U/L	IFCC WITH JUT
SGPT (ALT)	15	0 - 45	U/L	IFCC WITH JUT
ALKALINE PHOSPHATASE	97	30 - 170	IU/L	MODIFIED IECC
TOTAL PROTEINS	7.3	6.4 - 8.0	g/dL	BIURET
ALBUMIN	4.1	3.3 - 5.5	g/dL	BCG DYE
GLOBULIN	3.2	2.3 - 4.5	g/dL	CALCULATED
A/G RATIO	1.28	1.1 - 2.2		CALCULATED

***** END OF THE REPORT *****



Sample no.

Dr. SONIA KUMARI
 MBBS, MD (PATHOLOGY) Gold medalist

Dr. PRADIP KUMAR
 Consultant (Microbiology)

Dr. NISHA TIWARI
 MBBS, MD (Microbiology)

USER NM SONU

(This is only professional opinion and not the diagnosis, Please correlate clinically)

Q Block South City 11, Sohna Road, Main Sector-47, Gurgaon, Haryana
 Ph.: 0124-4900000 (100 Lines) Fax : 0124-2218733 E-mail : parkmedicenters@gmail.com Page 1 of 1

PARK GROUP OF HOSPITALS : West Delhi • South Delhi • Gurgaon • Karnal • Panipat • Hodal • Ambala • Behror

the health care providers the health care providers





DEPARTMENT OF PATHOLOGY

Patient Name : Mrs. KUMARI LAKSHMI
MR No : 670712
Age/Sex : 36 Years 2 Months 28 Days / Female
Type : OPD
TPA/Corporate : MEDIWHEEL PVT LTD

Bill Date : 28/01/2023
Reporting Date : 28/01/2023
Sample ID : 93062
Bill/Req. No. : 24031731
Ref Doctor : Dr.RMO

Test	Result	Bio. Ref. Interval	Units	Method
KFT (RENAL PROFILE)				
KFT				
SERUM UREA	28	10 - 45	mg/dL	UREASE-GLDH
SERUM CREATININE	1.0	0.4 - 1.4	mg/dL	MODIFIED JAFFES
SERUM URIC ACID	4.8	2.5 - 7.0	mg/dL	URICASE
SERUM SODIUM	143	136 - 148	mmol/L	ISE
SERUM POTASSIUM	4.2	3.5 - 5.5	meq/l	ISE
SERUM CALCIUM	8.9	8.5 - 10.5	mg/dL	ARSENAZO III
SERUM PHOSPHORUS	3.1	2.5 - 4.5	mg/dL	AMMONIUM

***** END OF THE REPORT *****



Sample no.

Dr. SONIA KUMARI
MBBS, MD (PATHOLOGY) Gold medalist

Dr. PRADIP KUMAR
Consultant (Microbiology)

Dr. NISHA TIWARI
MBBS, MD (Microbiology)
USER NM SONU

(This is only professional opinion and not the diagnosis, Please correlate clinically)

Q Block South City 11, Sohna Road, Main Sector-47, Gurgaon, Haryana
Ph.: 0124-4900000 (100 Lines) Fax : 0124-2218733 E-mail : parkmedicenters@gmail.com

Page 1 of 1

PARK GROUP OF HOSPITALS : West Delhi • South Delhi • Gurgaon • Karnal • Panipat • Hodal • Ambala • Behror

the health care providers the health care providers





NABL
Cert. No. NC - 4328



NABH
Cert. No. H-2015-0301

DEPARTMENT OF PATHOLOGY

Patient Name : Mrs. KUMARI LAKSHMI
MR No : 670712
Age/Sex : 36 Years 2 Months 28 Days / Female
Type : OPD
TPA/Corporate : MEDIWHEEL PVT LTD

Bill Date : 28/01/2023
Reporting Date : 28/01/2023
Sample ID : 93062
Bill/Req. No. : 24031731
Ref Doctor : Dr.RMO

Test	Result	Bio. Ref. Interval	Units	Method
LIPID PROFILE				
LIPID PROFILE				
TOTAL CHOLESTEROL	130	0 - 250	mg/dL	CHOD -Tris Jer
SERUM TRIGLYCERIDES	125	60 - 165	mg/dl	GPO-TRINER
HDL-CHOLESTEROL	37	30 - 70	mg/dl	DIRECT
VLDL CHOLESTEROL	25	6 - 32	mg/dL	calculated
LDL	68	50 - 135	mg/dl	calculated
LDL CHOLESTEROL/HDL RATIO	1.8	1.0 - 3.0	mg/dL	calculated
TOTAL CHOLESTEROL/HDL RATIO	3.5	2.0 - 5.0	mg/dl	calculated

***** END OF THE REPORT *****



Sample no.

Dr. SONIA KUMARI
MBBS, MD (PATHOLOGY) Gold medalist

Dr. PRADIP KUMAR
Consultant (Microbiology)

Dr. NISHA TIWARI
MBBS, MD (Microbiology)

USER NM SONU

(This is only professional opinion and not the diagnosis, Please correlate clinically)

Q Block South City 11, Sohna Road, Main Sector-47, Gurgaon, Haryana
Ph.: 0124-4900000 (100 Lines) Fax : 0124-2218733 E-mail : parkmedicenters@gmail.com

Page 1 of 1

PARK GROUP OF HOSPITALS : West Delhi • South Delhi • Gurgaon • Karnal • Panipat • Hodal • Ambala • Behror

the health care providers

the health care providers





DEPARTMENT OF RADIOLOGY

Patient Name	Mrs. KUMARI LAKSHMI	Billed Date	: 28/01/2023	10.31 AM
Reg No	670712	Reported Date	: 28/01/2023	
Age/Sex	36 Years 2 Months 28Days / Female	Req. No.	: 24031731	
Type	OPD	Consultant Doctor	: Dr. RMO	

X-RAY CHEST AP/PA

X-RAY CHEST P.A. VIEW

Bilateral lungs appears normal.

No focal lung lesion seen.

No evidence of free fluid is seen.

Both hila are normal in size, have equal density and bear normal relationship.

The heart and trachea are central in position and no mediastinal abnormality is visible.

The cardiac size is normal for patient age and view.

The domes of the diaphragms are normal in position, and show smooth outline.

To be correlated clinically



Dr. ANSHU K. SHARMA
MBBS, MD
CONSULTANT RADIOLOGIST

Dr. MANJEET SEHRAWAT
MBBS, MD, PDCC
CONSULTANT RADIOLOGIST

Dr. NEENA SIKKA
MBBS, DNB
CONSULTANT RADIOLOGIST

(This is only professional opinion and not the diagnosis, Please correlate clinically)

Q Block South City 11, Sohna Road, Main Sector-47, Gurgaon, Haryana
Ph.: 0124-4900000 (100 Lines) Fax : 0124-2218733 E-mail : parkmedicenters@gmail.com

PARK GROUP OF HOSPITALS : West Delhi • South Delhi • Gurgaon • Karnal • Panipat • Hodal • Ambala • Behror

the **health** care providers the **health** care providers



DEPARTMENT OF PATHOLOGY

Patient Name : Mrs. KUMARI LAKSHMI
MR No : 670712
Age/Sex : 36 Years 2 Months 28 Days / Female
Type : OPD
TPA/Corporate : MEDIWHEEL PVT LTD

Bill Date : 28/01/2023
Reporting Date : 30/01/2023
Sample ID : 93062
Bill/Req. No. : 24031731
Ref Doctor : Dr.RMO

Test	Result	Bio. Ref. Interval	Units	Method
URINE C/S				
NAME OF SPECIMEN	URINE			
ORGANISM IDENTIFIED	NO GROWTH SEEN IN CULTURE AFTER 48 HRS OF INCUBATION AT 37 C DEGREE.			Aerobic culture
Method :				
Note :				

***** END OF THE REPORT *****



Sample no.

Dr. SONIA KUMARI
MBBS, MD (PATHOLOGY) Gold medalist

Dr. PRADIP KUMAR
Consultant (Microbiology)

Dr. NISHA TIWARI
MBBS, MD (Microbiology)
USER NM ANJALIPA911

(This is only professional opinion and not the diagnosis, Please correlate clinically) Page 1 of 1

Q Block South City 11, Sohna Road, Main Sector-47, Gurgaon, Haryana
Ph.: 0124-4900000 (100 Lines) Fax : 0124-2218733 E-mail : parkmedicenters@gmail.com

PARK GROUP OF HOSPITALS : West Delhi • South Delhi • Gurgaon • Karnal • Panipat • Hodal • Ambala • Behror

the health care providers the health care providers



DEPARTMENT OF PATHOLOGY

Patient Name : Mrs. KUMARI LAKSHMI
MR No : 670712
Age/Sex : 36 Years 2 Months 28 Days / Female
Type : OPD
TPA/Corporate : MEDIWHEEL PVT LTD

Bill Date : 28/01/2023
Reporting Date : 29/01/2023
Sample ID : 93062
Bill/Req. No. : 24031731
Ref Doctor : Dr.RMO

Test	Result	Bio. Ref. Interval	Units	Method
THYROID PROFILE				
TRI-IODOTHYRONINE (T3)	1.37	0.60 - 1.81	ng/ml	Chemiluminescence
THYROXINE (T4)	9.7	5.01 - 12.45	µg/dL	Chemiluminescence
THYROID STIMULATING HORMONE	4.30	0.5-5.50	µIU/ml	
SPECIMEN TYPE	SERUM			
Method : chemiluminescent immunoassay				

Note : Clinical Significance:

Thyroid function tests (TFTs) is a collective term for blood tests used to check the function of the thyroid. TFTs may be requested if a patient is thought to suffer from hyperthyroidism (overactive thyroid) or hypothyroidism (underactive thyroid), or to monitor the effectiveness of either thyroid-suppression or hormone replacement therapy. It is also requested routinely in conditions linked to thyroid disease, such as atrial fibrillation and anxiety disorder. A TFT panel typically includes thyroid hormones such as thyroid-stimulating hormone (TSH, thyrotropin) and thyroxine (T4), and triiodothyronine (T3) depending on local laboratory policy.

Note: Please correlate with clinical condition

***** END OF THE REPORT *****



Sample No.

Dr. SONIA KUMARI
MBBS, MD (PATHOLOGY) Gold medalist

Dr. PRADIP KUMAR
Consultant (Microbiology)

Dr. NISHA TIWARI
MBBS, MD (Microbiology)

USER NM DINESH

(This is only professional opinion and not the diagnosis, Please correlate clinically) Page 1 of 1

Q Block South City 11, Sohna Road, Main Sector-47, Gurgaon, Haryana
Ph.: 0124-4900000 (100 Lines) Fax : 0124-2218733 E-mail : parkmedicenters@gmail.com

PARK GROUP OF HOSPITALS : West Delhi • South Delhi • Gurgaon • Karnal • Panipat • Hodal • Ambala • Behror



DEPARTMENT OF RADIOLOGY

Cert. No. MC-1830 Cert. No. H-2019-1563

Patient Name	Mrs. KUMARI LAKSHMI	Billed Date	: 28/01/2023	10.31 AM
Reg No	670712	Reported Date	: 28/01/2023	
Age/Sex	36 Years 2 Months 28Days / Female	Req. No.	: 24031731	
Type	OPD	Consultant Doctor	: Dr. RMO	

USG WHOLE ABDOMEN

The real time, B mode, gray scale sonography of the abdominal organs was performed.

LIVER : The liver is normal in size 13.8cm **with fatty infiltration**. No evidence of any focal lesion. IHBR is not dilated.

GALL BLADDER : The gall bladder is well distended , No evidence any calculus or mass seen.GB wall thickness with in normal limits.No evidence of pericholecystic fluid is seen.

BILE DUCT :The common bile duct is normal in caliber. No evidence of calculus is noted in common bile duct.

SPLEEN :The spleen is normal in size 8.8cm and shape.Its echotexture is homogeneous.No evidence of focal lesion is noted.

PANCREAS :The pancreas is normal in size, shape, contours and echotexture.No evidence of solid or cystic mass lesion is noted.MPD is not dilated. No evidence of peripancreatic collection.

KIDNEYS :The bilateral kidneys are normal in size and echotexture. Cortico-medullary differentiation is maintained.There is no evidence of obvious calculus or hydronephrosis.

URINARY BLADDER :The urinary bladder is well distended.It shows uniformly thin walls and sharp mucosa.No evidence of calculus is seen. No evidence of mass or diverticulum is noted.

UTERUS: The uterus is anteverted. It measures 7.6x4.6x4.9 cms. in the longitudinal, anteroposterior and transverse dimensions respectivelyThe uterine margins is smooth and does not reveal any contour abnormalities.(IUCD seen in situ)
The uterine myometrium shows homogeneous echotexture.
No evidence of leiomyoma is noted. No solid or cystic mass lesion is noted.
The endometrial echo is in the midline .
The ovaries on the either side show normal echotexture.
No adnexal mass is seen.No cyst is seen in ovaries.
No evidence of ascites or interbowel free fluid is seen.
No evidence of obvious retroperitoneal or mesantric lymphadenopathy is seen.



IMPRESSION- Fatty liver grade-I

To be correlated clinically.

Dr. ANSHU K. SHARMA
MBBS, MD
CONSULTANT RADIOLOGIST

Dr. MANJEET SEHRAWAT
MBBS, MD, PDCC
CONSULTANT RADIOLOGIST

Dr. NEENA SIKKA
MBBS, DNB
CONSULTANT RADIOLOGIST

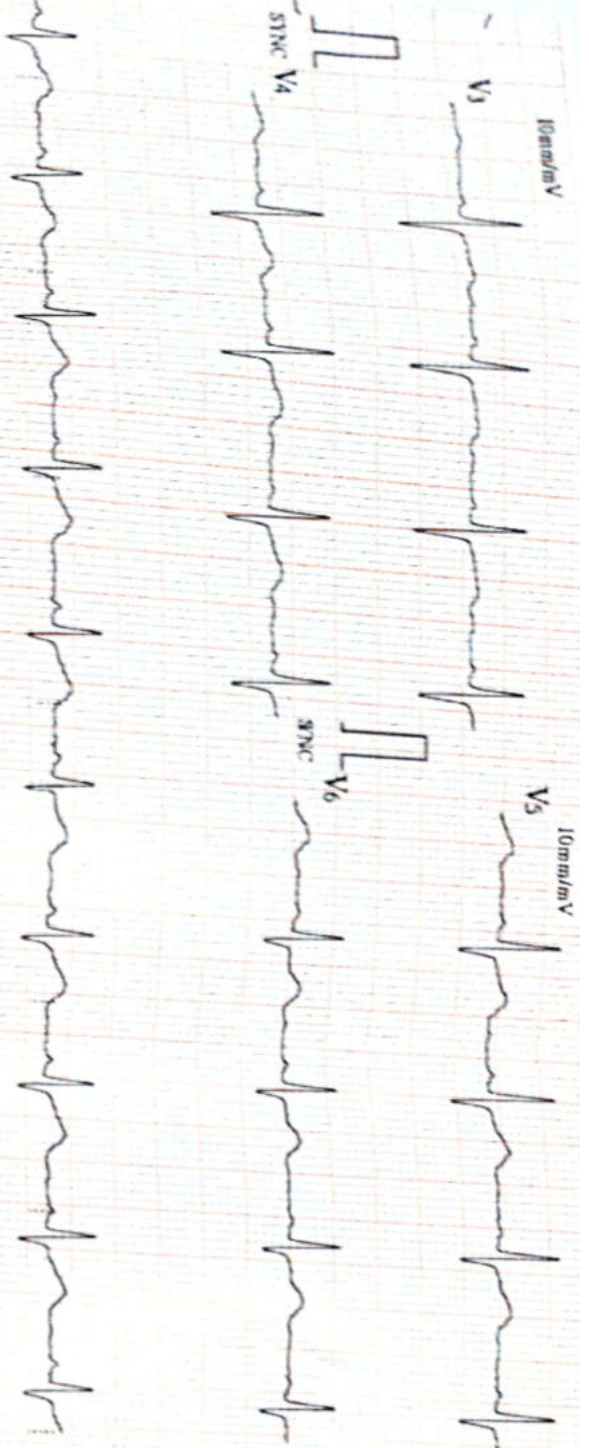
(This is only professional opinion and not the diagnosis, Please correlate clinically)

Q Block South City 11, Sohna Road, Main Sector-47, Gurgaon, Haryana
Ph.: 0124-4900000 (100 Lines) Fax : 0124-2218733 E-mail : parkmedicenters@gmail.com

PARK GROUP OF HOSPITALS : West Delhi • South Delhi • Gurgaon • Karnal • Panipat • Hodal • Ambala • Behror

the **health** care providers

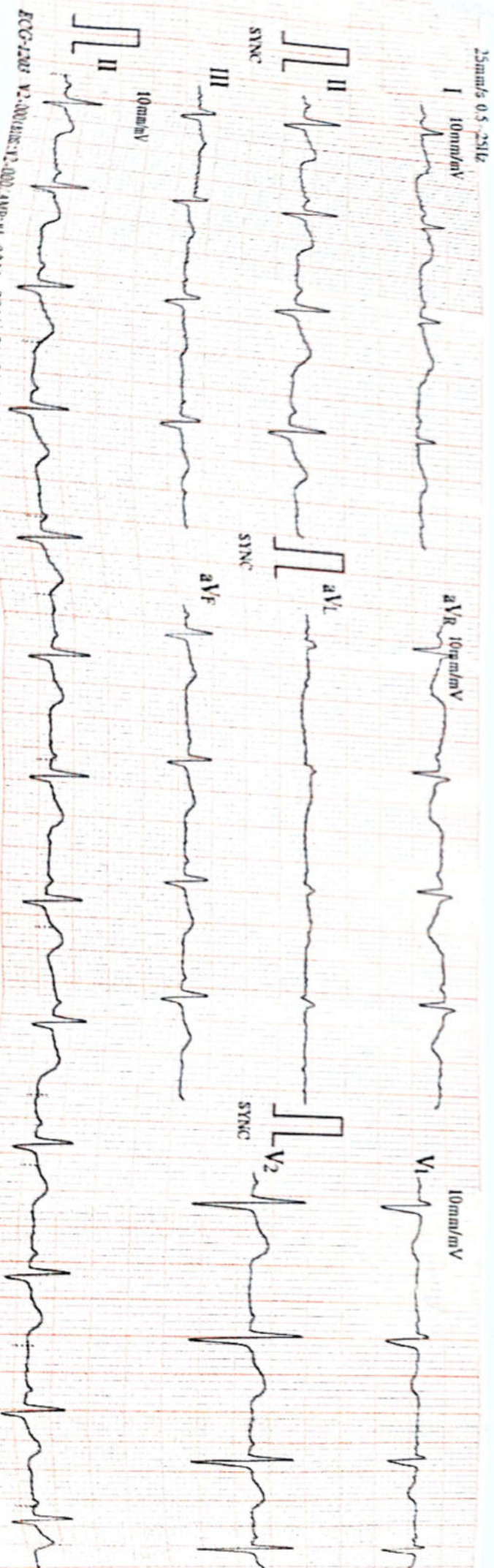
the **health** care providers



ID : 0301
 HR : 72
 Name: Kumari Lakshmi
 E-R : 72.3
 Sex : Female
 PRS : 95
 Age : 36 (Y)
 QT/QTc : 373/438
 P/QTc/T : 39/-3/51
 RV5/VI : 0.730/0.510 mV
 RV5/VI : 1.240 mV

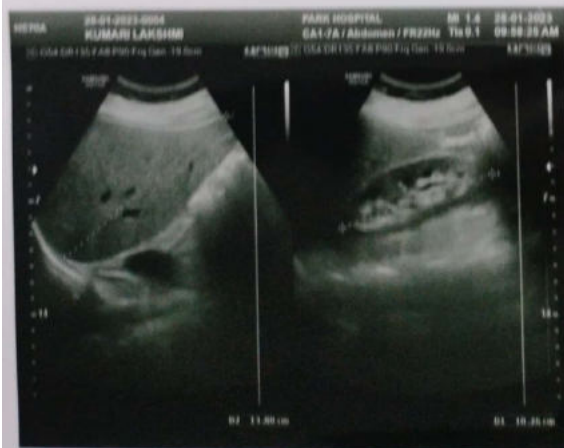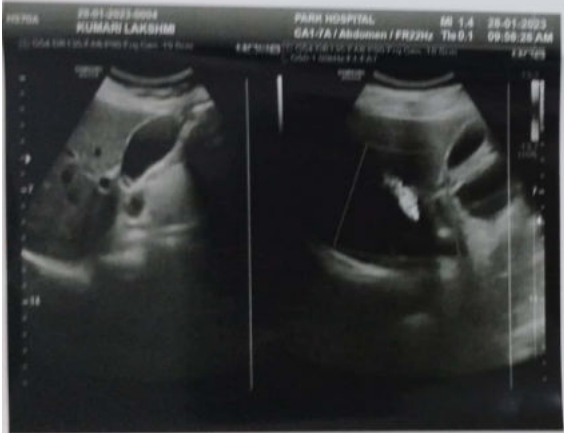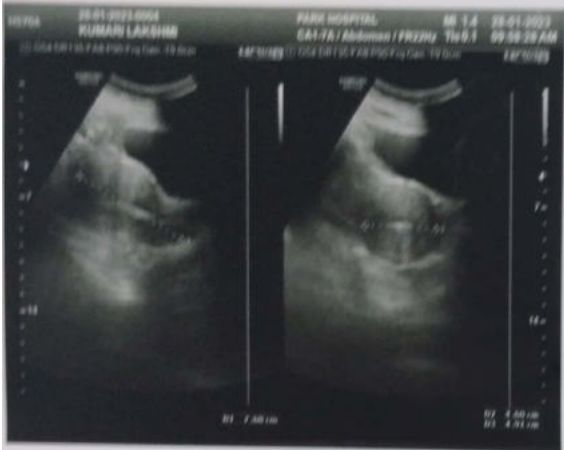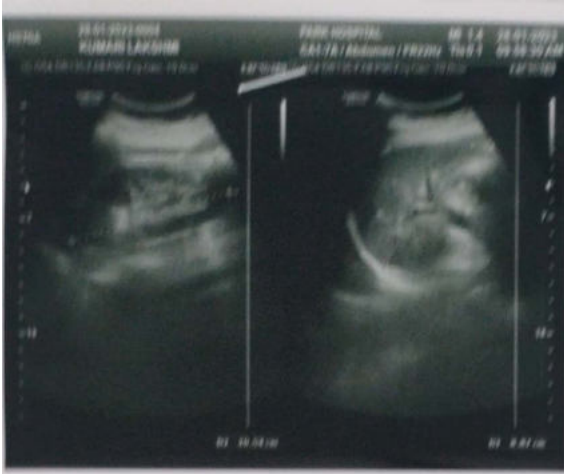Sinus Rhythm
 Short P-R Interval
 T Abnormality (Flat T)
 Mild Left Axis Deviation

Unconfirmed Report Verified by:

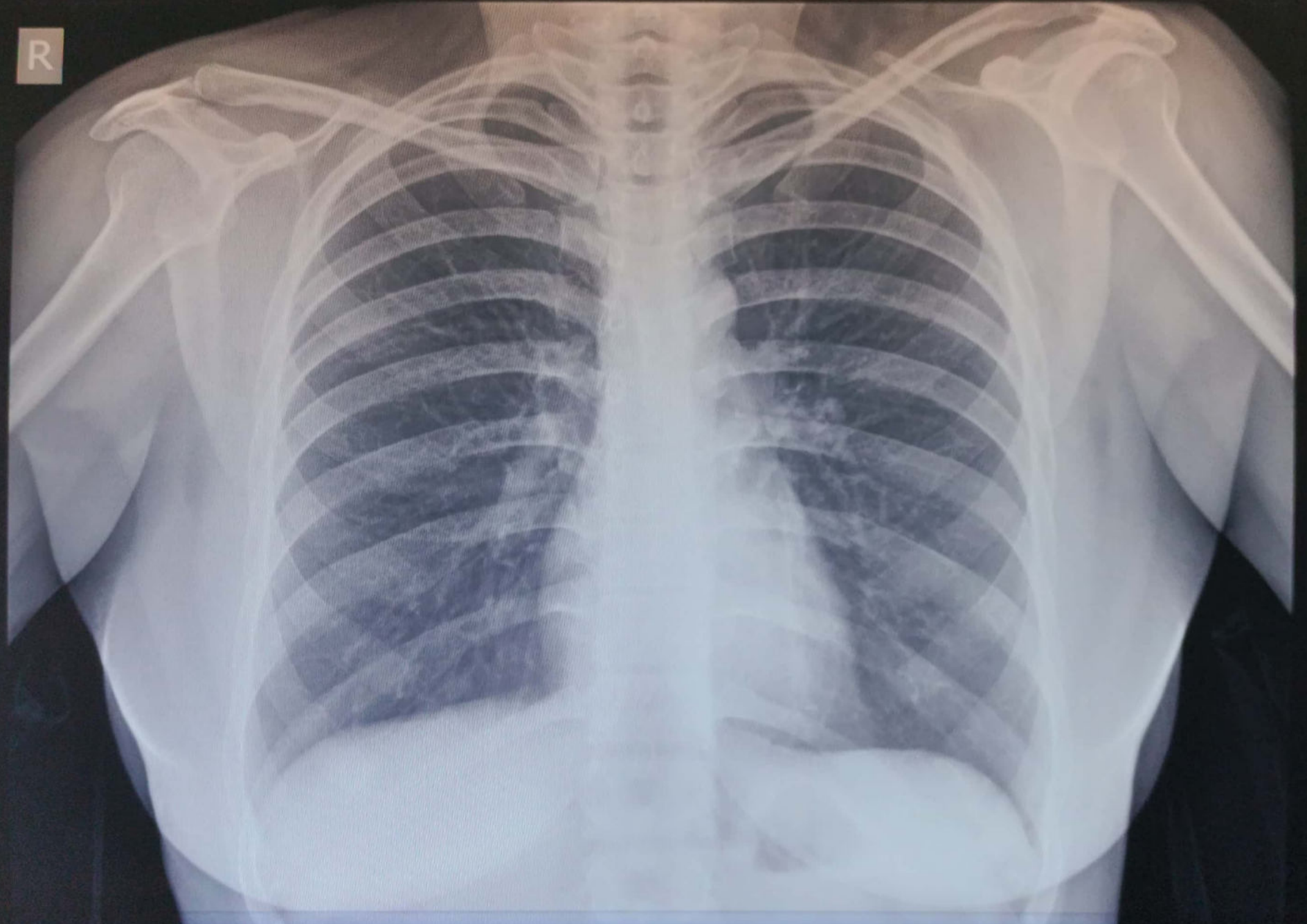


25mm/s 0.5 mV
 10mm/mV
 SYNC
 II
 I
 III
 aVR
 aVL
 aVF
 V1
 V2
 SYNC
 II
 I
 III
 aVR
 aVL
 aVF
 V1
 V2
 SYNC

ECG-12345 V2:001 (NS:12:00) AMP:11.001 2016-01-01 00:01



R



KUMARI LAKSHMI 36Y Female Chest PA REQ-24031680 1/28/2023 9:30:18 AM
PARK HOSPITAL, SOUTH CITY II, GURGAON, HARYANA

30%