



# Savita

**Superspeciality Hospital**  
(A Unit of Solace Healthcare Pvt. Ltd.)

Parivar Char Rasta, Waghodia-Dabhoi Ring Road, Vadodara-390019

☎ 0265-2578844 / 2578849 ✉ mh@savitahospital.com 🌐 savitahospital.com

## Examination By Ophthalmologist

<b>Name :</b>	<b>ANANT D RATHORE</b>	<b>Age :</b>	<b>33/MALE</b>
<b>Reg.No :</b>	<b>20220310989</b>	<b>DOE :</b>	<b>22/04/2023</b>
<b>Present Complaints :</b>	<b>NAD</b>		
<b>Medical History :</b>	<b>NAD</b>		
<b>Examination Of Eye :</b>	<b>NAD</b>		
<b>External Examination :</b>	<b>NAD</b>	<b>NAD</b>	
<b>Ati Seg Examination :</b>	<b>A/S: WNL</b>		
<b>Schiotz Tonometry IOP :</b>	<b>P:RRRL</b>		
<b>Fundus :</b>	<b>NILL</b>		
<b>Without Glass</b>	<b>Distant Vision : 6/6</b>	<b>6/6</b>	
	<b>Near Vision : N6</b>	<b>N6</b>	
<b>With Glass</b>	<b>Distant Vision :</b>		
	<b>Near Vision :</b>		
<b>Colour Vision (With Ishihara Chart) :</b>	<b>WNL</b>		
<b>Advice :</b>	<b>NAD</b>		



**DR CHETAN CHAUHAN**



## PHYSICIAN EXAMINATION

<b>Name :</b>	<b>ANANT D RATHORE</b>	<b>Age :</b>	<b>33/MALE</b>
<b>Reg.No :</b>	<b>20220310989</b>	<b>DOE :</b>	<b>22/04/2023</b>

### Physical Examination:

<b>Height:</b>	<b>179CM</b>	<b>Weight:</b>	<b>75 KG</b>	<b>PULSE:</b>	<b>98</b>	<b>Temperature:</b>	<b>NORMAL</b>
----------------	--------------	----------------	------------------	---------------	-----------	---------------------	---------------


<b>BMI :</b>	<b>23.40</b>	<b>BP :</b>	<b>132/80</b>	<b>SPO2</b>	<b>98%</b>
--------------	--------------	-------------	---------------	-------------	------------

<b>Chief Complaint :</b>	<b>NAD</b>
<b>Past History :</b>	<b>NAD</b>
<b>General Examination :</b>	<b>NAD</b>
<b>Systemic Examination :</b>	<b>NAD</b>
<b>INVESTIGATION :</b>	<b>NAD</b>
<b>ADVICE :</b>	<b>TAB: NEUROBLISS (MD) 1--0--0 (30DAYS)</b>




**DR. SAURABH JAIN**



<b>Patient Name :</b>	Anant Deepsingh Rathore	<b>Sample No. :</b>	20230400900 
<b>Patient ID :</b>	20220310989	<b>Visit No. :</b>	OPD20230401670
<b>Age / Sex :</b>	33y 1m/Male	<b>Call. Date :</b>	22/04/2023 09:17
<b>Consultant :</b>	DR SAURABH JAIN	<b>S. Coll. Date :</b>	22/04/2023 09:48
<b>Ward :</b>	-	<b>Report Date :</b>	22/04/2023 13:49

**Urine R/M**

Investigation	Result	Normal Value
Quantity - :	20 ml	
Colour - :	Pale Yellow	
Reaction (pH) :	7.0	4.6-8.0
Turbidity :	Clear	
Deposit :	Absent	Absent
Sp.Gravity :	1.010	1.005-1.010
Protein :	Absent	Absent
Glucose :	Absent	Absent
Bile Salts :	Absent	Absent
Bile pigments :	Absent	Absent
Ketones :	Absent	Absent
Urobilinogen :	Absent	
Blood :	Absent	Absent
Pus Cells :	0-1 /hpf	0-5/hpf
Red Blood Cells :	Absent /hpf	Absent
Epithelial Cells :	1-2 /hpf	



**Dr.Mehul Desai**  
**M.B.D.C.P**  
**Reg.No.G-9521**



Unipath Specialty Laboratory (Baroda) LLP - Platinum Complex, Opp. HDFC Bank, Nr. Radha Krishna char rasta, Akota, Vadodara - 390020  
Mobile: 9998724579 / 8155028222 | Email: info.baroda@unipathllp.in



## TEST REPORT

Reg. No. : 30401011483      Reg. Date : 22-Apr-2023 12:14      Collected On : 22-Apr-2023 12:14  
Name : Mr. ANANT RATHORE      Approved On : 22-Apr-2023 13:20  
Age : 33 Years      Gender : Male      Ref. No. :      Dispatch At :  
Ref. By :      Tele No. :  
Location : SAVITA SUPERSPECIALTY HOSPITAL @ WAGHODIYA ROAD

Test Name	Results	Units	Bio. Ref. Interval
<b>THYROID FUNCTION TEST</b>			
T3 (triiodothyronine) <i>Method:CLIA</i>	1.38	ng/mL	0.6 - 1.81
T4 (Thyroxine) <i>Method:CLIA</i>	9.60	µg/dL	4.5 - 12.6
TSH ( ultra sensitive) <i>Method:CLIA</i>	4.486	µIU/mL	0.55 - 4.78
Sample Type:Serum			

**Comments:**

Thyroid stimulating hormone (TSH) is synthesized and secreted by the anterior pituitary in response to a negative feedback mechanism involving concentrations of FT3 (free T3) and FT4 (free T4). Additionally, the hypothalamic tripeptide, thyrotropin-releasing hormone (TRH), directly stimulates TSH production. TSH stimulates thyroid cell production and hypertrophy, also stimulate the thyroid gland to synthesize and secrete T3 and T4. Quantification of TSH is significant to differentiate primary (thyroid) from secondary (pituitary) and tertiary (hypothalamus) hypothyroidism. In primary hypothyroidism, TSH levels are significantly elevated, while in secondary and tertiary hypothyroidism, TSH levels are low.

**TSH levels During Pregnancy :**

- First Trimester : 0.1 to 2.5 µIU/mL
- Second Trimester : 0.2 to 3.0 µIU/mL
- Third trimester : 0.3 to 3.0 µIU/mL

Reference : Carl A.Burtis,Edward R.Ashwood,David E.Bruns. Tietz Textbook of Clinical Chemistry and Molecular Diagnostics. 5th Eddition. Philadelphia: WB Saunders,2012:2170

This is an electronically authenticated report.

Test done from collected sample.

Dr. Vishal Jhaveri



**Patient Name :** Anant Deepsingh Rathore

**Sample No. :** 20230400900



**Patient ID :** 20220310989

**Visit No. :** OPD20230401670

**Age / Sex :** 33y 1m/Male

**Call. Date :** 22/04/2023 09:17

**Consultant :** DR SAURABH JAIN

**S. Coll. Date :** 22/04/2023 09:48

**Ward :** -

**Report Date :** 22/04/2023 13:49

### Lipid Profile

Investigation	Result	Normal Value
Sample :	Fasting	
Sample Type :	Normal	
Cholesterol (Chol) :	166 mg/dl	Low risk : < 200 Moderate risk : 200 - 239 High risk : > or = 240
Triglyceride :	109 mg/dl	Normal : < 200.0 High : 200 - 499 Very High : > or = 500
HDL Cholesterol :	39 mg/dl [ L ]	Low risk : > or = 60 mg/dL High risk : Up to 35 mg/dL
LDL :	105.2 mg/dl [ L ]	131.0 to 159.0(N) < 130.0(L) > 159.0(H)
VLDL :	21.8 mg/dl	Up to 0 to 34 mg/dl
LDL/HDL Ratio :	2.7	Low risk : 0.5 to 3.0 Moderate risk : 3.0 to 6.0 Elevted level high > 6.0
Total Chol / HDL Ratio :	4.26	Low Risk : 3.3 to 4.4 Average Risk : 4.4 to 7.1 Moderate Risk : 7.1 to 11.0 High Risk : > 11.0
Total Lipids :	614 mg/dl	400 to 700 mg/dl

**Note :-** Lipemic samples give high triglyceride value and falsely low LDL value.

**Dr. Mehul Desai**  
**M.B.D.C.P**  
**Reg.No.G-9521**



**Patient Name :** Anant Deepsingh Rathore

**Sample No. :** 20230400900



**Patient ID :** 20220310989

**Visit No. :** OPD20230401670

**Age / Sex :** 33y 1m/Male

**Call. Date :** 22/04/2023 09:17

**Consultant :** DR SAURABH JAIN

**S. Coll. Date :** 22/04/2023 09:48

**Ward :** -

**Report Date :** 22/04/2023 13:49

**LFT (Liver Function Test)**

Investigation	Result	Normal Value
Total Bilirubin :	1.2 mg/dl	0.2 to 1.0 mg/dl
Direct Bilirubin :	0.4 mg/dl	0.0 to 0.2 mg/dl
Indirect Bilirubin :	0.8 mg/dl	0.0 to 0.8 mg/dl
AST (SGOT) :	12 U/L	5 to 34 U/L
ALT (SGPT) :	14 U/L	0 to 55 U/L
Total Protein (TP) :	6.9 g/dL	6.4 to 8.3, g/dl
Albumin (ALB) :	4.1 g/dl	3.5 to 5.2 g/dl
Globulin :	2.8 g/dl	2.3 to 3.5 g/dl
A/G Ratio :	1.46	
Alkaline Phosphatase (ALP) :	88 U/L	40 to 150 U/L
GAMMA GT. :	23 U/L	7 to 35 U/L

**Dr.Mehul Desai**  
**M.B.D.C.P**  
**Reg.No.G-9521**



**Patient Name :** Anant Deepsingh Rathore

**Sample No. :** 20230400900



**Patient ID :** 20220310989

**Visit No. :** OPD20230401670

**Age / Sex :** 33y 1m/Male

**Call. Date :** 22/04/2023 09:17

**Consultant :** DR SAURABH JAIN

**S. Coll. Date :** 22/04/2023 09:48

**Ward :** -


**Report Date :** 22/04/2023 13:49

### RENAL FUNCTION TEST

Investigation	Result	Normal Value
Creatinine :	0.8 mg/dl	0.6 - 1.4 mg/dl
Urea :	13 mg/dl	13 - 45 mg/dl
Uric Acid :	5.7 mg/dl	3.5 - 7.2 mg/dl
Calcium :	10 mg/dl	8.5 - 10.5
Phosphorus :	5.2 mg/dl	1.5 - 6.8

**Dr. Mehul Desai**  
**M.B.D.C.P**  
**Reg.No.G-9521**



<b>Patient Name :</b>	Anant Deepsingh Rathore	<b>Sample No. :</b>	20230400900 
<b>Patient ID :</b>	20220310989	<b>Visit No. :</b>	OPD20230401670
<b>Age / Sex :</b>	33y 1m/Male	<b>Call. Date :</b>	22/04/2023 09:17
<b>Consultant :</b>	DR SAURABH JAIN	<b>S. Coll. Date :</b>	22/04/2023 09:48
<b>Ward :</b>	-	<b>Report Date :</b>	22/04/2023 13:49

### Blood Group


Investigation	Result	Normal Value
<b>BLOOD GROUP :</b>		
<b>ABO</b>	O	
<b>Rh</b>	Positive	

### FBS & PPBS

Investigation	Result	Normal Value
Blood Sugar (FBS) :	97 mg/dl	74 - 100 mg/dl
Urine Sugar ( FUS ) :	Nil	
Blood Sugar (PP2BS) :	103 mg/dl	70 to 120 mg/dl
Urine Sugar ( PP2US ) :	Nil	

### HBA1C

Investigation	Result	Normal Value
Glycosylated Hb :	5.7 %	Near Normal Glycemia : 6 to 7 Excellent Control : 7 to 8 Good Control : 8 to 9 Fair Control : 9 to 10 Poor Control : > 10
Average Plasma Glucose of Last 3 Months :	116.89	



**Dr. Mehul Desai**  
**M.B.D.C.P**  
**Reg.No.G-9521**





**Patient Name :** Anant Deepsingh Rathore

**Sample No. :** 20230400900



**Patient ID :** 20220310989

**Visit No. :** OPD20230401670

**Age / Sex :** 33y 1m/Male

**Call. Date :** 22/04/2023 09:17

**Consultant :** DR SAURABH JAIN

**S. Coll. Date :** 22/04/2023 09:48

**Ward :** -

**Report Date :** 22/04/2023 13:49

### CBC, ESR

Investigation	Result	Normal Value
Hemoglobin :	16.1 gm/dl	13.5 to 18.0 gm/dl
P.C.V. :	45.6 %	42.0 to 52.0 %
M.C.V. :	85.6 fL	78 to 100 fL
M.C.H. :	30.2 pg	27 to 31 pg
M.C.H.C. :	35.3 g/dl	32 to 36 g/dl
RDW :	11.5 %	11.5 to 14.0 %
RBC Count :	5.33 X 10 <sup>6</sup> /cumm	4.7 to 6.0 X 10 <sup>6</sup> /cumm
Polymorphs :	74 % [H]	38 to 70 %
Lymphocytes :	22 %	15 to 48 %
Eosinophils :	2 %	0 to 6 %
Monocytes :	2 % [L]	3 to 11 %
Basophils :	0 %	0.0 to 1.0 %
Total :	100	< 100 > 100
WBC Count :	7400 /cmm	4000 to 10000 /cmm
Platelets Count :	204000 /cmm	1,50,000 to 4,50,000 /cmm
ESR - After One Hour :	11 mm/hr	1 to 13 mm/hr

**Dr. Mehul Desai**  
**M.B.D.C.P**  
**Reg.No.G-9521**

33 Years

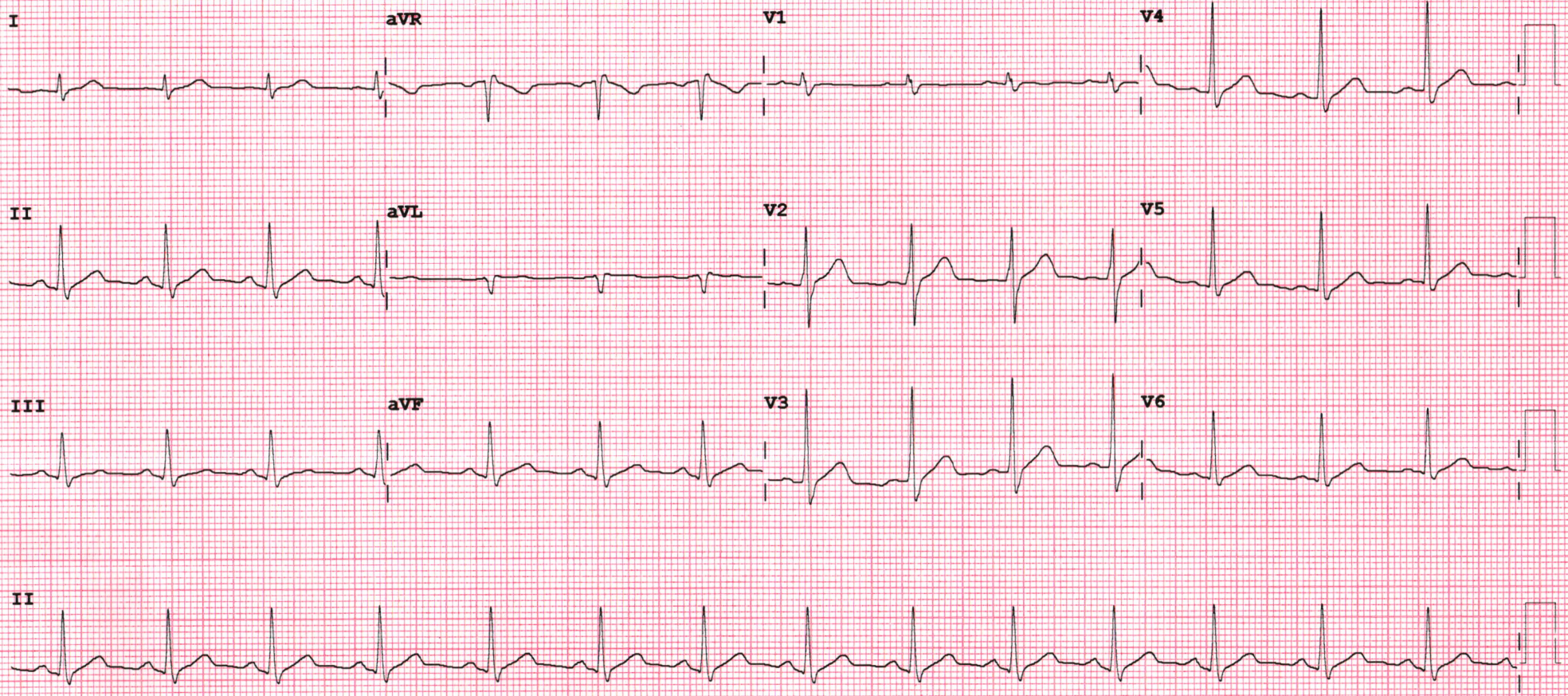
Male

Rate 86  
 PR 156  
 QRSD 112  
 QT 356  
 QTc 426

--AXIS--

P 81  
 QRS 80  
 T 52

12 Lead; Standard Placement



Device: Speed: 25 mm/sec Limb: 10 mm/mV Chest: 10.0 mm/mV F 50~ 0.50-150 Hz W PH09 P?

PHILIPS

REORDER M3708A



**2D-ECHOCARDIOGRAPHY AND COLOR DOPPLER REPORT**

**NAME: ANANT RATHORE**

**AGE/SEX: 33 YRS/ MALE**

**DATE: 22/04/2023**

**REF BY: DIRECT**

**OBSERVATION:**

- NORMAL LV SIZE AND NORMAL LV SYSTOLIC FUNCTION. LVEF = 60% (VISUAL).
- NO RWMA AT REST.
- NORMAL LV DIASTOLIC FUNCTION..
- NO MR. NO MS.
- NO AR. NO AS.
- NO TR. NO PAH.
- NORMAL SIZED LA, RA, RV WITH NORMAL RV SYSTOLIC FUNCTION.
- NORMAL SIZED MPA, RPA & LPA.
- INTACT IAS AND IVS.
- NO E/O INTRACARDIAC CLOT/VEGETATION/PE.
- NORMAL IVC.
- NORMAL PERICARDIUM.

**LA: 24 MM**

**AO: 20 MM**

**IVS: 09/12 MM**

**LVPW: 08/12MM**


**LVID: 46/32 MM**

**CONCLUSION:**

- NORMAL LV / RV SIZE AND SYSTOLIC FUNCTION.
- NO RWMA AT REST.
- LVEF = 60 % (VISUAL).

**DR.NIRAV BHALANI**  
[CARDIOLOGIST]

**DR.ARVIND SHARMA**  
[CARDIOLOGIST]

  
**DR. DARSHAN THAKKAR**  
[CARDIOLOGIST]



Patient name	ANANT RATHORE
Age / Sex	33 Y/M
Date	Saturday, 22 April 2023

**ULTRASOUND OF ABDOMEN**

**LIVER** appears normal in size (14.0 cm) and shows normal parenchymal echogenicity. No evidence of focal lesion. No evidence of dilated IHBR or portal vein. CBD appears normal.

**GALL BLADDER** is distended. No e/o wall thickening or calculus within.

**VISUALIZED PART OF PANCREAS** appears normal. MPD is WNL

**SPLEEN** appears normal in size (12.1 cm) and shows normal parenchymal echogenicity. No evidence of focal lesion.

**BOTH KIDNEYS** appear normal in size (RK: 9.9 cm & LK: 11.7 cm) and position. Show normal cortical echogenicity. Corticomedullary differentiation is maintained. No calculus or hydronephrosis on either side.

**URINARY BLADDER** is full. No e/o wall thickening or calculus within.

**PROSTATE** appears normal in size. No evidence of focal lesion noted.

**BOWEL LOOPS** appear normal and show normal peristalsis  
No evidence of LYMPHADENOPATHY noted.  
No evidence of ASCITES or PLEURAL EFFUSION noted.

**IMPRESSION:**

- **NO SIGNIFICANT ABNORMALITY NOTED AT PRESENT SCAN.**

**DR SHARAD RUNGTA**  
**MD RADIOLOGY**

*Not all pathologies can be detected on radiograph. Further radiographic evaluation is suggested if required.*





<b>NAME: ANANT D RATHORE</b>	<b>AGE/SEX: 33 YRS/M</b>
<b>DATE: Saturday, April 22, 2023</b>	

**CHEST XRAY (PA)**

Both lung fields appear normal.  
Both hila appear normal  
Bilateral costo-phrenic angles appear grossly clear  
Mediastinum and cardiac shadow appear normal  
Bony thorax appears unremarkable  
No evidence of free gas under domes of diaphragm

**IMPRESSION:**

- **NO SIGNIFICANT ABNORMALITY NOTED IN LUNG FIELDS**
- **NORMAL CARDIAC SHADOW**

**DR SHARAD RUNGTA**  
**MD RADIOLOGY**

*Not all pathologies can be detected on radiograph. Further radiographic evaluation is suggested if required.*

