

  
 [Redacted]  
 [Redacted]


 சிவகாமி  
 Sivagami  
 பிறந்த நாள் / DOB : 02/07/1964  
 பெண் / FEMALE



**4049 4223 7929**


---

ஆதார் - சாதாரண மனிதனின் அதிகாரம்

*N. Silagu-*

1947  
 1800 300 1947  
 help@uidai.gov.in  
 www.uidai.gov.in  
 P.O. Box No.1947,  
 Bengaluru-560 001

---



முகவரி:  
 W/O: Natarajan, 4, AVAPPAN  
 NAGAR main STREET,  
 Ayappakkam, Tiruvallur, Tamil  
 Nadu, 600077

31 411  
 [Redacted]  
 [Redacted]





# MURUGAN HOSPITALS

HEALING HANDS



## LAB REPORT

Patient Name : Mrs. SIVAGAMI.N  
 Age / Gender : 58-Years / Female  
 UHID ID : MH20220035808  
 Doctor Name : Dr. ARUN PRAKASH

OP Report No. : INVA2104913  
 Bill No. : INV2108798  
 Sample Date : 26/03/2022 - 01:44 PM  
 Report Date : 26/03/2022 - 06:36 PM

Test Name	Result	Units	Reference Interval
<b>HAEMATOLOGY</b>			
<b>Complete Blood Cell Count(CBC)</b>			
HAEMOGLOBIN	12.2	gms/dl	male :13.0 - 17.0 female :12.0 - 15.0
PACKED CELL VOLUME	38.0	%	male : 40 - 50 female : 36 - 46
RBC COUNT	<u>4.25</u>	millions cells/cu.mm	female: 3.8 - 4.8 male : 4.5 - 5.5
TOTAL WBC	8,200	Cells/Cumm	4,000 - 11,000
<b>Differential Count</b>			
NEUTROPHILS	52	%	40 - 65
LYMPHOCYTES	42	%	30-50
EOSINOPHILS	06	%	01-06
MONOCYTES	<u>00</u>	%	1-10
BASOPHILS	00	%	0-2
ESR 60 MTS	10	mm	5 - 20
PLATELET COUNT	3.00	Lakhs/cumm	1.5 - 4.5
MCV	89.5	fL	76 - 96
MCH	28.7	pg	27 - 32
MCHC	32.1	gms/dl	30 - 36

INTERPRETATION: Test done on automated three part cell counter, all abnormal results are reviewed and confirmed microscopically.

BLOOD GROUPING & RH TYPING " O "POSITIVE

Healing Hearts and Lives

264/125, Kilpauk Garden Road, Kilpauk, Chennai - 600 010.  
 Phone : +91 44 4644 8989 / 75500 53335 | Email : muruganhosp@gmail.com  
 Website : www.muruganhospitals.in





# MURUGAN HOSPITALS

HEALING HANDS



## LAB REPORT

Patient Name : Mrs. SIVAGAMI.N  
Age / Gender : 58-Years / Female  
UHID ID : MH20220035808  
Doctor Name : Dr. ARUN PRAKASH

OP Report No. : INVA2104913  
Bill No. : INV2108798  
Sample Date : 26/03/2022 - 01:44 PM  
Report Date : 26/03/2022 - 06:36 PM

Test Name	Result	Units	Reference Interval
<b>BIO CHEMISTRY</b>			
BLOOD SUGAR FASTING	116	mg/dl	70-110
BLOOD SUGAR POST PRANDIAL	<u>258</u>	mg/dl	80- 160
SERUM URIC ACID	4.2	mg/dl	male 3.1-7.0 , female 2.5-5.6
SERUM CREATININE	0.7	mg/dl	0.7-1.4
<b>LIPID PROFILE</b>			
TOTALCHOLESTEROL	161	mg/dl	< 200
TRIGLYCERIDE	116	mg/dl	< 150
HDL	49	mg/dl	35 - 80
VLDL	23	mg/dl	2 to 30
LDL	89	mg/dl	<130
CHOLESTEROL/ HDL RATIO	3.2	mg/dl	

**Healing Hearts and Lives**

264/125, Kilpauk Garden Road, Kilpauk, Chennai - 600 010.  
Phone : +91 44 4644 8989 / 75500 53335 | Email : muruganhosp@gmail.com  
Website : www.muruganhospitals.in





# MURUGAN HOSPITALS

HEALING HANDS



## LAB REPORT

Patient Name : Mrs. SIVAGAMI.N  
Age / Gender : 58-Years / Female  
UHID ID : MH20220035808  
Doctor Name : Dr. ARUN PRAKASH

OP Report No. : INVA2104913  
Bill No. : INV2108798  
Sample Date : 26/03/2022 - 01:44 PM  
Report Date : 26/03/2022 - 06:36 PM

Test Name	Result	Units	Reference Interval
<b>LIVER FUNCTION TEST</b>			
BILLIRUBIN(TOTAL)	0.7	mg/dl	0.0 -1.0
BILLIRUBIN(DIRECT)	0.2	mg/dl	0.1- 0.30
BILLIRUBIN(INDIRECT)	0.5	mg/dl	0.2-0.8
SGOT	19	IU/L	0-38
SGPT	24	IU/L	0.0-40
ALKALINE PHOSPHATASE	112	IU/L	40-140 4-6Years 93-309 13-15Years 74-390
TOTAL PROTEIN	7.7	gm/dl	6.6-8.7
ALBUMIN	4.5	gm/dl	3.5 - 5.5
GLOBULIN	3.2	gm/dl	2.0-3.5
AG RATIO	1.4		
GAMMA G T	14	U/L	male<49 female<32
BLOOD UREA NITROGEN	13.5	mg/dl	7-21
HBA1C	6.8	%	normal: <6.0 good control: 6.1-7.0 fair control: 7.1- 8.0 poor control:8.1 -10.0 unsatisfactory: >10.0





# MURUGAN HOSPITALS

HEALING HANDS



## LAB REPORT

Patient Name : Mrs. SIVAGAMLIN  
Age / Gender : 58-Years / Female  
UHID ID : MH20220035808  
Doctor Name : Dr. ARUN PRAKASH

OP Report No. : INVA2104913  
Bill No. : INV2108798  
Sample Date : 26/03/2022 - 01:44 PM  
Report Date : 26/03/2022 - 06:36 PM

Test Name	Result	Units	Reference Interval
<b><u>CLINICAL PATHOLOGY</u></b>			
URINE SUGAR (PP)	+		
<b>URINE ROUTINE</b>			
COLOUR	YELLOW		
APPEARANCE	CLEAR		
REACTION	ACIDIC		
SUGAR	NIL		
ALBUMIN	NIL		
<b>DEPOSITES</b>			
PUS CELLS	2 - 3	/ HPF	
EPI CELLS	5 - 6	/ HPF	
RBC COUNT	NIL	/ HPF	
CAST	NIL		
CRYSTALS	NIL		
OTHERS	NIL		

NITHYALAB

Verified by

\*\*\* End of Report \*\*\*



**Healing Hearts and Lives**

264/125, Kilpauk Garden Road, Kilpauk, Chennai - 600 010.  
Phone : +91 44 4644 8989 / 75500 53335 | Email : muruganhosp@gmail.com  
Website : www.muruganhospitals.in





# MURUGAN HOSPITALS

HEALING HANDS



## LAB REPORT

Patient Name : Mrs. SIVAGAMLIN  
Age / Gender : 58-Years / Female  
UHID ID : MH20220035808  
Doctor Name : Dr. ARUN PRAKASH

OP Report No. : INVA2104913  
Bill No. : INV2108798  
Sample Date : 26/03/2022 - 01:44 PM  
Report Date : 26/03/2022 - 07:03 PM

Test Name	Result	Units	Reference Interval
<b>ENDOCRINOLOGY</b>			
T3	0.816	ng/ml	0.52-1.85
T4	7.337	ug/dl	5.0 -13.0 ug/dl
TSH	2.737	uIU/ml	0.39 - 5.18 uIU/ml

NITHYALAB  
Verified by

\*\*\* End of Report \*\*\*

Authorized Signature

Healing Hearts and Lives

264/125, Kilpauk Garden Road, Kilpauk, Chennai - 600 010.  
Phone : +91 44 4644 8989 / 75500 53335 | Email : muruganhosp@gmail.com  
Website : www.muruganhospitals.in





# MURUGAN HOSPITALS

HEALING HANDS



## SCAN REPORT

NAME : MRS.SIVAGAMI  
AGE / SEX : 57Y/FEMALE  
CONSULTANT: DR. ARUN PRAKASH

UHID NO : MH20220035808  
IP / OP NO: OUTPATIENT  
DATE : 26.03.2022

### ULTRA SOUND SCAN OF ABDOMEN

**LIVER:** Normal in size and measures- 13.0 cm and normal in echotexture. No focal lesions are seen. No dilatation of intra-hepatic biliary radicals present. Hepatic veins and IVC appear normal. Portal vein is normal in caliber. Common bile duct is normal in caliber.

**GALL BLADDER:** Contracted.

**PANCREAS:** Normal in size and echotexture. No focal lesions are seen. No evidence of calculi or calcifications. No evidence of pancreatic duct dilation.

**PARA AORTIC AREAS:** Aorta and IVC appear normal. No evidence of para aortic lymphadenopathy.

**SPLEEN:** Normal in size and measures 7.3 cm. Normal in echotexture. No evidence of focal lesions.

**RIGHT KIDNEY:** Measures 8.9 x 4.0 cm and is normal in size and echotexture. Cortico medullary differentiation is well maintained. There is no calculus or hydronephrosis or mass.

**LEFT KIDNEY:** Measures 8.6 x 4.2 cm and is normal in size and echotexture. Cortico medullary differentiation is well maintained. There is no hydronephrosis or mass.  
**Microlith noted in interpolar region.**

**Healing Hearts and Lives**

264/125, Kilpauk Garden Road, Kilpauk, Chennai - 600 010. Phone : +91 44 4644 8989 / 75500 53335  
Email : muruganhosp@gmail.com | Website : www.muruganhospitals.in



**URINARY BLADDER:** Normal in size, contour and wall thickness. There is no evidence of calculus or mass. No vesical diverticulum present.

**UTERUS:** Measures 5.2 x 2.9 cm normal size and echo texture. ET-thin.

**Bilateral ovaries atrophic.**

No ascites present. No retroperitoneal lymphadenopathy present.

**IMPRESSION:**

- ❖ *Left renal microlith.*
- ❖ *No other significant abnormality.*

  
**Dr. SAKTHI SDRD.**  
**Consultant Radiologist.**





# MURUGAN HOSPITALS

HEALING HANDS



## ECHO CARDIOGRAM REPORT

NAME : MRS. SIVAGAMI.N

UHIDNO:MH20220035808

AGE&SEX : 57Y /FEMALE

IP/OP : OUTPATIENT

CONSULTANT: DR. ARUN PRAKASH

DATE : 26-03-2022

### 2D PLAX (mm)

RV - 23 mm  
AO - 27 mm  
LA - 21 mm

### COLOR DOPPLER

Normal

### M-Mode (mm)

IVS - 13 mm  
PW - 11 mm  
LVD - 39 mm  
LVS - 27 mm  
EF - 65 %  
FS - 35 %

### DOPPLER (m/sec)

MITRAL E - 0.5 m/s  
MITRAL A - 0.5 m/s  
PULMONARY - 0.8 m/s  
AORTIC - 1.0 m/s  
TRICUSPID - 0.3 m/s

### IMPRESSION:

**Mild concentric LVH**

No RWMA

Normal LV Systolic function

Grade I left ventricular diastolic dysfunction

Normal RV function

No pulmonary hypertension

No pericardial effusion

No clot/ Vegetation.



Dr. SIDHARTHAN, MD.,DM.,  
Consultant Cardiologist

Healing Hearts and Lives

264/125, Kilpauk Garden Road, Kilpauk, Chennai - 600 010.

Phone : +91 44 4644 8989 / 75500 53335 | Email : muruganhosp@gmail.com

Website : www.muruganhospitals.in



ID : 2203260004  
Name: MRS SIVAGAMI  
Sex : Female  
Divisions:

DateTime: 2022-03-26 08:48  
Age : 57  
BP : 140/80 mmHg  
Bed No. :

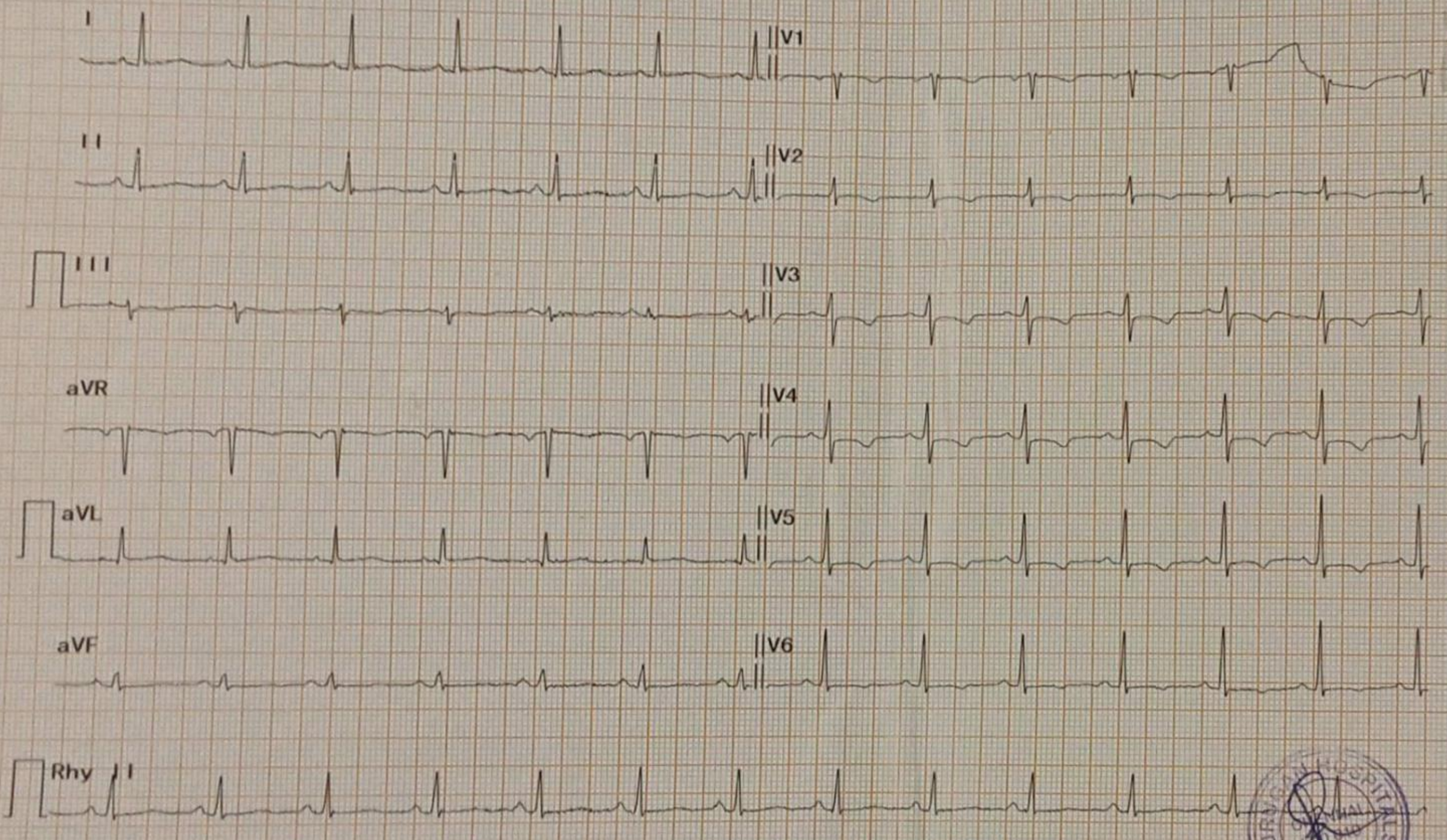
Hospital: MURUGAN HOSPITALS  
Height : 146 cm  
Weight : 48 kg  
Hospital No. :

HR 82 bpm  
P Dur/PR int 91 / 148ms  
QRS Dur 84 ms  
QT/QTc int 379 / 446 ms  
P/QRS/T axis 51 / 21 / 19 °

RV5/SV1 amp 1.031 / 0.462mV  
RV5+SV1 amp 1.493mV  
RV6/SV2 amp 1.057 / 0.187mV

Minnesota Code  
5-2-2 (V3, V4)  
5-2-1 (V5)

Diagnosis Info  
800: Sinus Rhythm  
621: Negative T (V5)

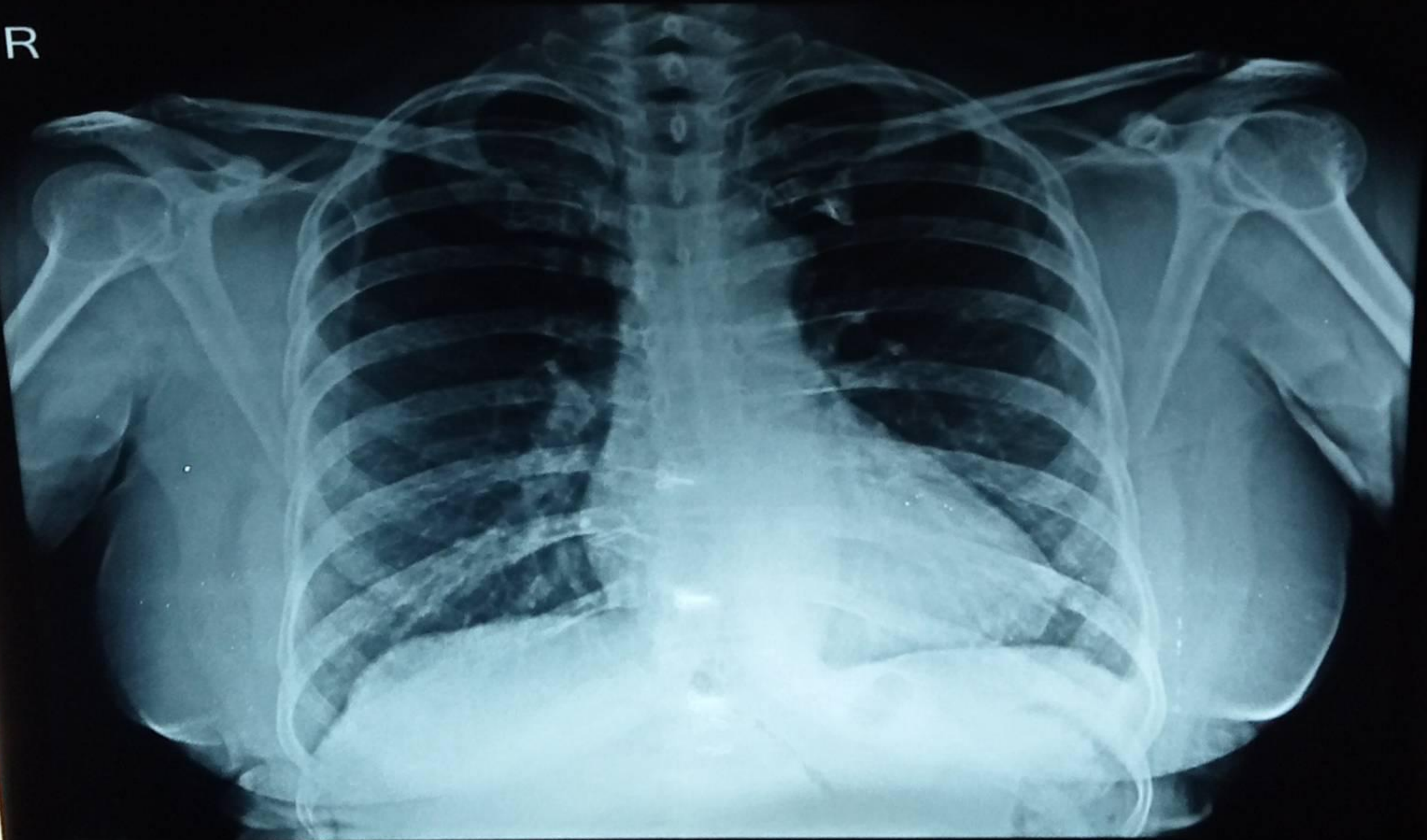


Diagnosis for reference, ask your doctor to confirm  
AUTO PRINT 6X2+1R 82bpm 10 mm/mV 0.50Hz-45Hz AC 60Hz 25 mm/sec Confirmed By:





R



MRS.SIVAGAMI.N 57YRS 35808 CHEST-PA 26-03-2022

MURUGAN HOSPITALS, KILPAUK, CHENNAI-10. PH. NO. 7550053335 / 46448989







# MURUGAN HOSPITALS

HEALING HANDS



## SCAN REPORT

NAME : Mrs.N.SIVAGAMI

AGE / SEX: 57 YEARS / FEMALE

9+7 CONSULTANT: DR. ARUN PRAKASH

UHID NO : MH20220035808

DATE : 26-03-2022

OP/IP : OUT PATIENT

### CHEST XRAY PA VIEW

- Trachea is in midline.
- Hila appear Normal.
- Mediastinal shadow appears normal.
- Costophrenic&Cardiophrenic angles appear free.
- Cardiothoracic ratio is within normal limits.
- Lungs fields appear clear
- Bony thorax and soft tissue appear normal

### IMPRESSION:

- No significant abnormality noted.



CONSULTANT RADIOLOGIST

Healing Hearts and Lives

264/125, Kilpauk Garden Road, Kilpauk, Chennai - 600 010. Phone : +91 44 4644 8989 / 75500 53335

Email : muruganhosp@gmail.com | Website : www.muruganhospitals.in