



# YASHFEEN CARDIAC HOSPITAL™

At. & Po. Viraval, Navsari. 396 445. Phone (H) (02637) 235725

Website : www.yashfeenhospital.in E-mail : info@yashfeenhospital.in

(For Laboratory Reports Only)



Patient Name : DARSHANA KETANBHAI PATEL      Age : 48 Years      Sex : F  
 Ref By Dr. : -      Area : Navsari      Date : 08/04/2023  
 Sample Time : 08/04/2023 09:08      No : 13      Time : 1:32PM

## HAEMOGRAM

Test	Findings	UOM	Normal Range
HAEMOGLOBIN	12.5	gm/dl	M-13.5-17.0 F-11.5-15.5
<b>HAEMOGRAM</b>			
RED BLOOD CELL	5.65	10 <sup>6</sup> /μL	3.76 - 5.70
TOTAL LEUCOCYTE COUNT	<b>12000</b>	cells/cumm	4,000-11,000
<b>Differential Count</b>			
Neutrophil	60	%	40-75
Lymphocytes	31	%	20-40
Eosinophil	5	%	1-6
Monocytes	4	%	2-10
Basophils	0	%	0-0
PLATELET COUNT	367000	lacs/cumm	1.5-5.5 Lacs
<b>RBC INDICES</b>			
P.C.V.	37.9	%	M-40-56% F-37-47%
M.C.V.	<b>67.1</b>	cu/microns	76-94
M.C.H.	<b>22.2</b>	pg	27-30
M.C.H.C.	33.1	-	30-35
BLOOD GROUP	" AB "	-	-
RH FACTOR	POSITIVE	-	-
E.S.R.(1 hour)	14	mm/hr.	M-5-10, F-5-20



Dr. PIYUSH B. CHAUDHARI

M.D. Medicine

Reg. No. G-21518

Signature

### Remarks

Designed By : Sarita Infotech Pvt. Ltd., Navsari

Yashfeen Cardiac Hospital

Thanks for Reference

Technician



# YASHFEEN CARDIAC HOSPITAL™

At. & Po. Viraval, Navsari. 396 445. Phone (H) (02637) 235725

Website : www.yashfeenhospital.in E-mail : info@yashfeenhospital.in

(For Laboratory Reports Only)



Patient Name : DARSHANA KETANBHAI PATEL

Ref By Dr. : -

Sample Time : 08/04/2023 09:09 No : 13

Age : 48 Years Sex : F

Area : Navsari Date : 08/04/2023

Time : 1:32PM

## HAEMOGLOBIN A1 C ESTIMATION

Test	Findings	UOM	Normal Range
Hb A1C	6.3	%	>8 :Action Suggested, 7-8 :Good Control, <7 :Goal, 6-7 :Near Normal Glycemia, <6 :Non-diabetic Level
<b>Technique</b> METHOD - HPLC			
Mean Blood Glucose	133.5	mg/dL	



Dr. PIYUSH B. CHAUDHARI  
M.D. Medicine  
Reg. No. G-21518

### Remarks

Designed By : Sarita Infotech Pvt. Ltd., Navsari

Yashfeen Cardiac Hospital

  
Signature

*Thanks for Reference*

Technician



# YASHFEEN CARDIAC HOSPITAL™

At. & Po. Viraval, Navsari. 396 445. Phone (H) (02637) 235725

Website : [www.yashfeenhospital.in](http://www.yashfeenhospital.in) E-mail : [info@yashfeenhospital.in](mailto:info@yashfeenhospital.in)  
(For Laboratory Reports Only)



Patient Name : DARSHANA KETANBHAI PATEL

Ref By Dr. : -

Sample Time : 08/04/2023 09:09 No : 13

Age : 48 Years Sex : F

Area : Navsari Date : 08/04/2023

Time : 1:32PM

## BIOCHEMICAL TEST REPORT

Test	Findings	UOM	Normal Range
S.CREATININE	<u>0.6</u>	mg/dL	M .0.9-1.4 , F. 0.8-1.2
S.URIC ACID	<u>7.1</u>	mg/dL	Male:3.5-7.2, Female:2.6-6.0
BLOOD UREA NITROGEN	7.5	mg/dL	4.7-23.0



Dr. PIYUSH B. CHAUDHARI  
M.D. Medicine  
Reg. No. G-21518

### Remarks

Designed By : Sarita Infotech Pvt. Ltd., Navsari

Yashfeen Cardiac Hospital

  
signature

*Thanks for Reference*

Technician



# YASHFEEN CARDIAC HOSPITAL™

At. & Po. Viraval, Navsari. 396 445. Phone (H) (02637) 235725

Website : www.yashfeenhospital.in E-mail : info@yashfeenhospital.in

(For Laboratory Reports Only)



Patient Name : DARSHANA KETANBHAI PATEL

Age : 48 Years Sex : F

Ref By Dr. : -

Area : Navsari Date : 08/04/2023

Sample Time : 08/04/2023 09:09 No : 13

Time : 1:32PM

## LIPID PROFILE TEST REPORT

Test	Findings	UOM	Normal Range
S.CHOLESTEROL	179.2	mg/dL	<200:Desirable, 200-239:Borderline High, >=240:High
HDL CHOLESTEROL	53.6	mg/dL	<40:Low(High Risk), >=60:High(Low Risk)
LDL CHOLESTEROL	<b>142.6</b>	mg/dL	<100: Optimal, 100-129: Nearoptimal/ Aboveoptimal, 130-159:BorderlineHigh,16 0-189:High,>=190:Very
VLDL CHOLESTEROL	22.8	mg/dL	UPTO 40
S.TRIGLYCERIDES	114.2	mg/dL	<150:Normal, 150-199:Borderline High,200-499:High, >=500:Very Hi
CHOL/ HDL RATIO	3.3	mg/dL	LESS THAN 5
LDL/ HDL RATIO	2.7	mg/dL	LESS THAN 5
REMARK	-	-	-



Dr. PIYUSH B. CHAUDHARI

M. D. Medicine

Reg. No. G-21518

### Remarks

Designed By : Sarita Infotech Pvt. Ltd., Navsari

Yashfeen Cardiac Hospital

Signature

Thanks for Reference

Technician



# YASHFEEN CARDIAC HOSPITAL™

At. & Po. Viraval, Navsari. 396 445. Phone (H) (02637) 235725

Website : [www.yashfeenhospital.in](http://www.yashfeenhospital.in) E-mail : [info@yashfeenhospital.in](mailto:info@yashfeenhospital.in)

(For Laboratory Reports Only)



Patient Name : DARSHANA KETANBHAI PATEL

Ref By Dr. : -

Sample Time : 08/04/2023 09:09 No : 13

Age : 48 Years Sex : F

Area : Navsari Date : 08/04/2023

Time : 1:32PM

## LIVER FUNCTION TEST REPORT

Test	Findings	UOM	Normal Range
TOTAL BILIRUBIN	0.3	mg/dL	0-1.0
DIRECT BILIRUBIN	0.2	mg/dL	0-0.8
INDIRECT BILIRUBIN	0.1	mg/dL	0-0.2
SGPT	13.0	U/L	Below 40.0
S.ALKALINE PHOSPHATASE	79.8	U/L	CH . 170.0-515.0 A. 37.0-147.0
TOTAL PROTEIN	7.2	g/dl	6.0-8.0
ALBUMIN	4.6	g/dl	3.0-5.0
GLOBULIN	2.6	g/dl	3.0-3.5
A/G	1.8	g/dl	
SGOT	11.5	U/L	Below 40.0



Dr. PIYUSH B. CHAUDHARI

M.D. Medicine

Reg. No. G-21518

### Remarks

Designed By : Sarita Infotech Pvt. Ltd., Navsari

Yashfeen Cardiac Hospital

  
Signature

*Thanks for Reference*

Technician



# YASHFEEN CARDIAC HOSPITAL™

At. & Po. Viraval, Navsari. 396 445. Phone (H) (02637) 235725

Website : www.yashfeenhospital.in E-mail : info@yashfeenhospital.in  
(For Laboratory Reports Only)



Patient Name : DARSHANA KETANBHAI PATEL

Ref By Dr. : -

Sample Time : 08/04/2023 09:09 No : 13

Age : 48 Years Sex : F

Area : Navsari Date : 08/04/2023

Time : 1:32PM

## THYROID FUNCTION TEST REPORT

Test	Findings	UOM	Normal Range
T3 (TRIODOTHYRONINE)	1.37	ng/ml	NEWBORNS:0.73-2.88 6DAYS-3MONTHS:0.80-2.75 4-12MONTHS:0.86-2.65 1-6YEARS:0.92-2.48 7-11YEARS:0.93-2.31 12-20YEARS:0.91-2.18 ADULT:0.80-2.00
T4 (THYROXINE)	10.15	µg/dl	NEWBORNS:5.04-18.5, 6DAYS-3MONTHS:5.41-17.0, 4-12 MONTHS:5.67-16.0, 1-6YEARS:5.95-14.7, 7-11 YEARS:5.99-13.8, 12-20 YEARS:5.91-13.2, ADULTS:5.10-14.1
TSH	2.80	µIU/ml	NEWBORNS:0.70-15.2, 6DAYS-3MONTHS:0.72-11.0, 4-12MONTHS:0.73-8.35, 1-6YEARS:0.70-5.97, 7-11YEARS:0.60-4.84, 12-20YEARS:0.51-4.30 ADULTS:0.27-4.20

### TECHNIQUE

ELECTROCHEMILUMINESCENCE



Dr. PIYUSH B. CHAUDHARI  
M.D. Medicine  
Reg. No. G-21518

### Remarks

Designed By : Sarita Infotech Pvt. Ltd., Navsari

Yashfeen Cardiac Hospital

signature

Thanks for Reference

Technician



# YASHFEEN CARDIAC HOSPITAL™

At. & Po. Viraval, Navsari. 396 445. Phone (H) (02637) 235725

Website : www.yashfeenhospital.in E-mail : info@yashfeenhospital.in

(For Laboratory Reports Only)



Patient Name : DARSHANA KETANBHAI PATEL

Age : 48 Years Sex : F

Ref By Dr. : -

Area : Navsari Date : 08/04/2023

Sample Time : 08/04/2023 09:09 No : 13

Time : 1:32PM

## ROUTINE URINE ANALYSIS

Test	Findings	UOM	Normal Range
<b>PHYSICAL EXAMINATION</b>			
Quantity	-	-	
Colour	YELLOW	-	
Appearance	CLEAR	-	
Reaction	ACIDIC	-	
Sp. Gravity	1.011	-	
<b>CHEMICAL EXAMINATION</b>			
U.Albumin	NIL	-	
Sugar	NIL	-	
Acetone	NIL	-	
Bile Salt	NIL	-	
Bile Pigment	NIL	-	
Occult Blood	NIL	-	
<b>MICROSCOPIC EXAMINATION</b>			
Pus Cells	1-2	/hpf	
Epithelial cells	1-2	/hpf	
Red cells	ABSENT	/hpf	
Casts	-	/hpf	
Crystals	-	/hpf	
Others	<b>BACTERIA {FEW} SEEN</b>	/hpf	



Dr. PIYUSH B. CHAUDHARI  
M.D. Medicine  
Reg. No. G-21518

### Remarks

Designed By : Sarita Infotech Pvt. Ltd., Navsari

Yashfeen Cardiac Hospital

  
Signature

Thanks for Reference

Technician



# YASHFEEN CARDIAC HOSPITAL™

At. & Po. Viraval, Navsari. 396 445. Phone (H) (02637) 235725

Website : www.yashfeenhospital.in E-mail : info@yashfeenhospital.in  
(For Laboratory Reports Only)



Patient Name : DARSHANA KETANBHAI PATEL Age : 48 Years Sex : F  
Ref By Dr. : - Area : Navsari Date : 08/04/2023  
Sample Time : 08/04/2023 09:09 No : 13 Time : 1:32PM

## GGT TEST REPORT

Test	Findings	UOM	Normal Range
SERUM GGT	22	U/L	10-71 U/L



Dr. PIYUSH B. CHAUDHARI  
M.D. Medicine  
Reg. No. G-21518

### Remarks

Designed By : Sarita Infotech Pvt. Ltd., Navsari

Yashfeen Cardiac Hospital

  
Signature

*Thanks for Reference*

Technician





# YASHFEEN CARDIAC HOSPITAL™

At. & Po. Viraval, Navsari. 396 445. Phone (H) (02637) 235725

Website : www.yashfeenhospital.in E-mail : info@yashfeenhospital.in

(For Laboratory Reports Only)



Patient Name : DARSHANA KETANBHAI PATEL

Age : 48 Years Sex : F

Ref By Dr. : -

Area : Navsari Date : 08/04/2023

Sample Time : 08/04/2023 09:09 No : 13

Time : 1:32PM

## BLOOD SUGAR TEST REPORT

Test	Findings	UOM	Normal Range
FASTING BLOOD SUGAR	<u>113.0</u>	mg/dL	70-110
FASTING URINE SUGAR	NIL	-	NIL
POSTPANDRIAL BLOOD SUGAR	<u>158.0</u>	mg/dL	70-140
POSTPANDRIAL URINE SUGAR	NIL	-	NIL



Dr. PIYUSH B. CHAUDHARI

M.D. Medicine

Reg. No. G-21518

### Remarks

Designed By : Sarita Infotech Pvt. Ltd., Navsari

Yashfeen Cardiac Hospital

  
signature

*Thanks for Reference*

Technician



# YASHFEEN CARDIAC HOSPITAL™

MANAGED BY :- YASHFEEN FOUNDATION

VIRAVAL, NAVSARI. 396 445. PHONE : (H) (02637) 235725

Website : www.yashfeenhospital.in E-mail : info@yashfeenhospital.in

(Regd. No. E / 1390 / Navsari)

(Stationary For Report Only)

## 2D ECHO CARDIOGRAPHY COLOUR DOPPLER REPORT

Patient Name & No	: DARSHANA KETANBHAI PATEL CH23000931	Age/Sex	UHID :	: 125
Doctor	: Mohil Nagad	48/ F	No :	: 121
Referred By	:		Date :	: 08/04/2023

### M-Mode findings

LVIDd : 40mm  
 LVIDs : 28mm  
 IVSd : 11mm  
 PWd : 11mm  
 EF : 60%  
 Aorta : 22mm  
 LA : 32mm

### 2D Imaging

Aortic Valve : Trileaflet, Normal  
 Mitral Valve : Thin, Pliable, Normal Mobility, Trivial MR.  
 Tricuspid Valve : Trivial TR, RVSP: 20+ RAP  
 Pulmonary Valve : Normal

=> : All cardiac chambers are normal sized.  
 => : All cardiac valves are normal.  
 => : No regional wall motion abnormality.  
 => : Normal LV systolic function.  
 => : Grade I LV diastolic dysfunction.  
 => : IAS/IVS intact.  
 => : No obvious clots/ vegetations/ or effusion.  
 => : IVC Normal size.

### Doppler Findings

=> : No MS/Trivial MR, No TS/Trivial TR, No AS/AR & No PS/PR  
 Mitral inflow Pattern : E > A  
 Tissue Doppler Findings : E' > A'

Impression : Normal LVEF:60%, No RWMA, Grade I LV diastolic dysfunction.



Report Prepared By

*Mohil Nagad*  
**DR. MOHIL NAGAD**  
 M.D. Medicine, D.M. Cardiology  
 Senior Consultant- Interventional Cardiology  
 Reg. No. G- 22893  
 Parish Dhada  
 YASHFEEN HOSPITAL, NAVSARI  
 MBBS, FACC

Non-Invasive Cardiologist

Designed By : Sarita Infotech Pvt. Ltd., Navsari

DARSHANA ,  
ID:  
DOB:  
48 Years , ,  
Female ,Unknown  
Med.:  
Location:  
Referring Physician:  
Notes:

08-04-2023 09:49:35

Vent. Rate: 95 BPM  
PR int: 158 ms  
QRS dur: 78 ms  
QT/QTc: 282/334 ms  
P-R-T axes: 59 29 57  
Avg. RR: 630 ms  
QTcB: 355 ms  
QTcF: 328 ms

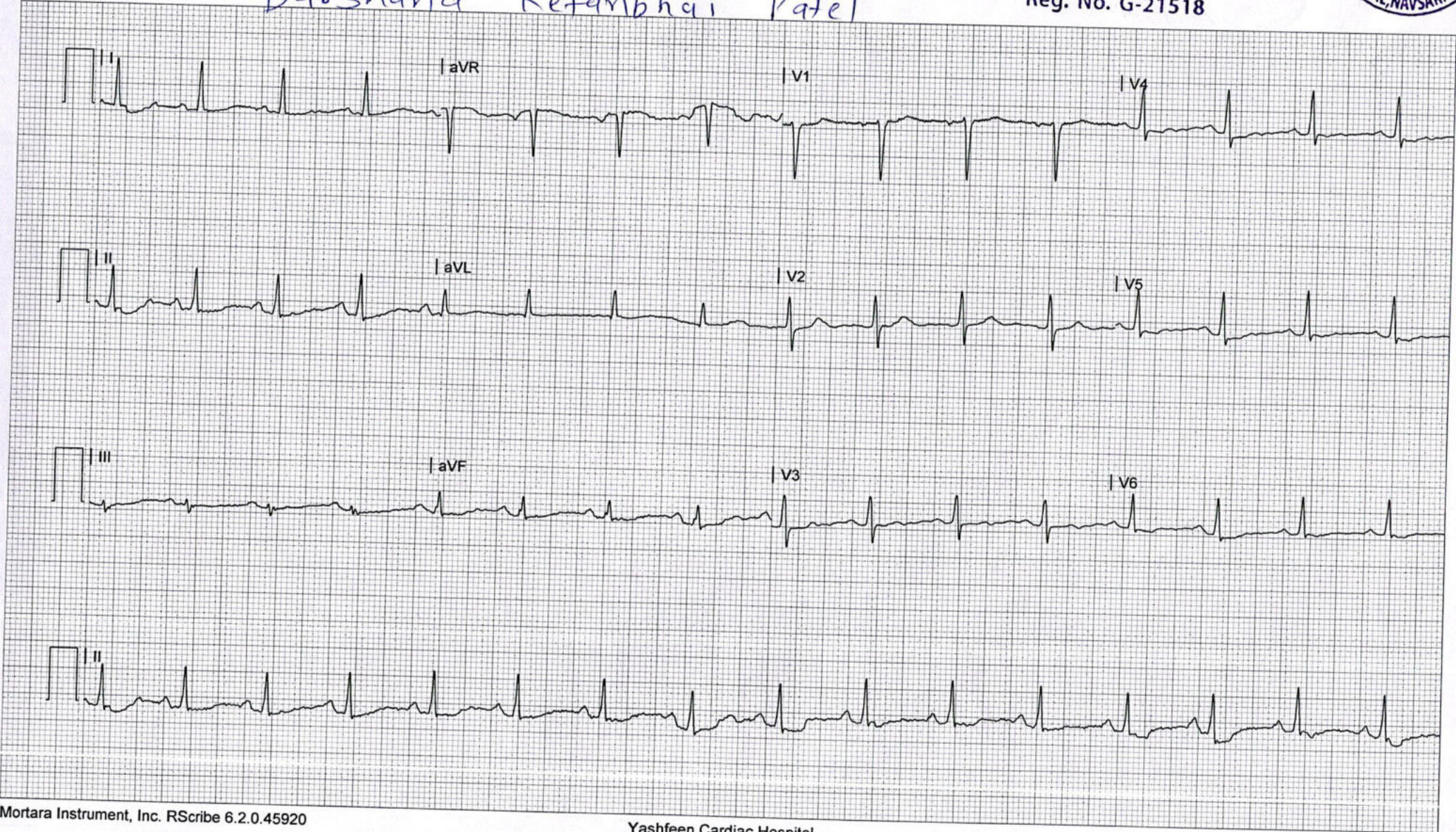
SINUS RHYTHM  
NONSPECIFIC ST & T-WAVE ABNORMALITY  
BORDERLINE ECG

UNCONFIRMED REPORT  
Reviewed by:

*P. Chaudhari* Signed by:  
**Dr. PIYUSH B. CHAUDHARI** Date:  
M.D. Medicine  
Reg. No. G-21518



*Darshana Ketanbhai Patel*



# YASHFEEN IMAGING & RADIOLOGY DEPARTMENT

MANAGED BY :- YASHFEEN FOUNDATION

VIRAVAL, NAVSARI. 396 445. PHONE : (H) (02637) 235725

Website : [www.yashfeenhospital.in](http://www.yashfeenhospital.in) E-mail : [info@yashfeenhospital.in](mailto:info@yashfeenhospital.in)

Name	DARSHANA KETAN PATEL	Age	48Y/F
Ref by Dr	SELF	Date	08/04/2023

## USG ABDOMEN & PELVIS (SCREENING)(TVS)

**Liver** appears normal in size & shape with normal echopattern.  
No e/o focal or diffuse lesion. IHBR appear normal.  
PV and CBD appear normal.

**Gall bladder** appears distended & normal in shape & size. No e/o calculus or mass seen.  
Walls appear normal.

**Pancreas** appears normal in size and echogenicity. No e/o focal or diffuse lesion.

**Spleen** appears normal in size and shows normal echopattern. No e/o focal lesion.

**Both Kidneys** appear normal in size and echopattern. CM Differentiation is preserved.  
No e/o calculus or hydronephrosis on either side.  
Perirenal spaces appear normal on either side.  
Suprarenal regions appear normal on either side. No e/o mass lesion.

**Bladder** is empty (due to non-compliance of patient). Adv: Follow up USG with normally distended bladder.

**Uterus is** not seen post hysterectomy status.  
Left adnexa shows 6 x 5 cm in size anechoic cystic lesion with internal echoes suggest left ovarian complex cyst.

RIF region appears normal.

No e/o ascites.

### IMPRESSION:

Left ovarian complex cyst.



**Dr. DHARMESH DESAI**

(M.D. Radiology)

Reg. No. G - 45284

YASHFEEN GROUP OF HOSPITAL  
MID

Please contact immediately for any typographical error.

This is only professional opinion, not a final diagnosis. Kindly correlate clinically. Not valid for medicolegal purpose.

# YASHFEEN IMAGING & RADIOLOGY DEPARTMENT

MANAGED BY :- YASHFEEN FOUNDATION

VIRAVAL, NAVSARI. 396 445. PHONE : (H) (02637) 235725

Website : [www.yashfeenhospital.in](http://www.yashfeenhospital.in) E-mail : [info@yashfeenhospital.in](mailto:info@yashfeenhospital.in)

Name	DARSHANA KETAN PATEL	Age	48Y/F
Ref by Dr	SELF	Date	08/04/2023

## USG BOTH BREASTS (SCREENING)

Breast parenchyma appears normal.  
No e/o focal solid or cystic lesion.  
No e/o mass or abscess.  
No e/o calcification.  
Skin and subcutaneous tissue appears normal  
Pectoral muscles appear normal  
Axillary region appears normal.

### IMPRESSION:

No significant abnormality detected.



Dr. DHARMESH DESAI

Dr. Dharmesh Desai  
(M.D. Radiology)

Reg. No. 015284

YASHFEEN GROUP OF HOSPITAL

Please contact immediately for any typographical error.  
This is only professional opinion, not a final diagnosis. Kindly correlate clinically. Not valid for medicolegal purpose.



# YASHFEEN CARDIAC HOSPITAL

## EYE DEPARTMENT

Chief Complaint :

*Refractive Check*

Medical History : DM / HT / ~~Asthama~~ / ~~Allergy~~ / ~~Heart~~ / ~~Thyroid~~ / .....

Ocular History :

Visual Acuity :

*6/15 < 6/18*

IOP :

	RIGHT EYE (PH.....)				LEFT EY	
	Sph.	Cyl.	Axis	V/A	Sph.	
Distance						
Near						

POTEC PLM-8000 PD  
08/04/2023 12:37:55  
NO: 01131  
NAME:

Cyl From: +/- ABBE: 42[d]


<R> SPH CYL AX  
+0.75 +1.00 166  
ADD 1.50

<L> SPH CYL AX  
+0.75 +1.25 161  
ADD 0.75

YASHFEEN CARDIAC HOSPITAL  
NAVSARI.

Distance/Reading/Bi-Focal/Progressive

Sle :



*Adv*  
*Reg. Fee*  
*Atten Symp*



# YASHFEEN IMAGING & RADIOLOGY DEPARTMENT

MANAGED BY :- YASHFEEN FOUNDATION

VIRAVAL, NAVSARI. 396 445. PHONE : (H) (02637) 235725

Website : [www.yashfeenhospital.in](http://www.yashfeenhospital.in) E-mail : [info@yashfeenhospital.in](mailto:info@yashfeenhospital.in)

Patient's Name:	DARSHANA K. PATEL	Age & Sex:	48Yrs/F
Ref. by Dr.	SELF	Date:	08-04-2023

## X RAY CHEST (PA VIEW)

Both lung fields appear normal.

Both hila appear normal.

Both CP angles appear clear.

Cardiac size appears within normal limit.

Both domes of diaphragm appear normal.

Bony thoracic cage appears normal.

### IMPRESSION:

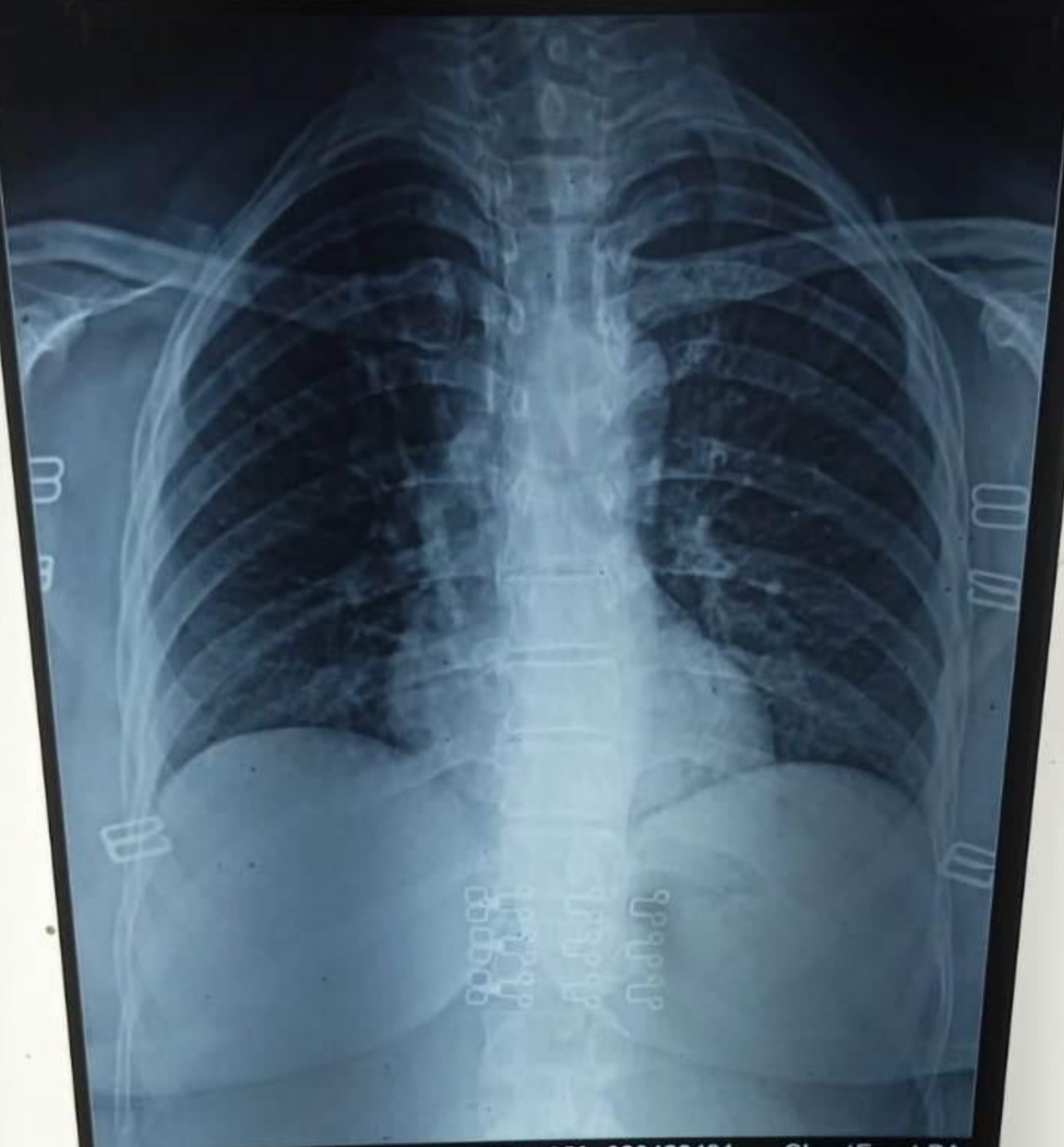- Normal X-ray chest (PA view).



**Dr. DHARMESH DESAI**  
Dr. Dharmesh Desai  
(M.D. Radiology)  
Reg. No. **MD** 45284  
YASHFEEN GROUP OF HOSPITAL

Please contact immediately for any typographical error.

This is only professional opinion, not a final diagnosis. Kindly correlate clinically. Not valid for medicolegal purpose.



CH23000931 DARSHANA K PATEL 48/Y 080423481 ChestErect PA  
YASHFEEN GROUP OF HOSPITALS NAVSARI PH:9924047789