



PARKLINE DIAGNOSTICS PVT. LTD.

L.G. 3, 4 & 5, Bhuvana Towers, S.D. Road, Secunderabad - 500 003.

Tel : +91 40-2784 5852, 6649 1787, 7995421787, 7093445852, Fax : +91 40 2784 7864

Email parklinediagnostics@gmail.com www.parklinediagnostics.com



NABL Accredited
Certificate No.MC-256

MEDICAL EXAMINATION REPORT

Name	Ms. K. Radhika		Date :	11/3/22	
Company	C/o- Medi wheel		Reg. No. :	1865427	
Contact No.	9000279554		Sex	<input type="checkbox"/> F	Age : <input type="checkbox"/> 40
Type	Pre-Emp		Emp. No.:	Spouse	
	Overseas		Height	163 cms.	
	Annual	✓	Weight	62 kg	
Remarks					
	<p>- Routine cholestroemia ⊕. Advice follow up.</p> <p>- U/E - Proteinuria ⊕. Advice follow up.</p> <p>- Rest all clinical & Lab parameters within (N) limits.</p>				
	<p>DR. PRIYANKA SANNIDHI MBBS Regn No: 11351</p>				
Fitness Status	Medically Fit / Unfit		Physician's Signature		


COMPREHENSIVE MEDICAL EXAMINATION REPORT

NAME Ms. K. RADHIKA

AGE 40 yrs Female

MARITAL STATUS married CHILDREN: M F

IDENTIFICATION (IF ANY) A mole on the (R) side of Neck region



PAST HISTORY

Any family H/o : High Blood Pressure, Heart Disease, Tuberculosis, Diabetes, Asthma, Cancer

Father Father 2 cases

Any personal H/o Major illness like : Typhoid..... 2003 Jaundice..... NIL Etc.

Any H/o STD..... Skin infection..... NIL

H/o Blood Transfusion..... NIL Recent Vaccination..... COVID 2 doses ✓

H/o Epilepsy..... Giddiness..... NIL

H/o Surgery..... 1 LSES Fracture in the past..... NIL

Any Personal H/O.

High Blood Pressure, Heart Disease Tuberculosis, Diabetes, Asthma, Cancer

x 6 months

Drug Abuse, Drug Allergy, Micturition, Bowels, Alcohol, Smoking, Sleep, MC, Wt. Loss/Wt. Gain

Present illness / Medication T. AMLODIPIN 5mg.

GENERAL EXAMINATION

Conjunctiva :
Skin :
Ears :
Nose :
Throat & Oral Cavity :

NAD

Bone, Joints : (N)
Nutritional Status : well Nourished.
Lymph Nodes : NPD
Edema Feet : NIL
Varicose Veins : NIL

Distant Vision : Near Vision :

Right Eye: 6/6

With ~~glasses~~ / Without glasses

left Eye : 6/6

with ~~glasses~~ / without glasses

Colour Vision : BE normal

Right Eye: N6

With ~~glasses~~ / Without glasses

left Eye : N6

with ~~glasses~~ / without glasses

DR. KATTA
MBBS, D.O., FRF
(AMC)
Ophthalmologist's Signature

Right Ear

Hearing : (N)

Rinee's Test ;

Weber Test :

Discharge : NIL

Left Ear

(N)

NIL

SYSTEMIC EXAMINATION

Pulse : 80 bpm

B.P. : 130/90 mmHg.

Lungs : A. Shape of Chest 3/4 symmetrical
B. Breath Sounds 3/4 clear ⊕
C. Adventitious Sounds No

Heart : A. Sounds S1 S2 ⊕
B. Murmurs No murmur

Nervous System

Abdomen : A. Liver NPD
B. Spleen NPD
C. Piles NIL
D. Any Lump NIL

A. Higher Function :
B. Cranial Nerves :
C. Sensory System : (N)
D. Motor System :
E. Jerks :


General : A. Hernia
B. Hydrocele
C. Varicocele
NAD

Breast : Rt _____ Lt. _____

CANDIDATE'S DECLARATION

I hereby solemnly declare that I am not suffering from Asthma, Hypertension, Diabetes, Occult Psychological disorders or any other ailment which can be suppressed without my voluntary declaration.

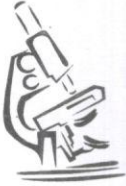Date :



Signature

Place :

Note : General Physical Examination and Investigation included in the health check-up Have certain limitations and may not be able to detect all latent and asymptomatic diseases. Any new symptoms developing after the health check-up or persisting thereafter should be brought to the attention of the treating physician.



PARKLINE DIAGNOSTICS PVT. LTD.

L.G. 3, 4 & 5, Bhuvana Towers, S.D. Road, Secunderabad - 500 003. Tel : +91 40-2784 5852, 6649 1787, 7995421787,
7093445852, Fax : +91 40 2784 7864 Email parklinediagnostics@gmail.com www.parklinediagnostics.com



NABL Accredited
Certificate No.MC-2566

ENT CONSULTATION

S.No. 1865427

Emp.No. Spouse

Date 11/3/22

Name Ms. K. Radhika

Age 40 Yrs

Sex M/F

EARS :

Right

Left

EAC

: patent, no Cerumen.

-db-

TM

: Intact, pearly white.
Cone of light (+)

-db-

TFT

: Rinne's +ve

Rinne's +ve -

weber's - central

NOSE

: Septum: (n). Bil. Turbinate (n). Pns: (n). no tenderness

THROAT

: Oropharynx: (n). Bil. v.c.s (n) moving &

NECK

: (n) Asymmetric bil.

IMPRESSION:

EAD clinically NAD.


Dr. D. Hari Krishna Reddy
MS (ENT)
Head & Neck Surgeon
Reg. No: 88379

Name : K. Radhika Sex : F Age : 40

Date : 11/3/22

OPD No : 496

Rx
Filling w.r.t 7⁶ ← / 6
Scaling.


MULTI SPECIALITY DENTAL CLINIC
Smile Confidently... Not Confidentially...
B.D.S, IMPLANTOLOGIST (USA)
Pajamudaliar Street, Kalasiguda,
Secunderabad, Cell : 8977910590.



PARKLINE DIAGNOSTICS PVT. LTD.

L.G. 3, 4 & 5, Bhuvana Towers, Sarojini Devi Road, Secunderabad - 500 003 Tel. +91 40-2784 5852
6649 1787 Fax : +91 40 2784 7864 Email : parklinediagnostics@gmail.com www.parklinediagnostics.com



NABL Accredited
Certificate No. MC-2566

TEST REPORT

Name : Ms . K.RADHIKA [SPOUSE]
Age / Gender : 40 Years / Female
Ref.By : Medi Wheel
Req. No : BIL1865427

TID : UMR0738133
Registered on : 11-Mar-2022 08:05 AM
Reported On : 11-Mar-2022 11:11 AM

DEPARTMENT OF ULTRASOUND Ultrasound Whole Abdomen

LIVER is normal shape, size (14.2 cms) and has uniform echopattern.
No evidence of focal lesion or intrahepatic biliary ductal dilatation.
Hepatic and portal vein radicals are normal.

GALL BLADDER Contracted.
CBD is of normal calibre.

PANCREAS has normal shape, size and uniform echopattern.
No evidence of ductal dilatation or calcification.

SPLEEN shows normal shape, size (10.4 cms) and echopattern.

KIDNEYS move well with respiration and have normal shape, size and echopattern.
Cortico- medullary differentiations are well made out.
No evidence of calculus or hydronephrosis.
Right kidney measures: 10.3 x 4.0 cms, Left kidney measures: 11.2 x 3.9 cms.

URINARY BLADDER shows normal shape and wall thickness.
It has clear contents. No evidence of diverticula.

UTERUS is anteverted has normal shape and size.
It has uniform myometrial echopattern.
Endometrial echo is of normal thickness 3 mm.
Uterus measures 8.0 x 3.1 x 3.4 cms.

OVARIES are normal in size, shape and echotexture.
Right ovary: 4.2 x 2.5 cms,
Dominant follicle noted in right ovary, measuring 19 x 17 mm
Left ovary: 2.4 x 1.4 cms.

No evidence of free fluid in the abdomen and pelvis.

IMPRESSION: NORMAL STUDY.

Suggested clinical correlation and follow up

FL

Dr.Karuna Belide
Consultant Radiologist

The Test marked with*are not accredited by NABL

Lab Timings (Weekdays) : 7.00 am to 8.30 pm

Sundays & Holidays : 7.00 am to 1.00 pm

Radiologists Timings (Weekdays) : 7.30 am to 1.30 pm

Sundays & Holidays : 7.30 am to 9.30 am



PARKLINE DIAGNOSTICS PVT. LTD.

L.G. 3, 4 & 5, Bhuvana Towers, Sarojini Devi Road, Secunderabad - 500 003 Tel. +91 40-2784 5852
6649 1787 Fax :+91 40 2784 7864 Email : parklinediagnostics@gmail.com www.parklinediagnostics.com



NABL Accredited
Certificate No. MC-2566

TEST REPORT

Name : Ms . K.RADHIKA [SPOUSE]

TID : UMR0738133

Age / Gender : 40 Years / Female

Registered on : 11-Mar-2022 08:05 AM

Ref.By : Medi Wheel

Reported On : 11-Mar-2022 10:39 AM

Req. No : BIL1865427

X-RAY CHEST PA VIEW

Lung fields are clear.

Cardia is normal.

Hila are normal.

C P angles are free.

Bony cage is normal.

Soft tissues are normal.

IMPRESSION : NORMAL CHEST X-RAY

12
Dr. D.J. MOHAN
MD DMRD
(Reg No. 8995)
Consultant Radiologist

The Test marked with*are not accredited by NABL

Lab Timings (Weekdays) : 7.00 am to 8.30 pm

Radiologists Timings (Weekdays) : 7.30 am to 1.30 pm

Sundays & Holidays : 7.00 am to 1.00 pm

Sundays & Holidays

Page:1 of 1
& 5.30 pm to 7.45 pm

: 7.30 am to 9.30 am

M.S.K.RADHIKA
Female 40Years

HR : 72 bpm
P : 96 ms
PR : 140 ms
QRS : 85 ms
QT/QTc : 370/406 ms
P/QRS/T : 33/44/11
RV5/SV1 : 1.216/0.000 mV

USP
WNC
L2

Dr. NAVEEN KUMAR .C
M.D., D.M.
Consultant Cardiologist
Reg. No. 52291

Diagnosis Information
Sinus Rhythm
Normal ECG

Report Confirmed by:

PATIENT SUMMARY REPORT

REI

REF. BY : MEDIWHEEL
DONE BY : DR NAVEEN KUMAR C
TECHNICIAN : G.M.SURESH

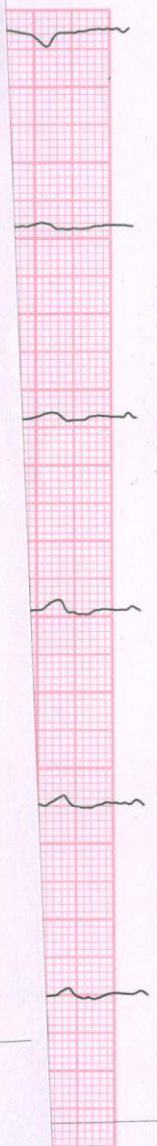
2022, 08:41:


LINE DIAGNOSTICS PVT.LTD
: 1865427
: **MS K RADHIKA**
SEX : 40 / FEMALE

HEIGHT (cm) : 163
WEIGHT (kg) : 62
PROTOCOL : BRUCE

HISTORY :
LOCATION :
OBJECT OF TEST : Routine Check Up.
FACTORS : Hypertension.
ACTIVITY : Very Active.
OTHER INVESTIGATION : ECG
REASON FOR TERMINATION : THR ACHIEVED
EXERCISE TOLERANCE : Good (> 10 METS).
EXERCISE INDUCED ARRHYTHMIAS : No.
SYMPTOM RESPONSE : Normal.
CHRONO RESPONSE : Normal.
GENERAL IMPRESSION :
ADDITIONAL COMMENTS :

negative for inducible ischemia



Confirmed By: 
Dr. NAVEEN KUMAR C
Signature M.D., D.M.
Consultant Cardiologist
Reg. No. 52291 Page No.: 1

BPL DYNATRAC