



Bangalore Diagnostics & Multi-Speciality Centre

Quality Assurance : EQAP from AIIMS & CMC- Vellore

Quality. Trust. Since 1982.

198, 12th Main, 3rd Block, (Above Namma MTR, Next to SBI), Rajajinagar, Bangalore- 560 010.
Ph. : 080-23505407, 9448079978 e-mail : bangalore.d.s@gmail.com

Name : MRS. AARTHI

Reg. No : C6763

Age/Sex: 41 Year(s) / Female

Date : 12/03/2022

Ref. by : DR. BANK OF BARODA

Corporate: NON CORPORATE

Test Name

Result

Reference Range

Page 1 of 3

HAEMATOLOGY REPORT

COMPLETE BLOOD COUNT

Haemoglobin	12.8 gms %	Male : 13.0 - 18.0 gms % Female: 11.0 - 15.0 gms %
Red Blood Cell Count	4.05 million/cumm	Male : 4.5-6.5 millions/cumm Female : 3.7-5.5 million/cumr

Packed Cell Volume	38.5 %	Females: 32 - 45 % Males: 39 - 54%
Total Count	7,200 cells /cumm	4000-11000 cells /cumm

Differential Count

Neutrophils	56.0 %	40 - 75%
Lymphocytes	34.6 %	20 - 45%
Monocytes	6.8 %	01 - 10%
Eosinophils	2.0 %	01 - 06 %
Basophils	0.5 %	00 to 01 %

COMPLETE BLOOD COUNT

Platelet count	2,15,000 cells/cumm	150000-400000 cells/cumm
Mean Corpuscular Volume	95 fL	78 - 98 fL
Mean Corpuscular Haemoglobin	31.6 pg	27 - 32 pg
Mean Corpuscular Haemoglobin Concentration	33.2 g/dl	31 - 36 g/dl
ESR	04 mm/hour	Male: 0 - 10 mm/ hour Female: 0 - 20 mm/hour

ABSOLUTE EOSINOPHIL COUNT	143 cells/cumm	40 - 440 cells/cumm
---------------------------	----------------	---------------------

BLOOD GROUP(ABO)	"A"
Rh Type (D)	POSITIVE

BIOCHEMISTRY REPORT

FASTING BLOOD SUGAR	89 mg/dl	70 to 100 mg/dl
FASTING URINE SUGAR	NIL	NIL



Bangalore Diagnostics & Multi-Speciality Centre

Quality Assurance : EQAP from AIIMS & CMC- Vellore

Quality. Trust. Since 1982.

198, 12th Main, 3rd Block, (Above Namma MTR, Next to SBI), Rajajinagar, Bangalore- 560 010.

Ph. : 080-23505407, 9448079978 e-mail : bangalore.d.s@gmail.com

Name : MRS. AARTHI

Reg. No : C6763

Age/Sex: 41 Year(s) / Female

Date : 12/03/2022

Ref. by : DR. BANK OF BARODA

Corporate: NON CORPORATE

Test Name

Result

Reference Range

Page 2 of 3

BIOCHEMISTRY REPORT

POST PRANDIAL BLOOD SUGAR 96 mg/dl 80 to 140 mg/dl

POST PRANDIAL URINE SUGAR NIL NIL

Glycosylated Haemoglobin (HbA1c)

Glycosylated Haemoglobin (HbA1c) 5.5 %
Normal <6.0 %
Good control 6.0-7.0 %
Fair control 7.0-8.0 %
Unsatisfactory 8.0-10.0 %
Poor control >10 %

LIPID PROFILE

TOTAL CHOLESTEROL 174.8 mg/dl up to 200 mg/dl
TRIGLYCERIDES 86.8 mg/dl <150 : Normal
HDL Cholesterol 43.4 mg/dl Male: >40 mg/dl
Female: > 50 mg/dl
LDL Cholesterol 114.1 mg/dl <100 mg/dl
VLDL Cholesterol 17.3 mg/dl <40 mg/dl
CHOLESTEROL/HDL RATIO 4.0:1.0 up to 6.0 %

LIVER FUNCTION TESTS

Total Bilirubin 0.52 mg/dl up to 1.2 mg/dl
Direct Bilirubin 0.16 mg/dl 0 to 0.3 mg/dl
Indirect Bilirubin 0.36 mg/dl up to 1.5 mg/dl
S.G.O.T. (AST) 21.6 U/L 0 - 46 U/L
S.G.P.T. (ALT) 23.2 U/L 0 - 49 U/L
ALKALINE PHOSPHATASE 63.9 U/L
Men : 80-306
Women : 64-306
Children upto 15 Yrs : upto 644
Children upto 17 yrs : upto 483

Gamma Glutamyl Transpeptidase (GGT) 13.4 IU/L 0 - 55 IU/L
Total Protein 6.8 gms/dl 6.6 - 8.3 gms/dl
Albumin 3.5 gms/dl 3.4 - 5.0 gms/dl
Globulin 3.3 gms/dl 2.3 - 3.5 gms/dl
A/G Ratio 1.1:1.0 1.2 : 1.0



Bangalore Diagnostics & Multi-Speciality Centre

Quality Assurance : EQAP from AIIMS & CMC- Vellore

Quality. Trust. Since 1982.

198, 12th Main, 3rd Block, (Above Namma MTR, Next to SBI), Rajajinagar, Bangalore- 560 010.
Ph. : 080-23505407, 9448079978 e-mail : bangalore.d.s@gmail.com

Name : MRS. AARTHI

Reg. No : C6763

Age/Sex: 41 Year(s) / Female

Date : 12/03/2022

Ref. by : DR. BANK OF BARODA

Corporate: NON CORPORATE

Test Name

Result

Reference Range

Page 3 of 3

BIOCHEMISTRY REPORT

SERUM CREATININE	0.76 mg/dl	Females 0.6 – 1.2 mg/dl Males 0.7 – 1.4 mg/dl
BLOOD UREA NITROGEN (BUN)	10.2 mg/dl	7-18 mg/dl
URIC ACID	5.52 mg/dl	M: 3.5 -7.2 mg/dl F: 2.6 - 6.0 mg/dl

URINE EXAMINATION REPORT

PHYSICAL EXAMINATION

COLOUR	LIGHT YELLOW
APPEARANCE	CLEAR
REACTION	ACIDIC

BIOCHEMICAL EXAMINATION

PROTEIN	NIL	
GLUCOSE	NIL	
BILE SALT	NIL	
BILE PIGMENT	NIL	
SPECIFIC GRAVITY	1.018	1.003 – 1.035

MICROSCOPIC EXAMINATION

PUS CELLS	1-2/HPF
EP CELLS	1-2/HPF
MACROPHAGES	NIL
R.B.C.s	ABSENT
CASTS	NIL
CRYSTALS	NIL

----- End of Report -----

Biochemist

Microbiologist

Pathologist

Dr. Mahadevan



Bangalore Diagnostics & Multi-Speciality Centre

Quality Assurance : EQAP from AIIMS & CMC- Vellore

Quality. Trust. Since 1982.

198, 12th Main, 3rd Block, (Above Namma MTR, Next to SBI), Rajajinagar, Bangalore- 560 010.
Ph. : 080-23505407, 9448079978 e-mail : bangalore.d.s@gmail.com

Name : Mrs. AARTHI 763

Visit No. : V101416323

Age/Gender : 41 Y/Female

Referred by : BANGALORE DIAGNOSTICS & MULTI SPECIALITY CENTER

Patient No. : P101296275

Registered On : 12/03/2022 15:18

Collected On : 12/03/2022 17:02

Reported On : 12/03/2022 18:18

Final Report

Test Name / Method	Results	Units	Reference Range	Sample Type
CLINICAL BIOCHEMISTRY				
THYROID PROFILE				
TRIODO THYRONINE-T3 TOTAL <i>Method : ECLIA</i>	1.02	ng/ml	0.80 - 2.0	SERUM
THYROXINE -T4 TOTAL <i>Method : ECLIA</i>	6.76	ug/dl	5.1 - 14.1	
THYROID STIMULATING HORMONE - TSH (Ultra Sensitive) <i>Method : ECLIA</i>	1.33	mIU/ml	0.40 - 4.20 First Trimester:0.1-2.5* Second & Third Trimester:0.2-3.0* *American Thyroid Association trimesterspecific	

*** End Of Report ***

Outside sample to be correlated with other clinical finding.

PROCESSED BY : NAYANA

RESULT VERIFIED BY : BHARATH KUMAR C, Lab Incharge

Prof. KSHAMA HIREMATH

M.Sc, Med. Biochemistry, CFN, DNHE

Chief Biochemist



Bangalore Diagnostics & Multi-Speciality Centre

Quality Assurance : EQAP from AIIMS & CMC- Vellore

Quality, Trust. Since 1982.

198, 12th Main, 3rd Block, (Above Namma MTR, Next to SBI), Rajajinagar, Bangalore- 560 010.
Ph. : 080-23505407, 9448079978 e-mail : bangalore.d.s@gmail.com

NAME : MRS. AARTHI

DATE: 14/03/2022

REF BY : B.O.B

AGE/ GENDER : 41 YEARS/FEMALE

ABDOMEN AND PELVIC ULTRA SOUND SCAN REPORT

Liver : Normal in size, shape and echotexture. No focal lesion seen.

No intrahepatic biliary dilatation seen. PV & CBD is normal

Gall Bladder: GB is normal. Normal in wall thickness. No abnormal intraluminal echoes.

Pancreas : Normal in size and echo texture. No focal lesion, Pancreatic duct appears normal.

Spleen : Normal in size, shape and echo texture

Kidneys : Both kidney's are normal in size, shape and position.

No calculi / hydronephrosis seen. Corticomedullary differentiation is good.

Right Kidney : 111 x 17 mm

Left kidney : 115 x 16mm

Urinary Bladder: Normal in contour and wall thickness with clear contents.

Uterus : Anteverted, Measures 93 x 40 x 45 mm, **Bulky in size** and normal in shape and echotexture. **Endometrium is thickened measures 10mm.** POD is empty.

Ovaries : Both ovaries are visualized in adnexa, appears normal.

IMPRESSION:

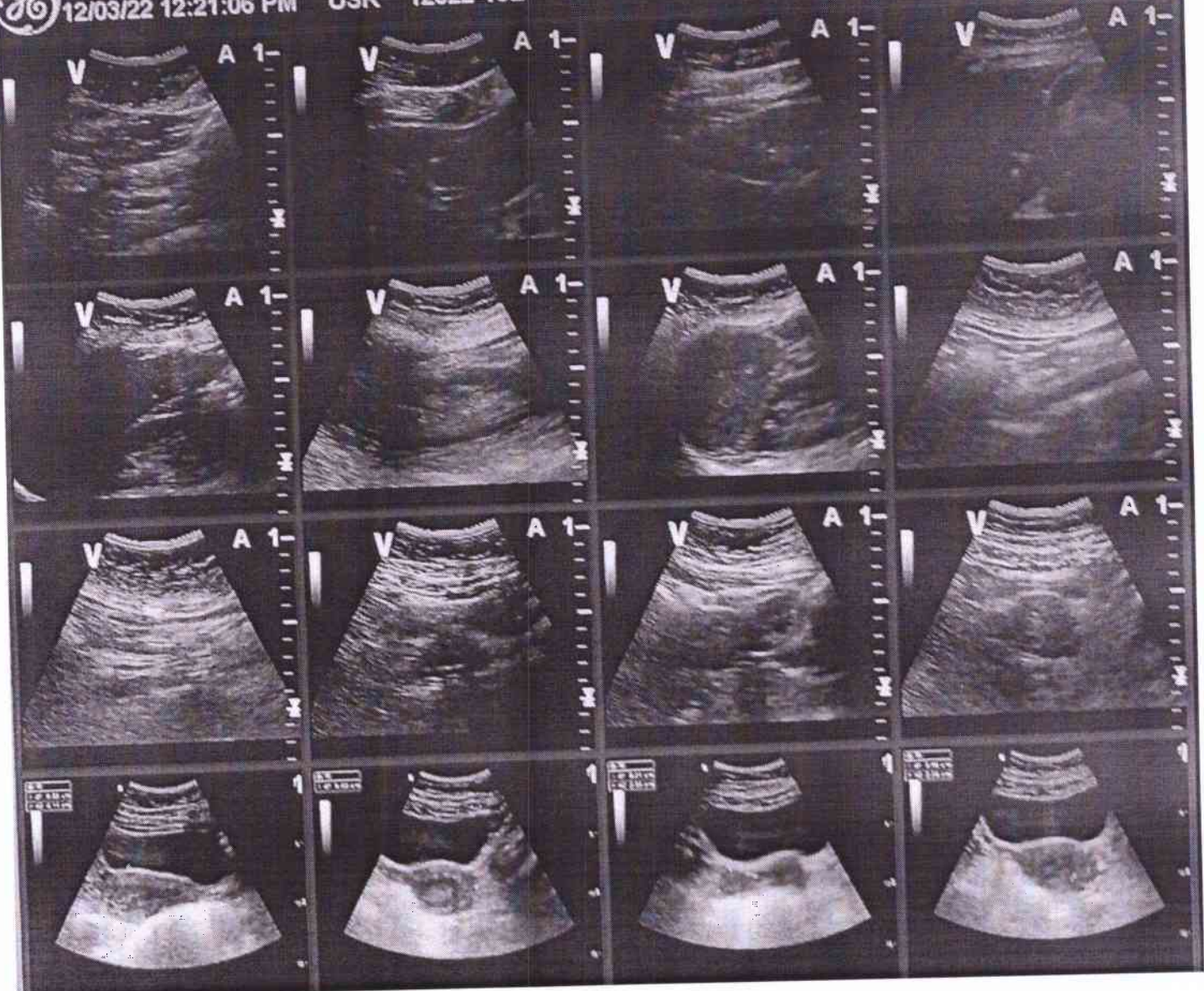- **Bulky uterus.**
- **Thickened endometrium.**


SONOLOGIST



GE Healthcare
12/03/22 12:21:06 PM

ARTHI 41,
USR 12322-13B





Bangalore Diagnostics & Multi-Speciality Centre

Quality Assurance : EQAP from AIIMS & CMC- Vellore

Quality. Trust. Since 1982.

198, 12th Main, 3rd Block, (Above Namma MTR, Next to SBI), Rajajinagar, Bangalore- 560 010.

Ph. : 080-23505407, 9448079978, e-mail : bangalore.d.s@gmail.com

Echocardiography Report

NAME : MRS. AARTHI

DATE: 12.03.2022

AGE/SEX: 41 YEARS/FEMALE

REF BY : B.O.B.

LA : 33 mm	MV : E 0.70 A : 0.76 m/sec
AO : 25 mm	AV : 1.00 m/sec
RVID : 18 mm	TV : 0.43 m/sec
LVIDD : 43mm	PV : 0.66 m/sec
LVIDS : 29 mm	
IVSD : 10 mm	MR : NIL
IVSS : 15mm	AR : NIL
LVPWD: 10mm	TR : NIL
LVPWS : 16 mm	PR : NIL
FS : 32 %	
EF : 61%	
LV mass: 154 gm	

IMPRESSION

- NORMAL CHAMBER DIMENSIONS.
- NO RWMA.
- NORMAL LV SYSTOLIC FUNCTION. LVEF 61%
- LV DIASTOLIC DYSFUNCTION GRADE I.
- NORMAL VALVES.
- NORMAL COLOR FLOW AND SPECTRAL DOPPLER STUDY.
- NO THROMBUS / PE

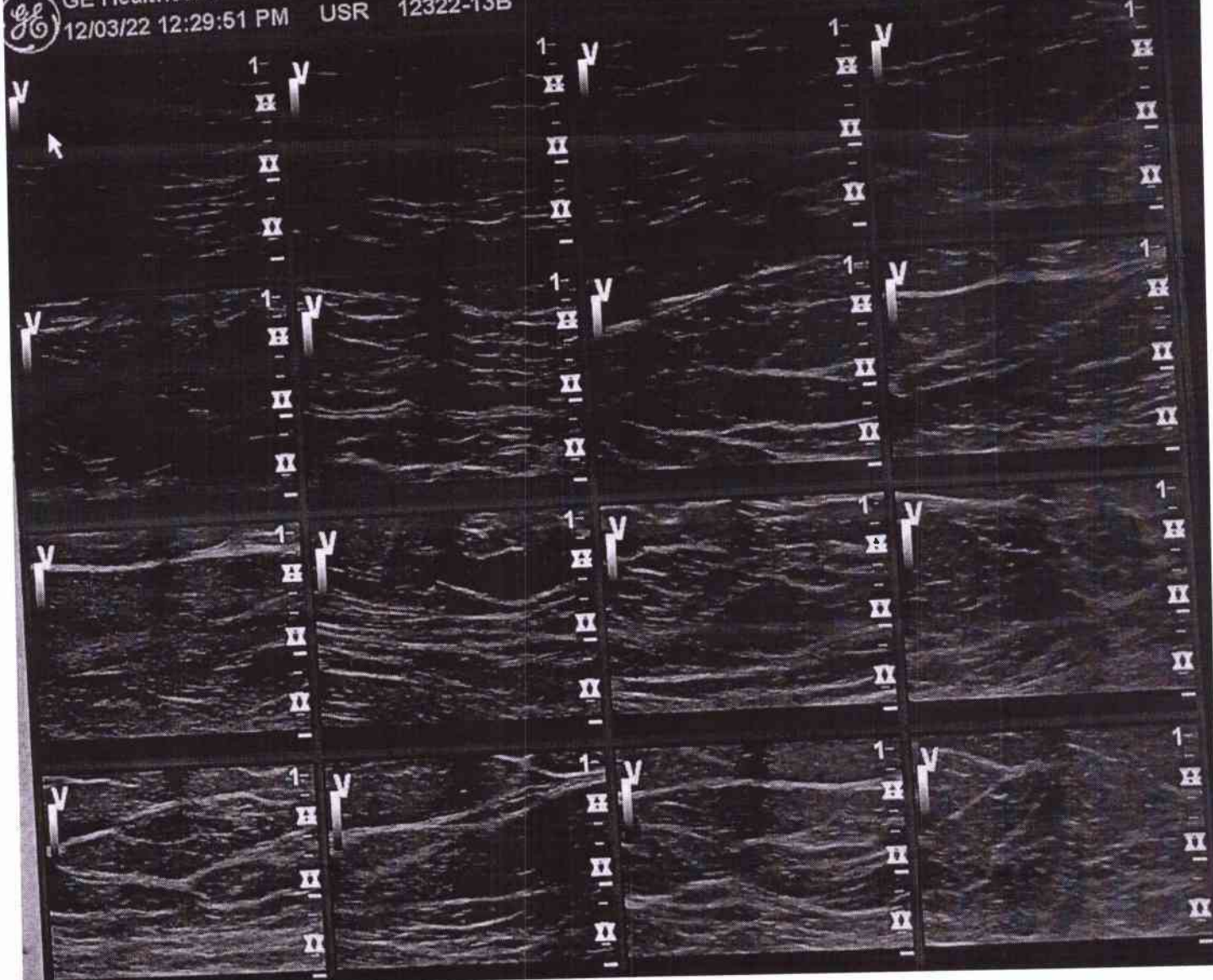
CONSULTANT CARDIOLOGIST


BANGALORE DIAGNOSTICS CENTRE
198, 12th Main, 3rd Block
Rajajinagar, Bangalore-560 010



GE Healthcare
12/03/22 12:29:51 PM

ARTHI 41,
USR 12322-13B





Bangalore Diagnostics & Multi-Speciality Centre

Quality Assurance : EQAP from AIIMS & CMC- Vellore

Quality. Trust. Since 1982.

198, 12th Main, 3rd Block, (Above Namma MTR, Next to SBI), Rajajinagar, Bangalore- 560 010.
Ph. : 080-23505407, 9448079978 e-mail : bangalore.d.s@gmail.com

NAME : MRS. AARTHI

DATE: 12.03.2022

AGE/SEX: 41 YEARS/FEMALE

REF BY : B.O.B.

BREAST ULTRA SOUND SCAN REPORT

Both breast glandular soft tissue echo texture appeared within normal limits.

Left breast glandular soft tissue echotexture appeared within normal limits.

There is no evidence of Solid/ Cystic foci's in all IV Quadrant's

No ductal dilatations seen.

Axillary regions appeared normal; no evidence of enlarged lymphnodes.

IMPRESSION:

NORMAL SONOLOGIC STUDY.

BIRADS SCORE - I (Suggest routine screening)

SONOLOGIST.

BANGALORE DIAGNOSTICS CENTRE
198, 12th Main, 3rd Block
Rajajinagar, Bangalore-560 010



GE Healthcare

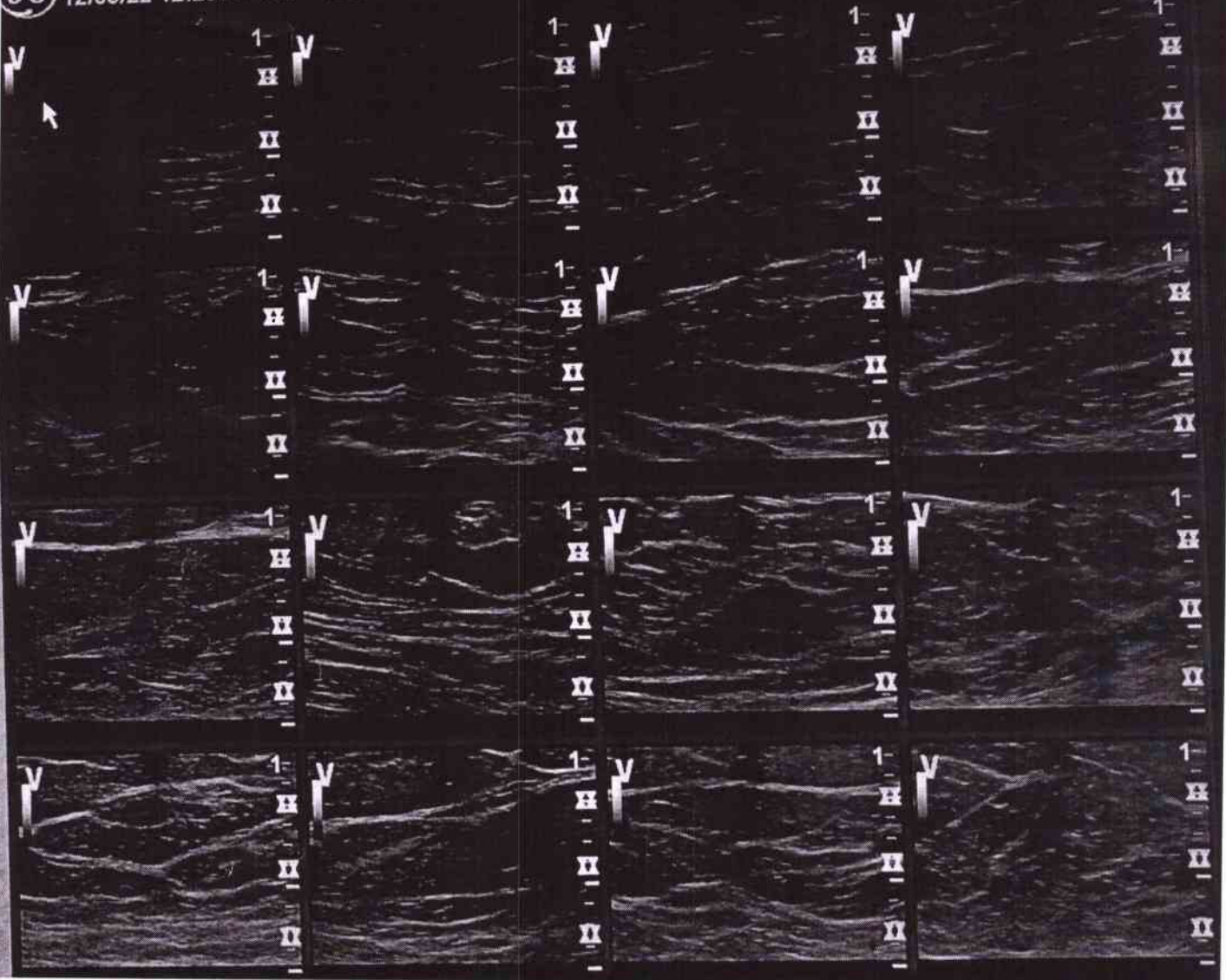
12/03/22 12:29:51 PM

USR

ARTHI 41,

12322-13B

---:---:---





Bangalore Diagnostics & Multi-Speciality Centre

Quality Assurance : EQAP from AIIMS & CMC- Vellore

Quality. Trust. Since 1982.

198, 12th Main, 3rd Block, (Above Namma MTR, Next to SBI), Rajajinagar, Bangalore- 560 010.


Ph. : 080-23505407, 9448079978 e-mail : bangalore.d.s@gmail.com

REG.NO:: C-6763	DATE:: 15/03/2022
NAME:: Mrs.AARTHI	AGE& SEX : 41 YRS; FEMALE
REF.BY DR:: BANK OF BARODA	

CYTOLOGY REPORT

NATURE OF SPECIMEN :: Cervico- vaginal smear	
SPECIMEN ADEQUACY :: Satisfactory for evaluation	
GENERAL CATEGORISATION :: Inflammatory	
MICROSCOPY :: Smears show high cellular yield of epithelial cells. The background showed neutrophilic infiltration. The epithelial cells are superficial and intermediate cells with predominance of the former and both are exhibiting isodiametric nucleus. Good number of endocervical cells seen. There is no evidence of metaplastic/dysplastic cells/Trichomoniasis/ Candidiasis/Cellular changes suggesting viral infection.	
EPITHELIAL CELL ABNORMALITIES :: None evident	
HORMONAL EVALUATION :: Not done	
IMPRESSION :: INFLAMMATORY SMEAR. NEGATIVE FOR INTRAEPITHELIAL LESION.	

**BANGALORE DIAGNOSTICS &
MULTI-SPECIALITY CENTRE**
198, 12th Main, 3rd Block
Rajajinagar, Bangalore-560 010


Dr. MAHADEVA. K.C.
M.D., (Path)
KMC. No.: 17647



Bangalore Diagnostics & Multi-Speciality Centre

Quality Assurance : EQAP from AIIMS & CMC- Vellore

Quality. Trust. Since 1982.

198, 12th Main, 3rd Block, (Above Namma MTR, Next to SBI), Rajajinagar, Bangalore- 560 010.
Ph. : 080-23505407, 9448079978 e-mail : bangalore.d.s@gmail.com

Patient Name	MRS.AARTHI	Patient Id	X-RAY-35
Age/DOB	41/	Gender	F
Ref.Doctor	BANK OF BARODA	Date	12/03/2022

X-RAY CHEST PA VIEW

OBSERVATION:

Both hila are normal.

Cardiophrenic and costophrenic angles are normal.

The trachea is central.

The mediastinal and cardiac silhouette are normal.

Cardiothoracic ratio is normal.

Bones of the thoracic cage are normal.

Soft tissues of the chest wall are normal.

IMPRESSION:

NORMAL STUDY

Dr. Vijay Kumar
MBBS, MDRD
Consultant Radiologist

**BANGALORE DIAGNOSTICS &
MULTI-SPECIALITY CENTRE**
198, 12th Main, 3rd Block
Rajajinagar, Bangalore-560 010

R



DXV35 MRS ARTHI 41 F 12.03.2022 12:27:01
BANGALORE DIAGNOSTIC SERVICE RAJAJINAGARA BANGALORE-560010



Bangalore Diagnostics & Multi-Speciality Centre

Quality Assurance : EQAP from AIIMS & CMC- Vellore

Quality. Trust. Since 1982.

198, 12th Main, 3rd Block, (Above Namma MTR, Next to SBI), Rajajinagar, Bangalore- 560 010.
Ph. : 080-23505407, 9448079978 e-mail : bangalore.d.s@gmail.com

ELECTROCARDIOGRAM

NAME/AGE : mess. Aarthi

Lab No.: Banks of Barode DATE: 12/03/22

ECG FINDINGS

Standardization	<u>low</u>	Rate	<u>80b</u>
Rhythm	<u>sin</u>	Axis	<u>N</u>
P Wave	<u>N</u>	PR Interval	<u>0.16 sec</u>
Q Wave	<u>N</u>	QRS Voltage	<u>SVI + AVI 5.2</u>
QRS Duration	<u>0.08 sec</u>	ST Segment	<u>ST Elevate</u>
QT interval	<u>0.35 sec</u>		
U Wave		Wave	<u>N</u>
Recommendations <u>Normal</u>			

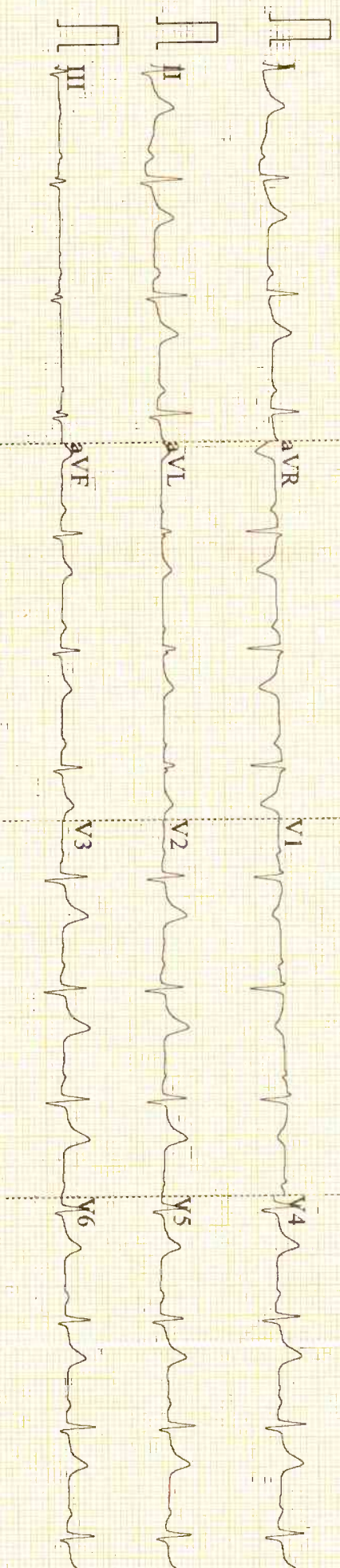
Dr. [Signature]

BANGALORE DIAGNOSTICS &
MULTI-SPECIALITY CENTRE
198, 12th Main, 3rd Block
Rajajinagar, Bangalore-560 010

Dr. ASHOK
MD (Internal Medicine)
Reg No 13444

ID: 1540 12-03-2022 01:07:47 PM

0.15~35Hz AC50 25mm/s 10mm/mV 80 VI.0 SEMIP VI.7



ID: 1540

Female
41 Years
cm

kg

mmHg

Diagnosis Information:
Sinus Rhythm
Poor R Wave Progression (V4, V5)
Low Voltage (Chest Leads)

HR	:	80	bpm
P	:	102	ms
PR	:	161	ms
QRS	:	83	ms
QT/QTc	:	369/426	ms
P/QRS/T	:	47/22/34	°
RV5/SV1	:	0.423/0.470	mV

Report Confirmed by: MM

AP01A17