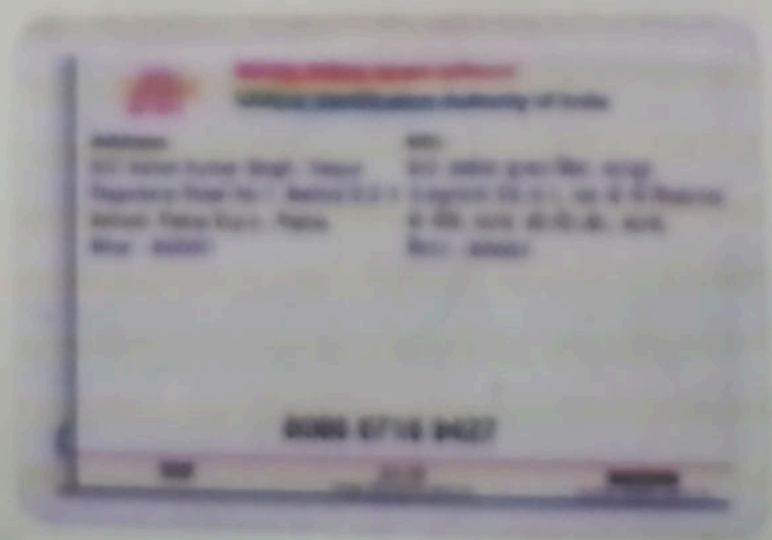




Handwritten signature



Pt. Name :- KUMAR HARSHVARDHAN
Ref. By :- DR .MEDIWEEL

Date:- 23-Sep-22
Age / Sex - 34 Yrs. M.

Thanks for your kind referral

X-RAYCHEST (P.A.VIEW)

The lungs on the either side show equal translucency.

The peripheral pulmonary vasculature is normal.

No focal lung lesion is seen.

The pleural spaces are normal.

Both hila are normal in size, have equal density and bear normal relationship.

The heart and trachea are central in position and no mediastinal abnormality is visible.

The cardiac size is normal.

The domes of the diaphragms are normal in position, and show smooth outline.

IMPRESSION

- NO EVIDENCE OF PULMONARY OR CARDIAC PATHOLOGY IS NOTED.

↓
e
23/9/22

ESTB BY:-

Dr. P. K. Tiwari
MD, M.Sc (Radio Imaging)
Ph.D (Al) Nuclear Medicine
Consultant Imaginologist & Sonologist

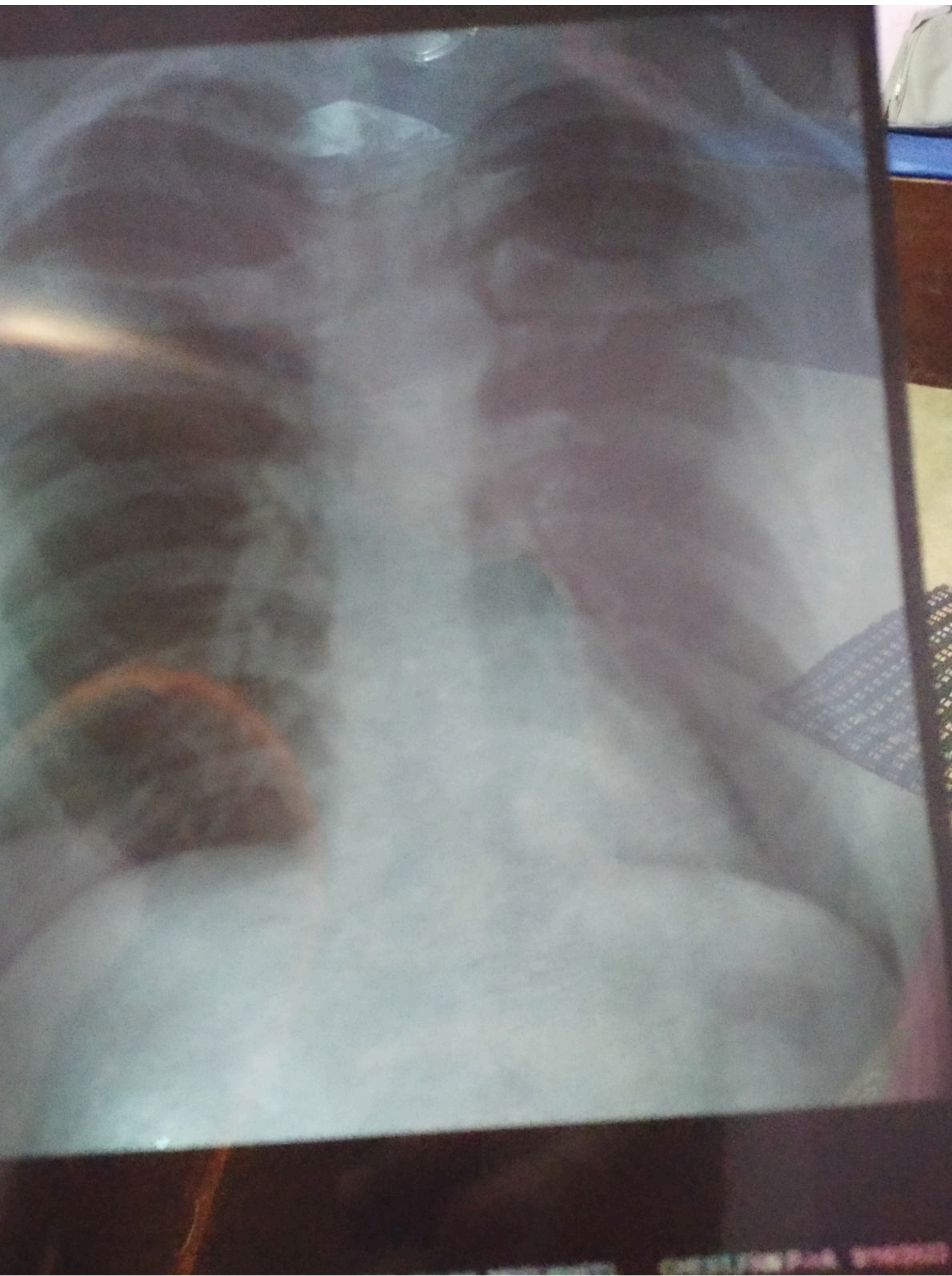Dr. S. Kumar
MD (Pat)
Consultant Pathologist

Dr. Abhishek Kumar
MBBS, MD
Consultant Neuropatho Physiologist

Dr. Kumari Suman
MBBS, DGO, MD
Consultant (TVS & HSG Specialist)

Dr. A. K. Singh
MBBS, PGDMCH
Consultant Radiologist & Sonologist

Consultant Radiologist



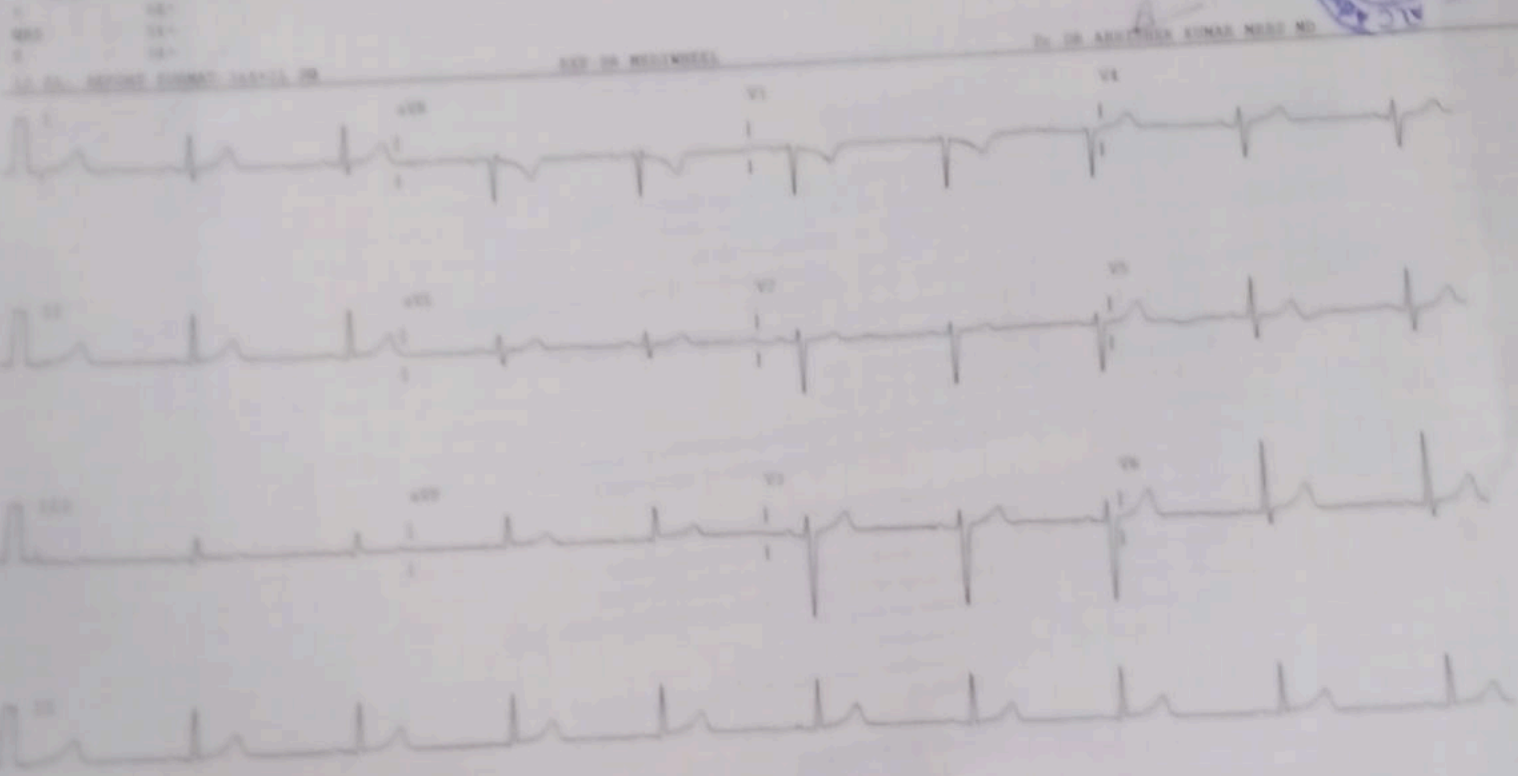
PRINTING MISTAKE SHOULD BE REPORTED BACK IMMEDIATELY

23/09/2022 11:07:06

ALC ADVANCE IMAGING DIAGNOSTICS
E95 PC COLONY KANKARBAGH PATNA

ED 1805 CASE 1 KUMAR HARSHVARDAN
AGE 34Y 0M 0D MALE

HTA 165 CM
WGT 75 KG
PULSE 80
BP 120/80
TEMP 37.5
RESPIR 18



ECG REPORT: Normal sinus rhythm, normal intervals, no ST-T changes.

Date: 23-Sep-22
Time: 11:07 AM

ALC Advance Imaging Diagnostics





Pt. Name :- **KUMAR HARSHVARDHAN**
Ref. By :- **DR. / MEDHHEEL**

Date :- **23-Sep-22**
Age / Sex - **Yrs. M.**


REAL TIME U.S.G. OF WHOLE ABDOMEN
Thanks for your kind referral

(Report,)

- LIVER** :- Measures 13.92 cm. Normal in shape, size and echo texture. I.H.B.R. are not dilated. Hepatic veins are normal. No SOL seen.
- G.BL.** :- Lumen is echo free. Wall thickness appears normal.
- C.B.D.** :- Measures 3.3 mm in diameter with echo free lumen. No calculi or mass seen.
- P.V.** :- Measures 7.2 mm in diameter. Appears normal. No thrombus seen.
- PANCREAS** :- Normal in shape, size and echo texture. No calcification mass seen.
- SPLEEN** :- Measures 10.29 cm. Normal in shape, size and echo texture. No SOL seen.
- KIDNEY** :- Both kidney shows normal shape, size & echotexture. C.M.D, intact. P.C.S is not dilated. No calculi, cyst or hydronephrosis seen on either side.
- Right Kidney** :- Measures 9.70 X 4.3 cm.
- Left Kidney** :- Measures 9.50 X 4.2 cm.
- URETER** :- Not dilated. No apparent calculi seen.
- U.BLADDER** :- Shows normal in outline with echo free lumen. No calculi or mass seen.
- Pre void - 280 ml. Post void - is in significant**
- PROSTATE** :- Measures 15 gms (approx). Appears Normal in size, shape, and echo texture. No calcification, mass, growth seen. capsule is intact.
- R.I.F.** :- Son graphically no appendicular mass or collection seen.
- OTHERS** :- No Ascites, no Lymph Adenopathy. No pleural effusion seen on either side.

IMPRESSION

➤ **Son graphically normal scan no detectable lesion seen**


23/9/22

Consultant Radiologist

ESTB BY-

DR. P. K. TIWARI
MD, M.Sc. (Radio Imaging)
M.D. (Ab. Nuclear Medicine)
Consultant Imagingologist & Sonologist

DR. S. KUMAR
MD (Path)
Consultant Pathologist

DR. ABHISHIK KUMAR
MBBS, MD
Consultant Neuro Patho Physiologist

DR. KUMARI SUMAN
MBBS, DGO, MCh
Consultant (Tvs to HSG Specialist)

DR. A. K. SINGH
MBBS, PGDMSCH
Consultant Radiologist Esomologist

A.L.C. ADVANCE IMAGING DIAGNOSTICS
E-95, P/C COLONY KANKARBAGH PATNA-20

4072 / MR. KUMAR HARSHVARDHAN / 34 Yrs / M / 171 Cms / 78 Kg Date: 23-Sep-2022 Technician : ARUN

Report



Stage	Time	Duration	Pull Speed (mmpl)	Elevation	METS	Rate	% THR Achieved	BP	RPP	PVC	Comments
Supine	01:28	0:01	00.0	00.0	01.0	89	48 %	120/80	106	00	
Standing	01:36	0:01	00.0	00.0	01.0	89	48 %	120/80	106	00	
HV	01:55	0:01	00.0	00.0	01.0	093	45 %	120/80	099	00	
Warm Up	02:23	0:01	01.0	00.0	01.0	092	49 %	120/80	110	00	
Ex-Start	02:48	0:07	01.7	10.0	01.1	084	45 %	120/80	100	00	
BRUCE Stage 1	05:48	3:00	01.7	10.0	04.7	120	65 %	125/85	150	00	
BRUCE Stage 2	08:48	3:00	02.5	12.0	07.1	122	66 %	130/80	158	00	
BRUCE Stage 3	11:48	3:00	03.4	14.0	10.2	145	78 %	140/100	203	00	
PeakEx	11:52	0:07	00.0	00.0	10.3	146	78 %	140/100	204	00	
Recovery	12:21	0:29	00.0	00.0	07.3	146	78 %	140/100	204	00	
Recovery	13:51	2:00	00.0	00.0	01.0	110	59 %	130/80	143	00	
Recovery	15:29	3:37	00.0	00.0	01.0	096	52 %	120/80	115	00	



Findings :

- Exercise Time : 09:05
- Max HR Attained : 146 bpm 78% of Target 186
- Max BP Attained : (Syst) 140/100
- Max Workload Attained : 10.3 Good response to induced stress
- Max ST Dep Lead & Value : II & -2.0 mm in PeakEx mm
- Test End Reasons : Test Complete

Report :

(06021190729)/A/Arun

Doctor : ALC DIAGNOSTIC

[Handwritten Signature]
 23/9/22

SUNDAY

EMERGENCY REPORTING FACILITY AVAILABLE

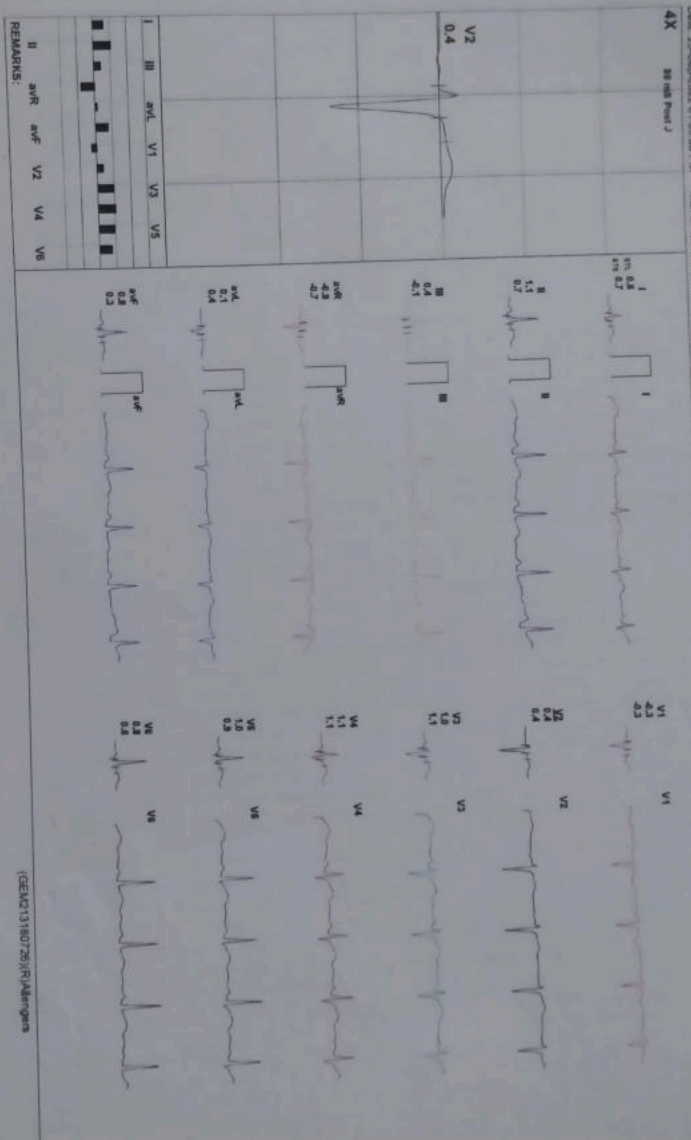
ALLC ADVANCE IMAGING DIAGNOSTICS

4072 / MR KUMAR HARSHVARDHAN / 34 YRS / M / 171 Cm / 78 Kg / HR 89

Date: 23-Sep-2022 01:53:08 PM METS: 1.00 RM bpm 47% at 11HR BP: 120/80 mmHg Scan ECG BLC DOV NIMH ONV HF 0.05 Hz @ F 20 Hz

Supine

ECGTime: 01:28 0.0 mHz 0.2%
28 samples, 1.8 Channel




EMERGENCY REPORTING FACILITY AVAILABLE

SUNDAY 01

ALLC ADVANCE IMAGING DIAGNOSTICS

4072 / MR KUMAR HARSHVARDHAN / 34 Yrs / M / 171 Cms / 78 Kg / HR 89
 Date: 23-Sep-2022 01:53:08 PM METS: 1.00 88 bpm 87% of 1HR BP: 120/80 mmHg Pnw: ECG BL C On: Nihil On: HF 0.00 HVAL: 20 Hz
 Standing ECGTime: 01:38 0.2 mVp 0.07s
 28 mVp/sec 1.5 Channel



REMARKS: (GEK213180726)R/M/HR/egms

EMERGENCY REPORTING FACILITY AVAILABLE

SUNDAY OPD

ALC. ADVANCE IMAGING DIAGNOSTICS

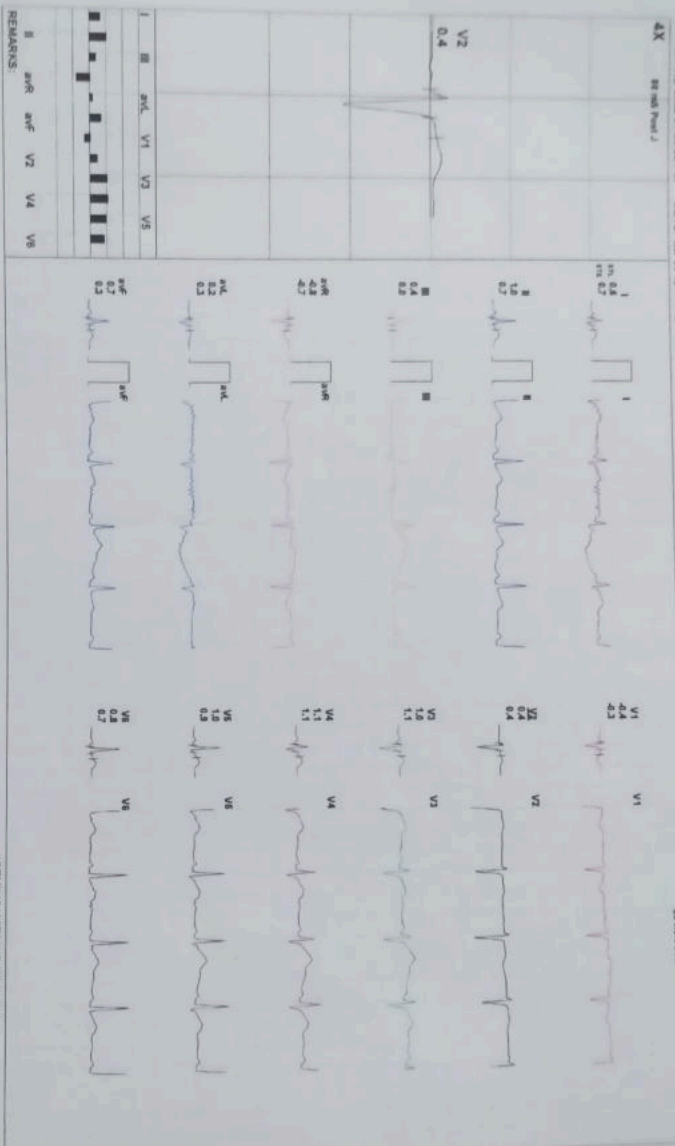
4072 / MR. KULIAH HASSHARQHAN / 34 Yrs / M / 171 Cms / 78 Kg / HR 83

Date: 23-Sep-2022 01:53:08 PM METS: 1.00 83 bpm 48% of ThHR BP: 120/80 mmHg Rest ECG/RLC ON/NOISE CH/HR: 0.05 HRA/F: 20 Hz

HV



ExTime: 01:55 0.0 min 0.0%
28 mV/Div. 1.0 cm/Div



(GEN013)180726(R)Rajadiganis

SUNDAY 0

EMERGENCY REPORTING FACILITY AVAILABLE

Patient's Name: Pachros
 Part Scanned: _____
 Scan No.: _____
 Age/Sex: V1 Date: 24/9/22
 Referred by: Dr. Meeli Wheeler

EMERGENCY REPORTING FACILITY AVAILABLE

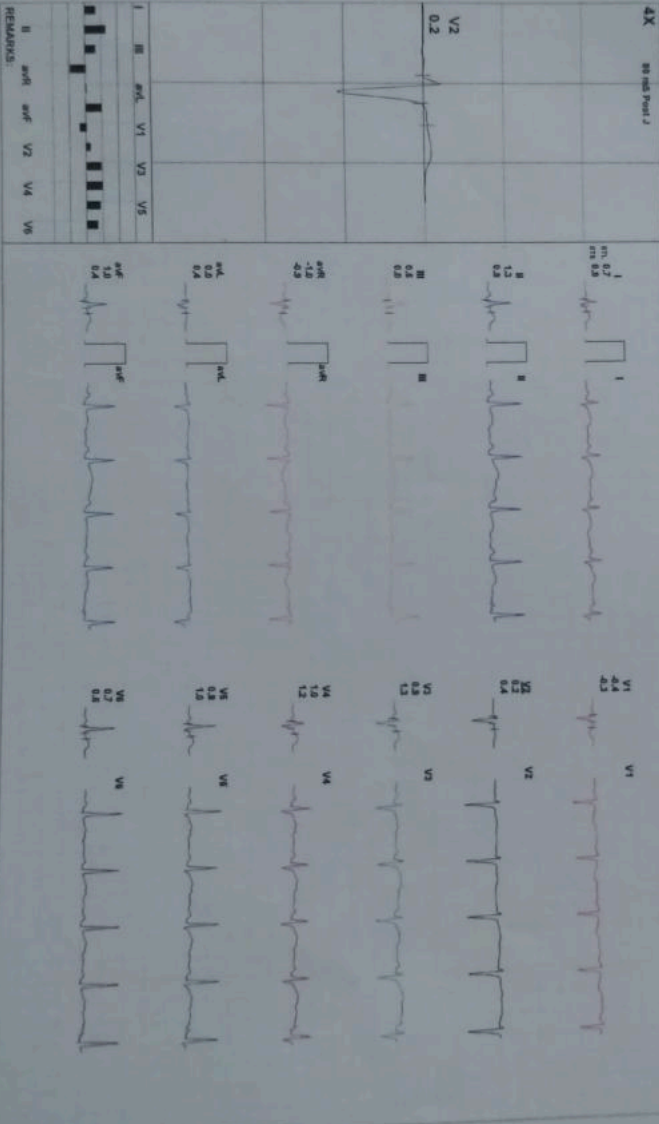
SUNDAY OPEN

ALL C. ADVANCE IMAGING DIAGNOSTICS

Warm Up



4072 / MR KUMAR HARSHWARDHAN / 34 Yrs / M / 171 Cms / 78 Kg / HR 92
 Date: 23-Sep-2022 01:53:08 PM METS: 1.0 82 bpm 80% of THR BP: 120/80 mmHg Brain ECG BLG Chl Nestr Chl Hr 0.05 HALF 20 Hz
 EstTime: 02:24 1.0 mph 0.0%



EMERGENCY REPORTING FACILITY AVAILABLE

SUNDAY OPEN

Referred by: Dr. Neelish...

EMERGENCY REPORTING FACILITY AVAILABLE

SUNDAY OPEN

ALLC ADVANCE IMAGING DIAGNOSTICS

A072 / MR KUMAR HARSHVARDHAN / 34 Yrs / M / 171 Cms / 78 Kg / HR: 84

Date: 23-Sep-2022 01:53:08 PM METS: 1.51 84 bpm 45% of THR BP: 120/80 mmHg Raw ECG BLC ON NICH ON HF 0.05 HALF 20 Hz

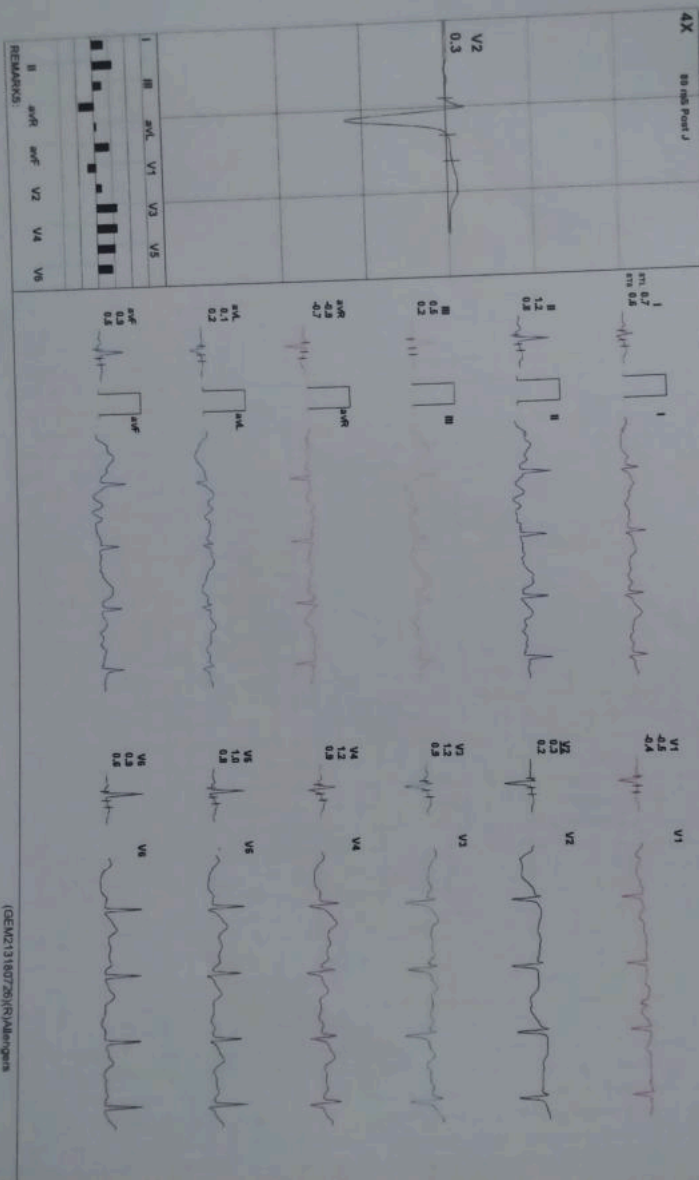
ExTime: 00:07 1.7 mph 10.0%

28 mmHg 1.8 CmmV

ExStart



4X 80 lead Post J



REMARKS:

(GEM213180726/RVAB/0gms)

EMERGENCY REPORTING FACILITY AVAILABLE

SUNDAY OPEN

EMERGENCY REPORTING FACILITY AVAILABLE

SUNDAY OPEN

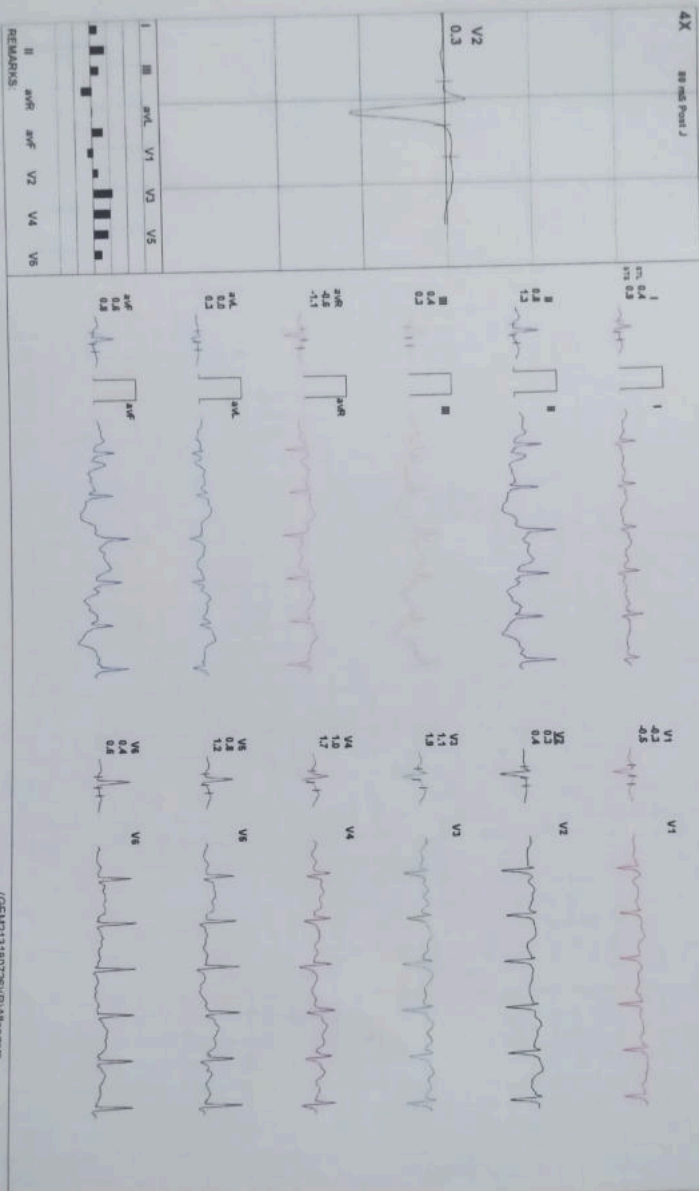
ALLC. ADVANCE IMAGING DIAGNOSTICS

BRUCE: Stage 1(3:00)



4072 / MR. KUMAR HARSHVARDHAN / 34 Yrs / M / 171 Cms / 78 Kg / HR 120
Date: 25-Sep-2022 01:53:09 PM METS: 4.7/ 120 bpm 64% of THR BP: 125/85 mmHg Raw ECG BLC ON Natch Cal: HF 0.05 Hz/LE 20 Hz

ExTime: 03:00 1.7 mph 10.0%
28 min/Sec. 1.0 Cm/IV



EMERGENCY REPORTING FACILITY AVAILABLE

SUNDAY

EMERGENCY REPORTING FACILITY AVAILABLE

SUNDAY OPEN

ALL.C. ADVANCE IMAGING DIAGNOSTICS

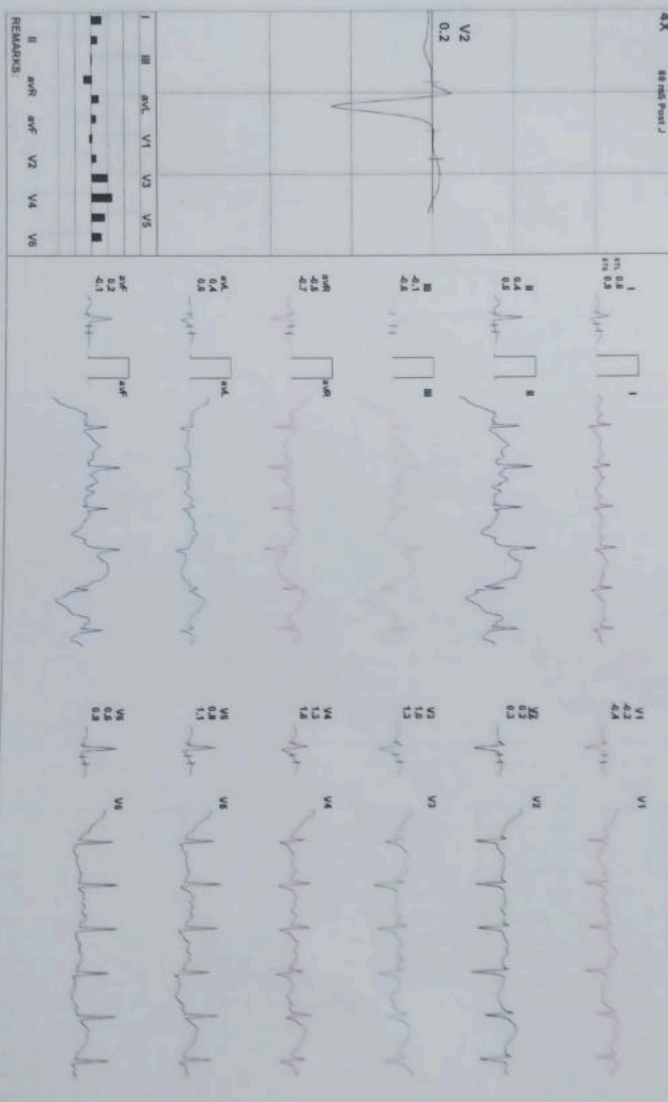
BRUCE: Stage 2(13:00)

4072 / MR KUMAR HARSHWARDHAN / 34 Yrs / M / 177 Cms / 78 Kg / HR 122

Date: 23-SEP-2022 01:53:08 PM METS: 7.51 122 bpm 65% of THR BP: 130/90 mmHg Raw ECG/BLC Cov: Harsh On: HR: 0.06 HVUL: 20 Hz

4X 60 deg Post J

ExTime: 06:59 2.5 cups 122% 28 minutes 1.8 Coupled



(CEMKT3180729)(9)Advarga

EMERGENCY REPORTING FACILITY AVAILABLE

SUNDAY

IMAGING DIAGNOSTICS


Patient's Name: Pradeep Anandh
 Part Scanned: Pacemaker
 Age/Sex: 41 / M Date: 24/9/22
 Scan No.: _____
 Referred by: Dr. Nelli Vebell

SUNDAY OPEN

EMERGENCY REPORTING FACILITY AVAILABLE

A.L.C. ADVANCE IMAGING DIAGNOSTICS

4072 / MR KUMAR HARSHVARDHAN / 34 Yrs / M / 171 Cms / 78 Kg / HR - 145
 Date: 23-Sep-2022 01:53:08 PM METS: 10.21 148 bpm 77% dLTHR BP: 140/100 mmHg Raw ECGI B.L.C. ON NUBIN ON HF 0.05 HALF 20 Hz
 BRUCE: Stage 3(3:00)
 ExtTime: 09:00 3.4 mph 14.0%
 58 rev/sec 1.8 Cm/mV



CGENCT31807281R048489gpm

SUNDAY

- Ultrasound
- Digital X-Ray
- EEG
- Pathology
- EMG
- CT
- TMT
- Colour Doppler
- NCV
- PFT
- HSG
- BERA
- MRI

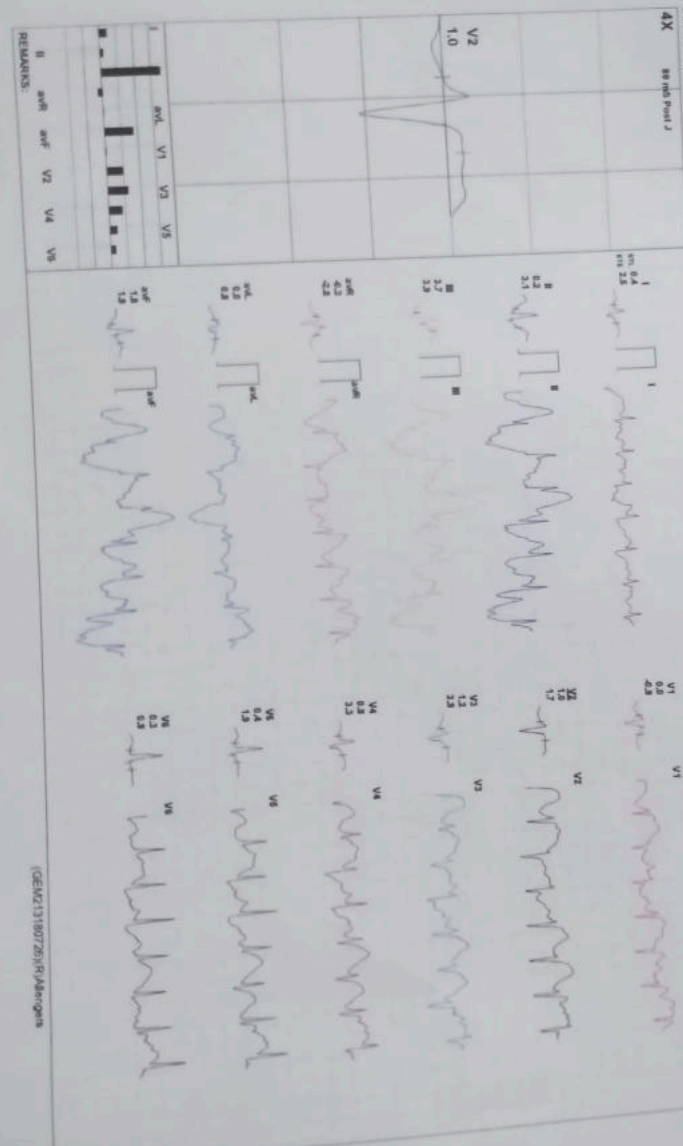
H.O. : E-95, P.C.Colony, Lohianagar, Near Sai Natralaya, Kankarbagh, Patna-20
 B.O. : Ajay Market, Bank of Baroda, Ground Floor, East Ashok Nagar, Kankarbagh, Patna-800007
 B.O. : Shriram Market, Nala Road, Poliganj (Near Devi Mandir)
 e-mail : shubham.pat.usg@gmail.com # website : www.alchealthcheckup.in
MOBILE : 9955245153, 70500037

ALL.C. ADVANCE IMAGING DIGNOSTICS

4072 / MR KUMAR HARSHWARDHAN / 34 YRS / M / 171 Cms / 78 Kg / HR. 145
 Date: 23-Sep-2022 01:53:08 PM METS: 10.2 145 bpm 77% of THR BP: 160/100 mmHg Hemo/CO2 BLC Oxy/Hemo CVR HF 0.05 HRVF 20. 142

BRUCE:Stage 3(13:00)

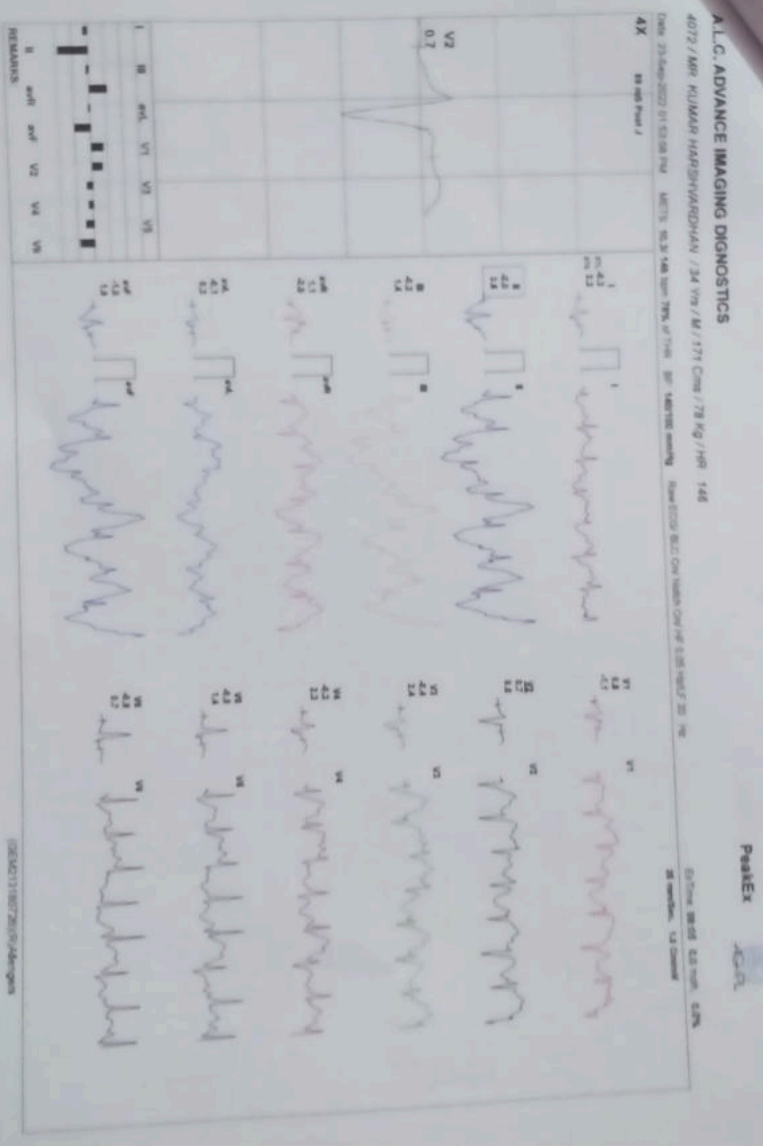
ExTime: 09:00 3.4 mph. 14.0%
 38 minutes. 142 Overall



(GENC13180726)R/M/48/09/20

- Digital X-ray
- HSG
- EEG
- Colour Doppler
- Pathology
- NCV
- EMG
- BERA
- MRI

H.O. : E-95, P.C.Colony, Lohianagar, Near Sai Natralaya, Kankarbagh, Patna-20
 B.O. Ajey Market, Bank of Baroda, Ground Floor, East Ashok Nagar, Kankarbagh, Patna-800002
 B.O. : Shriram Market, Nala Road, Poligarh (Near Devi Mandir)
 e-mail : shubham_pat.usg@gmail.com # website : www.aichealthcheckup.in
MOBILE : 9955245153, 70500037



EMERGENCY REPORTING FACILITY AVAILABLE

SUNDAY

Pathology
EMG

NCV

MRI

H.O. : E-95, P.C.Colony, Lohianagar, Near Sai Natralaya, Kankarbagh, Patna-86
B.O. : Alay Market, Bank of Baroda, Ground Floor, East Ashok Nagar, Kankarbagh, Patna-86
B.O. : Shriram Market, Nala Road, Poliganj (Near Devi Mandir)
e-mail : shubham.pat.usg@gmail.com # website : www.alchealthcheckup.com
MOBILE : 9955245153, 7050003

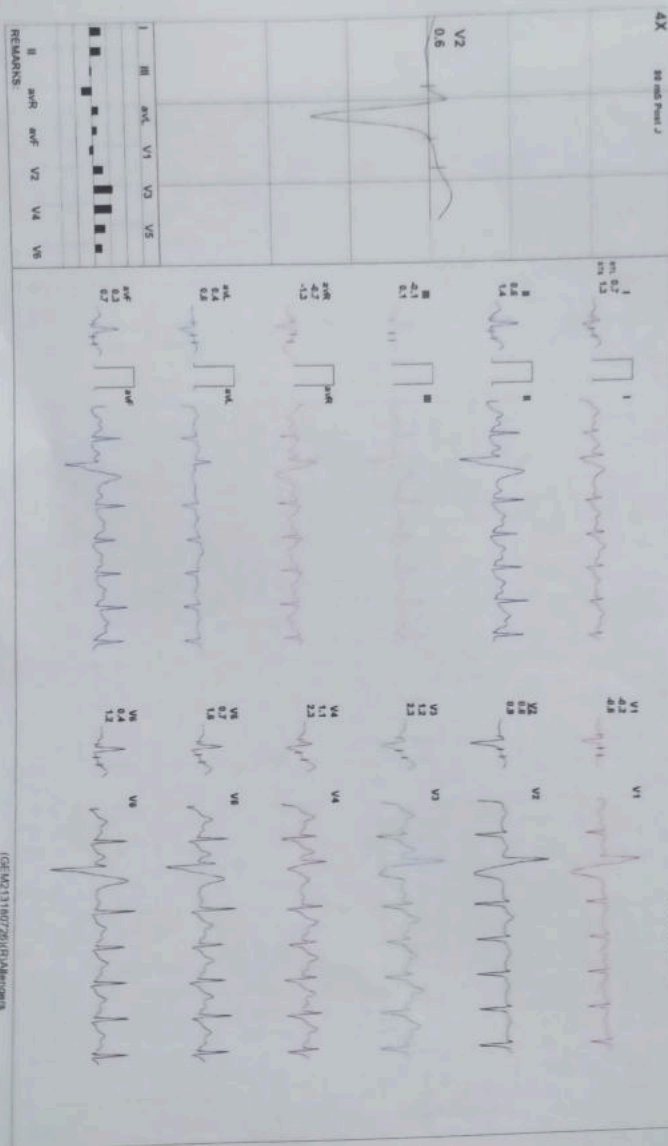
ALC. ADVANCE IMAGING DIAGNOSTICS

4072 / MR KUMAR HARSHWARDHAN / 34 Yrs / M / 171 Cms / 78 Kg / HR 146

Date: 23-Sep-2022 01:53:08 PM METS: 7.2% 148 bpm 78% of THR BP: 140/100 mmHg Raw ECG BLC ON Nihil ON /# 0.06 HV/LT 20 14

Recovery(0:29)

EC Time: 08:05 0.0 min, 0.0%
36 samples, 1.0 Count



GE340C131807291R1PAdiagnostics

SUNDAY


EMERGENCY REPORTING FACILITY AVAILABLE

- Digital X-Ray
- TMT
- PFT
- EEG
- Colour Doppler
- HSG
- Pathology
- NCV
- BERA
- EMG
- MRI

H.O. : E-95, P.C.Colony, Lohianagar, Near Sai Natralaya, Kankarbagh, Patna-21
 B.O. : Shriram Market, Nala Road, Poligarj (Near Devi Mandir)
 e-mail : shubham.pat.usg@gmail.com # website : www.alchealthcheckup.in

MOBILE : 9955245153, 70500037

A.L.C. ADVANCE IMAGING DIAGNOSTICS Recovery(2:00)



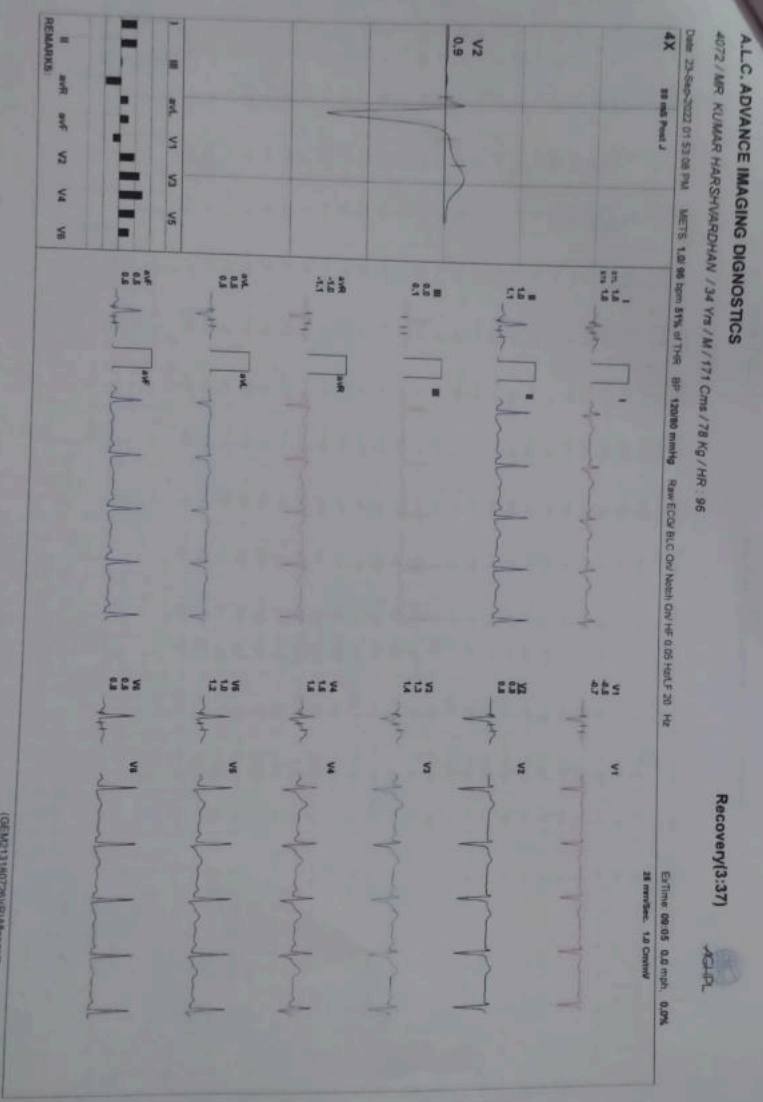
EMERGENCY REPORTING FACILITY AVAILABLE

SUNDAY OPEN

- Ultrasound
- CT
- Digital X-Ray
- TMT
- EEG
- Colour Doppler
- Pathology
- NCV
- EMG
- Echo
- PFT
- BERA
- MRI

H.O. : E-95, P.C.Colony, Lohianagar, Near Sai Natralaya, Kankarbagh, Patna-20
 B.O. : Ajay Market, Bank of Baroda, Ground Floor, East Ashok Nagar, Kankarbagh, Patna-800029
 B.O. : Shriram Market, Nala Road, Poliganj (Near Devi Mandir)
 e-mail : shubham.pat.usg@gmail.com # website : www.alchealthcheckup.in

MOBILE : 9955245153, 70500376



SUNDAY OP

EMERGENCY REPORTING FACILITY AVAILABLE

- EEG
- Pathology
- EMG
- Colour Doppler
- NCV
- BERA
- MRI

H.O. : E-95, P.C.Colony, Lohianagar, Near Sai Natralaya, Kankarbagh, Patna
 B.O. : Ajay Market, Bank of Baroda, Ground Floor, East Ashok Nagar, Kankarbagh, Patna
 B.O. : Shriram Market, Nala Road, Poliganj (Near Devi Mandir)
 e-mail : shubham.pat.usg@gmail.com # website : www.alchealthchecku
MOBILE : 9955245153, 70500

P.C. ADVANCE IMAGING DIAGNOSTICS

6/95, P.C COLONY KANKARBAGH PATNA-20
 4077 / MR. KUMAR HARSINAROHAN / 24 Yrs / Male / 171 Cm / 78 Kg

Median Measurement Summary

Time (Min.)	HR (bpm)	PR (bpm)	QRS WID (ms)	QRS AXIS (Deg)	QTc (ms)	P (ms)	Q (ms)	S (ms)	T (ms)	Min. J Leads for (ms)	Min. Post JPR Var (ms)	VEB (Counts)	Missed Beats (Counts)
00:30	0	0	0	70	0	3163	800	478	3052	-117	V1	0	0
01:00	0	0	0	76	0	154	887	-724	224	-83	V1	0	0
01:30	89	252	54	77	112	141	874	-700	-234	-110	V1	0	0
02:00	83	268	56	76	113	123	806	-892	-211	-124	V1	0	0
02:30	92	100	54	78	292	123	806	-892	-211	-124	V1	0	0
03:00	84	268	56	73	513	-249	700	-717	376	100	III	0	0
03:30	98	170	54	56	428	167	813	-572	275	34	aVF	0	0
04:00	108	100	54	69	126	168	788	-580	-226	177	III	0	0
04:30	112	182	54	75	136	135	815	-599	315	-137	V1	0	0
05:00	114	134	54	73	134	129	819	-608	-223	155	III	0	0
05:30	113	192	54	73	130	150	825	-597	-223	137	III	0	0
06:00	120	182	54	66	131	176	888	-600	-246	121	III	0	0
06:30	117	186	54	66	131	176	888	-600	-246	121	III	0	0
07:00	124	134	54	77	137	159	807	-622	-250	92	V1	0	0
07:30	127	92	54	75	151	190	824	-620	-240	-108	V1	0	0
08:00	126	168	54	78	153	190	785	-630	-275	76	II	0	0
08:30	123	176	54	75	132	167	813	-644	-345	64	aVL	0	0
09:00	126	168	54	73	168	232	868	-638	327	-108	aVL	0	0
09:30	123	176	54	73	168	232	868	-638	327	-108	aVL	0	0
10:00	144	146	54	81	168	279	770	-630	328	-221	aVL	0	0
10:30	144	146	54	81	168	279	770	-630	328	-221	aVL	0	0
11:00	147	136	54	81	382	-259	773	-602	-396	-61	aVF	0	0
11:30	144	142	52	81	333	320	814	-562	489	51	aVF	0	0
12:00	144	142	54	84	162	389	749	-681	407	-112	II	0	0
12:30	145	142	52	84	353	216	728	-737	381	221	III	0	0

EMERGENCY REPORTING FACILITY AVAILABLE

SUNDAY

- Ultrasound
- Digital X-Ray
- EEG
- Pathology
- EMG
- TMT
- Colour Doppler
- NCV
- PFT
- HSG
- BERA
- MRI

H.O. : E-95, P.C.Colony, Lohianagar, Near Sai Natralaya, Kankarbagh, Patna-86
 B.O. : Ajay Market, Bank of Baroda, Ground Floor, East Ashok Nagar, Kankarbagh, Patna-86
 B.O. : Shriram Market, Nala Road, Poliganj (Near Devi Mandir)
 e-mail : shubham.pat.usg@gmail.com # website : www.alchealthcheckup.com
MOBILE : 9955245153, 7050003

ADVANCE IMAGING DIGNOSTICS

ALCHEALTH PVT. COLONY KANKARBAGH PATNA-20
 OFFICE: 808, KUMAR HASTHAKRISHAN / 24 Vm / Male / 771 Cm / 78 Kg

Median Measurement Summary

Time (Min)	HR (bpm)	PR Int (ms)	QRS Wid (ms)	QRS Axis (Deg)	QTC (ms)	PR/V (ms)	RP/V (ms)	SP/V (ms)	TR/V (ms)	Min. J Leads for QRS (ms)	Min. Post JQR View (ms)	VEB (Count)	Missed Beats (Count)
13:30	118	174	52	95	334	186	304	-796	323	271	8	0	0
13:30	104	126	52	86	441	214	832	-796	264	338	8	0	0
14:00	99	126	54	90	447	183	830	-822	284	328	8	0	0
14:30	106	218	54	84	141	186	786	-842	-207	2	18	0	0
15:00	103	136	54	85	143	156	803	-784	-200	20	18	0	0





A.L.C. Advance Imaging Diagnostics

(A Unit of Subham Imaging P.K. Arogyam Health & Wellness Center)

E-95, P.C. Colony, Near Sai Netryalaya Transformer, Kankarbagh, Patna - 20

www.pkarogayamhealthcheckup.com

7050037694, 8271206196

alcdiagnostics@gmail.com

OPINION MUST BE CORRELATES WITH CLINICALLY & OTHER INVESTIGATION FOR FINAL DIAGNOSIS. NOT FOR MEDICO LEGAL PURPOSE

PATIENT NAME : KUMAR HARSH VARDHAN

PATIENT ID: 1905

COL DATE : 23/09/2022 REPORTING DATE: 23/09/2022 AGE SEX:- 34 YRS/M

REF.BY : DR. / MEDIWHEEL.

TEST NAME	RESULT	Unit	REF.RANGE
-----------	--------	------	-----------

BLOOD GROUP	:	'O'	
-------------	---	-----	--

Rh Typing	:	POSITIVE	
-----------	---	----------	--

Note: Do always cross – matching before blood transfusion

ESTB BY:-

Dr. P. K. Tiwari
MD, M.Sc (Radio Imaging)
Ph.D (AI) Nuclear Medicine
Consultant Imaginologist & Sonologist

Dr. S. Kumar
MD (Pat)
Consultant Pathologist

Dr. Abhishek Kumar
MBBS, MD
Consultant Neuropatho Physiologist

Dr. Kumari Suman
MBBS, DGO, MD
Consultant (TVS & HSG Specialist)

Dr. A. K. Singh
MBBS, PGDMCH
Consultant Radiologist & Sonologist

23/09/22
Consultant Radiologist

PRINTING MISTAKE SHOULD BE REPORTED BACK IMMEDIATELY!



A.L.C. Advance Imaging Dignostics

[A Unit of Subham Imaging P.K. Arogyam Health & Wellness Center]

E-95, P.C. Colony, Near Sai Netryalaya Transformer, Kankarbagh, Patna - 20

alodiagnosics@gmail.com

www.pkarogyamhealthcheckup.com

7058937694, 827126196

OPINION MUST BE CORRELATES WITH CLINICALLY & OTHER INVESTIGATION FOR FINAL DIAGNOSIS. NOT FOR MEDICO LEGAL PURPOSE

PATIENT NAME : KUMAR HARSH VARDHAN

PATIENT ID: 1905

COL DATE : 23/09/2022 REPORTING DATE: 23/09/2022 AGE SEX:- 34 YRS/M

REF.BY : DR. /MEDIWHEEL.

ROUTINE EXAMINATION OF URINE

PHYSICAL EXAMINATION

Quantity	20 ml	Colour... .	Straw
Appearance...	Clear	Sediment ...	Nil
Specific gravity....	1.010		

CHEMICAL EXAMINATION

Reaction	6.0	Nitrite.....	Not done
Sugar	Nil	Bile Pigment	Not done
Albumin	Nil	Urobilinogen....	Not done
Excess of Phosphate....	Nil	Chile.....	Not done
Bile Salt	Not Done	Acetone...	Not done

MICROSCOPIC EXAMINATION

Erythrocytes....	Nil	Casts	Nil
Leucocytes	1-3 / HPE	Crystals....	Nil
Epith. Cell	A, Few	Others	Nil

ESTB BY:-

Dr. P. K. Tiwari

MD, M.Sc (Radio Imaging)
Ph.D (Ab Nuclear Medicine)

Consultant Imaginologist & Sonologist

Dr. S. Kumar

MD (Pat)
Consultant Pathologist

Dr. Abhishek Kumar

MBBS, MD
Consultant Neuropatho Physiologist

Dr. Kumari Suman

MBBS, DGO, MD
Consultant (TVS & HSG Specialist)

Dr. A. K. Singh

MBBS, PGDMCH
Consultant Radiologist & Sonologist

23/09/22

Consultant Radiologist

PRINTING MISTAKE SHOULD BE REPORTED BACK IMMEDIATELY/ यहाँ जन्म से पहले भ्रूण का लिंग जाँच नहीं होता है ।

A.L.C. Advance Imaging Dignostics

(A Unit of Subham Imaging P.K. Arogyam Health & Wellness Center)

E-95, P.C. Colony, Near Sai Netryalaya Transformer, Kankarbagh, Patna - 20

alcdiagnostics@gmail.com

www.pkarogyamhealthcheckup.com

7080037694 8271206196

OPINION MUST BE CORRELATES WITH CLINICALLY & OTHER INVESTIGATION FOR FINAL DIAGNOSIS. NOT FOR MEDICO LEGAL PURPOSE

PATIENT NAME : KUMAR HARSH VARDHAN

PATIENT ID: 1905

COL DATE : 23/09/2022 REPORTING DATE: 23/09/2022 AGE SEX:- 34 YRS/M

REF.BY : DR./ MEDIWHEEL.

TEST NAME	RESULT	Unit	REF.RANGE
ESR	14 mm/hr		<20 mm/hr

CBC

Total W.B.C. Count	5,800 /cumm	4000-11,000 /cumm
R B C COUNT	4.55 Million/ CUmm	4 - 7 Million/ CUmm
Platelets count	1.89 Lakh/ cumm	1.5-5.0 Lakh/ cumm
Differential Count of W.B.C.		
Neutrophils	54 %	40-70%
Lymphocytes	43 %	25-40%
Eosinophils	02 %	01-05%
Mnonocytes	01 %	00-02%
Basophiles	00 %	00-0%
HAEMOGLOBIN	13.5 gm/dl (92.4 %)	14.6 gm/dl = 100%
PCV	40.4 %	35-47 %
MCV	88.8 fl	76-96 fl
MCH	29.6 pg	29-35 pg
MCHC	33.4 %	30-38 %

Consultant Radiologist

ESTB BY:-

Dr. P. K. Tiwari
MD, M.Sc (Radio Imaging)
Ph.D (AI) Nuclear Medicine
Consultant Imagianologist & Sonologist

Dr. S. Kumar
MD (Pat)
Consultant Pathologist

Dr. Abhishek Kumar
MBBS, MD
Consultant Neuropatho Physiologist

Dr. Kumari Suman
MBBS, DGO, MD
Consultant (TVS & HSG Specialist)

Dr. A. K. Singh
MBBS, PGDMCH
Consultant Radiologist & Sonologist

PRINTING MISTAKE SHOULD BE REPORTED BACK IMMEDIATELY/ यहाँ जन्म से पहले भ्रुण का लिंग जाँच नहीं होता है ।

(A Unit of Subham Imaging P.K. Arogyam Health & Wellness Center)

E-95, P.C. Colony, Near Sai Netryalaya Transformer, Kankarbagh, Patna - 20

www.pkarogyamhealthcheckup.com

7030027984, 8271206196

OPINION MUST BE CORRELATES WITH CLINICALLY & OTHER INVESTIGATION FOR FINAL DIAGNOSIS. NOT FOR MEDICO LEGAL PURPOSE

PATIENT NAME : KUMAR HARSH VARDHAN

PATIENT ID: 1905


COL DATE : 23/09/2022 REPORTING DATE: 23/09/2022 AGE SEX : 34 YRS/M

REF.BY : DR. /MEDIWHEEL

TEST NAME	RESULT	Unit	REF.RANGE
BLOOD SUGAR (F)	84.0 mg/dl		70 - 110 mg/dl

LIPID PROFILE:-

TOTAL CHOLESTROL	157.0 mg/dl		130 -250 mg/dl
TRIGLYCERIDE	149.0 mg/dl		50 -160 mg/dl
HDL CHOLESTROL	40.0 mg/dl		30 - 60 mg/dl
LDL CHOLESTROL	87.2 mg/dl		80 -130 mg/dl
VLDL CHOLESTROL	29.8 mg/dl		15 - 40 mg/dl
T.CH./HDL RATIO	3.9:1		Upto 5:1
LDL./HDL RATIO	2.1:1		2 - 4:1


Consultant Radiologist

EDITED BY:-

Dr. P. K. Tiwari
MD, M.Ch. Radio Imaging
M.D. (In Nuclear Medicine)
Consultant Imaging & Dosimetry

Dr. S. Kumar
MD (Path)
Consultant Pathologist

Dr. Abhishek Kumar
MBBS, MD
Consultant Neurophysio Physiologist

Dr. Kumari Suman
MBBS, DGO, MD
Consultant (TVS & HSG Specialist)

Dr. A. K. Singh
MBBS, FCIMRCH
Consultant Radiologist (Ultrasound)

PRINTING MISTAKE SHOULD BE REPORTED BACK IMMEDIATELY/यहाँ जन्म से पहले हुए का रिपोर्ट जहाँ नहीं होता है


PATIENT NAME : KUMAR HARSH VARDHAN

PATIENT ID: 1905

COL DATE : 23/09/2022 REPORTING DATE: 23/09/2022 AGE SEX:- 34 YRS/M

REF.BY : DR./ MEDIWHEEL.

TEST NAME	RESULT	Unit	REF.RANGE
LFT:-			
SGPT	59.6	IU/L	5 - 48 IU/L
S G O T	47.0	IU/L	5 - 40 IU/L
ALKALINE PHOSPHATASE	110.2	IU/L	25 - 147 IU/L
TOTAL PROTIN	7.8	g/dl	6.0 - 8.7 g/dl
SERUM ALBUMIN	4.6	g/dl	3.5 - 5.4 g/dl
SERIUM GLUBLINE	3.2	g/dl	2.3 - 3.6 g/dl
AG RATIO	1.4 : 1		1.0 - 2.3 g/dl
BILIRUBIN			
TOTAL	0.70	mg/dl	0.1 - 1.1 mg/dl
IRECT	0.31	mg/dl	0.0 - 0.32 mg/dl
INDIRECT	0.39	mg/dl	0.0 - 0.78 mg/dl
GGTP (GGT)	21.7	iu/L	8 - 38 iu/L
KFT/RFT			
URIC ACID	5.7	mg/dl	3.2 - 7.0 mg/dl
SERUM CREATNINE	1.0	mg/dl	0.6 -1.5 mg/dl
BLOOD URIA	28.7	mg/dl	5 - 45 mg/dl
BLOOD URIA NITROZEN(BUN).	13.4	mg/dl	5 - 23 mg/dl


23/09/22
Consultant Radiologist

ESTB BY:-

Dr. P. K. Tiwari
MD, M.Sc (Radio Imaging)
Ph.D (Ab Nuclear Medicine)
Consultant Imagionologist & Sonologist

Dr. S. Kumar
MD (Pat)
Consultant Pathologist

Dr. Abhishek Kumar
MBBS, MD
Consultant Neuropatho Physiologist

Dr. Kumari Suman
MBBS, DGO, MD
Consultant (TVS & HSG Specialist)

Dr. A. K. Singh
MBBS, PGDMCH
Consultant Radiologist & Sonologist

PRINTING MISTAKE SHOULD BE REPORTED BACK IMMEDIATELY/ यहाँ जन्म से पहले भ्रूण का लिंग जाँच नहीं होता है

EEG

Pathology

Colour Doppler

Advance Imaging Dignostics

ISO 9001:2015 Certified center

(A Unit of Subham Imaging P.K. Arogyam Health & Wellness Center)

E-95, P.C. Colony, Near Sai Netryalaya Transformer, Kankarbagh, Patna - 20

diagnostics@gmail.com

www.pkarogayamhealthcheckup.com

7050037694, 8271206196

OPINION MUST BE CORRELATES WITH CLINICALLY & OTHER INVESTIGATION FOR FINAL DIAGNOSIS. NOT FOR MEDICO LEGAL PURPOSE

PATIENT NAME : KUMAR HARSH VARDHAN

PATIENT ID: 1905

COL DATE : 23/09/2022 REPORTING DATE: 23/09/2022 AGE SEX : 34 YRS/M

REF.BY : DR./ MEDIWHEEL.

GLYCOSYLATED HEMOGLOBIN

TEST NAME	RESULT	Unit	REF.RANGE
HbA1c	3.8 %		Below 5.7 % : Normal 5.7 – 6.4 % : Prediabetic > = 6.5 % : Diabetic
AVERAGE PLASMA GLUCOSE	92.0 mg/dl		90 – 120 mg/dl : Good Control 121– 150 mg/dl : Fair Control 151- 180 mg/dl: Unsatisfactory Control >180 mg/dl : Poor Control

[Handwritten Signature]
23/09/22
Consultant Radiologist

EEG

Pathology

Colour Doppler

Advance Imaging Dignostics

ISO 9001:2015 Certified center

(A Unit of Subham Imaging P.K. Arogyam Health & Wellness Center)

E-95, P.C. Colony, Near Sai Netryalaya Transformer, Kankarbagh, Patna - 20

diagnostics@gmail.com

www.pkarogayamhealthcheckup.com

7050037694, 8271206196

OPINION MUST BE CORRELATES WITH CLINICALLY & OTHER INVESTIGATION FOR FINAL DIAGNOSIS. NOT FOR MEDICO LEGAL PURPOSE

PATIENT NAME : KUMAR HARSH VARDHAN

PATIENT ID: 1905

COL DATE : 23/09/2022 REPORTING DATE: 23/09/2022 AGE SEX : 34 YRS/M

REF.BY : DR./ MEDIWHEEL

GLYCOSYLATED HEMOGLOBIN

TEST NAME	RESULT	Unit	REF.RANGE
HbA1c	3.8 %		Below 5.7 % : Normal 5.7 – 6.4 % : Prediabetic > = 6.5 % : Diabetic
AVERAGE PLASMA GLUCOSE	92.0 mg/dl		90 – 120 mg/dl : Good Control 121 – 150 mg/dl : Fair Control 151- 180 mg/dl: Unsatisfactory Control >180 mg/dl : Poor Control

[Handwritten Signature]
23/09/22
Consultant Radiologist

Advance Imaging Diagnostics
ISO 9001:2015 Certified center
(A Unit of Subham Imaging P.K. Arogyam Health & Wellness Center)

E-95, P.C. Colony, Near Sai Netryalaya Transformer, Kankarbagh, Patna - 20
www.pkarogyamhealthcheckup.com

7050037694, 8271206196

diagnostics@gmail.com

OPINION MUST BE CORRELATES WITH CLINICALLY & OTHER INVESTIGATION FOR FINAL DIAGNOSIS. NOT FOR MEDICO LEGAL PURPOSE
PATIENT NAME : KUMAR HARSH VARDHAN PATIENT ID: 1905

COL DATE : 23/09/2022 REPORTING DATE: 23/09/2022 AGE SEX:- 34 YRS/M

REF.BY : DR / MEDIWHEAL

TEST NAME	RESULT	Unit	REF.RANGE
Total Triiodothyronin T3	1.29	ng/mL	0.80 -2.00 ng/mL
Total Thyroxin T4	7.02	µg/dL	5.10 -14.10 µg/dL
Serum TSH	2.10	µIU/mL	0.27 - 4.20 µIU/mL

THYROID DISORDER (>: Increase: < Decrease: n Normal

1. T3(n) T4(n) TSH(n) :EUTHYROID STATE:
2. T3(>) T4(>) TSH(<): HYPERTHYROIDISM:
3. T3(<)T4(<) TSH(>): HYPOTHYROIDISM:
4. T3(n)T4(n) TSH(>) : SUB-CLINICAL HYPO-THYROIDISM:
5. T3(n)T4(n) TSH(<): SUB-CLINICAL HYPER-THYROIDISM:
6. T3(>) T4(n) TSH(<): T3 THYROTOXICOSIS:

Total T3/T4 level is dependent on Level:

So determination of free T3/T4is a better MARKER of Thyroid Function.


Consultant Radiologist

Dr. P. K. Tiwari
MD (in Radio Imaging)
MD (in Nuclear Medicine)

Dr. S. Kumar Dr. Abhishek Kumar
MD (Pat)
Consultant Pathologist

MBBS, MD
Consultant

Dr. Kumari Suman
MBBS, DGO, MD

Dr. A. K. Singh

