



सत्यमेव जयते
भारत सरकार



ભારતીય વિશિષ્ટ ઓળખાણ પ્રાધિકરણ

ભારત સરકાર
Unique Identification Authority of India
Government of India

નોંધણીની ઓળખ / Enrollment No.: 2715/14859/72563


To,
લીલાબેન પ્રાણુભાઈ પટેલ
Leelaben Pranubhai Patel
C/O Bipinbhai Patel
MOTI DHODIYAWAD
-
PARNERA Valsad
Parnera (urban) Valsad Valsad
Gujarat 396020
9879429631

12/04/2013

Ref: 1787 / 03T / 242481 / 242491 / P



SB978194405FH



તમારો આધાર નંબર / Your Aadhaar No. :

8306 1818 8469

મારો આધાર, મારી ઓળખ



ભારત સરકાર

Government of India



લીલાબેન પ્રાણુભાઈ પટેલ
Leelaben Pranubhai Patel
જન્મ તારીખ / DOB : 01/06/1972
સ્ત્રી / Female



8306 1818 8469

મારો આધાર, મારી ઓળખ



सत्यमेव जयते
Government of India



निर्देश

- **આધાર** ઓળખનું પ્રમાણ છે, નાગરિકતાનું નહિ .
- ઓળખનું પ્રમાણ ઓનલાઇન ઓથેન્ટિકેશન દ્વારા પ્રાપ્ત કરો .

INFORMATION

- **Aadhaar** is proof of identity, not of citizenship .
- To establish identity, authenticate online .


- **આધાર** દેશભરમાં માન્ય છે .
- **આધાર** ભવિષ્યમાં સરકારી અને બિન-સરકારી સેવાઓનો લાભ મેળવવામાં ઉપયોગી થશે .
- **Aadhaar** is valid throughout the country .
- **Aadhaar** will be helpful in availing Government and Non-Government services in future .

03T / 242481



ભારતીય વિશિષ્ટ ઓળખાણ-પ્રાધિકરણ
Unique Identification Authority of India

સરનામું: C/O બીપીનભાઈ પટેલ, મોટી ઢોડીયાવાડ, -,
પારનેરા, વલસાડ, પારનેરા અર્બન, ગુજરાત, 396020
Address: C/O Bipinbhai Patel, MOTI DHODIYAWAD,
-, PARNERA, Valsad, Parnera (urban), Gujarat,
396020



8306 1818 8469



1947



help@uidai.gov.in



www.uidai.gov.in



बैंक ऑफ़ बड़ौदा
Bank of Baroda



नाम

बिपिनभाई नमलाभाई पटेल

Name

BIPINBHAI NAMALABHAI PATEL

कर्मचारी कूट क्र.

E.C. No.

57757

जारीकर्ता प्राधिकारी
Issuing Authority

धारक के हस्ताक्षर
Signature of Holder



To,

The Coordinator,
Mediwheel (Arcofemi Healthcare Limited)
Helpline number: 011- 41195959

Dear Sir / Madam,

Sub: Annual Health Checkup for the employees of Bank of Baroda

This is to inform you that the following spouse of our employee wishes to avail the facility of Cashless Annual Health Checkup provided by you in terms of our agreement.

PARTICULARS OF HEALTH CHECK UP BENEFICIARY	
NAME	LEELABEN BIPINPATEL
DATE OF BIRTH	01-06-1972
PROPOSED DATE OF HEALTH CHECKUP FOR EMPLOYEE SPOUSE	27-08-2022
BOOKING REFERENCE NO.	22S57757100024214S
SPOUSE DETAILS	
EMPLOYEE NAME	MR. PATEL BIPIN N
EMPLOYEE EC NO.	57757
EMPLOYEE DESIGNATION	HEAD CASHIER "E" _II
EMPLOYEE PLACE OF WORK	PARNERA
EMPLOYEE BIRTHDATE	17-03-1968

This letter of approval / recommendation is valid if submitted along with copy of the Bank of Baroda employee id card. This approval is valid from **25-08-2022** till **31-03-2023**. The list of medical tests to be conducted is provided in the annexure to this letter. Please note that the said health checkup is a **cashless facility** as per our tie up arrangement. We request you to attend to the health checkup requirement of our employee's spouse and accord your top priority and best resources in this regard. The EC Number and the booking reference number as given in the above table shall be mentioned in the invoice, invariably.

We solicit your co-operation in this regard.

Yours faithfully,

Sd/-

**Chief General Manager
HRM Department
Bank of Baroda**

(Note: This is a computer generated letter. No Signature required. For any clarification, please contact Mediwheel (Arcofemi Healthcare Limited))



GPS Map
Camera Lite

XW6H+RM5, Mahavir Society, Viraval, Gujarat 396445, India

Latitude
20.9620075°

Longitude
72.9291847°

Local 09:53:30 AM
GMT 04:23:30 AM

Altitude -49.3 meters
Saturday, 27 Aug 2022



YASHFEEN CARDIAC HOSPITALS™

MANAGED BY : YASHFEEN FOUNDATION,

At. & Po. Viraval, Navsari. 396 445. Phone (H) (02637) 235725

(Regd. No.E/ 1390 / Navsari)



Date :

Niranjan Ojha

CH22020571 27/08/2022

LEELABEN PRANUBHAI
50/F

Panera, Valsad, 9879429631



Hooghel Co.

P/12345

lilaben ,
ID:
DOB:
Female ,Unknown
Med.:
Location:
Referring Physician:
Notes:

27/08/2022 9:30:29 AM

Vent. Rate: 87 BPM
PR int: 162 ms
QRS dur: 86 ms
QT/QTc: 335/380 ms
P-R-T axes: 58 23 -34
Avg. RR: 683 ms
QTcB: 405 ms
QTcF: 380 ms

SINUS RHYTHM
MODERATE T-WAVE ABNORMALITY, CONSIDER INFERIOR ISCHEMIA
ABNORMAL ECG
INTERPRETATION BASED ON A DEFAULT AGE OF 40 YEARS

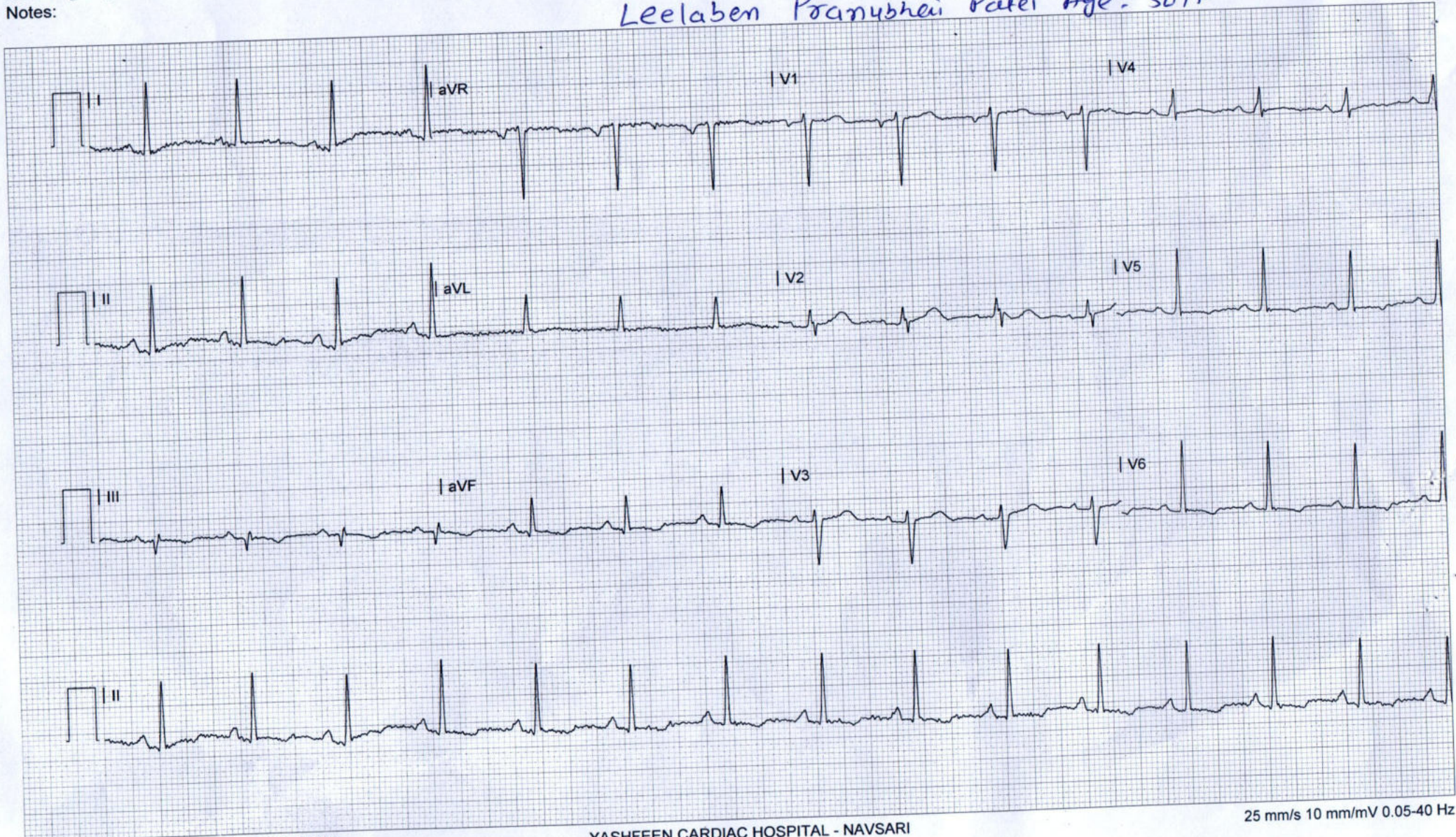
UNCONFIRMED REPORT
Reviewed by:

P. Chaudhari
Dr. PIYUSH B. CHAUDHARI
M.D. Medicine
Reg. No. G-21518

Signed by:
Date:



Leelaben Pranubhai Patel Age - 50/F



YASHFEEN IMAGING & RADIOLOGY DEPARTMENT

MANAGED BY :- YASHFEEN FOUNDATION

VIRAVAL, NAVSARI. 396 445. PHONE : (H) (02637) 235725

Website : www.yashfeenhospital.in E-mail : info@yashfeenhospital.in

Name	LEELABEN PRANUBHAI PATEL	Age	50Y/F
Ref by Dr	SELF	Date	27/08/2022

USG BOTH BREASTS (SCREENING)

Breast parenchyma appears normal.
No e/o focal solid or cystic lesion.
No e/o mass or abscess.
No e/o calcification.
Skin and subcutaneous tissue appears normal
Pectoral muscles appear normal
Axillary region appears normal.

IMPRESSION:

No significant abnormality detected.



Dr. DHARMESH DESAI
(M.D. Radiology)
Reg. No. G- 45284
Dr. Dharmesh Desai
YASHFEEN GROUP OF HOSPITAL

Please contact immediately for any typographical error.

This is only professional opinion, not a final diagnosis. Kindly correlate clinically. Not valid for medicolegal purpose.

YASHFEEN IMAGING & RADIOLOGY DEPARTMENT

MANAGED BY :- YASHFEEN FOUNDATION

VIRAVAL, NAVSARI. 396 445. PHONE : (H) (02637) 235725

Website : www.yashfeenhospital.in E-mail : info@yashfeenhospital.in

Name	LEELABEN PRANUBHAI PATEL	Age	50Y/F
Ref by Dr	SELF	Date	27/08/2022

USG ABDOMEN & PELVIS (SCREENING)(TVS)

Liver appears enlarged in size & shape with bright echopattern.
No e/o focal lesion. IHBR appear normal.
PV and CBD appear normal.

Gall bladder appears distended & normal in shape & size. No e/o calculus or mass seen.
Walls appear normal.

Pancreas appears normal in size and echogenicity. No e/o focal or diffuse lesion.

Spleen appears normal in size and shows normal echopattern. No e/o focal lesion.

Both Kidneys appear normal in size and echopattern. CM Differentiation is preserved.
No e/o calculus or hydronephrosis on either side.
Perirenal spaces appear normal on either side.
Suprarenal regions appear normal on either side. No e/o mass lesion.

Bladder is physiologically distended. No e/o calculus or mass. Walls appear normal.

Uterus is not seen post hysterectomy status.

RIF region appears normal.

No e/o ascites.

IMPRESSION:

Mild hepatomegaly with grade III fatty changes.



Dr. DHARMESH DESAI

(M.D. Radiology)

Reg. No. G - 45284

Dr. Dharmesh Desai
YASHFEEN GROUP OF HOSPITAL
MB

Please contact immediately for any typographical error.

This is only professional opinion, not a final diagnosis. Kindly correlate clinically. Not valid for medicolegal purpose.

YASHFEEN CARDIAC HOSPITAL™

MANAGED BY :- YASHFEEN FOUNDATION

VIRAVAL, NAVSARI. 396 445. PHONE : (H) (02637) 235725

Website : www.yashfeenhospital.in E-mail : info@yashfeenhospital.in



(Regd. No. E / 1390 / Navsari)

2D ECHO CARDIOGRAPHY COLOUR DOPPLER REPORT

Patient Name & No : LEELABEN PRANUBHAI PATEL CH22020481 Age/Sex UHID : : 3488
Doctor : Mohil Nagad 50/ F No : : 2769
Referred By : Date : : 27/08/2022

M-Mode findings

LVIDd : 46mm
LVIDs : 32mm
IVSd : 09mm
PWd : 08mm
EF : 55%
Aorta : 22mm
LA : 35mm

2D Imaging

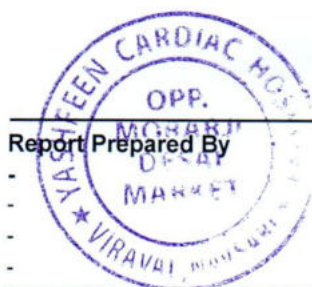
Aortic Valve : Trileaflet, Sclerotic AV, Trace AR.
Mitral Valve : Thin, Pliable, Normal Mobility, Mild MR.
Tricuspid Valve : Mild TR, RVSP: 20+ RAP
Pulmonary Valve : Normal

⇒ : All cardiac chambers are normal sized.
⇒ : All cardiac valves are normal.
⇒ : No regional wall motion abnormality.
⇒ : Normal LV systolic function.
⇒ : Normal LV diastolic function.
⇒ : IAS/IVS intact.
⇒ : No obvious clots/ vegetations/ or effusion.
⇒ : IVC (10mm) 50% Collapsing with inspiration

Doppler Findings

⇒ : No MS/Mild MR, No TS/Mild TR, No AS/Trace AR & No PS/PR
Mitral inflow Pattern : E > A
Tissue Doppler Findings : E' > A'

Impression : Normal LVEF: 55%, No RWMA, Mild MR.



Report Prepared By

Report Checked By

DR. MOHIL NAGAD
M.D. (Phy) Dip. Cardiology
Senior Consultant Non-Invasive Cardiology
Reg. No. G- 22893
YASHFEEN HOSPITAL, NAVSARI

Designed By : Sarita Infotech Pvt. Ltd., Navsari



YASHFEEN CARDIAC HOSPITAL

EYE DEPARTMENT

Chief Complaint :

Refraction Checked

Medical History : DM / HT / Asthama / Allergy / Heart / Thyroid /

Hb long Glass

Ocular History :

Visual Acuity :

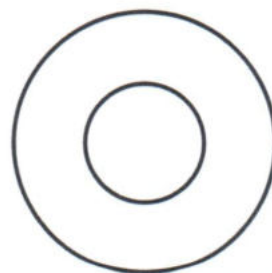
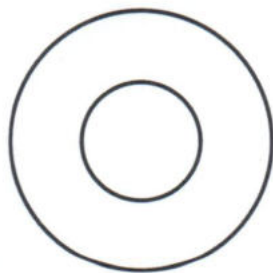
20/20 (6/9)

IOP :

	RIGHT EYE (PH.....)				LEFT EYE (PH.....)			
	Sph.	Cyl.	Axis	V/A	Sph.	Cyl.	Axis	V/A
Distance	<i>Plan</i>			<i>6/9</i>	<i>Plan</i>			<i>6/9</i>
Near	<i>20/20</i>				<i>20/20</i>			

Distance/Reading/Bi-Focal/Progressive/Separate Glasses

Slit :



Handwritten marks and signature

*R
Dr. Tejinder
Eye MD
0000*

Handwritten signature



YASHFEEN CARDIAC HOSPITAL™

At. & Po. Viraval, Navsari. 396 445. Phone (H) (02637) 235725

Website : www.yashfeenhospital.in E-mail : info@yashfeenhospital.in
(For Laboratory Reports Only)



Patient Name : LEELABEN PRANUBHAI PATEL

Age : 50 Years Sex : F

Ref By Dr. : -

Area : Panera

Date : 27/08/2022

Sample Time : 27/08/2022 08:53 No : 20

Time : 2:10PM

GGT TEST REPORT

Test	Findings	UOM	Normal Range
SERUM GGT	42	U/L	10-71 U/L



P. Chaudhri
Dr. PIYUSH B. CHAUDHARI
M. D. Medicine
Reg. No. G-21518

Remarks

Designed By : Sarita Infotech Pvt. Ltd., Navsari

Yashfeen Cardiac Hospital

Thanks for Reference

H. Patel
Signature
Technician



YASHFEEN CARDIAC HOSPITAL™

At. & Po. Viraval, Navsari. 396 445. Phone (H) (02637) 235725

Website : www.yashfeenhospital.in E-mail : info@yashfeenhospital.in
(For Laboratory Reports Only)



Patient Name : LEELABEN PRANUBHAI PATEL

Age : 50 Years Sex : F

Ref By Dr. : -

Area : Panera

Date : 27/08/2022

Sample Time : 27/08/2022 08:52 No : 20

Time : 2:10PM

ROUTINE URINE ANALYSIS

Test	Findings	UOM	Normal Range
<u>PHYSICAL EXAMINATION</u>			
Quantity	-	-	-
Colour	YELLOW	-	-
Appearance	CLEAR	-	-
Reaction	ACIDIC	-	-
Sp. Gravity	1.010	-	-
<u>CHEMICAL EXAMINATION</u>			
U.Albumin	NIL	-	-
Sugar	NIL	-	-
Acetone	NIL	-	-
Bile Salt	NIL	-	-
Bile Pigment	NIL	-	-
Occult Blood	NIL	-	-
<u>MICROSCOPIC EXAMINATION</u>			
Pus Cells	2-3	/hpf	
Epithelial cells	6-5	/hpf	
Red cells	ABSENT	/hpf	
Casts	-	/hpf	
Crystals	AMORPHOUS SEEN	/hpf	
Others	BACTERIA {+} SEEN	/hpf	



P. Chaudhari
Dr. PIYUSH B. CHAUDHARI
M.D. Medicine
Reg. No. G-21518

Remarks

Designed By : Sarita Infotech Pvt. Ltd., Navsari

Yashfeen Cardiac Hospital

H. D. D.
**Signature
Technician**

Thanks for Reference



YASHFEEN CARDIAC HOSPITAL™

At. & Po. Viraval, Navsari. 396 445. Phone (H) (02637) 235725

Website : www.yashfeenhospital.in E-mail : info@yashfeenhospital.in
(For Laboratory Reports Only)



Patient Name : LEELABEN PRANUBHAI PATEL

Age : 50 Years Sex : F

Ref By Dr. : -

Area : Panera Date : 27/08/2022

Sample Time : 27/08/2022 08:52 No : 20

Time : 2:10PM

BIOCHEMICAL TEST REPORT

Test	Findings	UOM	Normal Range
S.CREATININE	0.6	mg/dL	M .0.9-1.4 , F. 0.8-1.2
S.URIC ACID	<u>7.0</u>	mg/dL	Male:3.5-7.2, Female:2.6-6.0
BLOOD UREA NITROGEN	7.1	mg/dL	4.7-23.0



P. Chaudhri
Dr. PIYUSH B. CHAUDHARI
M.D. Medicine
Reg. No. G-21518

Remarks

Designed By : Sarita Infotech Pvt. Ltd., Navsari

Yashfeen Cardiac Hospital

Thanks for Reference

H. Chauhan
Signature
Technician



YASHFEEN CARDIAC HOSPITAL™

At. & Po. Viraval, Navsari. 396 445. Phone (H) (02637) 235725

Website : www.yashfeenhospital.in E-mail : info@yashfeenhospital.in

(For Laboratory Reports Only)



Patient Name : LEELABEN PRANUBHAI PATEL

Age : 50 Years Sex : F

Ref By Dr. : -

Area : Panera Date : 27/08/2022

Sample Time : 27/08/2022 08:52 No : 20

Time : 2:10PM

THYROID FUNCTION TEST REPORT

Test	Findings	UOM	Normal Range
T3 (TRIODOTHYRONINE)	1.26	ng/ml	NEWBORNS:0.73-2.88 6DAYS-3MONTHS:0.80-2.75 4-12MONTHS:0.86-2.65 1-6YEARS:0.92-2.48 7-11YEARS:0.93-2.31 12-20YEARS:0.91-2.18 ADULT:0.80-2.00
T4(THYROXINE)	7.25	µg/dl	NEWBORNS:5.04-18.5, 6DAYS-3MONTHS:5.41-17.0, 4-12 MONTHS:5.67-16.0, 1-6YEARS:5.95-14.7, 7-11 YEARS:5.99-13.8, 12-20 YEARS:5.91-13.2, ADULTS:5.10-14.1
TSH	2.49	µIU/ml	NEWBORNS:0.70-15.2, 6DAYS-3MONTHS:0.72-11.0, 4-12MONTHS:0.73-8.35, 1-6YEARS:0.70-5.97, 7-11YEARS:0.60-4.84, 12-20YEARS:0.51-4.30, ADULTS:0.27-4.20

TECHNIQUE

ELECTROCHEMILUMINESCEN
CE

P. Chaudhari
Dr. PIYUSH B. CHAUDHARI
M.D. Medicine
Reg. No. G-21513

Remarks

Designed By : Santosh Tech Pvt. Ltd., Navsari

Yashfeen Cardiac Hospital

Thanks for Reference

H. Patel
**Signature
Technician**



YASHFEEN CARDIAC HOSPITAL™

At. & Po. Viraval, Navsari. 396 445. Phone (H) (02637) 235725

Website : www.yashfeenhospital.in E-mail : info@yashfeenhospital.in

(For Laboratory Reports Only)



Patient Name : LEELABEN PRANUBHAI PATEL

Age : 50 Years Sex : F

Ref By Dr. : -

Area : Panera Date : 27/08/2022

Sample Time : 27/08/2022 08:52 No : 20

Time : 2:10PM

LIVER FUNCTION TEST REPORT

Test	Findings	UOM	Normal Range
TOTAL BILIRUBIN	0.3	mg/dL	0-1.0
DIRECT BILIRUBIN	0.1	mg/dL	0-0.8
INDIRECT BILIRUBIN	0.2	mg/dL	0-0.2
SGPT	31.0	U/L	Below 40.0
S.ALKALINE PHOSPHATASE	70.2	U/L	CH . 170.0-515.0 A. 37.0-147.0
TOTAL PROTEIN	7.6	g/dl	6.0-8.0
ALBUMIN	4.8	g/dl	3.0-5.0
GLOBULIN	2.8	g/dl	3.0-3.5
A/G	1.7	g/dl	
SGOT	23.6	U/L	Below 40.0



P. Chaudhari
Dr. PIYUSH B. CHAUDHARI
M.D. Medicine
Reg. No. G-21518

Remarks

Designed By : Sarita Infotech Pvt. Ltd., Navsari

Yashfeen Cardiac Hospital

Thanks for Reference

Hrou
Signature
Technician



YASHFEEN CARDIAC HOSPITAL™

At. & Po. Viraval, Navsari. 396 445. Phone (H) (02637) 235725

Website : www.yashfeenhospital.in E-mail : info@yashfeenhospital.in

(For Laboratory Reports Only)



Patient Name : LEELABEN PRANUBHAI PATEL
Ref By Dr. : -
Sample Time : 27/08/2022 08:52 No : 20

Age : 50 Years Sex : F
Area : Panera Date : 27/08/2022
Time : 2:10PM

LIPID PROFILE TEST REPORT

Test	Findings	UOM	Normal Range
S.CHOLESTEROL	241.7	mg/dL	<200:Desirable, 200-239:Borderline High, >=240:High
HDL CHOLESTEROL	48.9	mg/dL	<40:Low(High Risk), >=60:High(Low Risk)
LDL CHOLESTEROL	188.4	mg/dL	<100: Optimal, 100-129: Nearoptimal/ Aboveoptimal, 130-159:BorderlineHigh,16 0-189:High,>=190:Very
VLDL CHOLESTEROL	34.1	mg/dL	UPTO 40
S.TRIGLYCERIDES	170.6	mg/dL	<150:Normal, 150-199:Borderline High,200-499:High, >=500:Very Hi
CHOL/ HDL RATIO	4.9	mg/dL	LESS THAN 5
LDL/ HDL RATIO	3.9	mg/dL	LESS THAN 5



P. Chaudhari
Dr. PIYUSH B. CHAUDHARI
M.D. Medicine
Reg. No. G-21518

Remarks

Designed By : Sarita Infotech Pvt. Ltd., Navsari

Yashfeen Cardiac Hospital

Thanks for Reference

H. Patel

Signature

Technician



YASHFEEN CARDIAC HOSPITAL™

At. & Po. Viraval, Navsari. 396 445. Phone (H) (02637) 235725

Website : www.yashfeenhospital.in E-mail : info@yashfeenhospital.in

(For Laboratory Reports Only)



Patient Name : LEELABEN PRANUBHAI PATEL

Age : 50 Years Sex : F

Ref By Dr. : -

Area : Panera

Date : 27/08/2022

Sample Time : 27/08/2022 08:52 No : 20

Time : 2:10PM

BLOOD SUGAR TEST REPORT

Test	Findings	UOM	Normal Range
FASTING BLOOD SUGAR	113.7	mg/dL	70-110
FASTING URINE SUGAR	NIL	-	NIL
POSTPANDRIAL BLOOD SUGAR	124.9	mg/dL	70-140
POSTPANDRIAL URINE SUGAR	N.R.	-	NIL



P. Chaudhari
Dr. PIYUSH B. CHAUDHARI
M.D. Medicine
Reg. No. G-21518

Remarks

Designed By : Sarita Infotech Pvt. Ltd., Navsari

Yashfeen Cardiac Hospital

Thanks for Reference

Signature
**Signature
Technician**



YASHFEEN CARDIAC HOSPITAL™

At. & Po. Viraval, Navsari. 396 445. Phone (H) (02637) 235725

Website : www.yashfeenhospital.in E-mail : info@yashfeenhospital.in

(For Laboratory Reports Only)



Patient Name : LEELABEN PRANUBHAI PATEL

Age : 50 Years Sex : F

Ref By Dr. : -

Area : Panera

Date : 27/08/2022

Sample Time : 27/08/2022 08:47 No : 20

Time : 2:10PM

HAEMOGLOBIN A1 C ESTIMATION

Test	Findings	UOM	Normal Range
Hb A1C	6.7	%	>8 : Action Suggested, 7-8 : Good Control, <7 : Goal, 6-7 : Near Normal Glycemia, <6 : Non-diabetic Level
Technique METHOD - HPLC			
Mean Blood Glucose	146.0	mg/dL	



P. Chaudhari
Dr. PIYUSH B. CHAUDHARI
M.D. Medicine
Reg. No. G-21518

Remarks

Designed By : Sarita Infotech Pvt. Ltd., Navsari

Yashfeen Cardiac Hospital

Thanks for Reference

Hrou
signature
Technician



YASHFEEN CARDIAC HOSPITAL™

At. & Po. Viraval, Navsari. 396 445. Phone (H) (02637) 235725

Website : www.yashfeenhospital.in E-mail : info@yashfeenhospital.in

(For Laboratory Reports Only)



Patient Name : LEELABEN PRANUBHAI PATEL

Age : 50 Years Sex : F

Ref By Dr. : -

Area : Panera

Date : 27/08/2022

Sample Time : 27/08/2022 08:47 No : 20

Time : 2:10PM

BLOOD GROUP TEST REPORT

Test	Findings	UOM	Normal Range
BLOOD GROUP	"A"	-	-
RH FACTOR	POSITIVE	-	-



P. Chaudhari
Dr. PIYUSH B. CHAUDHARI
M.D. Medicine
Reg. No. G-21518

Remarks

Designed By : Sarita Infotech Pvt. Ltd., Navsari

Yashfeen Cardiac Hospital

Thanks for Reference

H. Patel
Signature
Technician



YASHFEEN CARDIAC HOSPITAL™

At. & Po. Viraval, Navsari. 396 445. Phone (H) (02637) 235725

Website : www.yashfeenhospital.in E-mail : info@yashfeenhospital.in
(For Laboratory Reports Only)



Patient Name : LEELABEN PRANUBHAI PATEL

Age : 50 Years Sex : F

Ref By Dr. : -

Area : Panera

Date : 27/08/2022

Sample Time : 27/08/2022 08:47 No : 20

Time : 2:09PM

HAEMOGRAM REPORT

Test	Findings	UOM	Normal Range
HAEMOGLOBIN	11.8	gm/dl	M-13.5-17.0 F-11.5-15.5
HAEMOGRAM			
RED BLOOD CELL	5.35	10 ⁶ /μL	3.76 - 5.70
TOTAL LEUCOCYTE COUNT	7200	cells/cumm	4,000-11,000
Differential Count			
Neutrophil	47	%	40-75
Lymphocytes	48	%	20-40
Eosinophil	2	%	1-6
Monocytes	3	%	2-10
Basophils	0	%	0-0
PLATELET COUNT	259000	lacs/cumm	1.5-5.5 Lacs
RBC INDICES			
P.C.V.	37.5	%	M-40-56% F-37-47%
M.C.V.	70.1	cu/microns	76-94
M.C.H.	22.0	pg	27-30
M.C.H.C.	31.4	-	30-35
E.S.R.(1 hour)	14	mm/hr.	M-5-10, F-5-20



P. Chaudhri
Dr. P. MUSH B. CHAUDHARI
M.D. Medicine
Reg. No. G-21518

Remarks

Designed By : Sarita Infotech Pvt. Ltd., Navsari

Yashfeen Cardiac Hospital

Hrou
Signature

Thanks for Reference

Technician

YASHFEEN IMAGING & RADIOLOGY DEPARTMENT

MANAGED BY :- YASHFEEN FOUNDATION

VIRAVAL, NAVSARI. 396 445. PHONE : (H) (02637) 235725

Website : www.yashfeenhospital.in E-mail : info@yashfeenhospital.in

Patient's Name:	LEELABEN P. PATEL	Age & Sex:	50Yrs/F
Ref. by Dr.	SELF	Date:	27-08-2022

X RAY CHEST (PA VIEW)

Both lung fields appear normal.

Both hila appear normal.

Both CP angles appear clear.

Cardiac size appears within normal limit.

Both domes of diaphragm appear normal.

Bony thoracic cage appears normal.

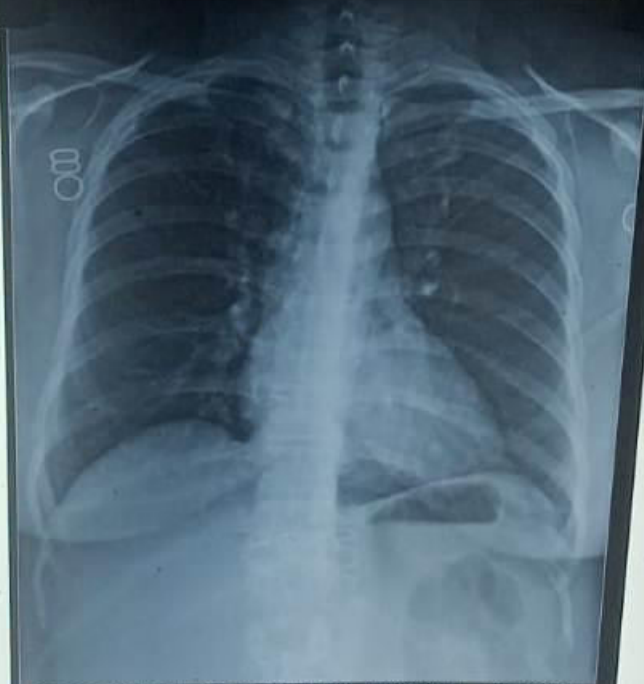IMPRESSION:

- Normal X-ray chest (PA view).




Dr. Dharmesh Desai
D.r. **DHARMESH DESAI**
(M.D. Radiology)
Reg. No. G - 45284

This is only a professional opinion, not a final diagnosis. Kindly correlate clinically. Not valid for medicolegal purpose.



CH22020481 LEELABEN P. PATEL 50Y 2708221871 CHEST PA
YASHFEEN GROUP OF HOSPITALS NAVSARI PH:9924047789