



A.L.C. Advance Imaging Dignostics

ISO 9001:2015 Certified center

(A Unit of Subham Imaging P.K. Arogyam Health & Wellness Center)

E-95, P.C. Colony, Near Sai Netryalaya Transformer, Kankarbagh, Patna - 20

alcdiagnostics@gmail.com

www.pkrogyamhealthcheckup.com

7050037694, 8271206196

OPINION MUST BE CORRELATES WITH CLINICALLY & OTHER INVESTIGATION FOR FINAL DIAGNOSIS. NOT FOR MEDICO LEGAL PURPOSE

ATIENT NAME : Mr. AJEET KR CHOUDHARY

PATIENT ID: 2643

COL DATE : 10/12/2022 REPORTING DATE: 10/12/2022 AGE SEX:- 48 YRS/M

REF.BY : DR. / MEDIWHEEL.

TEST NAME	RESULT	Unit	REF.RANGE
ESR	18 mm/hr		<20 mm/hr
CBC			
Total W.B.C. Count	5,400 /cumm		4000-11,000 /cumm
R B C COUNT	4.59 Million/ CUmm		4 - 7 Million/ CUmm
Platelets count	1.76 Lakh/ cumm		1.5-5.0 Lakh/ cumm
Differential Count of W.B.C.			
Neutrophils	66 %		40-70%
Lymphocytes	27 %		25-40%
Eosinophils	06 %		01-05%
Mnonocytes	01 %		00-02%
Basophiles	00 %		00-0%
HAEMOGLOBIN	15.4 gm/dl (105.4 %)		14.6 gm/dl = 100%
PCV	43.1 %		35-47 %
MCV	93.8 fl		76-96 fl
MCH	30.5 pg		29-35 pg
MCHC	34.7 %		30-38 %



Dr. A.K. Singh
10/12/22

ESTB BY:-

Dr. P. K. Tiwari
MD, M.Sc (Radio Imaging)
Ph.D (Air Nuclear Medicine)
Consultant Imagonologist & Sonologist

Dr. S. Kumar
MD (Pat)
Consultant Pathologist

Dr. Abhishek Kumar
MBBS, MD
Consultant Neuropatho Physiologist

Dr. Kumari Suman
MBBS, DGO, MD
Consultant (TVS & HSG Specialist)

Dr. A. K. Singh
MBBS, PGDMCH
Consultant Radiologist & Sonologist

Consultant Radiologist

PRINTING MISTAKE SHOULD BE REPORTED BACK IMMEDIATELY/ यहाँ जन्म से पहले भुण का लिंग जाँच नहीं होता है ।



A.L.C. Advance Imaging Diagnostics

ISO 9001 2015 Certified center

(A Unit of Subham Imaging P.K. Arogyam Health & Wellness Center)

E-95, P.C. Colony, Near Sai Netryalaya Transformer, Kankarbagh, Patna - 20

alcdiagnostics@gmail.com

www.pkarogyamhealthcheckup.com

7050037694 8271206196

OPINION MUST BE CORRELATES WITH CLINICALLY & OTHER INVESTIGATION FOR FINAL DIAGNOSIS. NOT FOR MEDICO LEGAL PURPOSE

PATIENT NAME : Mr. AJEET KR CHOUDHARY PATIENT ID: 2643
COL DATE : 10/12/2022 REPORTING DATE: 10/12/2022 AGE SEX:- 48 YRS/M
REF.BY : DR. / MEDIWHEEL.

TEST NAME	RESULT	Unit	REF.RANGE
-----------	--------	------	-----------

BLOOD GROUP	:	' B '	
Rh Typing	:	POSITIVE	

Note: Do always cross – matching before blood transfusion



10/12/22
Consultant Radiologist

ESTB BY:-
Dr. P. K. Tiwari MD, M.Sc (Radio Imaging) Ph.D (AI) Nuclear Medicine Consultant Imaginologist & Sonologist
Dr. S. Kumar MD (Pat) Consultant Pathologist
Dr. Abhishek Kumar MBBS, MD Consultant Neuropatho Physiologist
Dr. Kumari Suman MBBS, DGO, MD Consultant (TVS & HSG Specialist)
Dr. A. K. Singh MBBS, PGDMCH Consultant Radiologist & Sonologist

PRINTING MISTAKE SHOULD BE REPORTED BACK IMMEDIATELY/ यहाँ जन्म से पहले भ्रुण का लिंग जाँच नहीं होता है ।



A.L.C. Advance Imaging Dignostics

ISO 9001:2015 Certified center

(A Unit of Subham Imaging P.K. Arogyam Health & Wellness Center)

E-95, P.C. Colony, Near Sai Netryalaya Transformer, Kankarbagh, Patna - 20

alcdiagnostics@gmail.com

www.pkarogayamhealthcheckup.com

7050037694, 8271206196

OPINION MUST BE CORRELATES WITH CLINICALLY & OTHER INVESTIGATION FOR FINAL DIAGNOSIS. NOT FOR MEDICO LEGAL PURPOSE

PATIENT NAME : Mr. AJEET KR CHOUDHARY

PATIENT ID: 2643


COL DATE : 10/12/2022 REPORTING DATE: 10/12/2022 AGE SEX : 48 YRS/M

REF.BY : DR./ MEDIWHEEL.

GLYCOSYLATED HEMOGLOBIN

TEST NAME	RESULT	Unit	REF.RANGE
HbA1c	4.6 %		Below 5.7 % : Normal 5.7 – 6.4 % : Prediabetic > = 6.5 % : Diabetic
AVERAGE PLASMA GLUCOSE	99.0 mg/dl		90 – 120 mg/dl : Good Control 121– 150 mg/dl : Fair Control 151- 180 mg/dl: Unsatisfactory Control >180 mg/dl : Poor Control




Consultant Radiologist

ESTB BY:-
Dr. P. K. Tiwari MD, M.Sc (Radio Imaging) Ph.D (Alt Nuclear Medicine) Consultant Imaginologist & Sonologist
Dr. S. Kumar MD (Pat) Consultant Pathologist
Dr. Abhishek Kumar MBBS, MD Consultant Neuropatho Physiologist
Dr. Kumari Suman MBBS, DGO, MD Consultant (TVS & HSG Specialist)
Dr. A. K. Singh MBBS, PGDMCH Consultant Radiologist & Sonologist

PRINTING MISTAKE SHOULD BE REPORTED BACK IMMEDIATELY/ यहाँ जन्म से पहले भुण का लिंग जाँच नहीं होता है ।



A.L.C. Advance Imaging Dignostics

ISO 9001:2015 Certified center

(A Unit of Subham Imaging P.K. Arogyam Health & Wellness Center)

E-95, P.C. Colony, Near Sai Netryalaya Transformer, Kankarbagh, Patna - 20

alcdiagnostics@gmail.com

www.pkarogyamhealthcheckup.com

7050037694, 8271206196

OPINION MUST BE CORRELATES WITH CLINICALLY & OTHER INVESTIGATION FOR FINAL DIAGNOSIS. NOT FOR MEDICO LEGAL PURPOSE

PATIENT NAME : Mr. AJEET KR CHOUDHARY

PATIENT ID: 2643

COL DATE : 10/12/2022 REPORTING DATE: 10/12/2022 AGE SEX:- 48 YRS/M

REF.BY : DR./ MEDIWHEEL..

TEST NAME	RESULT	Unit	REF.RANGE
LFT:-			
SGPT	46.0	IU/L	5 - 48 IU/L
SGOT	30.6	IU/L	5 - 40 IU/L
ALKALINE PHOSPHATASE	91.9	IU/L	25 - 147 IU/L
TOTAL PROTIN	7.8	g/dl	6.0 - 8.7 g/dl
SERUM ALBUMIN	4.7	g/dl	3.5 - 5.4 g/dl
SERIUM GLUBLINE	3.1	g/dl	2.3 - 3.6 g/dl
AG RATIO	1.5 : 1		1.0 - 2.3 g/dl
BILIRUBIN			
TOTAL	0.62	mg/dl	0.1 - 1.1 mg/dl
IRECT	0.23	mg/dl	0.0 - 0.32 mg/dl
INDIRECT	0.39	mg/dl	0.0 - 0.78 mg/dl
GGTP (GGT)	24.0	iu/L	8 - 38 iu/L
KFT/RFT			
URIC ACID	4.9	mg/dl	3.2 - 7.0 mg/dl
SERUM CREATNINE	1.0	mg/dl	0.6 - 1.5 mg/dl
BLOOD URIA	29.9	mg/dl	5 - 45 mg/dl
BLOOD URIA NITROZEN(BUN).	13.9	mg/dl	5 - 24 mg/dl



AK
10/12/22

Consultant Radiologist

ESTB BY:-

Dr. P. K. Tiwari
MD, M.Sc (Radio Imaging)
Ph.D (Ab Nuclear Medicine)
Consultant Imagonologist & Sonologist

Dr. S. Kumar
MD (Pat)
Consultant Pathologist

Dr. Abhishek Kumar
MBBS, MD
Consultant Neuropatho Physiologist

Dr. Kumari Suman
MBBS, DGO, MD
Consultant (TVS & HSG Specialist)

Dr. A. K. Singh
MBBS, PGDMCH
Consultant Radiologist & Sonologist

PRINTING MISTAKE SHOULD BE REPORTED BACK IMMEDIATELY/ यहाँ जन्म से पहले भ्रुण का लिंग जाँच नहीं होता है ।



A.L.C. Advance Imaging Diagnostics

ISO 9001:2015 Certified center

(A Unit of Subham Imaging P.K. Arogyam Health & Wellness Center)

E-95, P.C. Colony, Near Sai Netryalaya Transformer, Kankarbagh, Patna - 20

alcdiagnostics@gmail.com

www.pkarogayamhealthcheckup.com

7050037694, 8271206196

OPINION MUST BE CORRELATES WITH CLINICALLY & OTHER INVESTIGATION FOR FINAL DIAGNOSIS. NOT FOR MEDICO LEGAL PURPOSE

PATIENT NAME : Mr. AJEET KR CHOUDHARY PATIENT ID: 2643
COL DATE : 10/12/2022 REPORTING DATE: 10/12/2022 AGE SEX : 48 YRS/M
REF.BY : DR. / MEDIWHEEL..

TEST NAME	RESULT	Unit	REF.RANGE
Total Triiodothyronin T3	1.78	ng/mL	0.80 -2.00 ng/mL
Total Thyroxin T4	9.24	µg/dL	5.10 -14.10 µg/dL
Serum TSH	3.02	µIU/mL	0.27 – 4.20 µIU/mL

THYROID DISORDER (>: Increase: < Decrease: n Normal

1. T3(n) T4(n) TSH(n) :EUTHYROID STATE:
2. T3(>) T4(>) TSH(<): HYPERTHYROIDISM:
3. T3(<)T4(<) TSH(>): HYPOTHYROIDISM:
4. T3(n)T4(n) TSH(>) : SUB-CLINICAL HYPO-THYROIDISM:
5. T3(n)T4(n) TSH(<): SUB-CLINICAL HYPER-THYROIDISM:
6. T3(>) T4(n) TSH(<): T3 THYROTOXICOSIS:

Total T3/T4 level is dependent on Level:

So determination of free T3/T4is a better MARKER of Thyroid Function.



10/12/22
Consultant Radiologist

ESTD BY:-

Dr. P. K. Tiwari
MD, M.Sc (Radio Imaging)
Ph.D (Ab Nuclear Medicine)
Consultant Imaginologist & Sonologist

Dr. S. Kumar
MD (Pat)
Consultant Pathologist

Dr. Abhishek Kumar
MBBS, MD
Consultant Neuropathology Physiologist

Dr. Kumari Suman
MBBS, DGO, MD
Consultant (TVS & HSG Specialist)

Dr. A. K. Singh
MBBS, PGDMCH
Consultant Radiologist & Sonologist

PRINTING MISTAKE SHOULD BE REPORTED BACK IMMEDIATELY/ यहाँ जन्म से पहले भ्रुण का लिंग जाँच नहीं होता है ।



A.L.C. Advance Imaging Dignostics

ISO 9001:2015 Certified center

(A Unit of Subham Imaging P.K. Arogyam Health & Wellness Center)

E-95, P.C. Colony, Near Sai Netryalaya Transformer, Kankarbagh, Patna - 20

alcdiagnosics@gmail.com

www.pkarogyamhealthcheckup.com

7050037694, 8271206196

OPINION MUST BE CORRELATES WITH CLINICALLY & OTHER INVESTIGATION FOR FINAL DIAGNOSIS. NOT FOR MEDICO LEGAL PURPOSE

PATIENT NAME : Mr . AJEET KR CHOUDHARY

PATIENT ID: 2643

COL DATE : 10/12/2022 REPORTING DATE: 10/12/2022 AGE SEX:- 48 YRS/M

REF.BY : DR. /MEDIWHEEL.

ROUTINE EXAMINATION OF URINE

PHYSICAL EXAMINATION

Quantity	30 ml	Colour... .	Straw
Appearance...	Clear	Sediment ...	Nil
Specific gravity....	1.010		

CHEMICAL EXAMINATION

Reaction	6.0	Nitrite.....	Not done
Sugar	Nil	Bile Pigment	Not done
Albumin	Nil	Urobilinogen....	Not done
Excess of Phosphate....	Nil	Chile.....	Not done
Bile Salt	Not Done	Acetone...	Not done

MICROSCOPIC EXAMINATION

Erythrocytes....	Nil	Casts	Nil
Leucocytes	1-5/ HPE	Crystals....	Nil
Epith. Cell	A, Few	Others	Nil

ESTB BY:-

Dr. P. K. Tiwari
MD, M.Sc (Radio Imaging)
Ph.D (Ait Nuclear Medicine)
Consultant Imaginologist & Sonologist

Dr. S. Kumar
MD (Pat)
Consultant Pathologist

Dr. Abhishek Kumar
MBBS, MD
Consultant Neuropathology & Physiologist

Dr. Kumari Suman
MBBS, DGO, MD
Consultant (TVS & HSG Specialist)

Dr. A. K. Singh
MBBS, PGDMCH
Consultant Radiologist & Sonologist



Handwritten signature and date: 10/12/22

Consultant Radiologist

PRINTING MISTAKE SHOULD BE REPORTED BACK IMMEDIATELY/ यहाँ जन्म से पहले भ्रूण का लिंग जाँच नहीं होता है ।



A.L.C. Advance Imaging Diagnostics

ISO 9001:2015 Certified center

(A Unit of Subham Imaging P.K. Arogyam Health & Wellness Center)

E-95, P.C. Colony, Near Sai Netryalaya Transformer, Kankarbagh, Patna - 20

alcdiagnostics@gmail.com

www.pkarogayamhealthcheckup.com

7050037694, 8271206196

OPINION MUST BE CORRELATES WITH CLINICALLY & OTHER INVESTIGATION FOR FINAL DIAGNOSIS. NOT FOR MEDICO LEGAL PURPOSE

PATIENT NAME : Mr. AJEET KR CHOUDHARY

PATIENT ID: 2643

COL DATE : 10/12/2022 REPORTING DATE: 10/12/2022 AGE SEX : 48 YRS/M

REF.BY : DR. /MEDIWHEEL.

TEST NAME	RESULT	Unit	REF.RANGE
BLOOD SUGAR (F)	82.0 mg/dl		70 - 110 mg/dl

LIPID PROFILE:-

TOTAL CHOLESTROL	159.0 mg/dl		130 -250 mg/dl
TRIGLYCERIDE	162.5 mg/dl		50 -160 mg/dl
HDL CHOLESTROL	40.0 mg/dl		30 - 60 mg/dl
LDL CHOLESTROL	86.5 mg/dl		80 -130 mg/dl
VLDL CHOLESTROL	32.5 mg/dl		15 - 40 mg/dl
T.CH./HDL RATIO	3.9 : 1		Upto 5:1
LDL./HDL RATIO	2.1 : 1		2 - 4:1



10/12/22

Consultant Radiologist

ESTB BY:-

Dr. P. K. Tiwari
MD, M.Sc (Radio Imaging)
Ph.D (AIr Nuclear Medicine)
Consultant Imagonologist & Sonologist

Dr. S. Kumar
MD (Pat)
Consultant Pathologist

Dr. Abhishek Kumar
MBBS, MD
Consultant Neuropatho Physiologist

Dr. Kumari Suman
MBBS, DGO, MD
Consultant (TVS & HSG Specialist)

Dr. A. K. Singh
MBBS, PGDMCH
Consultant Radiologist & Sonologist

PRINTING MISTAKE SHOULD BE REPORTED BACK IMMEDIATELY/ यहाँ जन्म से पहले भुण का लिंग जाँच नहीं होता है ।

ID: 2643 CASE:

AJEET KR CHOUDHARY

10/12/2022 11:36:34

AGE: 48Y 0M 0D

MALE

ALC ADVANCE IMAGING DIAGNOSTICS
E95 PC COLONY KANKARBAGH PATNA

Cms Kg

RATE : 52 bpm SINUS RHYTHM
 R-R : 1147 ms LEAD(S) UNSUITABLE FOR ANALYSIS: V1
 P-R : 156 ms
 QRS : 88 ms
 QT : 414 ms
 QTc : 400 ms



--AXIS--

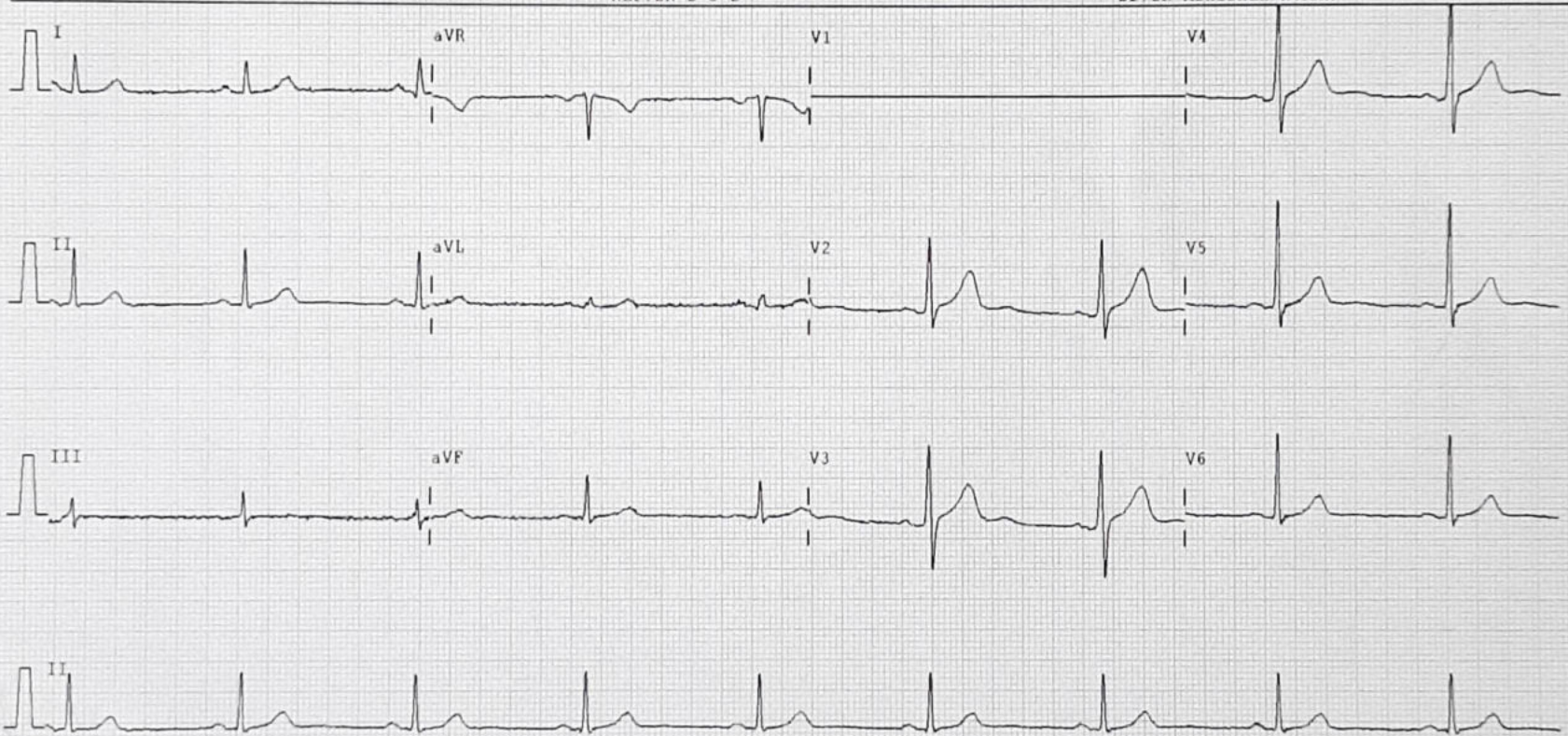
P : 21°
 QRS : 48°
 T : 34°

NORMAL ECG BASED ON AVAILABLE LEADS

12 SL: REPORT FORMAT: 3x4+1L SQ

REF: DR B O B

Dr. DR ABHISHEK KUMAR





A.L.C. Advance Imaging Diagnostics

ISO 9001:2015 Certified center

(A Unit of Subham Imaging P.K. Arogyam Health & Wellness Center)

E-95, P.C. Colony, Near Sai Netryalaya Transformer, Kankarbagh, Patna - 20

alcdiagnostics@gmail.com

www.pkarogayamhealthcheckup.com

7050037694, 8271206196

OPINION MUST BE CORRELATES WITH CLINICALLY & OTHER INVESTIGATION FOR FINAL DIAGNOSIS. NOT FOR MEDICO LEGAL PURPOSE

ECHOCARDIOGRAPHY & COLOR DOPPLER REPORT

Patient's Name : Mr.AJEET KUMAR

Age/Sex : 48 Yrs /M

Ref. by : DR./ MEEDIWHEEL

Date : 11-Dec-22

ECHOCARDIOGRAPHIC WINDOW: Fair

2D & M MODE ECHOCARDIOGRAPHY

Left ventricle

EDD:	30	mm (20 - 28 mm / m ²)	ESD:	21	mm(13 - 21 mm /m ²)
IVS :	11	mm (6 - 11 mm)	PW:	8	mm (6 -11 mm)
Ejection fraction:	60% (61 ± 8%)		FS:	35	% (34 - 44 %)
IVS:	Intact		LV clot	Absent	

Left atrium/ Aorta 35/31 mm

Right ventricle Normal

Right atrium Normal

Pericardium Normal with no pericardial effusion

2D:

Normal LA/LV Size and normally contracting left ventricle. No RWMA, concentric LVH

Mitral valve

AML/ PML: Normal

Tricuspid valve Normal

Aortic valve Normal

Pulmonary valve Normal

Continuous & Pulse Wave Doppler study

Valve	Velocity (m/sec)			Gradient (mmHg)			Valve area (PHT Method)	Regurg.
	Peak	Mean	EDV	Peak	Mean	EDG		
Mitral	E=07 A=0.6			2.3	2.0			Nil
Tricuspid	E=0.5 A=0.3			1.9	0.2			Nil
Aortic	1.12			5.0	2.5			Nil
Pulmonary	0.9			3.5	1.7			Nil

ESTB BY:-

Dr. P. K. Tiwari

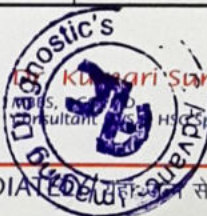MD, M.Sc (Radio Imaging)
Ph.D (AI Nuclear Medicine)
Consultant Imagiologist & Sonologist

Dr. S. Kumar

MD (Pat)
Consultant Pathologist

Dr. Abhishek Kumar

MBBS, MD
Consultant Neuropatho Physiologist



Dr. K. Suman

MBBS, MD
Consultant Radiologist & HSG Specialist

Consultant Radiologist

Dr. A. K. Singh

MBBS, PGDMCH
Consultant Radiologist & Sonologist

PRINTING MISTAKE SHOULD BE REPORTED BACK IMMEDIATELY. (पहले भ्रुण का लिंग जाँच नहीं होता है ।)

A.L.C. Advance Imaging Dignostics

ISO 9001:2015 Certified center

(A Unit of Subham Imaging P.K. Arogyam Health & Wellness Center)

E-95, P.C. Colony, Near Sai Netryalaya Transformer, Kankarbagh, Patna - 20

alcdiagnostics@gmail.com

www.pkarogayamhealthcheckup.com

7050037694, 8271206196

OPINION MUST BE CORRELATES WITH CLINICALLY & OTHER INVESTIGATION FOR FINAL DIAGNOSIS. NOT FOR MEDICO LEGAL PURPOSE

Colour Flow Imaging

No TR, No MR/PR, No AR

No flow shunt

COMMENTS :

- ◆ Normal size all chamber
- ◆ Normal LV filling Pressure
- ◆ No RWMA
- ◆ Normal LV systolic function
- ◆ Grade I LV diastolic dysfunction.
- ◆ Global LVEF = 60%
- ◆ All cardiac valves are normal
- ◆ No PAH, Mild concentric LVH
- ◆ No MS / TS / AS / PS / PR
- ◆ No clot / vegetation / pericardial effusion.

IMPRESSION:

All chambers are normal

No RWMA, No PAH

Grade I LV diastolic dysfunction.

Normal LV systolic function, LVEF – 65%

Please correlate clinically

DR. SANDEEP KUMAR MBBS MD



ESTB BY:-

Dr. P. K. Tiwari
MD, M.Sc (Radio Imaging)
Ph.D (All Nuclear Medicine)
Consultant Imagonologist & Sonologist

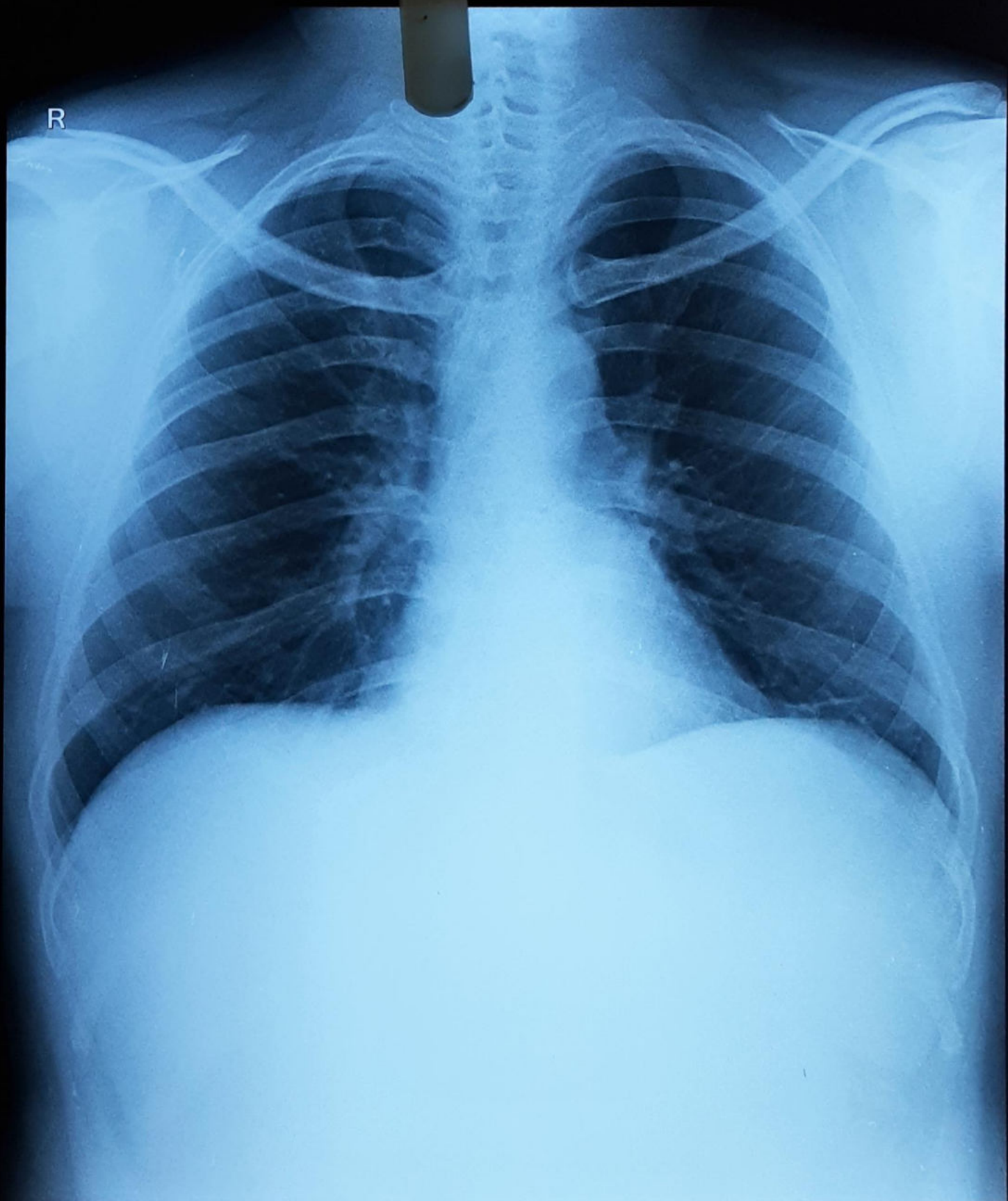
Dr. S. Kumar
MD (Pat)
Consultant Pathologist

Dr. Abhishek Kumar
MBBS, MD
Consultant Neuropatho Physiologist

Dr. Kumari Suman
MBBS, DGO, MD
Consultant (TVS & HSG Specialist)

Consultant Radiologist

Dr. A. K. Singh
MBBS, PGDMCH
Consultant Radiologist & Sonologist



AJEET KR CHOUDHARY AGE 48 YEARS 2643 DR B O B CHEST,FRN P->A 12/09/2022

A.L.C. Advance Imaging Diagnostics Centre PATNA - 20



A.L.C. Advance Imaging Dignostics

ISO 9001:2015 Certified center

(A Unit of Subham Imaging P.K. Arogyam Health & Wellness Center)

E-95, P.C. Colony, Near Sai Netryalaya Transformer, Kankarbagh, Patna - 20

alcdiagnostics@gmail.com

www.pkarogayamhealthcheckup.com

7050037694, 8271206196

OPINION MUST BE CORRELATES WITH CLINICALLY & OTHER INVESTIGATION FOR FINAL DIAGNOSIS. NOT FOR MEDICO LEGAL PURPOSE

Pt. Name :- **AJEET KUMAR CHOUDHARY**

Date:- **11-Dec-22**

Ref. By :- **DR / MEEDIWHEEL**

Age / Sex – **48 Yrs. M.**

Thanks for your kind referral

X-RAYCHEST (P.A.VIEW)

The lungs on the either side show equal translucency.

The peripheral pulmonary vasculature is normal.

No focal lung lesion is seen.

The pleural spaces are normal.

Both hila are normal in size, have equal density and bear normal relationship.

The heart and trachea are central in position and no mediastinal abnormality is visible.

The cardiac size is normal.

The domes of the diaphragms are normal in position, and show smooth outline.

IMPRESSION

- NO EVIDENCE OF PULMONARY OR CARDIAC PATHOLOGY IS NOTED.



Consultant Radiologist

ESTB BY:-

Dr. P. K. Tiwari

MD, M.Sc (Radio Imaging)

Ph.D (All Nuclear Medicine)

Consultant Imagingologist & Sonologist

Dr. S. Kumar

MD (Pat)

Consultant Pathologist

Dr. Abhishek Kumar

MBBS, MD

Consultant Neuropatho Physiologist

Dr. Kumari Suman

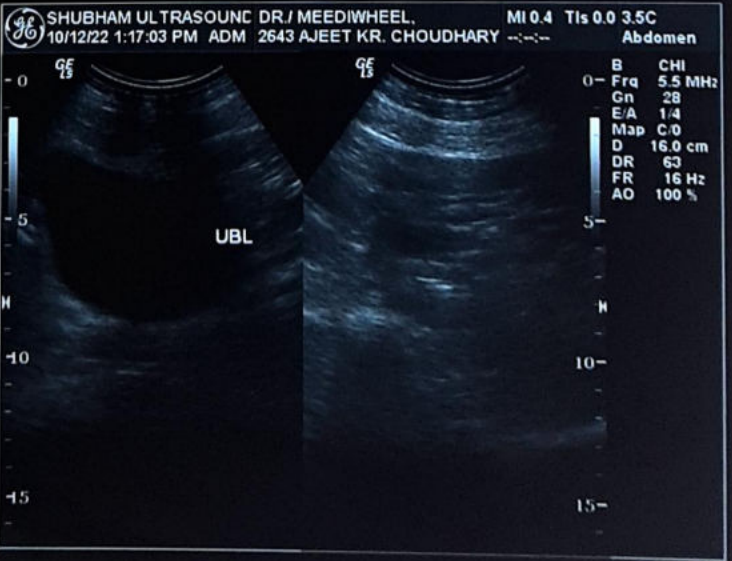
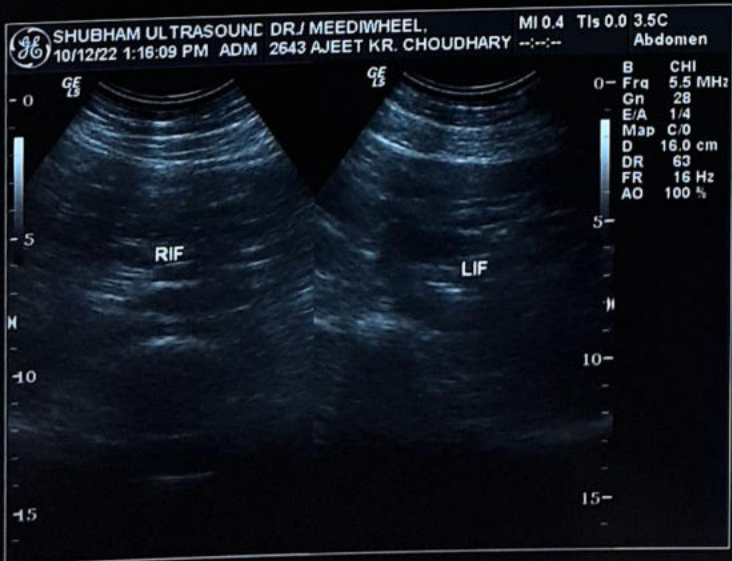
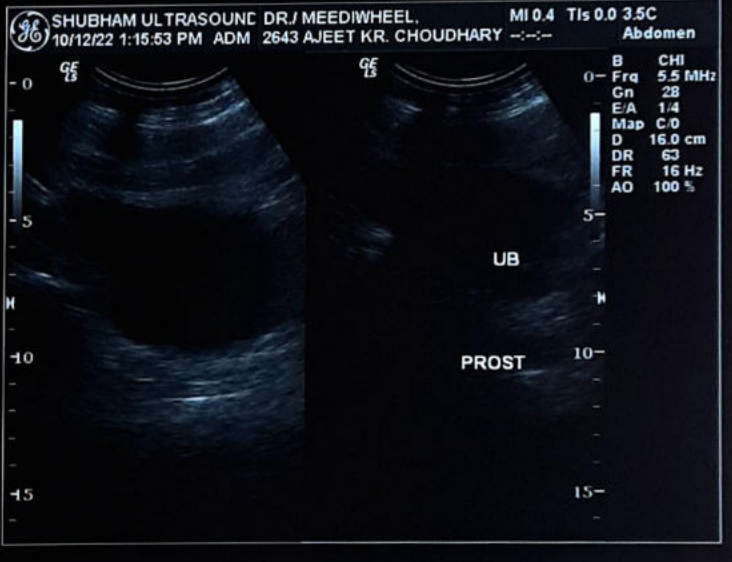
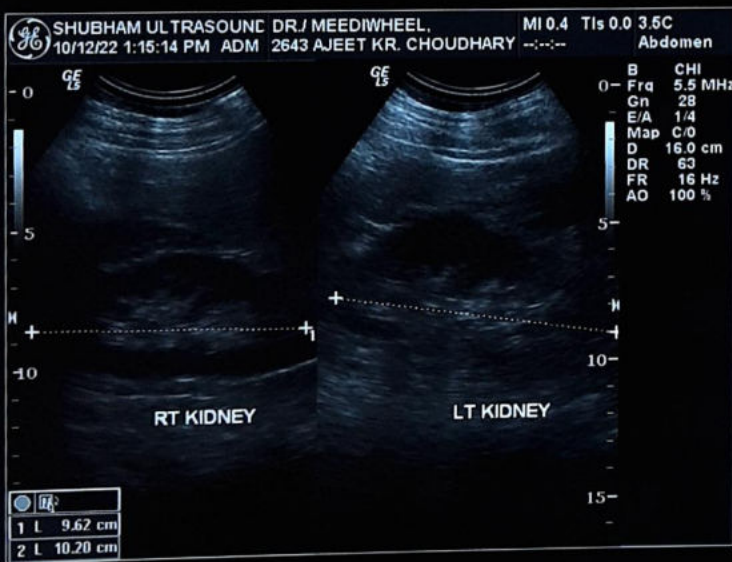
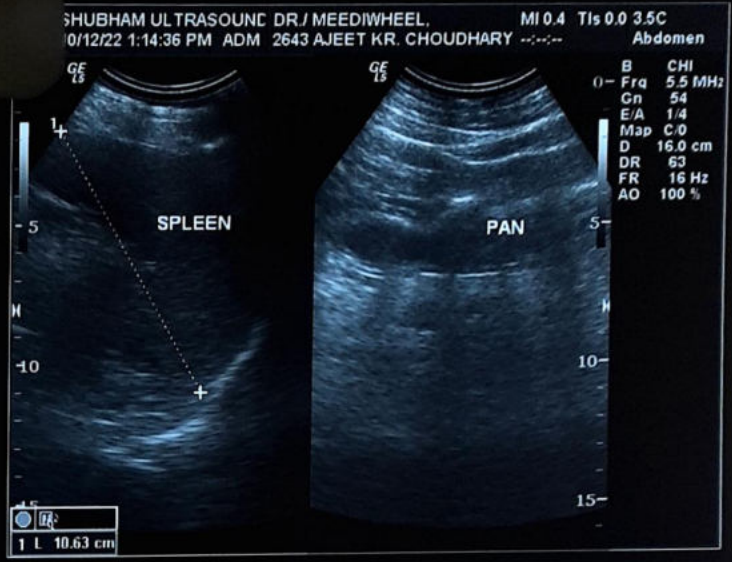
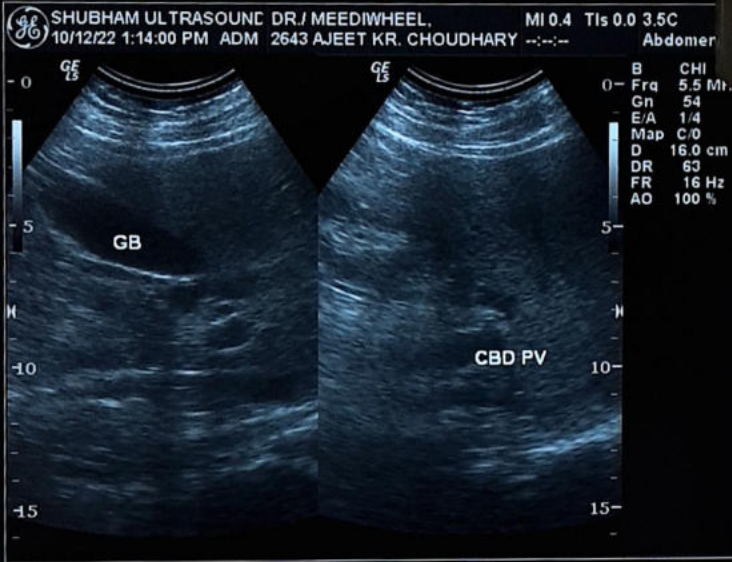
MBBS, DGO, MD

Consultant (TVS & HSG Specialist)

Dr. A. K. Singh

MBBS, PGDMCH

Consultant Radiologist & Sonologist





A.L.C. Advance Imaging Dignostics

ISO 9001:2015 Certified center

(A Unit of Subham Imaging P.K. Arogyam Health & Wellness Center)

E-95, P.C. Colony, Near Sai Netryalaya Transformer, Kankarbagh, Patna - 20

alcdiagnostics@gmail.com

www.pkarogayamhealthcheckup.com

7050037694, 8271206196

OPINION MUST BE CORRELATES WITH CLINICALLY & OTHER INVESTIGATION FOR FINAL DIAGNOSIS. NOT FOR MEDICO LEGAL PURPOSE

Pt. Name :- **AJEET KR. CHOUDHARY**

Date:- **10-Dec-22**

Ref. By :- **DR ./MEEDIWHEEL**

Age / Sex – **48 Yrs. M.**

REAL TIME U.S.G. OF WHOLE ABDOMEN

Thanks for your kind referral

(Report.)

LIVER :- Measures 14.13 cm. Mild Enlarged in shape , size and echo texture fatty change seen in liver parenchyma .I.H.B.R. are not dilated.

Hepatic veins are normal. No SOL seen.

G.BL. :- Lumen is echo free. Wall thickness appears normal.

C.B.D. :- Measures 3.4 mm in diameter with echo free lumen. No calculi or mass seen.

P.V. :- Measures 7.6 mm in diameter. Appears normal. No thrombus seen.

PANCREAS :- Normal in shape, size and echo texture. No calcification mass seen.

SPLEEN :- Measures 10.63 cm. Normal in shape, size and echo texture.
No SOL seen.

KIDNEY :- Both kidney shows normal shape, size & echotexture. C.M.D.intact.
P.C.S.is not dilated. No calculi, cyst or hydronephrosis seen on either side.

Right Kidney :- Measures 9.62 X 4.50 cm.

Left Kidney :- Measures 10.20 X 4.70 cm.

URETER :- Not dilated .No apparent calculi seen.

U.BLADDER:- Shows normal in outline with echo free lumen. No calculi or mass seen.

Pre void –260 ml. Post void – is in significant

PROSTATE :- Measures 22 gms.(approx). Appears Normal in size, shape, and echo texture.
No calcification , mass ,growth seen. capsule is intact.

R.I.F. :- Son graphically no appendicular mass or collection seen.

OTHERS :- No Ascites . no Lymph Adenopathy. No pleural effusion seen on either side .

IMPRESSION

- **Mild Hepatomegaly With fatty liver G-I**
- **Adv:- Further work up/ other investigation**
Otherwise son graphically normal scan. of rest organs



10/12/22

ESTB BY:-

Consultant Radiologist

Dr. P. K. Tiwari

MD, M.Sc (Radio Imaging)
Ph.D (Altr Nuclear Medicine)
Consultant Imagiologist & Sonologist

Dr. S. Kumar

MD (Pat)
Consultant Pathologist

Dr. Abhishek Kumar

MBBS, MD
Consultant Neuropathology Physiologist

Dr. Kumari Suman

MBBS, DGO, MD
Consultant (TVS & HSG Specialist)

Dr. A. K. Singh

MBBS, PGDMCH
Consultant Radiologist & Sonologist

PRINTING MISTAKE SHOULD BE REPORTED BACK IMMEDIATELY/ यहाँ जन्म से पहले भ्रुण का लिंग जाँच नहीं होता है ।