


भारत सरकार
Government of India



 असमा
 Asma
 जन्म तिथि / DOB : 11/09/1991
 महिला / Female



2443 3578 1636

आधार - आम आदमी का अधिकार


Asma



भारतीय विशिष्ट पहचान प्राधिकरण
Unique Identification Authority of India


पता:
 आत्मजा: नसीम अहमद, 522/2,
 रामपुर रोड, सपना टाकीज के सामने,
 रुडकी, हरिद्वार, रुडकी, उत्तराखंड,
 247667

Address:
 D/O: Naseem Ahmed, 522/2,
 Rampur Road, In front of sapna
 takij, Roorkee, Haridwar, Roorkee,
 Uttarakhand, 247667

2443 3578 1636

 1947
 1800 300 1947

 help@uidai.gov.in

 www.uidai.gov.in

Malik Radix Health Care Pvt. Ltd.
C-217, C-218, Nirman Vihar
Delhi-110092
Ph. : 011-22011196, 22011192
Regd. No. 607

MALIK RADIX HEALTHCARE PVT LTD

UNI-EMC-217/218 NIRMAN VIHAR VIKAS MARG

DELHI 110092

Handwritten signature

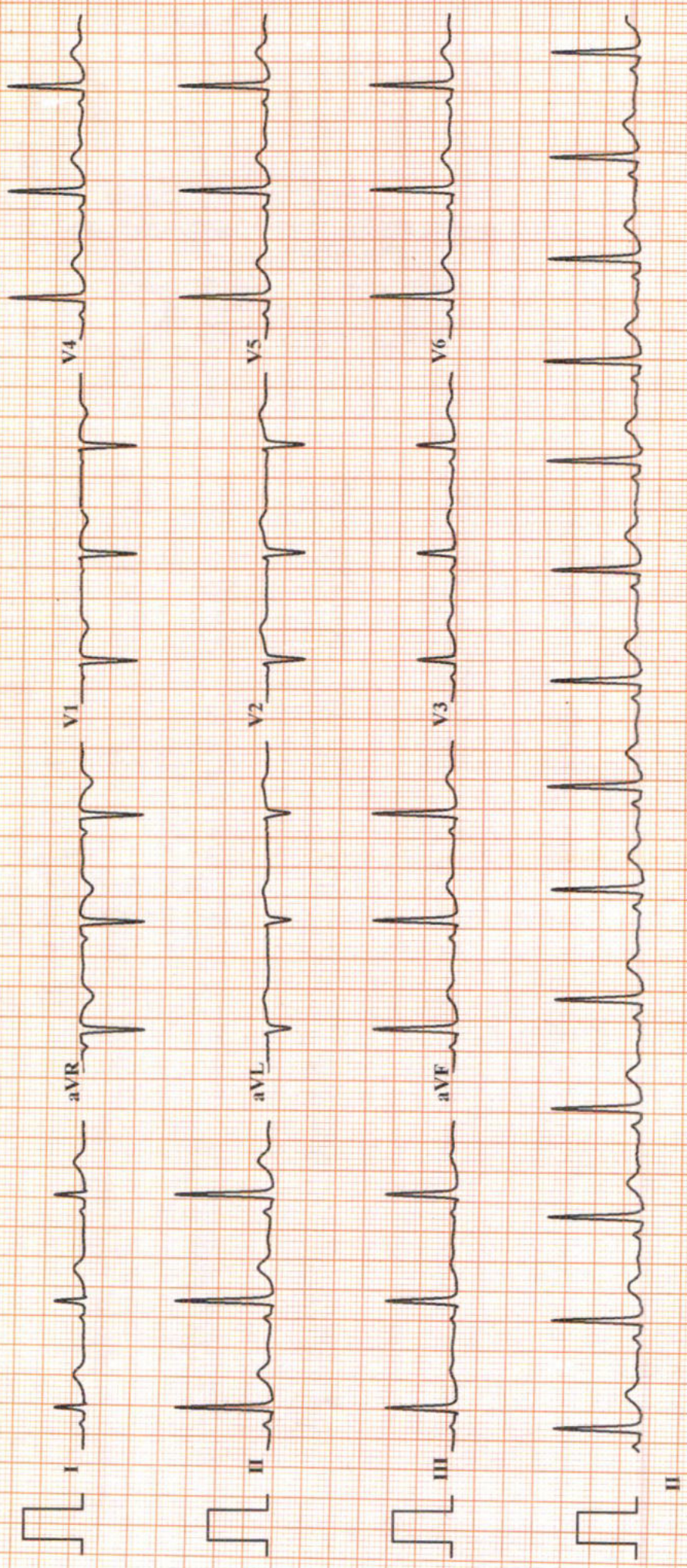
ASMA : 947
I.D. :
AGE/SEX : 31 Yr / F
HT/WT :
DATE : 20-12-2022 09:40:29 AM
REF BY : Dr.
MACHINE INTERPRETATION : Normal ECG.

RATE : 85 bpm
BP : N/A
P-Axis : 59 deg.
QRS Axis : 73 deg.
T Axis : 45 deg.

P Duration : 69 ms
PR Duration : 109 ms
QRS Duration : 69 ms
QT Interval : 337 ms
QTc Interval : 379 ms

Linked Median

Speed : 25 mm/s
Sensitivity : 10 mm/mV



Malik Radix HealthCare.

ELECTROCARDIOGRAM

Name: MRS. ASMA

Age & Sex: 31 YR/FEMALE

Ref by: MEDIWHEEL

Date: 20/12/2022

ECC FINDINGS:

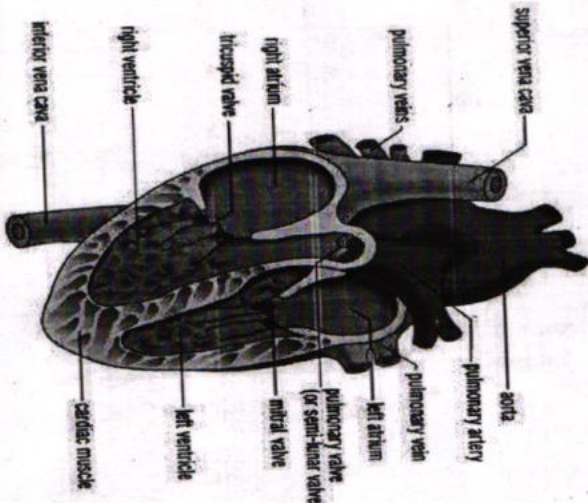
Rate 85bpm Rhythm Sinus Mechanism Normal

Axis Normal P Wave Normal PR Interval 0.10/Sec

QRS Complex Normal QT Interval Normal Q Wave Normal

ST Segment Normal T Wave Normal

Conclusion Sinus Rhythm, Normal Axis, TWNL.



Doctors Signature Dr. SHEIKH SAZIB AHMED
M.D. "Physician"
PGDCC
DMC-46499



MALIK RADIX HEALTH CARE

(UNIT OF MALIK RADIX HEALTHCARE PVT. LTD)
C-217, 218, Nirman Vihar, Vikas Marg, New Delhi - 110092
Tel.: 011-22011192, 22011196, 47060150 • Fax.: 22011208
E-mail : radixhealthcare@yahoo.co.in
Website : www.radixhealthcare.org



Safety at WEI now accredited by NABH

Name - Asma
Age - 31yr/F

20/12/22

Routine Checkup

Vu 6/6 e/f
6/6 e/f

Near No
No

No systemic
Complaint

Dr. Adhi Gupta
MBS, MS, DNB
Casualtant Ophthalmologist
Malik Radix Healthcare Pvt. Ltd.
DMC No. 121661

Facilities Available :

MRHC / GEN / FR / 15

- ★ Multispeciality Hospital ★ 24 Hours Emergency ★ X-Ray/ ECG/ Ultrasound ★ Dental
- ★ Fully Equipped Operation Theatre ★ Fully Functional Lab ★ Casualty/ICU ★ Nursery
- ★ Labour Room ★ All Speciality OPD ★ Laparoscopic Surgery ★ ECHO ★ Plastic Surgery

Home Collection Facility Available Contact : 8587915647



MALIK RADIX HEALTH CARE

(UNIT OF MALIK RADIX HEALTHCARE PVT. LTD)

C-217, 218, Nirman Vihar, Vikas Marg, New Delhi - 110092

Tel.: 011-22011192, 22011196, 47060150 • Fax.: 22011208

E-mail : radixhealthcare@yahoo.co.in

Website : www.radixhealthcare.org



Safety at WEI now accredited by NABH

Echocardiogram Report

Patient Name	MRS. ASMA
Date of Test	20/12/2022
Age	31YRS/ FEMALE
Ref. by	MEDI WHEEL

Dimensions	Result	Normal Range
AO (ed)	2.1 cm	(2.1 -3.7cm)
LA (es)	2.6 cm	(2.1 -3.7cm)
RVID (ed)	2.0 cm	(1.1-3.0cm)
LVID (ed)	3.7 cm	(3.6 – 5.5 cm)
LVID (es)	2.5 cm	(2.3-3.9cm)
IVS (ed)	1.1 cm	(0.6 – 1-2 cm)
LVPW (ed)	1.1 cm	(0.6 – 1-2 cm)
EF	60 %	
FS	31 %	(28 % - 42 %)

Impression

NO REGIONAL WALL MOTION ABNORMALITY SEEN.

LVEF= 60 %

NORMAL CHAMBERS DIMENSION.

NORMAL MIP.

NORMAL COLOUR FLOW.

NO INTRA CARDIAC CLOT/MASS/ VEGETATION/PERICARDIAL EFFUSION SEEN.

Dr. Nishant Tyagi

(M.D. Medicine. DNB Cardiology)

(Senior Consultant, Cardiology)

Dr. Sheikh Nazir Ahmed

M.D. "Physician" PGDCC

(Consultant Non – Invasive Cardiologist)

Facilities Available :

MRHC / GEN / FR / 15

- ★ Multispeciality Hospital
- ★ 24 Hours Emergency
- ★ X-Ray/ ECG/ Ultrasound
- ★ Dental
- ★ Fully Equipped Operation Theatre
- ★ Fully Functional Lab
- ★ Casualty/ICU
- ★ Nursery
- ★ Labour Room
- ★ All Speciality OPD
- ★ Laparoscopic Surgery
- ★ ECHO
- ★ Plastic Surgery

Home Collection Facility Available Contact : 8587915647



LAB REPORT

Reg. Date	20/12/2022	Patient Id	2212200002	DOB.	11/09/1991
Name	MRS. ASMA	Gender	F	Perm. ID	
Age	31 Yrs. 3 Mn. 9 Day	Panel	MEDIWHEEL	Reported	20/12/2022 16:47:41
Ref. By	MEDIWHEEL				

Test Name	Result	Units	Ref. Range
MEDIWHEEL F BELOW 40			

HAEMATOLOGY

COMPLETE HAEMOGRAM

HAEMOGLOBIN (HB%)	13.7	gm/dl	12 - 15
TOTAL LEUCOCYTE COUNT (TLC)	8,200	/cumm	4000 - 11000

DIFFERENTIAL LEUCOCYTE COUNT (DLC)

NEUTROPHIL	55	%	40 - 80
LYMPHOCYTE	40	%	28 - 55
MONOCYTE	04	%	02 - 10
EOSINOPHIL	02	%	01 - 06
BASOPHIL	00	%	0 - 0
ESR (WESTEGREN'S METHOD)	12	mm/1st hr.	0 - 15
R B C COUNT	4.81	Millions/cmm	4.247 - 5.4
P.C.V / HAEMATOCRIT	42.0	%	35 - 45
M C V	87.3	fl.	80 - 100
M C H	28.5	Picogram	27.0 - 31.0
M C H C	32.6	gm/dl	33 - 37
PLATELET COUNT	2.89	Lakh/cu mm	1.50 - 4.50

Urine Routine Examination

PHYSICAL EXAMINATION

QUANTITY	10	ml.	
COLOUR	Pale Yellow		Pale Yellow
TRANSPARENCY	Clear		
SPECIFIC GRAVITY	1.010		
PH	6.5		

Checked by : _____
Page 1 Contd...2

If test results are alarming or unexpected, patient is advised to contact the laboratory immediately for possible remedial action.

Facilities Available

- Multispeciality Hospital - 24 Hours Emergency - X-Ray/ ECG/ Ultrasound/ CT Scan - Dental - Fully Equiped Operation Theatre
- Fully Functional Lab - Casualty/ ICU-Nursery - Labour Room - All Speciality OPD - Laproscopic Surgery - ECHO - Plastic Surgery



LAB REPORT

Reg. Date	20/12/2022	Patient Id	2212200002	DOB.	11/09/1991
Name	MRS. ASMA	Gender	F	Perm. ID	
Age	31 Yrs. 3 Mn. 9 Day	Panel	MEDIWHEEL	Reported	20/12/2022 16:47:41
Ref. By	MEDIWHEEL				

Test Name	Result	Units	Ref. Range
CHEMICAL EXAMINATION			
ALBUMIN	Nil		
SUGAR	Nil		
MICROSCOPIC EXAMINATION			
PUS CELLS	2-3	/HPF	
RBC'S	Nil	/HPF	
CASTS	Nil		
CRYSTALS	NIL		
EPITHELIAL CELLS	2-3	/HPF	
BACTERIA	Nil		
OTHERS	Nil		
Stool Examination Report			
BLOOD GROUP ABO	" AB "		
RH TYPING	Positive		
BLOOD SUGAR FASTING	97.76	mg/dl	70 - 100
BLOOD SUGAR PP	102.65	mg/dl	90 - 140
HB A1C	5.16	%	

Interpretation

Non Diabetic	: 4-6%
Good Diabetic Control	: 6-8%
Fair Control	: 8-10%

Checked by : _____
Page 2 Contd...3

If test results are alarming or unexpected, patient is advised to contact the laboratory immediately for possible remedial action.

Facilities Available

- Multispeciality Hospital - 24 Hours Emergency - X-Ray/ ECG/ Ultrasound/ CT Scan - Dental - Fully Equiped Operation Theatre
- Fully Functional Lab - Casualty/ ICU-Nursery - Labour Room - All Speciality OPD - Laproscopic Surgery - ECHO - Plastic Surgery



LAB REPORT

Reg. Date	20/12/2022	Patient Id	2212200002	DOB.	11/09/1991
Name	MRS. ASMA	Gender	F	Perm. ID	
Age	31 Yrs. 3 Mn. 9 Day	Panel	MEDIWHEEL	Reported	20/12/2022 16:47:41
Ref. By	MEDIWHEEL				

Test Name	Result	Units	Ref. Range
Poor Control	: >10%		

The Glycosylated haemoglobin assay has been validated as a reliable indicator Of mean blood glucose levels for a period of 8-12 week period. ADA recommended the testing twice a year in patients with stable blood glucose and quarterly. If treatment change, or if blood glucose levels are unstable.

TO BE CORRELATED CLINICALLY.

THYROID PROFILE

Free T3 ELFA	2.16	ng/ml	02 - 04
Free T4 ELFA	1.23	ug/dl	0.8 - 2.7
TSH Serum/ELFA	7.750	uIU/ml	0.25 - 5.50 uIU/ml

Interpretation

Clinical Use

- Diagnose Hypothyroidism and Hyperthyroidism
- Monitor T4 replacement or T4 suppressive Therapy
- Quantify TSH levels in the subnormal range

Increased Levels : Primary Hypothyroidism Subclinical Hypothyroidism, TSH dependent, Thyroid Hormone Resistance.

Decreased Levels : Grave's Disease, Autonomous Thyroid Hormone Secretion, TSH Deficiency

LIPID PROFILE

TOTAL CHOLESTEROL	253.30	mg/dL	130.0 - 200.0 (<200)
-------------------	--------	-------	----------------------

Checked by : _____
Page 3 Contd...4

If test results are alarming or unexpected, patient is advised to contact the laboratory immediately for possible remedial action.

Facilities Available

- Multispeciality Hospital - 24 Hours Emergency - X-Ray/ ECG/ Ultrasound/ CT Scan - Dental - Fully Equiped Operation Theatre
- Fully Functional Lab - Casualty/ ICU-Nursery - Labour Room - All Speciality OPD - Laproscopic Surgery - ECHO - Plastic Surgery



LAB REPORT

Reg. Date	20/12/2022	Patient Id	2212200002	DOB.	11/09/1991
Name	MRS. ASMA	Gender	F	Perm. ID	
Age	31 Yrs. 3 Mn. 9 Day	Panel	MEDIWHEEL	Reported	20/12/2022 16:47:41
Ref. By	MEDIWHEEL				

Test Name	Result	Units	Ref. Range
TRIGLYCERIDES	236.40	mg/dL	80.5 - 150.0 (<150)
H D L CHOLESTEROL DIRECT	36.83	mg/dL	42.0 - 60.0 (<40->59)
V L D L	47.3	mg/dL	4.0 - 30. (23-45)
L D L CHOLESTEROL	169.2	mg/dL	50.0 - 150.0 (50-150)
TOTAL CHOLESTEROL / HDL RATIO	6.9		3.3 - 5.1
LDL / HDL CHOLESTEROL RATIO	4.6		1.5 - 3.5
SERUM URIC ACID	4.40	mg/dl	2.4 - 6.0
BLOOD UREA NITROGEN (BUN)	14.50	mg/dl	6.0 - 21.0
SERUM CREATININE	0.90	mg/dl	0.6 - 1.2
BUN/CREAT RATIO	16.1	mg/dl	
<u>LIVER FUNCTION TEST (LFT)</u>			
BILIRUBIN TOTAL	0.82	mg/dl	0.2 - 1.2
CONJUGATED (D. BILIRUBIN)	0.22	mg/dl	0.00 - 0.3
UNCONJUGATED (I.D.BILIRUBIN)	0.60	mg/dl	0.2 - 0.9
SGOT / AST	35.25	IU/L	0 - 35
SGPT / ALT	41.55	IU/L	0 - 35
ALKALINE PHOSPHATASE	219.20	U/L	64 - 306
TOTAL PROTEIN	8.39	gm/dl	6.0 - 8.3
ALBUMIN	4.96	gm/dl	3.2 - 5.0
GLOBULIN	3.43	gm/dl	2.5 - 5.6
A/G RATIO	1.45		0.9 - 2.0
GAMMA GT	25.00	IU/L	0.0 - 35.0

10 - 20

Dr. REEMA DAHIYA
M.B.B.S, MD (Path.)
Checked by: Malik Radix Healthcare Pvt. Ltd.
C-217, C-218, Nirman Vihar,
Delhi-92

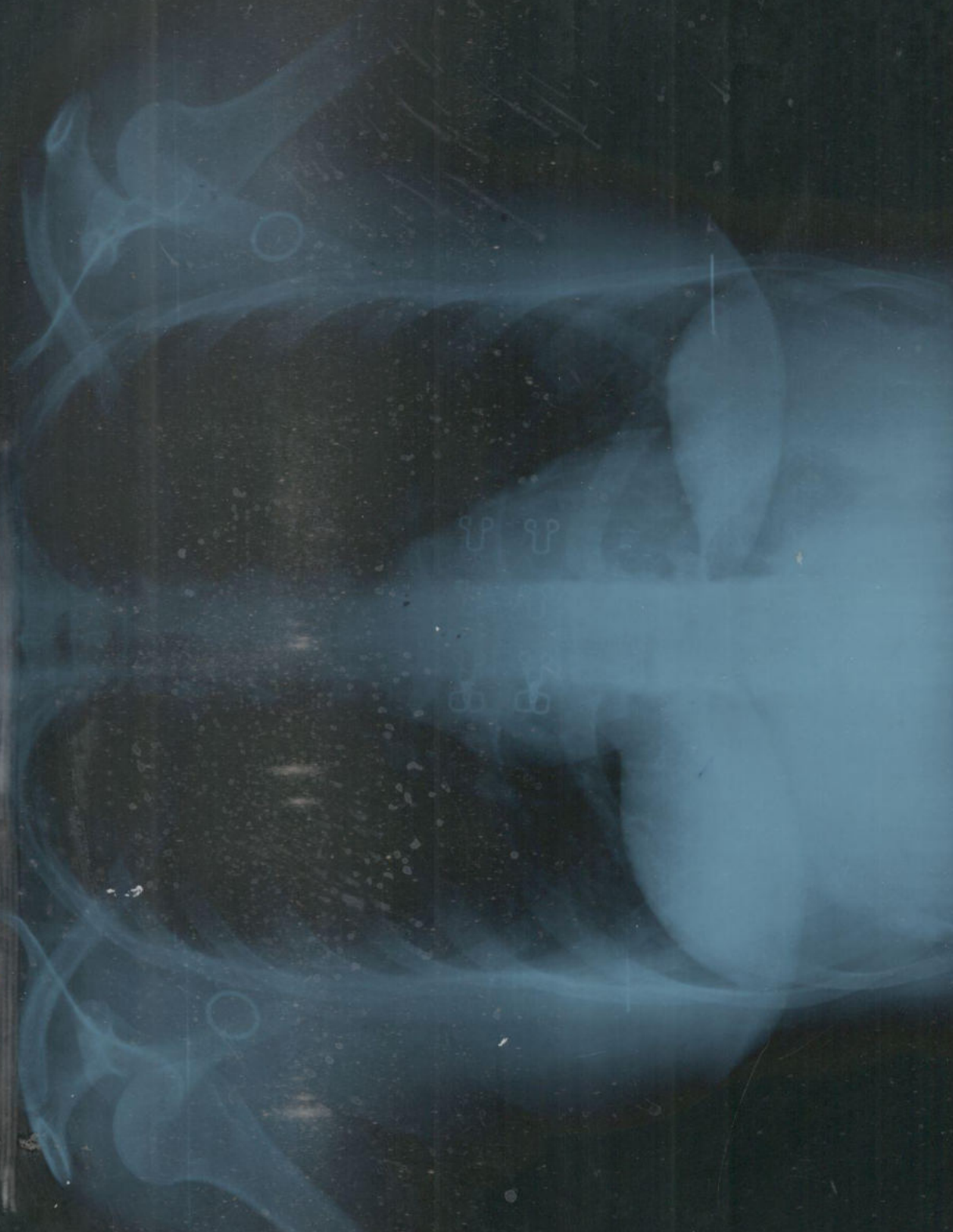
DR. MEENU AGGARWAL
M.B.B.S, MD (Path.)

If test results are alarming or unexpected, patient is advised to contact the laboratory immediately for possible remedial action.

Facilities Available

- Multispeciality Hospital - 24 Hours Emergency - X-Ray/ ECG/ Ultrasound/ CT Scan - Dental - Fully Equipped Operation Theatre
- Fully Functional Lab - Casualty/ ICU-Nursery - Labour Room - All Speciality OPD - Laproscopic Surgery - ECHO - Plastic Surgery

R



35 MA 31-Y/F PT176990 CHEST PA 20/Dec/2022 09:40 AM
RADIOLOGY HEALTH CARE C 218 NIRMAN VIHAR PH 2011106

UHID	PT176990	LAB No.	XRY2207734
Name	Mrs. ASMA	Regn. No.	GEN2232456
Age / Sex	31 Yrs / F	Receiving Dt/Time	20/Dec/2022 09:40
		Reporting Dt/Time	20/Dec/2022 09:45 AM



XRAY

CHEST (PA)

Both lung fields are normal.

Cp angles are clear.

Hila are normal...

Heart size appears within normal limits.

Soft tissue shadows and bony thorax are normal.

Advised....please correlate clinically.

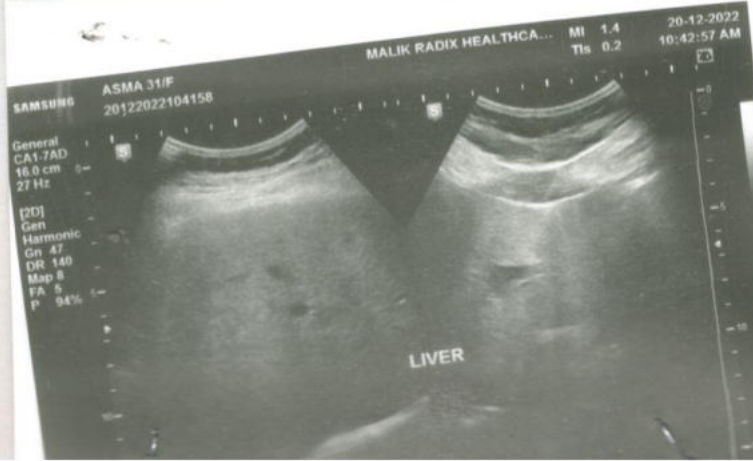
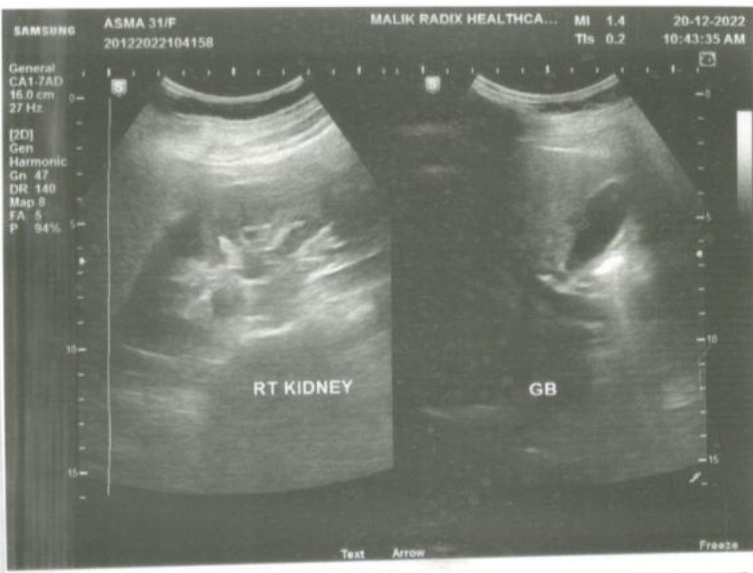
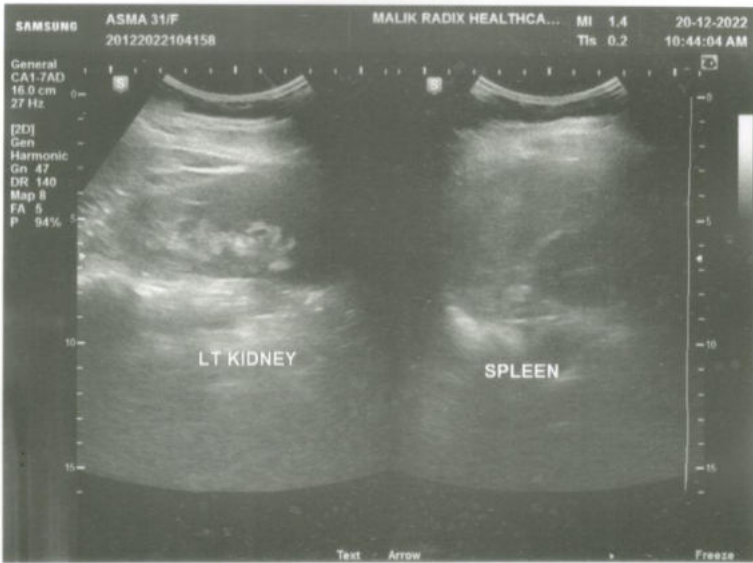
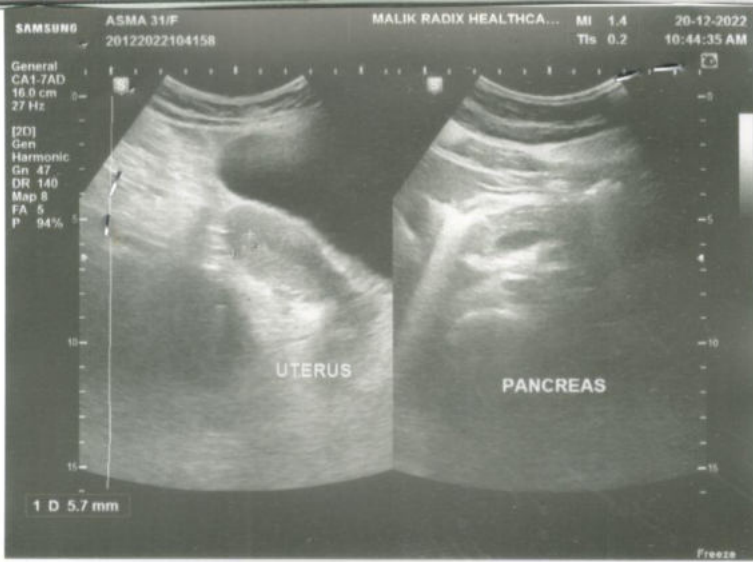
***** END OF REPORT *****

DR. K.K. SINHA
M.B.B.S. D.M.R.D.
SENIOR CONSULTANT
Reg. No. 25437 (DMC)

DR. RAJESH MALHOTRA
MBBS, MD (RADIOLOGY)
CONSULTANT RADIOLOGY
Reg.No.DMC9299

DR. T. K VOHRA
MD (RADIODIAGNOSIS)
SENIOR CONSULTANT
Reg. No. 3272 (DMC)

DR. MUKESH KOSHAL
MBBS, MD (RADIOLOGY)
CONSULTANT RADIOLOGY
Reg.No.DMC10407





MALIK RADIX HEALTH CARE

(UNIT OF MALIK RADIX HEALTHCARE PVT. LTD)
C-217, 218, Nirman Vihar, Vikas Marg, New Delhi - 110092
Tel.: 011-22011192, 22011196, 47060150 • Fax.: 22011208
E-mail : radixhealthcare@yahoo.co.in
Website : www.radixhealthcare.org



NAME	MRS ASMA	AGE	31 Y/F
REFD. BY.	HEALTH CHECK UP	DATE	20.12.22

Ultrasound Examination of Whole Abdomen & Pelvis :

Liver: Liver shows grade 1 fatty change . No focal SOL is seen in liver. IHBR & portal radicles are normal.

Gallbladder: Gallbladder shows normal anechoic pattern. No evidence of cholecystitis or cholelithiasis seen. Common bile duct is normal in course & caliber.

Pancreas: Pancreas shows normal size & echotexture.

Spleen: Spleen shows normal size, outline & echotexture.

Kidneys: Kidneys show normal size, shape, position & echotexture. No calculus, hydronephrosis or SOL is seen in kidneys. Cortico- medullary differentiation and cortical thickness is normal on both sides.

No supra- renal mass seen.

Great abdominal vessels are normal.

Domes of diaphragm are seen to move normally & synchronously in respiration. No infra- or supradiaphragmatic collection seen.

No ascites or pericardial effusion seen.

No para aortic lymph nodes seen.

Urinary bladder: Urinary bladder shows normal anechoic pattern. No calculus, SOL or diverticulum seen.

Uterus: Uterus is anteverted and normal in size & echotexture. No intrinsic SOL is seen in uterus. Endometrial thickness is 5.7 mm.

Adnexa: Adnexal regions including the ovaries are sonographically normal.

IMP- GRADE 1 FATTY LIVER

Regards,

Dr Mukesh Koshal MD (Rad- diag)
Regn. No. DMC 10407

RADIOLOGIST :

Facilities Available :

- ★ Multispeciality Hospital ★ 24 Hours Emergency ★ X-Ray/ ECG/ Ultrasound ★ Dental
- ★ Fully Equipped Operation Theatre ★ Fully Functional Lab ★ Casualty/ICU ★ Nursery
- ★ Labour Room ★ All Speciality OPD ★ Laparoscopic Surgery ★ ECHO ★ Plastic Surgery

Home Collection Facility Available Contact : 8587915647