

NAME - Jal laxmi

AGE- 29 yrs

DATE- 14-4-23

REF.BY- BOB

USG ABDOMEN

Liver is normal in size, shape and homogeneous in echotexture. Margins are smooth and regular. No focal lesion is seen. IHBRs and hepatic veins are normal in caliber. Portal vein is normal in caliber.

Rt Lobe - 12 cm

Gall bladder is well distended with normal wall thickness. No evidence of calculus/sludge or mass lesion is noted. CBD is normal in diameter.

Pancreas is normal in size, shape and homogeneous in echotexture. No focal lesion is seen. Pancreatic duct is not dilated.

Spleen is normal in size, shape and homogeneous in echotexture.

Right kidney is normal in size, shape & echotexture, C-M differentiation is maintained. No calculus and hydronephrosis is seen.

Left kidney is normal in size, shape & echotexture, C-M differentiation is maintained. No calculus and hydronephrosis is seen.

Urinary bladder is well distended. Wall thickness is normal. No evidence of calculus or mass lesion is seen.

Uterus is normal in size shape and anteverted. Myometrial & endometrial echotexture is normal. Endometrial thickness is normal

Right ovary- is normal in size and echotexture.

Left ovary- is normal in size and echotexture.

No free fluid is seen in peritoneal cavity.

IMPRESSION: Abdominal Organs are Normal

DR. ROOPA GOYAL (M.D.)
RMC NO. 004507/15600
[MD RADIOLOGIST]
Co [RMC NO 004507/15600]

Note: This report is not valid for medico legal purpose.

2. Sonography reports should be viewed in correlation with Clinical findings. If any doubt, USG may be repeated.
भ्रूण लिंग परीक्षण करवाना जघन्य अपराध है तथा इसकी शिकायत 104 टोल फ्री सेवा पर की जा सकती है

भ्रूण लिंग परीक्षण करवाना जघन्य अपराध है। इसकी शिकायत 104 टोल फ्री सेवा पर की जा सकती है।

IAME- Mrs . Jay Laxmi Saini

AGE- 29 yrs

DATE - 14-04-2023

REF.BY -

SKIAGRAM CHEST PA VIEW

**Both cp angles are clear.
Cardiac size is within normal limits.
Both lungs fields are clear.**

NAD IN HEART AND LUNGS.

Dr. ROOPA GOYAL (M.B.B.S., M.D.)
Consultant Radiologist
RMC No-004507/15600

मूण लिंग परिक्षण करवाना जघन्य अपराध है। इसकी शिकायत 104 टोल फ्री सेवा पर की जा सकती है।

ALTER TMT ECHOCARDIOGRAPHY SPIROMETRY DIGITAL X-RAY BMD OPG MAMMOGRAPHY CLINICAL LAB. PAP SMEAR FNAC
RESULTS ALWAYS BE CO-RELATED WITH THE CLINICAL AND OTHER INVESTIGATION FINDING WHERE APPLICABLE THIS REPORT IS NOT MEANT FOR MEDICO-LEGAL PURPOSE.

Patient Name: Mrs. JAYLAXMI 29/F

5 Seconds ECG Report

April 14, 2023

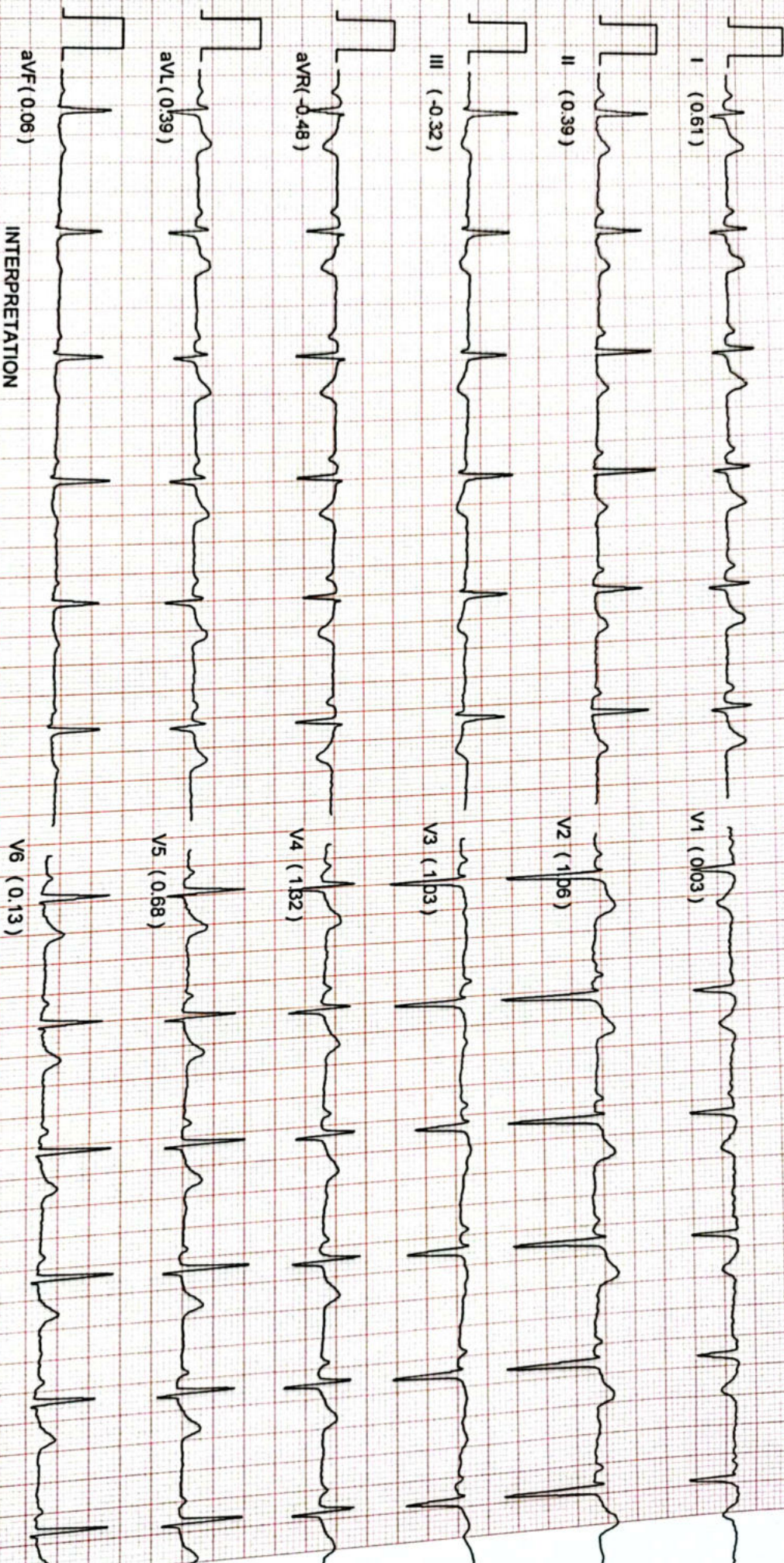
Time: 09:57:02

P-QRS-T Axis (20)-(47)-(16) deg

PR Interval: 0.12 sec
QRS Duration: 0.076 Sec

RR Interval: 0.80 sec

HR : 75 bpm - BP : 0/0 mmHg



INTERPRETATION

Sinus Rhythm, PR is normal, Normal QRS Width, Normal QT Interval, QRS Axis is normal,
T wave inversion in Lead III, V1,
Otherwise Normal ECG

*Unconfirmed Reporting. Refer to Clinician

DR
MD