

Malik Radix Health Care Pvt. Ltd.  
C-217, C-218, Nirman Vihar  
Delhi-110092  
Ph. : 011-22011196, 22011192  
Regd. No. 607



भारत का प्रमुख परामर्श आधिकारिक  
 Ministry of India

पता: W/O: गणेश प्रसाद, ए - 1, तीसरा फ्लोर,  
 नार्थ ब्लॉक, गली नं.- 1, वेस्ट विनोद नगर,  
 शकर पुर बरामद, पूर्वी दिल्ली, दिल्ली, 110092  
 Address: W/O: Ganesh Prasad, A - 1, 3rd  
 Floor, North Block, Gali No.- 1, West Vinod  
 Nagar, Shakar Pur Baramad, East Delhi,  
 Delhi, 110092

4631 4464 4095

1947 help@uidai.gov.in www.uidai.gov.in

Print Date: 24/01/2023

MILIK KANIT...  
 C-217, C-218, Indraprastha  
 S-217, S-218  
 PH: 011-23011100, 23011102  
 Regd. No. 607





# MALIK RADIX HEALTH CARE

(UNIT OF MALIK RADIX HEALTHCARE PVT. LTD)

C-217, 218, Nirman Vihar, Vikas Marg, New Delhi - 110092

Tel.: 011-22011192, 22011196, 47060150 • Fax.: 22011208

E-mail : radixhealthcare@yahoo.co.in

Website : www.radixhealthcare.org



Safety at WEI now accredited by NABH

Name - Babita Devi  
Age - 36yrs / F

26/11/22

U-6/6 ~~2/6~~  
6/6 ~~2/6~~

Nea <sup>no</sup> <sub>no</sub>

Colo <sup>no</sup> <sub>no</sub>

Index : WNC  
(RR)

Dr.

No Ophthalmological  
problems so far

Dr. *[Signature]* Gupta  
MBBS, MS, DNB  
Casualty Ophthalmologist  
Malik Radix Healthcare Pvt. Ltd.  
DMC No. 121601

### Facilities Available :

- ★ Multispeciality Hospital
- ★ 24 Hours Emergency
- ★ X-Ray/ ECG/ Ultrasound
- ★ Dental
- ★ Fully Equipped Operation Theatre
- ★ Fully Functional Lab
- ★ Casualty/ICU
- ★ Nursery
- ★ Labour Room
- ★ All Speciality OPD
- ★ Laparoscopic Surgery
- ★ ECHO
- ★ Plastic Surgery



# MALIK RADIX HEALTH CARE

(UNIT OF MALIK RADIX HEALTHCARE PVT. LTD)  
C-217, 218, Nirman Vihar, Vikas Marg, New Delhi - 110092  
Tel.: 011-22011192, 22011196, 47060150 • Fax.: 22011208  
E-mail : radixhealthcare@yahoo.co.in  
Website : www.radixhealthcare.org



## Echocardiogram Report

Patient Name	MRS. BABITA DEVI
Date of Test	26/11/2022
Age	36 YRS/ FEMALE
Ref. by	MEDI WHEEL

Dimensions	Result	Normal Range
AO (ed)	2.4 cm	( 2.1 -3.7cm)
LA (es)	3.1 cm	(2.1 -3.7cm)
RVID (ed)	2.0 cm	(1.1-3.0cm)
LVID (ed)	4.0 cm	(3.6 – 5.5 cm)
LVID (es)	2.8 cm	(2.3-3.9cm)
IVS (ed)	1.1 cm	(0.6 – 1-2 cm)
LVPW (ed)	1.1 cm	(0.6 – 1-2 cm)
EF	60 %	
FS	31 %	(28 % - 42 %)

## Impression

1. NO REGIONAL WALL MOTION ABNORMALITY SEEN.
2. LVEF= 60%.
3. NORMAL CHAMBERS DIMENSION.
4. NORMAL MIP.
5. NORMAL COLOUR FLOW.
6. NO INTRA CARDIAC CLOT/MASS/ VEGETATION/PERICARDIAL EFFUSION SEEN.

Dr. Nishant Tyagi  
(M.D. Medicine. DNB Cardiology)  
(Senior Consultant, Cardiology)

Dr. Sheikh Nazeer Ahmed  
M.D. "Physician" PGDCC  
(Consultant Non – Invasive Cardiologist)

- ★ Multispeciality Hospital ★ 24 Hours Emergency ★ X-Ray/ ECG/ Ultrasound ★ Dental
- ★ Fully Equipped Operation Theatre ★ Fully Functional Lab ★ Casualty/ICU ★ Nursery
- ★ Labour Room ★ All Speciality OPD ★ Laparoscopic Surgery ★ ECHO ★ Plastic Surgery





**LAB REPORT**

Reg. Date	26/11/2022	Patient Id	2211260006	DOB.	
Name	MRS. BABITA DEVI	Gender	F	Perm. ID	
Age	36 Yrs.	Panel	MEDIWHEEL	Reported	26/11/2022 17:13:55
Ref. By	MEDIWHEEL				

Test Name	Result	Units	Ref. Range
-----------	--------	-------	------------

MEDIWHEEL F BELOW 40

**HAEMATOLOGY**

**COMPLETE HAEMOGRAM**

HAEMOGLOBIN (HB%)	8.0	gm/dl	12 - 15
TOTAL LEUCOCYTE COUNT (TLC)	6,400	/cumm	4000 - 11000
<b><u>DIFFERENTIAL LEUCOCYTE COUNT (DLC)</u></b>			
NEUTROPHIL	60	%	40 - 80
LYMPHOCYTE	35	%	28 - 55
MONOCYTE	04	%	02 - 10
EOSINOPHIL	01	%	01 - 06
BASOPHIL	00	%	0 - 0
ESR (WESTEGREN'S METHOD)	22	mm/1st hr.	0 - 15
R B C COUNT	3.97	Millions/cmm	4.247 - 5.4
P.C.V / HAEMATOCRIT	28.3	%	35 - 45
M C V	71.3	fl.	80 - 100
M C H	20.2	Picogram	27.0 - 31.0
M C H C	28.3	gm/dl	33 - 37
PLATELET COUNT	1.82	Lakh/cu mm	1.50 - 4.50

Urine Routine Examination

**PHYSICAL EXAMINATION**

QUANTITY	30	ml.	
COLOUR	Pale Yellow		Pale Yellow
TRANSPARENCY	Clear		
SPECIFIC GRAVITY	1.010		
PH	6.0		

Checked by : \_\_\_\_\_  
Page 1 Contd...2

If test results are alarming or unexpected, patient is advised to contact the laboratory immediately for possible remedial action.

**Facilities Available**

- Multispeciality Hospital - 24 Hours Emergency - X-Ray/ ECG/ Ultrasound/ CT Scan - Dental - Fully Equiped Operation Theatre  
- Fully Functional Lab - Casualty/ ICU-Nursery - Labour Room - All Speciality OPD - Laproscopic Surgery - ECHO - Plastic Surgery





**LAB REPORT**

Reg. Date	26/11/2022	Patient Id	2211260006	DOB.	
Name	MRS. BABITA DEVI	Gender	F	Perm. ID	
Age	36 Yrs.	Panel	MEDIWHEEL	Reported	26/11/2022 17:13:55
Ref. By	MEDIWHEEL				

Test Name	Result	Units	Ref. Range
<b>CHEMICAL EXAMINATION</b>			
ALBUMIN	Trace		
SUGAR	Nil		
<b>MICROSCOPIC EXAMINATION</b>			
PUS CELLS	2-4	/HPF	
RBC'S	Nil	/HPF	
CASTS	Nil		
CRYSTALS	NIL		
EPITHELIAL CELLS	8-10	/HPF	
BACTERIA	Nil		
OTHERS	Nil		
Stool Examination Report			
BLOOD GROUP ABO	" B "		
RH TYPING	Positive		
BLOOD SUGAR FASTING	81.61	mg/dl	70 - 100
BLOOD SUGAR PP	90.5	mg/dl	90 - 140
HB A1C	4.39	%	

**Interpretation**

Non Diabetic	: 4-6%
Good Diabetic Control	: 6-8%
Fair Control	: 8-10%

Checked by : \_\_\_\_\_  
Page 2 Contd...3

If test results are alarming or unexpected, patient is advised to contact the laboratory immediately for possible remedial action.

**Facilities Available**

- Multispeciality Hospital - 24 Hours Emergency - X-Ray/ ECG/ Ultrasound/ CT Scan - Dental - Fully Equiped Operation Theatre  
- Fully Functional Lab - Casualty/ ICU-Nursery - Labour Room - All Speciality OPD - Laproscopic Surgery - ECHO - Plastic Surgery





**LAB REPORT**

Reg. Date	26/11/2022	Patient Id	2211260006	DOB.	
Name	MRS. BABITA DEVI			Perm. ID	
Age	36 Yrs.	Gender	F	Reported	26/11/2022 17:13:55
Ref. By	MEDIWHEEL	Panel	MEDIWHEEL		

Test Name	Result	Units	Ref. Range
Poor Control	>10%		

The Glycosylated haemoglobin assay has been validated as a reliable indicator Of mean blood glucose levels for a period of 8-12 week period. ADA recommended the testing twice a year in patients with stable blood glucose and quarterly. If treatment change, or if blood glucose levels are unstable.

**TO BE CORRELATED CLINICALLY.**

**THYROID PROFILE**

Free T3 ELFA	2.56	ng/ml	02 - 04
Free T4 ELFA	0.94	ug/dl	0.8 - 2.7
TSH Serum/ELFA	3.020	uIU/ml	0.25 - 5.50 uIU/ml

**Interpretation**

**Clinical Use**

- Diagnose Hypothyroidism and Hyperthyroidism
- Monitor T4 replacement or T4 suppressive Therapy
- Quantify TSH levels in the subnormal range

Increased Levels : Primary Hypothyroidism Subclinical Hypothyroidism, TSH dependent, Thyroid Hormone Resistance.

Decreased Levels : Grave's Disease, Autonomous Thyroid Hormone Secretion, TSH Deficiency

**LIPID PROFILE**

TOTAL CHOLESTEROL	120.40	mg/dL	130.0 - 200.0 (<200)
-------------------	--------	-------	-------------------------

Checked by : \_\_\_\_\_  
Page 3 Contd...4

If test results are alarming or unexpected, patient is advised to contact the laboratory immediately for possible remedial action.

**Facilities Available**

- Multispeciality Hospital - 24 Hours Emergency - X-Ray/ ECG/ Ultrasound/ CT Scan - Dental - Fully Equiped Operation Theatre
- Fully Functional Lab - Casualty/ ICU-Nursery - Labour Room - All Speciality OPD - Laproscopic Surgery - ECHO - Plastic Surgery





**LAB REPORT**

Reg. Date	26/11/2022	Patient Id	2211260006	DOB.	
Name	MRS. BABITA DEVI	Gender	F	Perm. ID	
Age	36 Yrs.	Panel	MEDIWHEEL	Reported	26/11/2022 17:13:55
Ref. By	MEDIWHEEL				

Test Name	Result	Units	Ref. Range
TRIGLYCERIDES	89.50	mg/dL	80.5 - 150.0 (<150)
H D L CHOLESTEROL DIRECT	39.42	mg/dL	42.0 - 60.0 (<40->59)
V L D L	17.9	mg/dL	4.0 - 30. (23-45)
L D L CHOLESTEROL	63.1	mg/dL	50.0 - 150.0 (50-150)
TOTAL CHOLESTEROL / HDL RATIO	3.1		3.3 - 5.1
LDL / HDL CHOLESTEROL RATIO	1.6		1.5 - 3.5
SERUM URIC ACID	4.42	mg/dl	2.4 - 6.0
BLOOD UREA NITROGEN (BUN)	13.40	mg/dl	6.0 - 21.0
SERUM CREATININE	1.00	mg/dl	0.6 - 1.2
BUN/CREAT RATIO	13.4	mg/dl	
<b><u>LIVER FUNCTION TEST (LFT)</u></b>			
BILIRUBIN TOTAL	0.75	mg/dl	0.2 - 1.2
CONJUGATED (D. BILIRUBIN)	0.39	mg/dl	0.00 - 0.3
UNCONJUGATED (I.D.BILIRUBIN)	0.36	mg/dl	0.2 - 0.9
SGOT / AST	46.54	IU/L	0 - 35
SGPT / ALT	34.71	IU/L	0 - 35
ALKALINE PHOSPHATASE	39.20	U/L	64 - 306
TOTAL PROTEIN	7.75	gm/dl	6.0 - 8.3
ALBUMIN	4.50	gm/dl	3.2 - 5.0
GLOBULIN	3.25	gm/dl	2.5 - 5.6
A/G RATIO	1.38		0.9 - 2.0
GAMMA GT	26.32	IU/L	0.0 - 35.0

10 - 20

**Dr. REEMA DAHIYA**

M.B.B.S. (Path.)

Malik Radix Healthcare Pvt. Ltd.

M.B.B.S. MD (Path.)

Checked by Nirman Vihar

Delhi-92 Page 4 of 4

**DR. MEENU AGGARWAL**

M.B.B.S, MD (Path.)

If test results are alarming or unexpected, patient is advised to contact the laboratory immediately for possible remedial action.

**Facilities Available**

- Multispeciality Hospital - 24 Hours Emergency - X-Ray/ ECG/ Ultrasound/ CT Scan - Dental - Fully Equiped Operation Theatre  
- Fully Functional Lab - Casualty/ ICU-Nursery - Labour Room - All Speciality OPD - Laproscopic Surgery - ECHO - Plastic Surgery



NAME	MRS BABITA	AGE	36 Y/F
REFD. BY.	HEALTH CHECK UP	DATE	26.11.22

### Ultrasound Examination of Whole Abdomen & Pelvis :

**Liver:** Liver shows normal parenchymal echotexture. **Right of liver shows a calcified hemangioma.** IHBR & portal radicles are normal.

**Gallbladder:** Gallbladder shows normal anechoic pattern. No evidence of cholecystitis or cholelithiasis seen. Common bile duct is normal in course & caliber.

**Pancreas:** Pancreas shows normal size & echotexture.

**Spleen:** Spleen shows normal size, outline & echotexture.

**Kidneys:** Kidneys show normal size, shape, position & echotexture. No calculus, hydronephrosis or SOL is seen in kidneys. Cortico- medullary differentiation and cortical thickness is normal on both sides. No supra- renal mass seen.

Great abdominal vessels are normal.

Domes of diaphragm are seen to move normally & synchronously in respiration. No infra- or supra diaphragmatic collection seen.

No ascites or pericardial effusion seen.

No para aortic lymph nodes seen.

**Urinary bladder:** Urinary bladder shows normal anechoic pattern. No calculus, SOL or diverticulum seen.

**Uterus:** Uterus is anteverted and normal in size & echotexture. No intrinsic SOL is seen in uterus. Endometrial thickness is 8.2 mm.


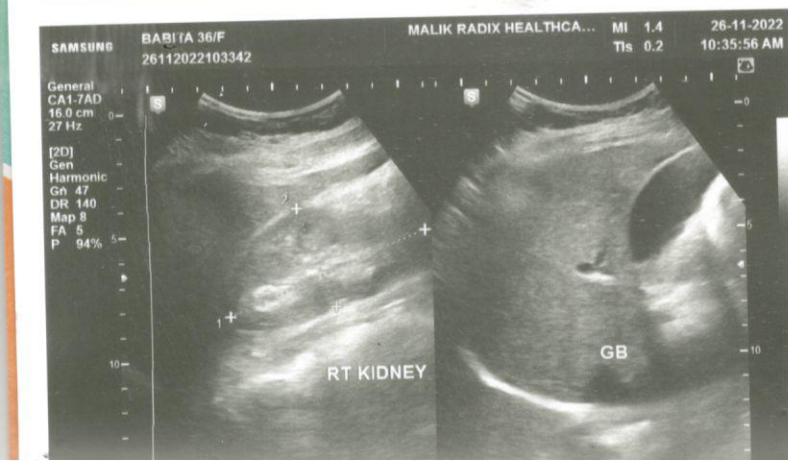
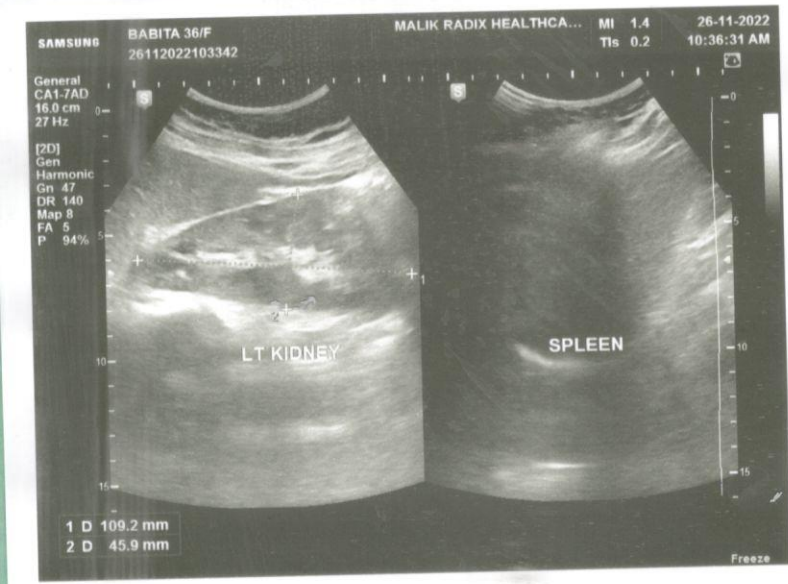
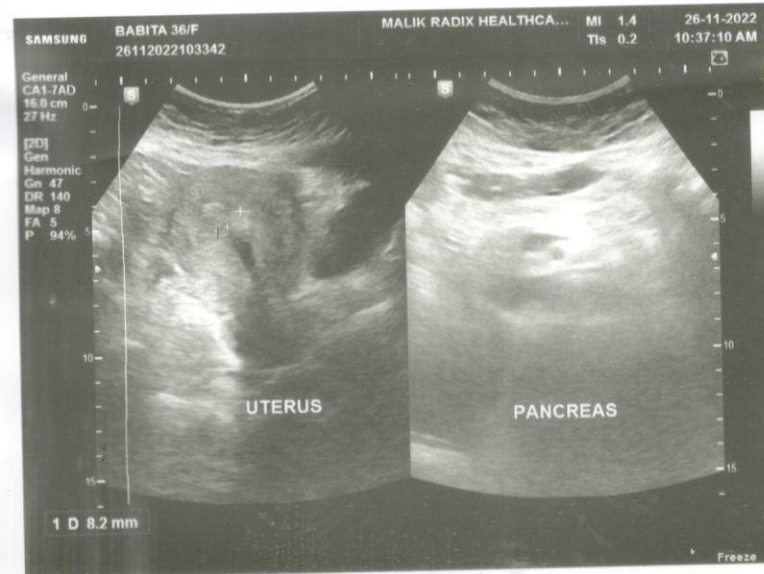
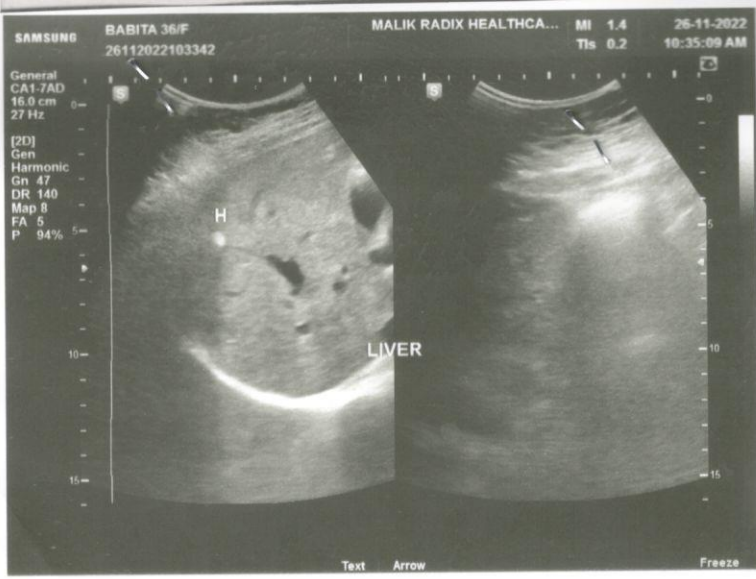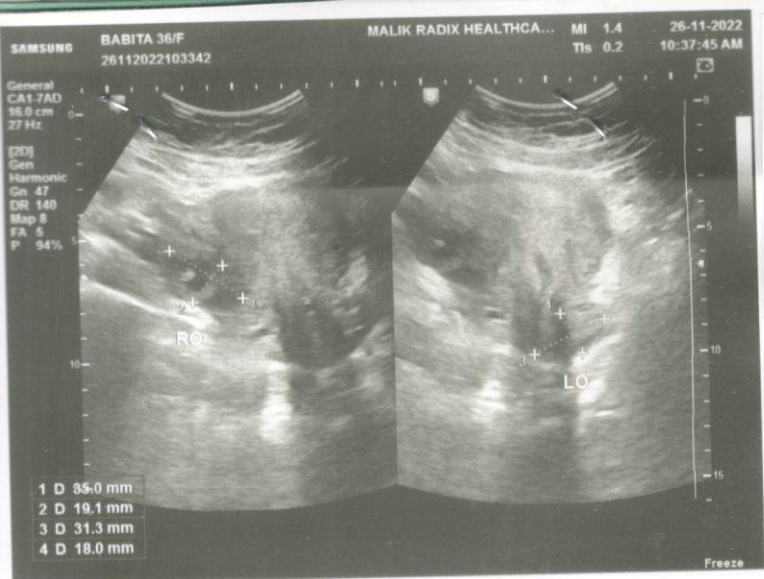
**Adnexa:** Adnexal regions including the ovaries are sonographically normal.

Regards.

  
Dr Mukesh Koshal MD ( Rad- diag)

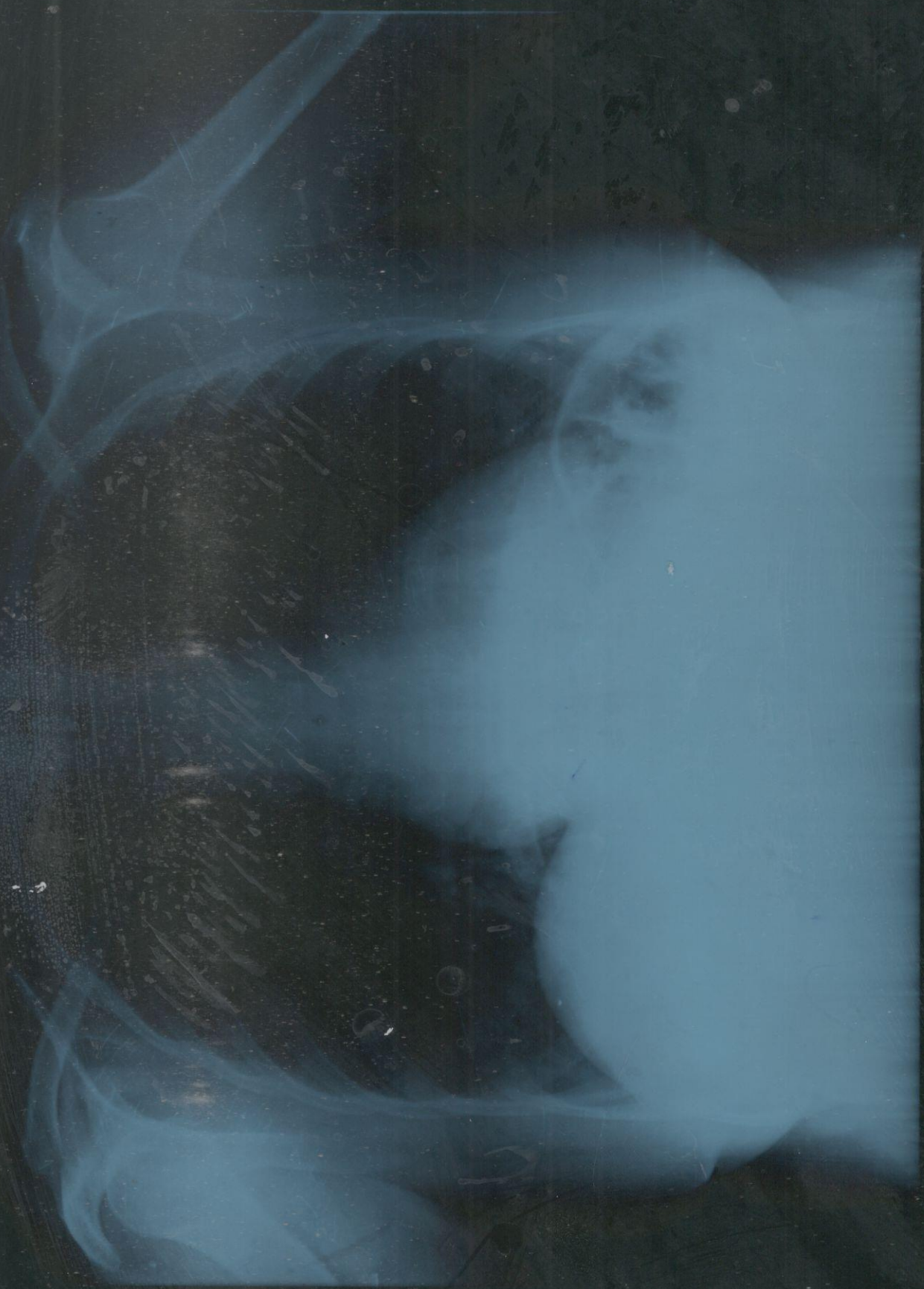Regn. No. DMC 10407







R



BABITA DEVI 3EY/F 175306 F CHEŞI PA 26 Nov 2022 09 F



UHID	PT175306	LAB No.	XRY2206923
Name	Mrs. BABITA DEVI	Regn. No.	GEN2229671
Age / Sex	36 Yrs / F	Receiving Dt/Time	26/Nov/2022 09:05
		Reporting Dt/Time	26/Nov/2022 09:29 AM



**XRAY**

CHEST (PA)

Both lung fields are normal.

Cp angles are clear.

Hila are normal...

Heart size appears within normal limits.

Soft tissue shadows and bony thorax are normal.

**IMP- NORMAL CHEST X-RAY**

Advised....please correlate clinically.

\*\*\*\*\* END OF REPORT \*\*\*\*\*

DR. K.K. SINHA  
M.B.B.S. D.M.R.D.  
SENIOR CONSULTANT  
Reg. No. 25437 (DMC)

DR. RAJESH MALHOTRA  
MBBS, MD (RADIOLOGY)  
CONSULTANT RADIOLOGY  
Reg.No.DMC9299

DR. T. K VOHRA  
MD (RADIODIAGNOSIS)  
SENIOR CONSULTANT  
Reg. No. 3272 (DMC)

DR. MUKESH KOSHAL  
MBBS, MD (RADIOLOGY)  
CONSULTANT RADIOLOGY  
Reg.No.DMC10407