

Health Check up Booking Request(bobE11678),Package Code(PKG10000240),Beneficiary Code(10440)

1 message

Mediwheel <customercare@policywheel.com>

25 April 2022 at 10:51

To: "vidhidiagnostics@gmail.com" <vidhidiagnostics@gmail.com>

Cc: Mediwheel CC <customercare@mediwheel.in>, Mediwheel CC <mediwheelwellness@gmail.com>



Mediwheel
...Your wellness partner



011-41195959

Email:wellness@mediwheel.in

Dear Vidhi Diagnostics,
City : Ahmedabad . Location : .New Wadaj,

We have received the following request for Health Check up from

Name : MR. MALI PRAVEEN KUMAR
Age : 34
Gender : Male
Member Relations : Employee
Package Name : Metro Full Body Health Checkup Male Below 40
Package Code : PKG10000240
User Location : Rajasthan,JAWAL,307801
Contact Details : 9726226720
Booking Date : 25-04-2022
Appointment Date : 28-04-2022

Member Information			
Booked Member Name	Age	Gender	Cost(In INR)
MR. MALI PRAVEEN KUMAR	34	Male	Cashless
Total amount to be paid			Cashless

Please login to your account to confirm the same. Also you mail us for confirmation

Package Name : Metro Full Body Health Checkup Male Below 40 - Includes (37)Tests

Tests included in this Package : Ecg, TSH, X-ray Chest, Stress Test (tmt)/ 2d Echo, Blood Sugar Postprandial, A:g Ratio, Blood Group, Total Cholesterol, Triglycerides, Fasting Blood Sugar, Ultrasound Whole Abdomen , Glycosylated Haemoglobin (hba1c), Hdl, Vldl, Urine Analysis, LDL, Total Protine, General Consultation, HDL/ LDL ratio, GGT(Gamma-glutamyl Transferase), Eye Check-up consultation, ALP (ALKALINE PHOSPHATASE), Uric Acid, AST/ALT Ratio, Serum Protein, CBC with ESR, Stool Analysis, Urine Sugar Fasting, Urine Sugar PP, T3, T4, Cholesterol Total / HDL Ratio, BUN, BUN/Creatinine Ratio, Bilirubin Total & Direct and Indirect, Albumin, Globulin

PRE EMPLOYMENT HEALTH SCREENING

Date : 25/04/2022

1. Personal Particulars

Name : Poojeen kumar melli NRIC No : _____
Age : 34 yrs Gender : Male / Female
Marital Status : married

Past & Present Medical History : _____
Family Medical History : _____
Allergy : _____

2. Clinical Medical Examination

Height : 165 cm Weight : 63 kg
Blood Pressure : 122/82 mmHg Pulse : 68 p/min
Vision : Uncorrected : (R) -1.25 (L) -1.25 Corrected : (R) _____ (L) _____
Colour Vision : Normal / Colour Blind
General Condition : Normal Skin : _____
Central Nervous System : Normal Head & Neck : _____
Cardiovascular System : Normal Chest : _____
Abdomen : Normal Limbs : _____
Last menstrual period : NA

3. Investigations

Chest X-Ray : Normal

I, the undersigned hereby authorize the doctor to release my medical check-up

Poojeen kumar melli
Signature of applicant

Remarks : Fit / ~~Unfit~~ for employment

Dr. Vidhi D. Modh
MSBS
Reg. No. G-74540
Dr's name, signature & chop
Vidhi Diagnostics

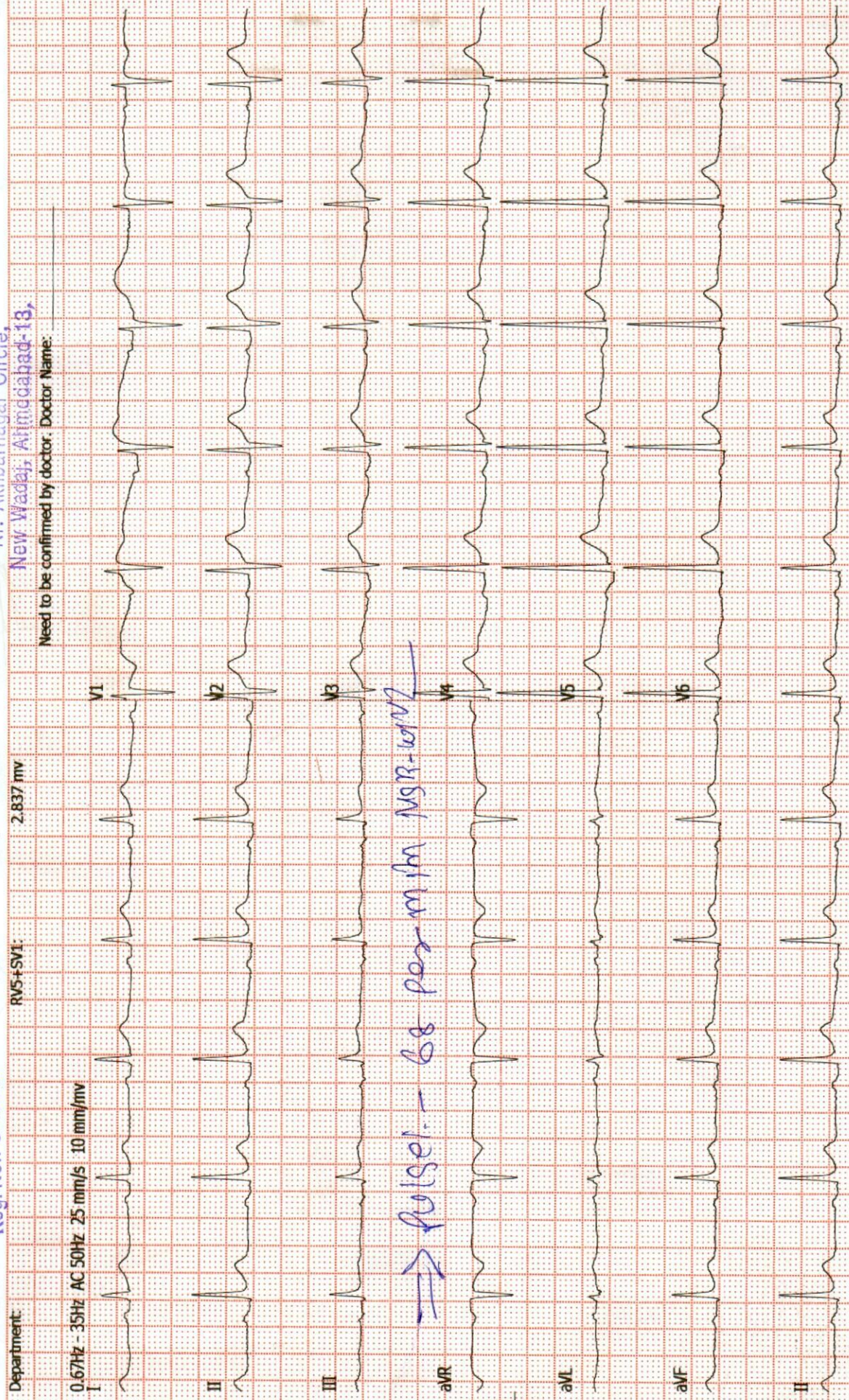
L-86, Swatantra Kenani Nagar,
Opp. Akhbarnagar Bus Terminals,
Nr. Akhbarnagar Circle,
New Wadaj, Ahmedabad-13.

HR : 68 bpm
 PR : 180 ms
 QRS : 88 ms
 QT/QTc : 352/374 ms
 P/QRS/T : 24/54/53 deg.
 RV5/SV1 : 1.979/-0.858 mv

ID: 4701
 Name: pravinkumar
 Age: 34yrs
 Sex: Male
 Hospital: **Dr. Avinash Bhatnagar**
 Reg. No.: G-45946

Vidhi Diagnostics
 L-86, Swatantra-Sonani Nagar,
 Opp. Akharnagar Bus Terminals,
 Nr. Akharnagar Circle,
 New Wadaj, Ahmedabad-13,

Need to be confirmed by doctor. Doctor Name: _____



Dr. Dinesh S. Modh

M.D., D.M.R.E. (Radiodiagnosis)

Consultant Radiologist & Sonologist

Ex. Junior Lecturer, B.J. Medical College, Civil Hospital, A'bad.

Panel Doctor of L.I.C.



Patient's name: PRAVEENKUMAR MALI

Reg. ID : R-937-21

Referred by : Dr. MEDIWHEEL

Age/Sex : 34 Years/Male


Accession : 12838

Date : 25/04/2022

X-RAY CHEST (PA VIEW)

Both lung fields appear normal.
No e/o consolidation or cavitations is seen.
Both costo-phrenic angles appear clear.
Cardiac size is with in normal limits.
Both domes of diaphragm appear normal.
Bony thoracic cage appears normal.

Thanks for reference.


Dr. Dinesh S. Modh
MD DMRE (Radiodiagnosis)
G-23825
DR DINESH S. MODH
M.D. DMRE(RADIODIAGNOSIS)

ISO 9001:2015 Certified Diagnostics Center

Vidhi Imaging Center

L-86, Swatantra Senani Nagar, Opp. Akhbarnagar Petrol Pump, Nr. Akhbarnagar Circle, Nava-Vadaj, Ahmedabad - 380 013.

Phone : 079-2762 1406, Mobile : 98799 29406, 98250 09406, E-mail : vidhidiagnostics@gmail.com, Website : www.vidhidiagnostics.com

Time : Mon. to Sat. 9.00 am to 2.00 pm, 5.00 pm to 9.00 pm, Sunday 9.00 am to 12.00 Noon

FACILITIES : Live 3D-4D Sonography | Colour Doppler | Echo Cardiography | Interventional Radiology | Fetal Medicine | Digital X-Ray
Digital Mammography | Digital OPG / TMJ | ECG / TMT / PFT / EEG / EMG | Pathology Laboratory | Health Check Up Plans | Pre Employment Check Up

Dr. Dinesh S. Modh

M.D., D.M.R.E. (Radiodiagnosis)

Consultant Radiologist & Sonologist

Ex. Junior Lecturer, B.J. Medical College, Civil Hospital, A'bad.

Panel Doctor of L.I.C.



Patient's name: PRAVEENKUMAR MALI

Reg. ID : R-937-21

Referred by : Dr. MEDIWHEEL

Age/Sex : 34 Years/Male

Accession : 12838

Date : 25/04/2022

USG ABDOMEN

LIVER:- Liver appears normal in size & echo texture. No evidence of focal lesion is seen. IHBR appear normal. Portal vein and CBD appear normal. No e/o calculus is seen in bile duct.

GALL BLADDER:- Gall bladder is distended & appears normal. No evidence of calculus or cholecystitis is seen.

SPLEEN:- Spleen appears normal in size & shows normal echo texture. No evidence of diffuse or focal lesion is seen.

PANCREAS:- Pancreas appears normal size and echo pattern. No e/o diffuse or focal lesion is seen. Main pancreatic duct appears normal.

KIDNEY:- Both Kidneys appear normal in size & echo texture.

- No e/o calculus or hydronephrosis/ hydroureter is seen on both sides.

Cortico-medullary differentiation is maintained on both sides.

Both suprarenal regions appear normal.

No evidence of pre & para aortic lymphadenopathy is seen.

Both suprarenal regions appear normal.

No evidence of pre & para aortic lymphadenopathy is seen.

RIF & BOWEL LOOPS (By high frequency probe):- Normal.

No evidence of dilated or thickened bowel loops is seen.

No evidence of free fluid is seen in abdomen.

Urinary bladder:- appears normal. No e/o calculus or mass lesion is seen in bladder.

Small ureterocele measure 13x9mm seen at left vesico-ureteric junction.

Prostate appears normal size and echopattern.

Thanks for reference.

Dr. Dinesh S. Modh
MD DMRE (Radiodiagnosis)

DR DINESH S. MODH

M.D. DMRE(RADIODIAGNOSIS)

ISO 9001:2015 Certified Diagnostics Center

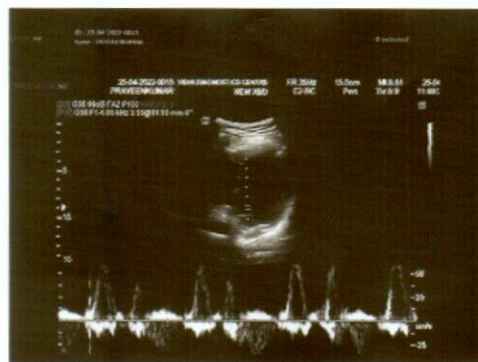
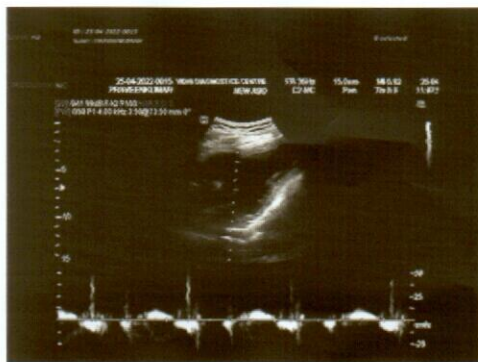
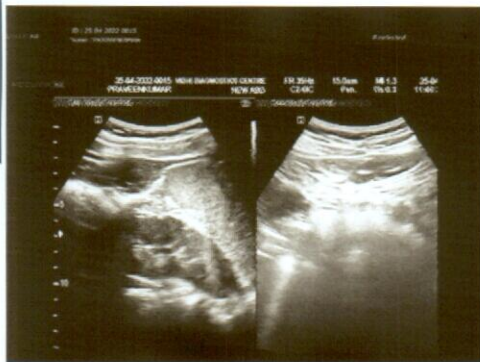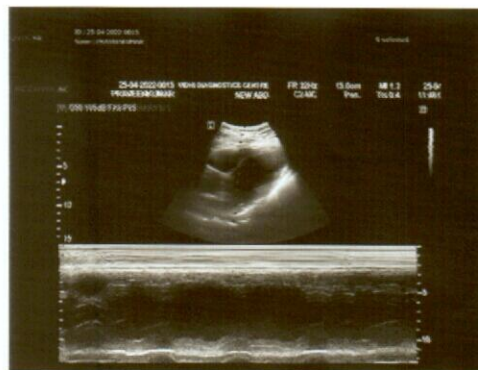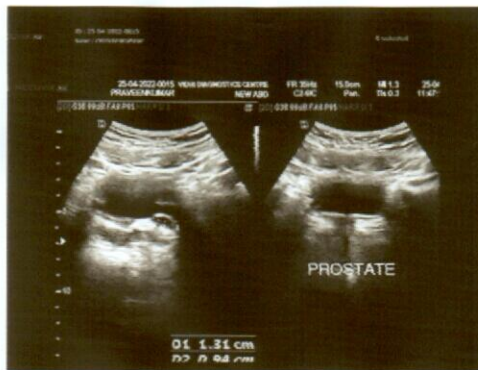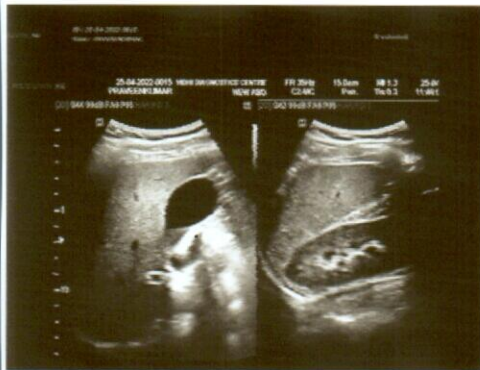Vidhi Imaging Center

L-86, Swatantra Senani Nagar, Opp. Akhbarnagar Petrol Pump, Nr. Akhbarnagar Circle, Nava-Vadaj, Ahmedabad - 380 013.

Phone : 079-2762 1406, Mobile : 98799 29406, 98250 09406, E-mail : vidhidiagnostics@gmail.com, Website : www.vidhidiagnostics.com

Time : Mon. to Sat. 9.00 am to 2.00 pm, 5.00 pm to 9.00 pm, Sunday 9.00 am to 12.00 Noon

FACILITIES : Live 3D-4D Sonography | Colour Doppler | Echo Cardiography | Interventional Radiology | Fetal Medicine | Digital X-Ray
Digital Mammography | Digital OPG / TMJ | ECG / TMT / PFT / EEG / EMG | Pathology Laboratory | Health Check Up Plans | Pre Employment Check Up



Dr. Dinesh S. Modh

M.D., D.M.R.E. (Radiodiagnosis)
Consultant Radiologist & Sonologist
Ex. Junior Lecturer, B.J. Medical College, Civil Hospital, A'bad.
Panel Doctor of L.I.C.



Patient's name: PRAVEENKUMAR MALI
Reg. ID : R-937-21
Referred by : Dr. MEDIWHEEL

Age/Sex : 34 Years/Male
Accession : 12838
Date : 25/04/2022

2D- ECHO REPORT

FINAL CONCLUSION:

LV IS NORMAL SIZE. GOOD LV SYSTOLIC FUNCTION NO RWMA.
LVEF - 60%. NO CONCENTRIC LVH.
NORMAL LV COMPLANCE.
LA IS NORMAL SIZE. NO LA CLOT.
RV IS NORMAL SIZE. GOOD RV SYSTOLIC FUNCTION.
RA IS NORMAL SIZE.
MITRAL VALVE IS NORMAL. NO MS. MILD MR (15%). NO MVP.
AORTIC VALVE IS NORMAL. NO AS. NO AR.
TRICUSPID VALVE IS NORMAL. NO TR. RVSP-26 mmHg. NO PAH.


NO CLOT, NO VEGETATION, NO PERICARDIAL EFFUSION.

DIMENSIONS:

AORTA	2.6 C.M
LEFT ATRIUM	2.7 C.M
LVDD	4.1 C.M.
IVSD	1.0 C.M
PWD	1.0 C.M
LVDS	2.6 C.M.

COLOUR DOPPLER FINDING:

STRUCTURE	VELOCITY m/sec
	Max
PULMONARY VALVE	0.7
MITRAL VALVE	E : 0.7 A: 0.4
AORTIC VALVE	1.0


Dr. Avinash Bhaskar
MBBS. D Cardio
Reg. No.: G-45946
DR AVINASH BHASKAR
CLINICAL CARDIOLOGIST

ISO 9001:2015 Certified Diagnostics Center

Vidhi Imaging Center

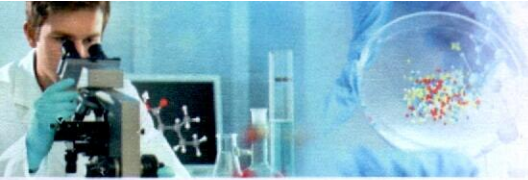L-86, Swatantra Senani Nagar, Opp. Indian Oil Petrol Pump, Akhbarnagar Circle, Nava Vadaj, Ahmedabad - 380 013.

Phone : (Radiology) 079-2762 1406 | M. 98799 29406, 98250 09406 | Time (Radiology) : Mon. to Sat. 9 am to 2 pm, 5 to 9 pm, Sunday 9 am to 12 Noon

E-mail : vidhidiagnostics@gmail.com, Website : www.vidhidiagnostics.com

Multislice CT Scan | CBCT-Dental Scan | Live 3D-4D Sonography | Colour Doppler | Echo Cardiography | Interventional Radiology | Maxillofacial Radiology | Fetal Medicine
Digital X-Ray | Digital Mammography | Digital OPG/TMJ | ECG/TMT/PFT/EEG/EMG | Audiometry | Pathology Laboratory | Health Check Up Plans | Pre Employment Check Up

CT SCAN & CBCT FACILITY NOW AVAILABLE



Patient's name : PRAVEEN KUMAR MALI
Age/Sex : 34 Years/Male
Referred by : -
Collection Time : 11:11

Reg. ID : P-677-21
Accession : 12842
Order Dt/time : 25/04/2022 11:11

Complete Blood Count

Sample Type: EDTA

Test Name	Result	Units	Biological Reference Interval
<u>Blood Counts</u>			
Haemoglobin :	13.5	Gms%	13.5 - 18.0
Total R.B.C. :	4.16	mill/c.mm	4.7 - 6.0
Total W. B. C. :	4,210	/cu mm	4000 - 10500
Platelet Count :	1,30,000	/cu.mm	1,50,000 - 4,50,000
<u>Differential Count</u>			
Neutrophils :	55	%	40 - 70
Lymphocytes :	40	%	20 - 40
Eosinophils :	03	%	1 - 4
Monocytes :	02	%	2 - 6
Basophils :	00	%	0 - 01
<u>Blood Indices</u>			
P. C. V :	41.0	%	42 - 52
M. C. V. :	98.6	fl	78 - 100
M.C.H :	32.4	pg	27 - 31
M. C. H. C :	32.9	%	32 - 36
R.D.W :	13.9	%	11.5 - 14.0
<u>E.S.R.(Westergren Method)</u>			
After one hour :	06	mm/hr	1 - 7

TESTS DONE ON FULLY AUTOMATED HEMATOLOGY ANALYZER.

Dr. Gayatri M. Mehta
M. D. (Patho)

Reg. No. G-32215

DR GAYATRI MEHTA
MD(PATHOLOGY)

DR. ANAND D. PARIKH
MD(PATHOLOGY)

LAB USE ONLY (Entered by :GM Enter Date/Time:25/04/2022 11:47:00 AM) (Verify by :GM Verify Date/Time:25/04/2022 11:47:00 AM)

ISO 9001:2015 Certified Diagnostics Center
Vidhi Imaging Center | Pathology Department

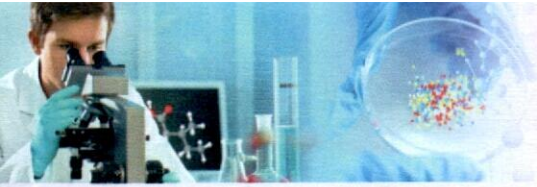L-86, Swatantra Senani Nagar, Opp. Akhbarnagar Petrol Pump, Nr. Akhbarnagar Circle, Nava-Vadaj, Ahmedabad - 380 013.

Ph. (Pathology) : 079-2764 5405, 8849893954 M. 98799 29406, 98250 09406, E-mail : vidhidiagnostics@gmail.com, Web. : www.vidhidiagnostics.com

Time (Pathology) : Mon. to Sat. 8.30 am to 8.00 pm, Sunday 9 am to 12 Noon

Pathology means science behind medicine

CT SCAN & CBCT FACILITY NOW AVAILABLE



Pathology Department



Patient's name : PRAVEEN KUMAR MALI
Age/Sex : 34 Years/Male
Referred by : -
Collection Time : 11:11

Reg. ID : P-677-21
Accession : 12842
Order Dt/time : 25/04/2022 11:11

Blood Group

Sample Type: EDTA sample.

Test Name	Result
BG :	" B "
RH :	NEGATIVE
Remarks	Done by forward grouping method.

Dr. Gayatri M. Mehta

M. D. (Patho)

Reg. No. G-32215

DR GAYATRI MEHTA
MD(PATHOLOGY)

DR. ANAND D. PARIKH
MD(PATHOLOGY)

LAB USE ONLY (Entered by :GM Enter Date/Time:25/04/2022 3:48:00 PM) (Verify by :GM Verify Date/Time:25/04/2022 3:48:00 PM)

ISO 9001:2015 Certified Diagnostics Center

Vidhi Imaging Center | Pathology Department

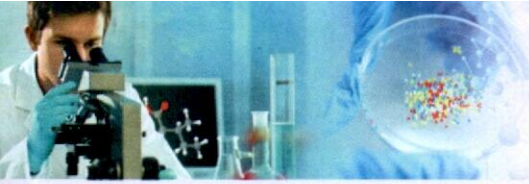L-86, Swatantra Senani Nagar, Opp. Akhbarnagar Petrol Pump, Nr. Akhbarnagar Circle, Nava-Vadaj, Ahmedabad - 380 013.

Ph. (Pathology) : 079-2764 5405, 8849893954 M. 98799 29406, 98250 09406, E-mail : vidhidiagnostics@gmail.com, Web. : www.vidhidiagnostics.com

Time (Pathology) : Mon. to Sat. 8.30 am to 8.00 pm, Sunday 9 am to 12 Noon

Pathology means science behind medicine

CT SCAN & CBCT FACILITY NOW AVAILABLE



Patient's name : PRAVEEN KUMAR MALI
 Age/Sex : 34 Years/Male
 Referred by : -
 Collection Time : 11:11

Reg. ID : P-677-21
 Accession : 12842
 Order Dt/time : 25/04/2022 11:11

Blood Glucose

Sample Type: Serum

Test Name	Result	Units	Biological Reference Interval
Fasting Blood Glucose : <i>GOD-POD Method.</i>	<u>150.5</u>	mg/dl	70 - 110

Blood Glucose

Sample Type: Serum

Test Name	Result	Units	Biological Reference Interval
Post Prandial Blood Glucose After 2hr. : <i>GOD-POD Method.</i>	<u>210.6</u>	mg/dl	80 - 140

Lipid Profile

Sample Type: Serum

Test Name	Result	Units	Biological Reference Interval
S. Cholesterol : <i>Oxidase-esterase method.</i>	<u>211.0</u>	mg/dl	0 - 200
S. Triglyceride : <i>Enzymatic Colorimetry method</i>	169.7	mg/dL	0 - 200
S. HDL - Cholesterol : <i>Serum by Enzymatic method.</i>	44.2	mg/dL	35 - 65
S. LDL - Cholesterol : <i>Serum by Enzymatic method</i>	<u>132.86</u>	mg/dL	0 - 130
S. VLDL - Cholesterol :	<u>33.94</u>	mg/dL	0 - 30
S. Chole/HDL.Ratio :	4.77		1 - 6
S. LDL / HDL Cholesterol Ratio :	3.01		0 - 3.5

Dr. Gayatri M. Mehta

M. D. (Patho)

Reg. No. G-32215

ISO 9001:2015 Certified Diagnostics Center

Vidhi Imaging Center | Pathology Department

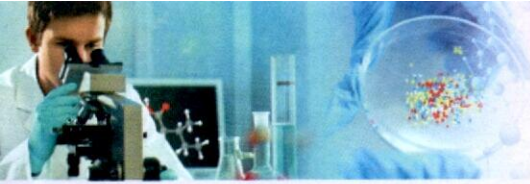L-86, Swatantra Senani Nagar, Opp. Akhbarnagar Petrol Pump, Nr. Akhbarnagar Circle, Nava-Vadaj, Ahmedabad - 380 013.

Ph. (FOR GAYATRI MEHTA) 5405, 8849893954 M. 98799 29406, 98250 09406, E-mail : vidhidiagnostics@ananddiparikh.com www.vidhidiagnostics.com

MD(PATHOLOGY)

Time (Pathology) : Mon. to Sat. 8.30 am to 8.00 pm, Sunday 9 am to 12 Noon

DR. ANAND DIPARIKH
MD(PATHOLOGY)*Pathology means science behind medicine***CT SCAN & CBCT FACILITY NOW AVAILABLE**



Pathology Department

Patient's name : PRAVEEN KUMAR MALI
Age/Sex : 34 Years/Male
Referred by : -
Collection Time : 11:11

Reg. ID : P-677-21
Accession : 12842
Order Dt/time : 25/04/2022 11:11

BIOCHEMISTRY

Sample type : Serum

Test Name	Result	Units	Biological Reference Interval
Urea , (Serum by GLDH method) :	18.5	mg/dl	10 - 50
S.Uric acid , (Serum by Uricase method) :	6.1	mg/dl	3.4 - 7.0
Bun :	8.6	mg/dl	6-20
Creatinine , (Serum by Enzymatic reaction) :	0.74	mg/dl	0.5-1.2
S.G.P.T (ALT) : (Serum by IFCC method)	18.4	U/L	0 - 40
S.G.O.T (AST) : (Serum by IFCC method)	29.2	U/L	0 - 37
ALK.PHOSPHATASE : (Serum by PNP method)	99.0	U/L	40-129
G.G.T :	16.2	U/L	8 - 78

BILIRUBIN

Total :	0.51	mg/dl	Up to 1.2
Direct :	0.24	mg/dl	0-0.7
Indirect :	0.27	mg/dl	0 - 0.5

SERUM PROTEINS

Total Protein (Serum by Biuret method) :	7.73	gms/dl	6.6 - 8.7
Albumin (Serum by BCG method) :	4.36	gms/dl	3.97-4.94
Globulins :	3.37	gms/dl	2.3 - 3.5
A/G Ratio :	1.294		0.9 - 2.9

Dr. Gayatri M. Mehta

M. D. (Patho)

Reg. No. G-32215
DR GAYATRI MEHTA
MD(PATHOLOGY)

DR. ANAND D. PARIKH
MD(PATHOLOGY)

LAB USE ONLY (Entered by :GM Enter Date/Time:25/04/2022 3:49:00 PM) (Verify by :GM Verify Date/Time:25/04/2022 3:49:00 PM)

ISO 9001:2015 Certified Diagnostics Center

Vidhi Imaging Center | Pathology Department

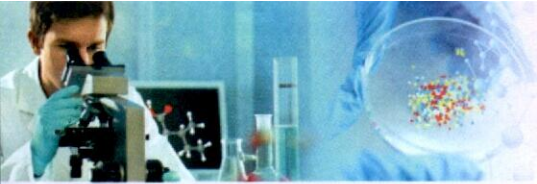L-86, Swatantra Senani Nagar, Opp. Akhbarnagar Petrol Pump, Nr. Akhbarnagar Circle, Nava-Vadaj, Ahmedabad - 380 013.

Ph. (Pathology) : 079-2764 5405, 8849893954 M. 98799 29406, 98250 09406, E-mail : vidhidiagnostics@gmail.com, Web. : www.vidhidiagnostics.com

Time (Pathology) : Mon. to Sat. 8.30 am to 8.00 pm, Sunday 9 am to 12 Noon

Pathology means science behind medicine

CT SCAN & CBCT FACILITY NOW AVAILABLE



Pathology Department



Patient's name : PRAVEEN KUMAR MALI
Age/Sex : 34 Years/Male
Referred by : -
Collection Time : 11:11

Reg. ID : P-677-21
Accession : 12842
Order Dt/time : 25/04/2022 11:11

HbA1C

Sample Type: Serum

Test Name	Result	Units	Biological Reference Interval
HbA1C :	6.5	%	Non-diabetic: 4.2-6.2 Pre-diabetic : 6.3-7.2 Diabetic : 7.3-8.2
Mean Blood Glucose of Last 03 months.	139.85	mg/dl	

Comment

*As per the new 2009 update of American Diabetes Association regarding HbA1C & Mean Blood Glucose relationship.

NOTE:

This test is used to monitor diabetic patients compliance with the therapeutic regimen and logo It's level is proportional to both the average blood glucose concentration and the life span of the red blood cells (RBC) in circulation. HbA1c values are free of day to day glucose fluctuations and are unaffected by exercise or recent food intake.

Dr. Gayatri M. Mehta

M. D. (Patho)

Reg. No. G-32215

DR GAYATRI MEHTA
MD(PATHOLOGY)

DR. ANAND D. PARIKH
MD(PATHOLOGY)

LAB USE ONLY (Entered by :GM Enter Date/Time:25/04/2022 3:49:00 PM) (Verify by :GM Verify Date/Time:25/04/2022 3:49:00 PM)

ISO 9001:2015 Certified Diagnostics Center

Vidhi Imaging Center | Pathology Department

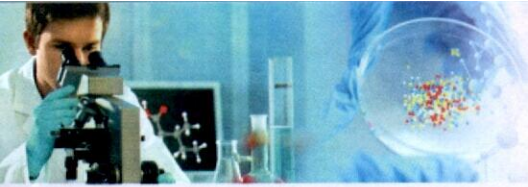L-86, Swatantra Senani Nagar, Opp. Akhbarnagar Petrol Pump, Nr. Akhbarnagar Circle, Nava-Vadaj, Ahmedabad - 380 013.

Ph. (Pathology) : 079-2764 5405, 8849893954 M. 98799 29406, 98250 09406, E-mail : vidhidiagnostics@gmail.com, Web. : www.vidhidiagnostics.com

Time (Pathology) : Mon. to Sat. 8.30 am to 8.00 pm, Sunday 9 am to 12 Noon

Pathology means science behind medicine

CT SCAN & CBCT FACILITY NOW AVAILABLE



Pathology Department



Patient's name : PRAVEEN KUMAR MALI
Age/Sex : 34 Years/Male
Referred by : -
Collection Time : 11:11

Reg. ID : P-677-21
Accession : 12842
Order Dt/time : 25/04/2022 11:11

Thyroid Function Test

Sample Type: Serum

Test Name	Result	Units	Biological Reference Interval
TOTAL T3 :	1.05	ng/ml	0.84 - 2.0
TOTAL T4 :	7.8	ug/dl	5.1 - 14.0
TSH(Ultra sensitive) :	1.472	mIU/L	0.27 - 4.2
Method	Electrochemiluminescence Immunoassay "ECLIA"		

Test done on Roche Cobas e411 Immunoassay Analyser

Dr. Gayatri M. Mehta

M. D. (Patho)

Reg. No. G-32215

DR GAYATRI MEHTA
MD(PATHOLOGY)

DR. ANAND D. PARIKH
MD(PATHOLOGY)

LAB USE ONLY (Entered by :GM Enter Date/Time:25/04/2022 3:50:00 PM) (Verify by :GM Verify Date/Time:25/04/2022 3:50:00 PM)

ISO 9001:2015 Certified Diagnostics Center

Vidhi Imaging Center | Pathology Department

L-86, Swatantra Senani Nagar, Opp. Akhbarnagar Petrol Pump, Nr. Akhbarnagar Circle, Nava-Vadaj, Ahmedabad - 380 013.

Ph. (Pathology) : 079-2764 5405, 8849893954 M. 98799 29406, 98250 09406, E-mail : vidhidiagnostics@gmail.com, Web. : www.vidhidiagnostics.com

Time (Pathology) : Mon. to Sat. 8.30 am to 8.00 pm, Sunday 9 am to 12 Noon

Pathology means science behind medicine

CT SCAN & CBCT FACILITY NOW AVAILABLE



Pathology Department



Patient's name : PRAVEEN KUMAR MALI
Age/Sex : 34 Years/Male
Referred by : -
Collection Time : 11:11

Reg. ID : P-677-21
Accession : 12842
Order Dt/time : 25/04/2022 11:11

Urine Analysis

Sample Type: Urine

Test Name	Result	Units	Biological Reference Interval
-----------	--------	-------	-------------------------------

Physical Examination

Quantity :	30	ml	0 - 500 ml
Colour :	Pale Yellow		Pale Yellow
Transparency :	Slight Turbid.		Clear
Reaction :	Acidic		4.6 - 8.0
Specific Gravity :	1.025		1.016 - 1.022
Sediment :	Present		

Chemical Examination

Albumin :	Present (Faint Trace)		Absent
Sugar :	NIL		Absent
Acetone :	Absent		Absent
Bile Salts :	Absent		Absent
Bile Pigments :	Absent		Absent
Urobilogen :	Absent		Absent
Nitrites :	Absent		Absent

Microscopic Examination

Red blood Cells :	Occasional	/h.p.f	Absent
Pus Cells :	1-2	/h.p.f	Absent
Epithelial Cells :	1-2	/h.p.f	< 10.0
Amorphous :	Absent	/h.p.f	Absent
Bacteria :	Absent	/h.p.f	Absent
Crystals :	Absent	/h.p.f	Absent
Casts :	Absent	/h.p.f	Absent
Fungus :	Not seen	/h.p.f	Absent

Dr. Gayatri M. Mehta

M. D. (Patho)

Reg. No. G-32215

DR GAYATRI MEHTA
MD(PATHOLOGY)

DR. ANAND D. PARIKH
MD(PATHOLOGY)

ISO 9001:2015 Certified Diagnostics Center

Vidhi Imaging Center | Pathology Department

LAB USE ONLY (Entered by: GM, Enter Date/Time: 25/04/2022 3:50:00 PM) (Verify by: GM, Verify Date/Time: 25/04/2022 3:50:00 PM)
L-86, Swatantra Senani Nagar, Opp. Akhbarnagar Petrol Pump, Nr. Akhbarnagar Circle, Nava-Vadaj, Ahmedabad - 380 013.

Ph. (Pathology) : 079-2764 5405, 8849893954 M. 98799 29406, 98250 09406, E-mail : vidhidiagnostics@gmail.com, Web : www.vidhidiagnostics.com

Time (Pathology) : Mon. to Sat. 8.30 am to 8.00 pm, Sunday 9 am to 12 Noon


Pathology means science behind medicine

CT SCAN & CBCT FACILITY NOW AVAILABLE



Dr. Vidhi D. Modh
MBBS
Reg. No. G-74540

Vidhi Diagnostics
L-86, Swatantra-Senani Nagar,
Opp. Akhbarnagar Bus Terminals,
Nr. Akhbarnagar Circle,
New Wadaj, Ahmedabad-13.



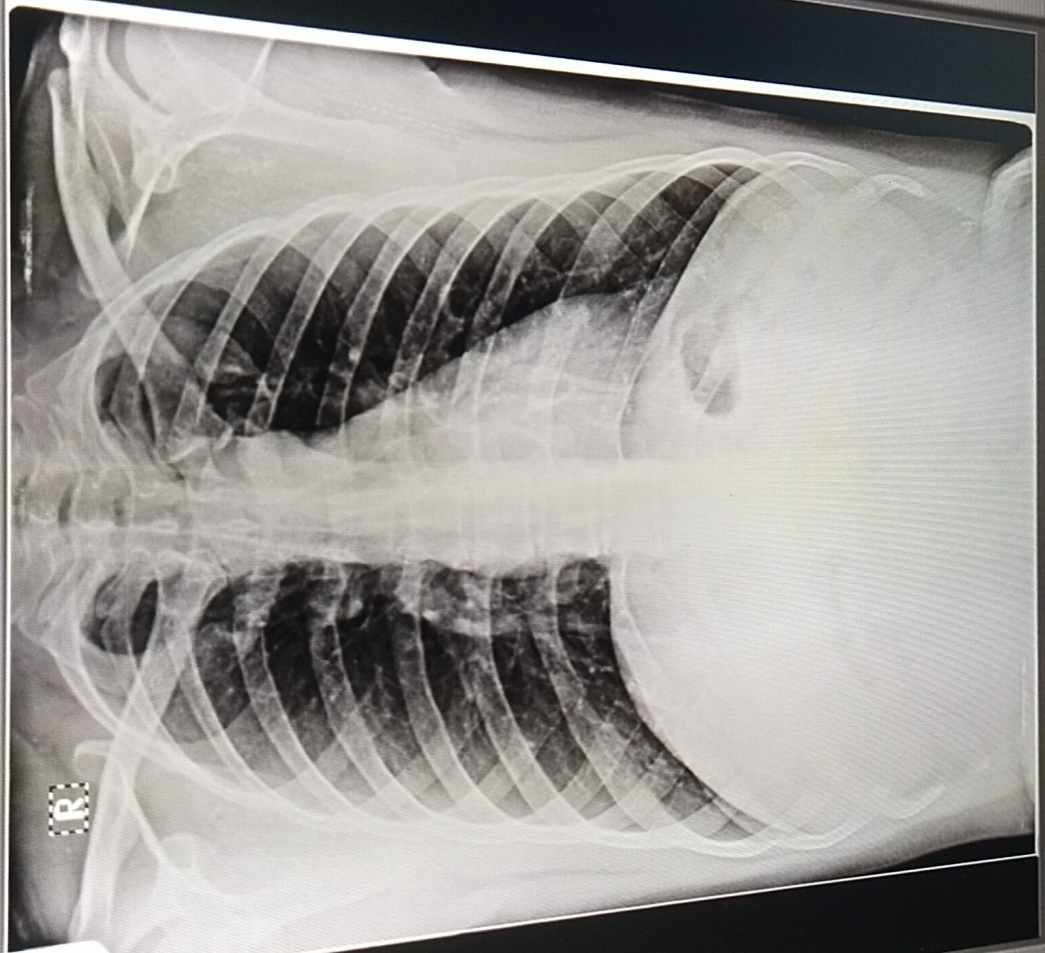
25 Apr 2022 11:11:09 AM
 54° NE
 Nirnay Nagar
 Ahmedabad
 Gujarat
 Altitude:-0.1m
 Index number: 2872

Dr. Vidhi D. Modh
 Reg. No. 174349

Vidhi Diagnostics
 L-86, Swatantra-Senani Nagar,
 Opp. Akhbarnagar Bus Terminals,
 Nr. Akhbarnagar Circle,
 New Wadaj, Ahmedabad-13

PRAVEENKUMAR MALI

042208



1 (1)



DELL

In Chronic Pain...
Zix-R OD
Capsules
Aceclofenac 200 mg SR + Rabeprazole 20 mg
Relieves Pain... without Acidity

