



# YASHFEEN CARDIAC HOSPITAL™

At. & Po. Viraval, Navsari. 396 445. Phone (H) (02637) 235725

Website : www.yashfeenhospital.in E-mail : info@yashfeenhospital.in

(For Laboratory Reports Only)



Patient Name : TARUNKUMAR VIKRAMBHAI PATEL Age : 40 Years Sex : M  
Ref By Dr. : - Area : Kangvai Date : 29/07/2023  
Sample Time : 29/07/2023 09:25 No : 13 Time : 1:47PM

## HAEMOGRAM

Test	Findings	UOM	Normal Range
------	----------	-----	--------------

HAEMOGLOBIN	12.9	gm/dl	M-13.5-17.0 F-11.5-15.5
-------------	------	-------	----------------------------

<b>HAEMOGRAM</b> RED BLOOD CELL	<b>7.55</b>	10 <sup>6</sup> /μL	3.76 - 5.70
------------------------------------	-------------	---------------------	-------------

TOTAL LEUCOCYTE COUNT	5900	cells/cumm	4,000-11,000
-----------------------	------	------------	--------------

### Differential Count

Neutrophil	61	%	40-75
Lymphocytes	30	%	20-40
Eosinophil	2	%	1-6
Monocytes	7	%	2-10
Basophils	0	%	0-0

PLATELET COUNT	262000	lacs/cumm	1.5-5.5 Lacs
----------------	--------	-----------	--------------

### RBC INDICES

P.C.V.	41.4	%	M-40-56% F-37-47%
M.C.V.	<b>54.8</b>	cu/microns	76-94
M.C.H.	<b>17.1</b>	pg	27-30
M.C.H.C.	31.3	-	30-35

BLOOD GROUP	" O "	-	-
RH FACTOR	POSITIVE	-	-

E.S.R.(1 hour)	<b>14</b>	mm/hr.	M-5-10, F-5-20
----------------	-----------	--------	----------------



### Remarks

Designed By : Sarita Infotech Pvt. Ltd., Navsari

Yashfeen Cardiac Hospital

*P. Chandhasi*  
Dr. PIYUSH B. CHAUDHARI  
M.D. Medicine

Reg. No. G-21518

Signature

Thanks for Reference

Technician



# YASHFEEN CARDIAC HOSPITAL™

At. & Po. Viraval, Navsari. 396 445. Phone (H) (02637) 235725

Website : [www.yashfeenhospital.in](http://www.yashfeenhospital.in) E-mail : [info@yashfeenhospital.in](mailto:info@yashfeenhospital.in)

(For Laboratory Reports Only)



Patient Name : TARUNKUMAR VIKRAMBHAI PATEL      Age : 40 Years      Sex : M  
Ref By Dr. : -      Area : Kangvai      Date : 29/07/2023  
Sample Time : 29/07/2023 09:27      No : 13      Time : 1:47PM

## BIOCHEMICAL TEST REPORT

Test	Findings	UOM	Normal Range
S.CREATININE	0.9	mg/dL	M .0.9-1.4 , F. 0.8-1.2
S.URIC ACID	4.6	mg/dL	Male:3.5-7.2, Female:2.6-6.0
BLOOD UREA NITROGEN	6.5	mg/dL	4.7-23.0



*P. Chaudhari*  
Dr. PIYUSH B. CHAUDHARI  
M.D. Medicine  
Reg. No. G-21518

### Remarks

Designed By : Sarita Infotech Pvt. Ltd., Navsari

Yashfeen Cardiac Hospital

*P. Chaudhari*  
signature

*Thanks for Reference*

Technician



# YASHFEEN CARDIAC HOSPITAL™

At. & Po. Viraval, Navsari. 396 445. Phone (H) (02637) 235725

Website : [www.yashfeenhospital.in](http://www.yashfeenhospital.in) E-mail : [info@yashfeenhospital.in](mailto:info@yashfeenhospital.in)

(For Laboratory Reports Only)



Patient Name : TARUNKUMAR VIKRAMBHAI PATEL  
Ref By Dr. : -  
Sample Time : 29/07/2023 09:28 No : 13

Age : 40 Years Sex : M  
Area : Kangvai Date : 29/07/2023  
Time : 1:47PM

## LIPID PROFILE TEST REPORT

Test	Findings	UOM	Normal Range
S.CHOLESTEROL	147.4	mg/dL	<200:Desirable, 200-239:Borderline High, >=240:High
HDL CHOLESTEROL	41.9	mg/dL	<40:Low(High Risk), >=60:High(Low Risk)
LDL CHOLESTEROL	<b>110.1</b>	mg/dL	<100: Optimal, 100-129: Nearoptimal/ Aboveoptimal, 130-159:BorderlineHigh,16 0-189:High,>=190:Very
VLDL CHOLESTEROL	13.2	mg/dL	UPTO 40
S.TRIGLYCERIDES	65.9	mg/dL	<150:Normal, 150-199:Borderline High,200-499:High, >=500:Very Hi
CHOL/ HDL RATIO	3.5	mg/dL	LESS THAN 5
LDL/ HDL RATIO	2.6	mg/dL	LESS THAN 5
REMARK	-	-	



*P. Chaudhari*  
Dr. PIYUSH B. CHAUDHARI  
M.D. Medicine  
Reg. No. G-21518

### Remarks

Designed By : Sarita Infotech Pvt. Ltd., Navsari

Yashfeen Cardiac Hospital

*Retu*  
Signature

*Thanks for Reference*

Technician



# YASHFEEN CARDIAC HOSPITAL™

At. & Po. Viraval, Navsari. 396 445. Phone (H) (02637) 235725

Website : [www.yashfeenhospital.in](http://www.yashfeenhospital.in) E-mail : [info@yashfeenhospital.in](mailto:info@yashfeenhospital.in)

(For Laboratory Reports Only)



Patient Name : TARUNKUMAR VIKRAMBHAI PATEL      Age : 40 Years      Sex : M  
Ref By Dr. : -      Area : Kangvai      Date : 29/07/2023  
Sample Time : 29/07/2023 09:28      No : 13      Time : 1:47PM

## LIVER FUNCTION TEST REPORT

Test	Findings	UOM	Normal Range
TOTAL BILIRUBIN	0.6	mg/dL	0-1.0
DIRECT BILIRUBIN	0.3	mg/dL	0-0.8
INDIRECT BILIRUBIN	0.3	mg/dL	0-0.2
SGPT	13.0	U/L	Below 40.0
S.ALKALINE PHOSPHATASE	61.3	U/L	CH . 170.0-515.0 A. 37.0-147.0
TOTAL PROTEIN	7.2	g/dl	6.0-8.0
ALBUMIN	5.0	g/dl	3.0-5.0
GLOBULIN	<b>2.2</b>	g/dl	3.0-3.5
A/G	2.3	g/dl	
SGOT	15.4	U/L	Below 40.0



*P. Chaudhari*  
Dr. PIYUSH B. CHAUDHARI  
M.D. Medicine  
Reg. No. G-21518

### Remarks

Designed By : Sarita Infotech Pvt. Ltd., Navsari

Yashfeen Cardiac Hospital

*Reth*  
signature

*Thanks for Reference*

Technician



# YASHFEEN CARDIAC HOSPITAL™

At. & Po. Viraval, Navsari. 396 445. Phone (H) (02637) 235725

Website : [www.yashfeenhospital.in](http://www.yashfeenhospital.in) E-mail : [info@yashfeenhospital.in](mailto:info@yashfeenhospital.in)

(For Laboratory Reports Only)



Patient Name : TARUNKUMAR VIKRAMBHAI PATEL  
Ref By Dr. : -  
Sample Time : 29/07/2023 09:28 No : 13

Age : 40 Years Sex : M  
Area : Kangvai Date : 29/07/2023  
Time : 1:47PM

## HAEMOGLOBIN A1 C ESTIMATION

Test	Findings	UOM	Normal Range
Hb A1C	5.6	%	>8 :Action Suggested, 7-8 :Good Control, <7 :Goal, 6-7 :Near Normal Glycemia, <6 :Non-diabetic Level
<b>Technique</b> METHOD - HPLC			
Mean Blood Glucose	113.7	mg/dL	



*P. Chaudhari*  
Dr. PIYUSH B. CHAUDHARI  
M.D. Medicine  
Reg. No. G-21518

### Remarks

Designed By : Sarita Infotech Pvt. Ltd., Navsari

Yashfeen Cardiac Hospital

*Retu*  
Signature

*Thanks for Reference*

Technician



# YASHFEEN CARDIAC HOSPITAL™

At. & Po. Viraval, Navsari. 396 445. Phone (H) (02637) 235725  
Website : www.yashfeenhospital.in E-mail : info@yashfeenhospital.in  
(For Laboratory Reports Only)



Patient Name : TARUNKUMAR VIKRAMBHAI PATEL Age : 40 Years Sex : M  
Ref By Dr. : - Area : Kangvai Date : 29/07/2023  
Sample Time : 29/07/2023 09:28 No : 13 Time : 1:47PM

## THYROID FUNCTION TEST REPORT

Test	Findings	UOM	Normal Range
T3 (TRIODOTHYRONINE)	1.04	ng/ml	NEWBORNS:0.73-2.88 6DAYS-3MONTHS:0.80-2.75 4-12MONTHS:0.86-2.65 1-6YEARS:0.92-2.48 7-11YEARS:0.93-2.31 12-20YEARS:0.91-2.18 ADULT:0.80-2.00
T4(THYROXINE)	6.11	µg/dl	NEWBORNS:5.04-18.5, 6DAYS-3MONTHS:5.41-17.0, 4-12 MONTHS:5.67-16.0, 1-6YEARS:5.95-14.7, 7-11 YEARS:5.99-13.8, 12-20 YEARS:5.91-13.2, ADULTS:5.10-14.1
TSH	<b>38.02</b>	µIU/ml	NEWBORNS:0.70-15.2, 6DAYS-3MONTHS:0.72-11.0, 4-12MONTHS:0.73-8.35, 1-6YEARS:0.70-5.97, 7-11YEARS:0.60-4.84, 12-20YEARS:0.51-4.30, ADULTS:0.27-4.20

### TECHNIQUE

ELECTROCHEMILUMINESCENCE



P. Chaudhari  
Dr. PIYUSH B. CHAUDHARI  
M.D. Medicine  
Reg. No. G-21518

### Remarks

Designed By : Sarita Infotech Pvt. Ltd., Navsari

Yashfeen Cardiac Hospital

signature

Thanks for Reference

Technician



# YASHFEEN CARDIAC HOSPITAL™

At. & Po. Viraval, Navsari. 396 445. Phone (H) (02637) 235725

Website : www.yashfeenhospital.in E-mail : info@yashfeenhospital.in

(For Laboratory Reports Only)



Patient Name : TARUNKUMAR VIKRAMBHAI PATEL  
Ref By Dr. : -  
Sample Time : 29/07/2023 09:28 No : 13

Age : 40 Years Sex : M  
Area : Kangvai Date : 29/07/2023  
Time : 1:47PM

## ROUTINE URINE ANALYSIS

Test	Findings	UOM	Normal Range
------	----------	-----	--------------

### PHYSICAL EXAMINATION

Quantity	-	-
Colour	YELLOW	-
Appearance	CLEAR	-
Reaction	<b>ALKALINE</b>	-
Sp. Gravity	1.002	-

### CHEMICAL EXAMINATION

U.Albumin	NIL	-
Sugar	NIL	-
Acetone	NIL	-
Bile Salt	NIL	-
Bile Pigment	NIL	-
Occult Blood	NIL	-

### MICROSCOPIC EXAMINATION

Pus Cells	1-2	/hpf
Epithelial cells	1-2	/hpf
Red cells	ABSENT	/hpf
Casts	-	/hpf
Crystals	<b>AMORPHOUS SEEN</b>	/hpf
Others	-	/hpf



*P. Chaudhari*  
Dr. PIYUSH B. CHAUDHARI  
M. D. Medicine  
Reg. No. G-21518

### Remarks

Designed By : Sarita Infotech Pvt. Ltd., Navsari

Yashfeen Cardiac Hospital

*Reten*  
Signature

*Thanks for Reference*


Technician



# YASHFEEN CARDIAC HOSPITAL™

At. & Po. Viraval, Navsari. 396 445. Phone (H) (02637) 235725

Website : [www.yashfeenhospital.in](http://www.yashfeenhospital.in) E-mail : [info@yashfeenhospital.in](mailto:info@yashfeenhospital.in)  
(For Laboratory Reports Only)



Patient Name : TARUNKUMAR VIKRAMBHAI PATEL Age : 40 Years Sex : M  
Ref By Dr. : - Area : Kangvai Date : 29/07/2023  
Sample Time : 29/07/2023 09:28 No : 13 Time : 1:47PM

## GGT TEST REPORT

Test	Findings	UOM	Normal Range
SERUM GGT	40	U/L	10-71 U/L



*P. Chaudhari*  
Dr. PIYUSH B. CHAUDHARI  
M.D. Medicine  
Reg. No. G-21518

### Remarks

Designed By : Sarita Infotech Pvt. Ltd., Navsari

Yashfeen Cardiac Hospital

*Retu*  
signature

*Thanks for Reference*

Technician






# YASHFEEN CARDIAC HOSPITAL™

At. & Po. Viraval, Navsari. 396 445. Phone (H) (02637) 235725

Website : [www.yashfeenhospital.in](http://www.yashfeenhospital.in) E-mail : [info@yashfeenhospital.in](mailto:info@yashfeenhospital.in)

(For Laboratory Reports Only)



Patient Name : TARUNKUMAR VIKRAMBHAI PATEL  
Ref By Dr. : -  
Sample Time : 29/07/2023 09:28 No : 13

Age : 40 Years Sex : M  
Area : Kangvai Date : 29/07/2023  
Time : 1:48PM

## BLOOD SUGAR TEST REPORT

Test	Findings	UOM	Normal Range
FASTING BLOOD SUGAR	91.4	mg/dL	70-110
FASTING URINE SUGAR	NIL	-	NIL
POSTPANDRIAL BLOOD SUGAR	84.0	mg/dL	70-140
POSTPANDRIAL URINE SUGAR	NIL	-	NIL



*P. Chaudhari*  
Dr. PIYUSH B. CHAUDHARI  
M.D. Medicine  
Reg. No. G-21518

### Remarks

Designed By : Sarita Infotech Pvt. Ltd., Navsari

Yashfeen Cardiac Hospital

*P. Chaudhari*  
signature

*Thanks for Reference*

Technician

TARUNKUMAR ,  
ID:  
DOB:  
40 Years , ,  
Male ,Unknown  
Med.:  
Location:  
Referring Physician:  
Notes:

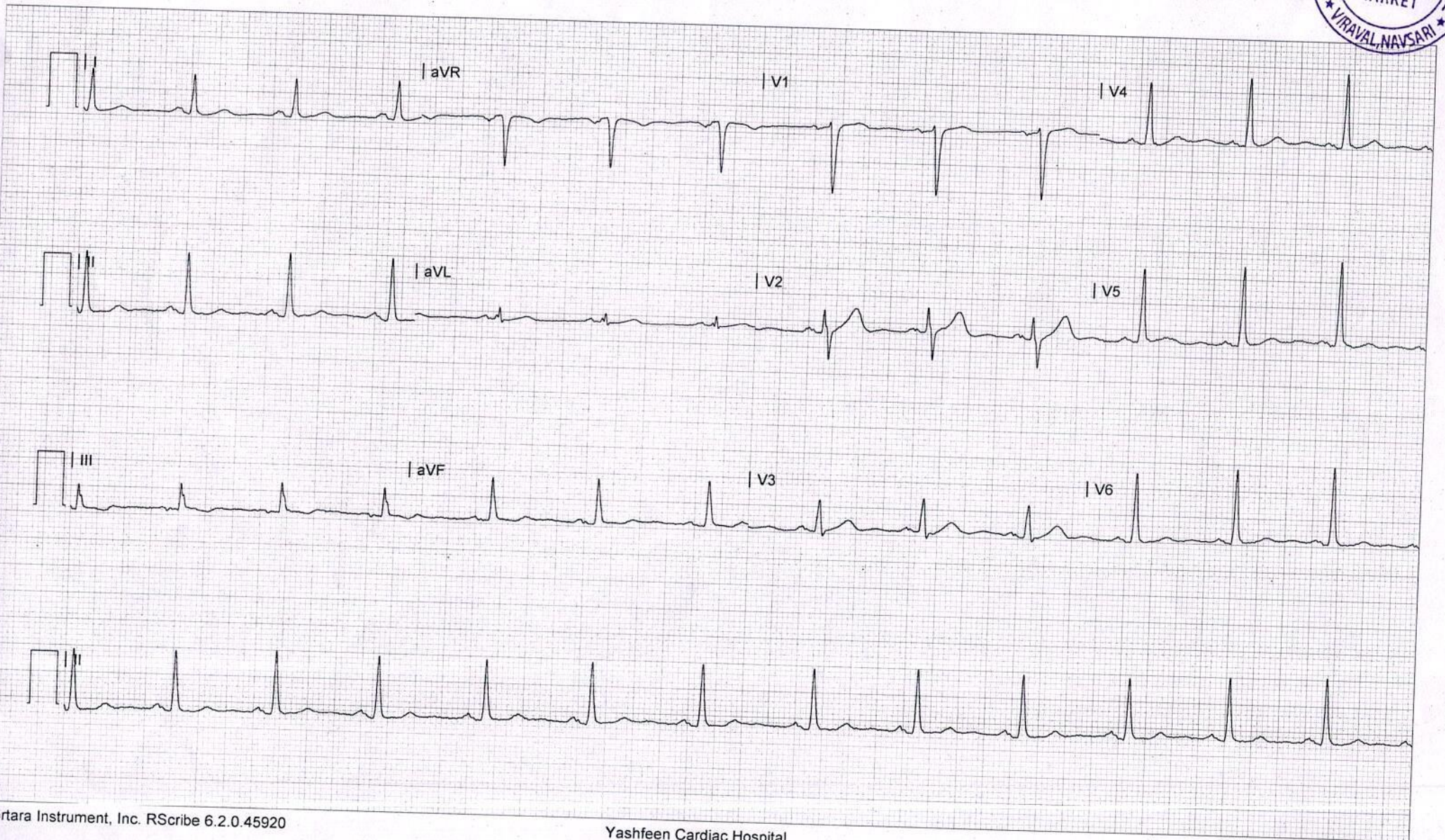
29-07-2023 10:30:49

Vent. Rate: 77 BPM  
PR int: 136 ms  
QRS dur: 97 ms  
QT/QTc: 336/368 ms  
P-R-T axes: 25 56 46  
Avg. RR: 774 ms  
QTcB: 381 ms  
QTcF: 365 ms

SINUS RHYTHM  
NONSPECIFIC T-WAVE ABNORMALITY  
BORDERLINE ECG

UNCONFIRMED REPORT  
Reviewed by:

Signed by:  
Date:





# YASHFEEN CARDIAC HOSPITAL

## EYE DEPARTMENT

Chief Complaint :

Rosher Chakrey

Medical History : ~~DM / HT / Asthama / Allergy / Heart / Thyroid~~

Ocular History :

Visual Acuity :

6/6  
6/6

NAME

29\_JUL\_2023 PM 12:05  
NO. 7766  
SN: 4771998

REF. DATA

VD: 12.00 CYL: MIX

<R> S C A  
- 0.25 - 0.25 26  
- 0.25 - 0.25 26  
- 0.25 - 0.50 26  
- 0.25 - 0.25 26  
S. E. - 0.50

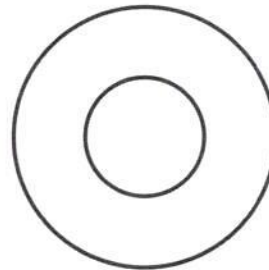
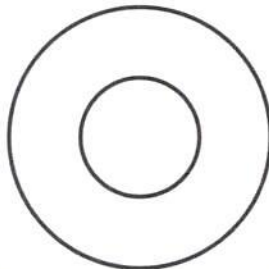
<L> S C A  
- 0.00 - 0.50 100  
- 0.00 - 0.50 100  
- 0.00 - 0.50 100  
- 0.00 - 0.50 100  
S. E. - 0.25

TOP :

	RIGHT EYE (PH.....)				LEFT EYE	
	Sph.	Cyl.	Axis	V/A	Sph.	Cyl.
Distance	Plan			6/6	Plan	6/6
Near				+1.00 Dm		nil

Distance/Reading/Bi-Focal/Progressive/Separate Glasses

Sle :



Abv  
Reg Pres  
After 1 year



ms

JS

# YASHFEEN IMAGING & RADIOLOGY DEPARTMENT

MANAGED BY :- YASHFEEN FOUNDATION

VIRAVAL, NAVSARI. 396 445. PHONE : (H) (02637) 235725

Website : [www.yashfeenhospital.in](http://www.yashfeenhospital.in) E-mail : [info@yashfeenhospital.in](mailto:info@yashfeenhospital.in)

Name	TARUNKUMAR V. PATEL	Age	40Y/M
Ref by Dr	SELF	Date	29/07/2023

## USG ABDOMEN (SCREENING)

**Liver** appears normal in size & shape with normal echopattern.  
No e/o focal or diffuse lesion. IHBR appear normal.  
PV and CBD appear normal.

**Gall bladder** appears distended & normal in shape & size. No e/o calculus or mass seen.  
Walls appear normal.

**Pancreas** appears normal in size and echogenicity. No e/o focal or diffuse lesion.

**Spleen** appears enlarged in size 12.2 cm and shows normal echopattern. No e/o focal lesion.

**Both Kidneys** appear normal in size and echopattern. CM Differentiation is preserved.  
No e/o calculus or hydronephrosis on either side.  
Perirenal spaces appear normal on either side.  
Suprarenal regions appear normal on either side. No e/o mass lesion.

**Bladder** is physiologically distended. No e/o calculus or mass. Walls appear normal.

**Prostate** appears normal in size & normal echopattern.  
No e/o calcification.

RIF region appears normal.

No e/o ascites.

**IMPRESSION:**  
Mild splenomegaly.



Dr. DHARMESH DESAI

(M.D. Radiology)

Reg.No.G - 45284

Dr. Dharmesh Desai  
YASHFEEN GROUP OF HOSPITAL  
MD

Please contact immediately for any typographical error.

This is only professional opinion, not a final diagnosis. Kindly correlate clinically. Not valid for medical/legal purpose.



# YASHFEEN CARDIAC HOSPITAL™

MANAGED BY :- YASHFEEN FOUNDATION

VIRAVAL, NAVSARI. 396 445. PHONE : (H) (02637) 235725

Website : www.yashfeenhospital.in E-mail : info@yashfeenhospital.in



(Regd. No. E / 1390 / Navsari)

## 2D ECHO CARDIOGRAPHY COLOUR DOPPLER REPORT

Patient Name & No	: TARUNKUMAR VIKRAMBHAI PATEL CH230160:	Age/Sex	UHID :	: 1906
Doctor	: Mohil Nagad	40/ M	No :	: 1942
Referred By	:		Date :	: 29/07/2023

### M-Mode findings

LVIDd : 45mm  
 LVIDs : 30mm  
 IVSd : 09mm  
 PWd : 08mm  
 EF : 60%  
 Aorta : 22mm  
 LA : 30mm

### 2D Imaging

Aortic Valve : Trileaflet, Peak Gradient 5mm of Hg.  
 Mitral Valve : Thin, Pliable, Normal Mobility, Normal function  
 Tricuspid Valve : Trace TR, RVSP: 15+ RAP  
 Pulmonary Valve : Normal

=> : All cardiac chambers are normal sized.  
 => : No regional wall motion abnormality.  
 => : Normal LV systolic function.  
 => : Normal LV diastolic function.  
 => : IAS/IVS intact.  
 => : No obvious clots/ vegetations/ or effusion.  
 => : IVC Normal size.

### Doppler Findings

=> : No MS/MR, No TS/Trace TR, No AS/AR & No PS/PR  
 Mitral inflow Pattern : E > A  
 Tissue Doppler Findings : E' > A'

Impression : Normal LVEF:60%, No RWMA.



Report Prepared By

**DR. MOHIL NAGAD**  
 M.D. Medicine, M.M. Cardiology  
 Senior Consultant - Interventional Cardiology  
 Report Checked By  
 Reg. No. G-10993 Sheikh  
 M.D. (Phy), D.L.C., NAVSARI  
 YASHFEEN HOSPITAL, NAVSARI  
 Non-Invasive Cardiologist

# YASHFEEN IMAGING & RADIOLOGY DEPARTMENT

MANAGED BY :- YASHFEEN FOUNDATION

VIRAVAL, NAVSARI. 396 445. PHONE : (H) (02637) 235725

Website : [www.yashfeenhospital.in](http://www.yashfeenhospital.in) E-mail : [info@yashfeenhospital.in](mailto:info@yashfeenhospital.in)

Patient's Name:	TARUNKUMAR V. PATEL	Age & Sex:	40Yrs/M
Ref. by Dr.	SELF	Date:	29-07-2023

## X RAY CHEST (PA VIEW)

Both lung fields appear normal.

Both hila appear normal.

Both CP angles appear clear.

Cardiac size appears within normal limit.

Both domes of diaphragm appear normal.

Bony thoracic cage appears normal.

### IMPRESSION:

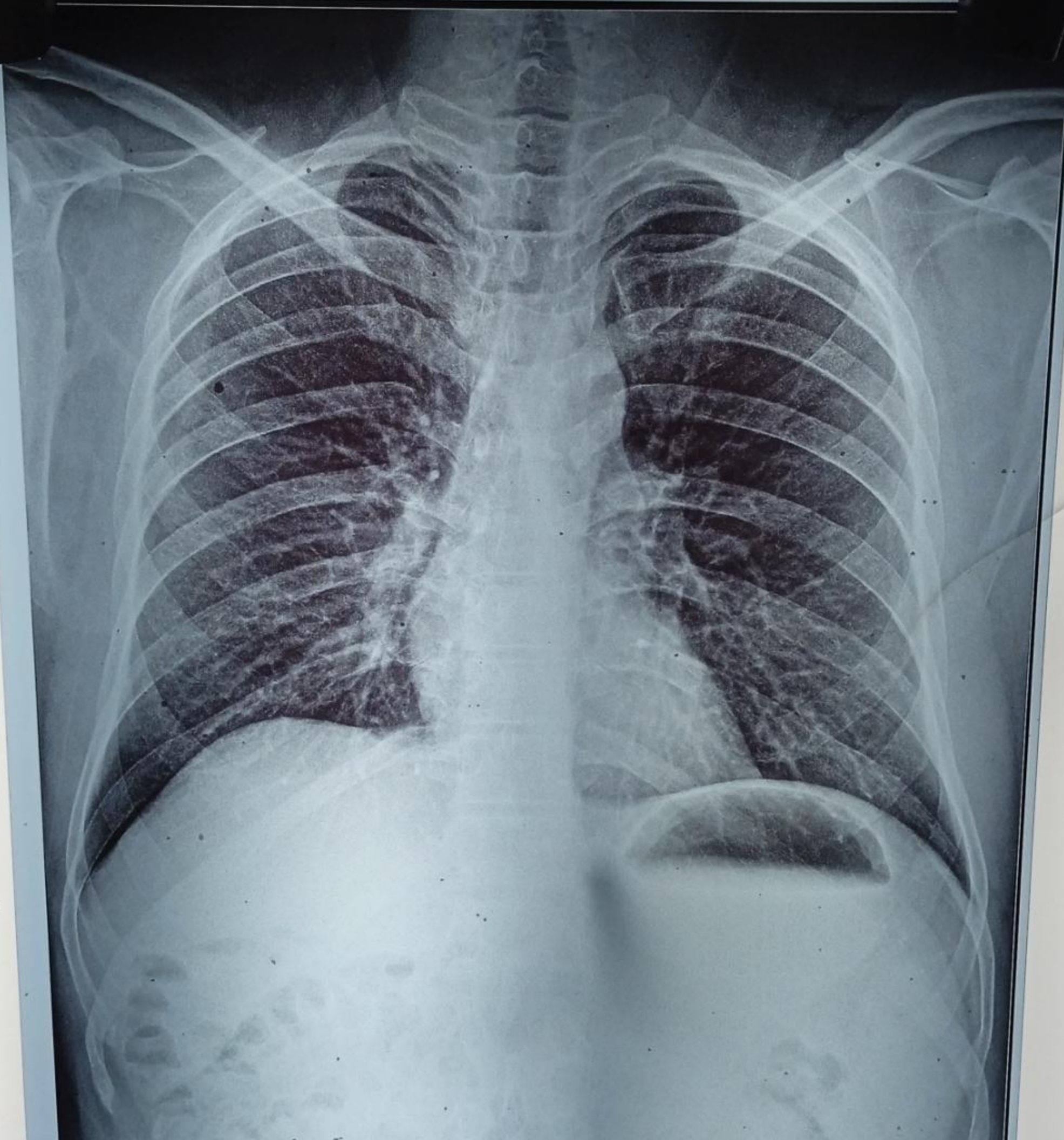
- Normal X-ray chest (PA view).



*DM*  
Dr. DHARMESH DESAI  
(M.D. Radiology)  
Reg. No. G - 45284  
MP  
YASHFEEN GROUP OF HOSPITAL

Please contact immediately for any typographical error.

This is only professional opinion, not a final diagnosis. Kindly correlate clinically. Not valid for medicolegal purpose.



CH23016030 TARUNKUMAR V PATEL 40Y 290723802 ChestErect  
YASHFEEN GROUP OF HOSPITALS NAVSARI PH:9924047789