

DAKSH HOSPITAL

396 - 397, Gandhi Nagar, Scheme No. 8, ALWAR -301001

Ref. No.

Date.....

MEDICAL EXAMINATION REPORT
Mediwheel (BOB)

Name: Mrs. Prem Yadav

Age: 48 yrs Sex: Female

Date: 26/08/2023

General Physical ExaminationHeight : 158 cm
Pulse : 62 /mt
Respiration : 18 /mtWeight : 65 kg
BP : 110/70 mm/hg
BMI : 26 kg/m²**Systemic Exam:-**

Normal

Dental Check up :-

Normal

Eye check-up :-

Normal

Skin Check up:-

Normal

ENT Check up:-

Normal

Gynae Check up:-

Menopausal

Impression:-

to multiple joint pain & swelling

Recommendation:-

RA factor / CRP / ANA / ACP

Dr. Mukesh Kumar Gupta
MD Gen. Medicine
Reg. No 5423/16262डॉ० मुकेश गुप्ता
M.D.F.C.C.S.
फिजिशियन एवं मधुमेह रोग विशेषज्ञ
दक्ष हॉस्पिटल, अलवर
रजि० नं०-5423/16262

Results

Run Date 26/08/2023 10:06:46 AM

Operator DAKSH

Last Name

Sample ID 5

First Name MRS PREM YADAV

Department

Gender Female Age

Physician DR. MUKESH GUPTA M.D

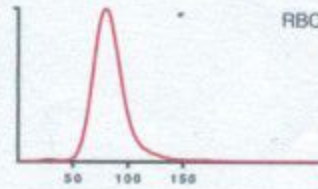
Patient ID AUTO_PID15545

Type Woman


Date of birth

Sample comments

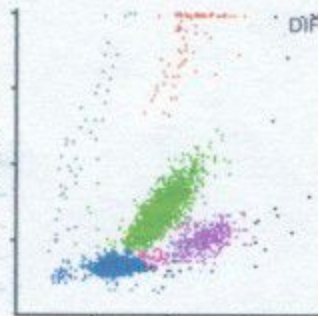
			Range
RBC	4.19 *	10 ⁶ /μL	3.80 - 5.50
HGB	11.9	g/dL	11.5 - 15.2
HCT	38.0 *	%	35.0 - 46.0
MCV	90.7 *	μm ³	77.0 - 97.0
MCH	28.3	pg	26.0 - 34.0
MCHC	31.2 L	g/dL	32.0 - 35.0
RDW-CV	15.5	%	11.0 - 17.0
RDW-SD	51.0 h	μm ³	37.0 - 49.0



			Range
PLT	231	10 ³ /μL	150 - 450
PCT	0.28	%	0.15 - 0.40
MPV	11.9 h	μm ³	8.0 - 11.0
PDW	21.3	μm ³	11.0 - 22.0
P-LCC	109	10 ³ /μL	44 - 140
P-LCR	47.1	%	18.0 - 50.0



			Range
WBC	7.19	10 ³ /μL	3.50 - 10.00
	#	Range	%
NEU	3.32	1.60 - 7.00	46.4
LYM	3.39 h	1.00 - 3.00	47.5 h
MON	0.18 l	0.20 - 0.80	2.5
EOS	0.15	0.00 - 0.50	2.1
BAS	0.11	0.00 - 0.15	1.5 h
LIC	0.04	0.00 - 0.10	0.5



Dr. R.S. Gupta

Dr. R.S. GUPTA
MD (Pathology) (MAHE)
RMC No. 7924/19778

Date :-26/08/2023

Name :- MRS. PREM YADAV

Age & Sex :- 47Yrs/ Female

Refd. :- Dr Mukesh Gupta M.D.

	TEST NAME	RESULT	REFERENCE RANGE	
	ESR		10 00 -20 mm/hrs	
	Blood Group & Rh Factor	A* POSITIVE		
	HbA1C	4.9	4 - 5.6%	
	Blood Sugar (F)	88.2	< 70 - 100 mg/dl	
	Blood Sugar (PP)	105.1	< 140 mg/dl	
	Urine Sugar (F)	NIL	-	
	Urine Sugar (PP)	NIL	-	
LIVER	S.Bilirubin Total	0.85	0.30 - 1.20 mg/dl	
	S.Bilirubin Direct	0.20	0.10 - 0.30 mg/dl	
	S.Bilirubin Indirect	0.65	0.30 - 0.90 mg/dl	
	S.G.O.T.	23	> 37 u/l	
	S.G.P.T.	30	> 40 u/l	
	S.Alk. Phosp.	179	80 - 306 u/l	
	G.G.T.	27	5 -40 u/l	
	Total Protein	7.0	6.5 - 8.5 gm/dl	
	Albumin	4.0	3.8 - 5.4 gm/dl	
	Globulin	3.0	2.3 - 3.5 gm/dl	
	A/G Ratio	1.3	-	
AST/ALT Ratio	0.7	-		
KIDNEY	Blood Urea	27.2	15 -45 mg/dl	
	S.Creatinine	0.86	0.60 - 1.30 mg/dl	
	BUN	15.0	6 -24 mg/dl	
	S.Uric Acid	4.9	M 3.1 - 7.0, F 2.5 - 5.6 mg/dl	
	BUN/Creatinine Ratio	17.4	-	
LIPID PROFILE	Total Cholesterol	170	Up to 200 mg/dl	
	S.HDL	43	30 - 70 mg/dl	
	S.LDL	101	Up to 170 mg/dl	
	S.VLDL	26	5.0 - 40 mg/dl	
	S. Triglycerides	130	Up to 170 mg/dl	
	LDL/HDL Ratio	2.3	-	
	Total Cholesterol/ HDL Ratio	3.9	-	
THYROID	T3	70.1	40 - 181 ng/dl	
	T4	6.8	4.6 - 10.5 µg/dl	
	TSH	5.51	0.30 - 5.0 mIU/l	
URINE EXAMINATION			Microscopic Examination :	
General/Chemical Examination:	Colour	Pale Yellow	RBC	Absent
	Reaction	Acidic	WBC	3 - 4
	Specific Gravity	QNS	Epithelial Cells	1 - 2
	Appearance	Clear	Cast	Absent
	Albumin	Nil	Crystal	Absent
	Sugar	Nil	Spermatozoa	Absent
			Amorphous Sediments	Absent
			Other	Absent
X-RAY CHEST	NORMAL STUDY			
STOOL EXAMINATION			Microscopic Examination :	
General/ Chemical Examination:	Colour	-	RBC	-
	Consistency	-	WBC	-
	PH	-	Ova & Parasites	-
	Reducing Substances	-		

Dr. R.S. GUPTA
 Doctor (Pathology) (MAHE)
 RMC No. 7924/19778

TECHNOLOGIST

Date :- 26/08/2023

Name :- Mrs. Prem Yadav

Refd. :- Dr Mukesh Gupta MD


Age & Sex :- 48Yrs/ Female

CYTO-PATHOLOGY

PAP SMEAR

1. Specimen type	Received two conventional smears.
2. Specimen adequacy	Smears are satisfactory for evaluation.
3. Microscopic finding	Smears are moderately cellular comprises of predominantly intermediate with mature superficial squamous epithelial cells arranged in clusters & scattered singly.
4. Inflammation	Not seen
5. Bacilli	Not seen
6. Endocervical cells	Not seen
7. Koilocytic changes	Not seen
8. Trichomonas	Not seen
9. Dysplasia	Nil
10. Neoplasia	Nil
11. Endometrial cells	Nil

Impression:- Negative for intraepithelial lesion or malignancy


Dr. R.S. GUPTA
MD (Pathology) (MAHE)
BMC No. 7924/19778
Doctor


TECHNOLOGIST



दक्ष हॉस्पिटल

396, गाँधी नगर स्कीम नं.8, अलवर (राज०) ☎ 0144-2703340

Sonography / 2D Echo Cardiography / Doppler Report

NAME :- MRS PREM YADAV/F/48 YRS

26-Aug-23

BOB HEALTH CHECKUP

U.S.G. OF ABDOMEN & PELVIS

LIVER

Liver is 13.2 cm vertically with normal echo-texture. Intra hepatic biliary radicals Are not dilated. No evidence of focal or diffuse lesion.

GALL BLADDER

Gall bladder is normally distended, lumen appear clear.

PANCREAS

Pancreas is normal in size, shape & echo-texture. No evidence of focal or diffuse lesion. MPD not dilated.

SPLEEN

Normal in size with normal shape & echo- texture. Spleen vein is normal. No evidence of focal or diffuse lesion

KIDNEY

Both kidneys are normal.

URINARY BLADDER

UB is normal.

UTERUS:

Uterus is normal in size (7.4x2.8x4.5cm) with homogenous echo-texture. Endometrium appear **thin**.

OVARIES:

Both ovaries appear small.

Dr. - Menopausal changes

Advice- follow up/ hormonal study review at higher center for confirmation

Please correlate clinically. USG accuracy is 95 % due to technical limitations as well as inaccuracies inherent in the laboratory and statistical analysis biological process.
This report is not valid for medico-legal cases

[Signature]
DR. MUKESH GUPTA
SONOLOGIST

Dr. Mukesh Kumar Gupta
Physician & Sonologist
RM 5423/16262



"भ्रूण लिंग परीक्षण की शिकायत
104 टोल फ्री सेवा पर भी की
जा सकती है"

भ्रूण लिंग परीक्षण की शिकायत 104 टोल फ्री सेवा पर भी की जा सकती है।



दक्ष हॉस्पिटल

396, गाँधी नगर स्कीम नं.8, अलवर (राज०) ☎ 0144-2703340

Sonography / 2D Echo Cardiography / Doppler Report

2D/ ECHO REPORT

Name: - Mrs Prem Yadav

Age: - 48 Yrs

Date: - 26-Aug-23

Reg. No.: - Alw/2009/04
BOB health checkup

PROCEDURES:

M-MODE/2D/DOPPLER/COLOR/CONTRAST B.A.S. M²

MEASUREMENT:		DOPPLER:	
AOD	22	NORMAL	NORMAL (cm/sec.)
LA	23	(20- 37mm)	MV 0.6 (0.8- 1.3) MR No
AVO	13	(19- 40mm)	AV 1.0 (1.2- 1.8) AR No
RVDd.	16	(12- 25mm)	TV 0.6 (0.3- 0.8) TR No
		(03- 09mm)	PV 0.8 (0.7- 1.1) PR No
LVDd	42.7	(37- 56mm)	MITRAL VALVE-
LVDs	24.6	(22- 40mm)	AML Normal
IVS d	7	(06- 12mm)	PML Normal
IVS s	12		
PWd	4.5	(05- 10mm)	AORTIC VALVE Normal
LV FUNCTION		TV & PV are normal.	
M- E- S Separation		<0.9cm	
Minor		24.42%	
LV Ejection Fraction	74%	65 +/- 12%	

LV WALL MOTION: NO RWMA
ALL CARDIAC CHAMBERS ARE NORMAL
ALL VALVES ARE NORMAL
NO CLOT, VEGETATION, PERICARDIAL EFFUSION

FINAL DIAGNOSIS: NORMAL STUDY

Adv: - Follow up/ review at higher center for confirmation

Note:- Please Correlate clinically. Due to technical limitations as well as inaccuracies inherent in the laboratory and statistical analysis of biological process. Diagnostic accuracy of ECHO is up to 95% only.
Report is not valid for medico-legal purpose.


Dr. Mukesh Kumar Gupta
DR. MUKESH GUPTA
Physician & Sonologist
PHYSICIAN
RM 5423/16262



"भ्रूण लिंग परीक्षण की शिकायत
104 टोल फ्री सेवा पर भी की
जा सकती है।"

भ्रूण लिंग परीक्षण की शिकायत 104 टोल फ्री सेवा पर भी की जा सकती है।



दक्ष हॉस्पिटल

396, गाँधी नगर स्कीम नं.8, अलवर (राज०) ☎ 0144-2703340

Sonography / 2D Echo Cardiography / Doppler Report

NAME :- MRS PREM YADAV/F/48 YRS

26-Aug-23

BOB HEALTH CHECKUP

U.S.G. OF BREAST

PROCEDURES: B-MODE SCAN DONE WITH LINEAR ARRAY TRANSDUCER

Left side:- In left breast all the quadrants and axillary area examined.
Subcutaneous plane, muscular plane, glandular and retro mammary fat planes appear normal.
No focal or diffuse lesion seen.

Right side:- In Right breast all the quadrants and axillary area examined.
Subcutaneous plane, muscular plane, glandular and retro mammary fat planes appear normal.
No focal or diffuse lesion seen.

No evidence of lymph node enlargement seen in both axillary areas.

Impression:- Normal USG breasts.

Please correlate clinically. USG accuracy is 95 % due to technical limitations as well as inaccuracies inherent in the laboratory and statistical analysis biological process.
This report is not valid for medico-legal cases


DR. MUKESH GUPTA
SONOLOGIST

Dr. Mukesh Kumar Gupta

Physician & Sonologist

RM 5423/16262



भ्रूण लिंग परीक्षण की शिकायत

104 टोल फ्री सेवा पर भी की

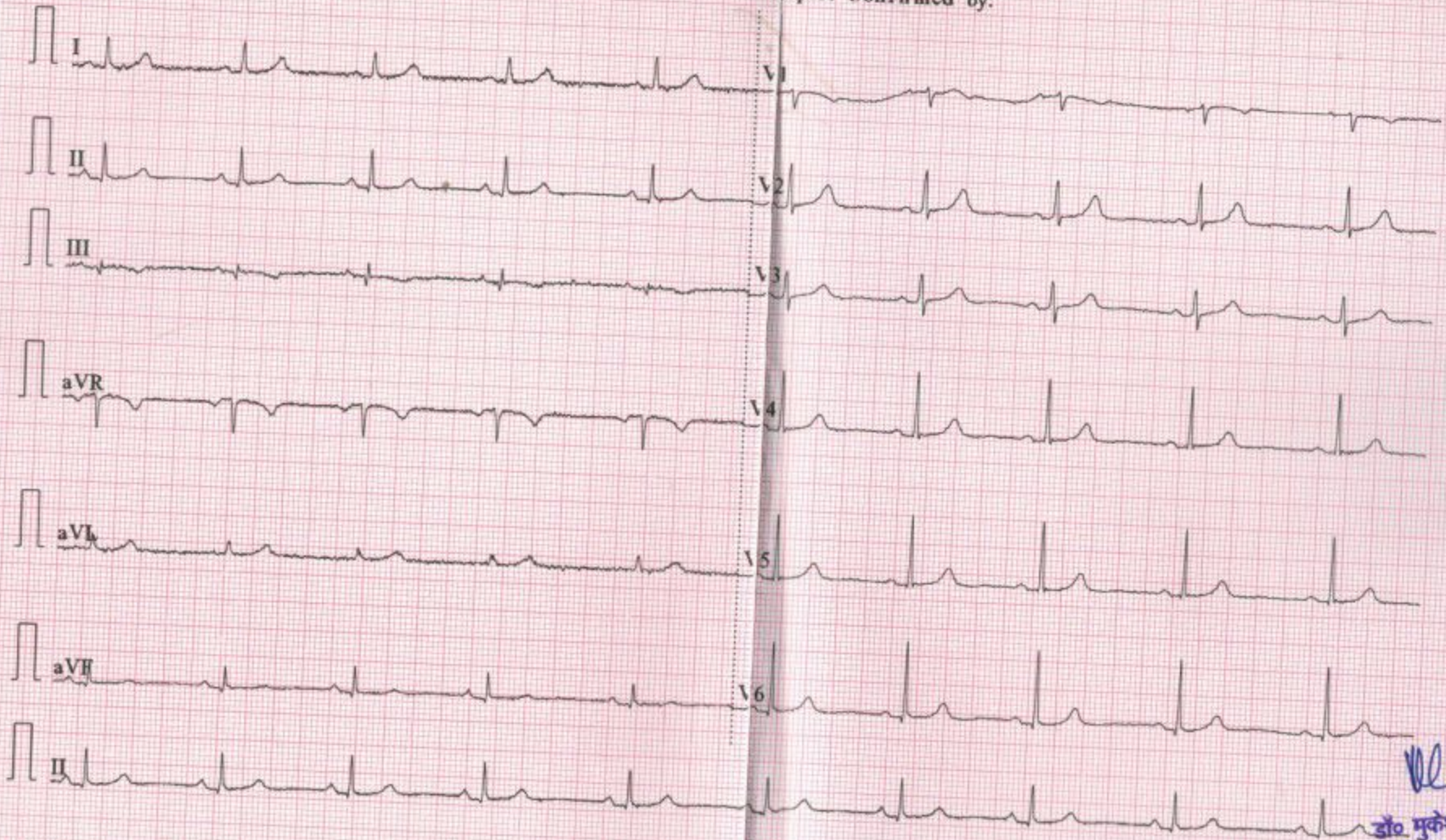
जा सकती है। भ्रूण लिंग परीक्षण की शिकायत 104 टोल फ्री सेवा पर भी की जा सकती है।

Female Years
Req. No. :

HR : 59 bpm
P : 94 ms
PR : 154 ms
QRS : 66 ms
QT/QTcBz : 402/399 ms
P/QRS/T : 54/35/17 °
RV5/SV1 : 1.196/0.274 mV

Diagnosis Information:
Sinus bradycardia
Normal ECG except for rate

Report Confirmed by:



0.67~35Hz AC50 25mm/s 10mm/mV 2*5.0s+1r CARDIART 9108

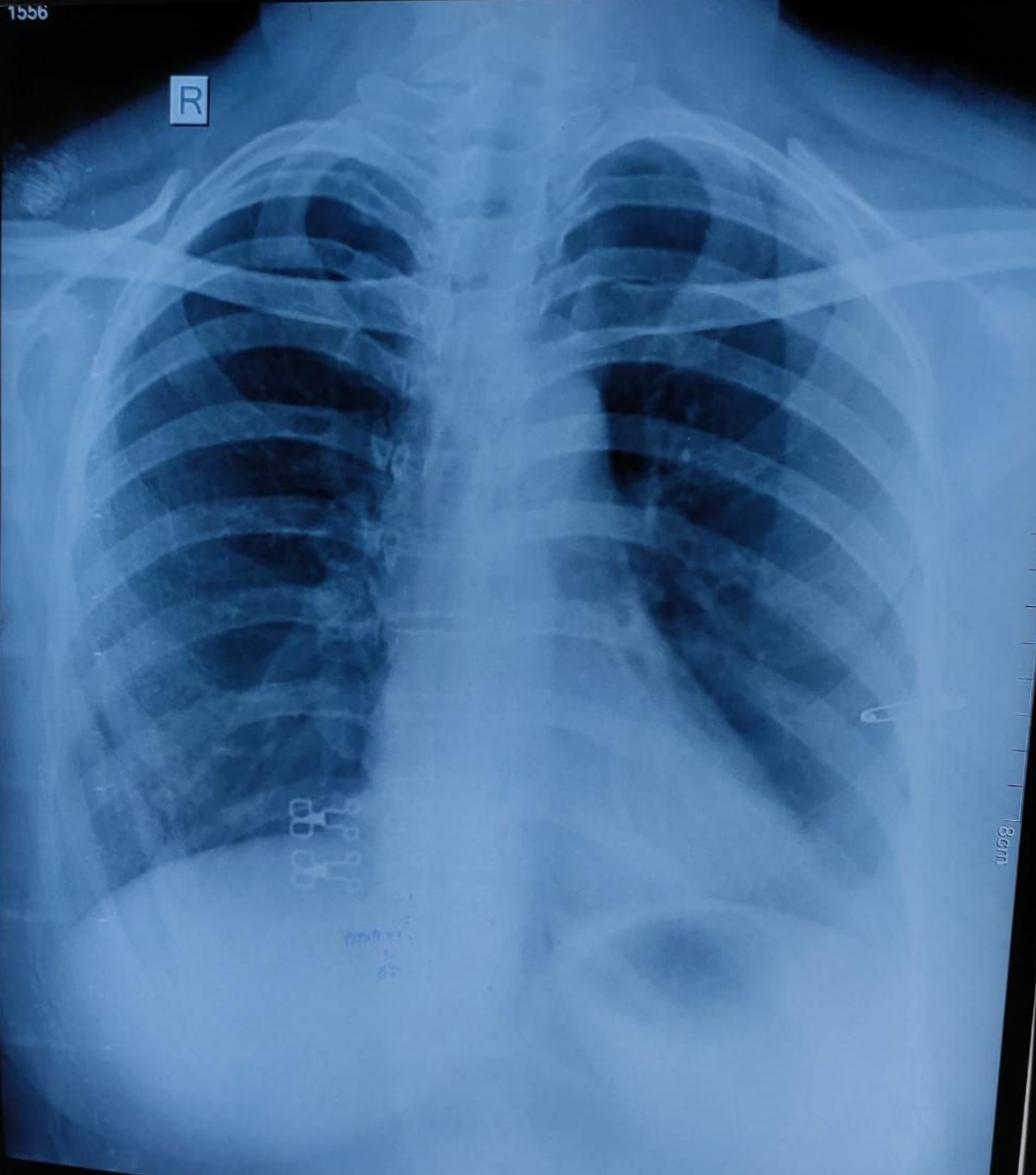
V1.44 Glasgow V286.7 Daksh Hospital Alwar

CARDIART

डॉ० मुकेश गुप्ता
M.D.F.C.C.S.
फिजिशियन एवं मधुमेह रोग विशेषज्ञ
दक्ष हॉस्पिटल, अलवर
रजि० नं०-542

1556

R



8cm

VIJAY DIAGNOSTIC CENTRE 1/16 KALA KUAN .ALWAR

1556