


 भारतीय विशिष्ट पहचान प्राधिकरण
 Unique Identification Authority of India
 

पता:
 जवाहर कुमार, हाउस नंबर-१११ सेकंड फ्लोर पॉकेट १,
 सेक्टर २५, रोहिणी, रोहिणी सेक्टर-२४, नॉर्थ वेस्ट दिल्ली,
 दिल्ली - ११००८५

Address:
 JAWAHAR KUMAR, H NO-111 SECOND FLOOR
 POCKET 1, SECTOR 25, ROHINI, Rohini
 Sector-24, North West Delhi,
 Delhi - 110085

Download Date: 15/02/2022





7162 4780 8634
 VID : 9176 5891 1091 4337

1947 | help@uidai.gov.in | www.uidai.gov.in

Handwritten signature

DR NITIN AGARWAL
 MBBS, MD
 Regn. No. DMC-R-1436

ONEPLUS ULTRASOUND LAB
 47, Harsh Vihar, Pitam Pura,
 Delhi-110034
 Ph. 011-42480101, 9599913051
 E-mail: oneplusul@gmail.com


 भारत सरकार
 Government of India
 

परविन्द कुमार
 Parvind Kumar
 जन्म तिथि/DOB: 06/06/1993
 पुरुष/ MALE

Issue Date: 31/12/2014



7162 4780 8634
 VID : 9176 5891 1091 4337

मेरा आधार, मेरी पहचान

ULTRASOUND
 No Admission Without Permission
Dr. Pooja Garg
 Radiologist
 MBBS, DNB (RADIOLOGY)

Ultrasound
 3D/4D/5D
 Ultrasound
 Color Doppler
 ECHO
 al X-Ray
 al Tests
 Barium
 tests, HSG
 il Tests
 Hormones
 EAC
 nology
 MT, ECG

Sweets
 District Park
 Google Green Lo

**48, Mahatma Hansraj
 Marg, Harsh Vihar, Pitam
 Pura, Delhi, 110034,
 India**
 Lat : 28.6935945
 Long : 77.1346798
 01/04/2023 10:40:03

[Handwritten signature]

[Handwritten signature]
DR. NITIN AGARWAL
 MBBS, MD
 Regn. No. DMC-R-1436

ONEPLUS ULTRASOUND
 47, Harsh Vihar, Pitam Pura,
 Delhi-110034
 Ph. 011-42480101, 9599913051
 E-mail: oneplusul@gmail.com

ONEPLUS ULTRASOUND LAB

47, HARSH VIHAR, PITAMPURA, DELHI- 110034

Mr. PARVIND KUMAR
 Age : 29/M
 Ref. by : MEDWHEEL
 Indication1 :
 Indication2 :
 Indication3 :
 COMMENTS :

ID : 2187
 H/Wt : 175/93
 Recorded : 1-4-2023 9:36
 Medication1 :
 Medication2 :
 Medication3 :

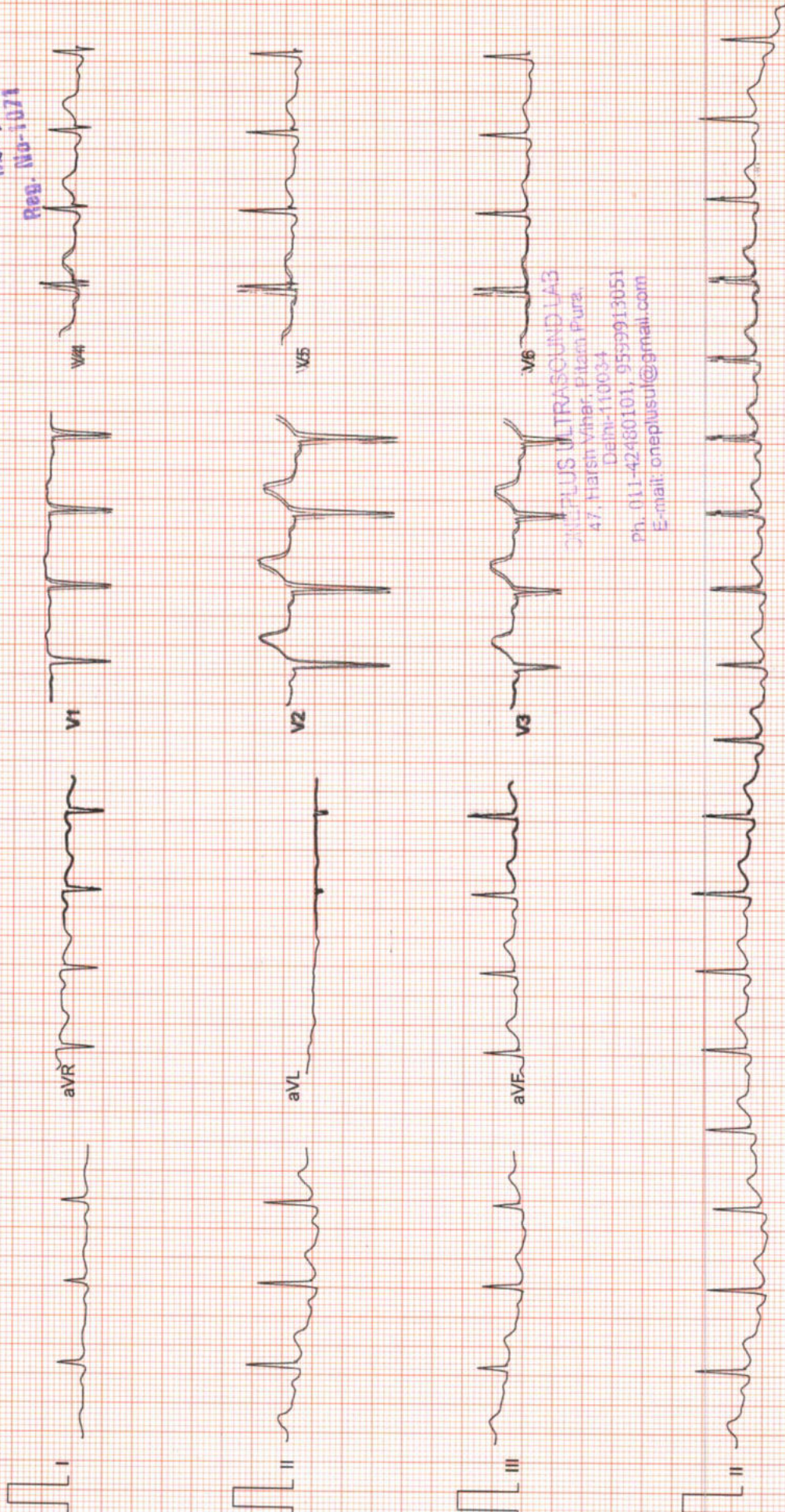
BPM : 112
 BP : 124/74
 P Axis : 53 deg
 QRS Axis : 60 deg
 T Axis : 61 deg

P duration : 86 msec
 PR duration : 133 msec
 QRS duration : 100 msec
 QT interval : 273 msec
 QTc interval : 364 msec

Raw E.C.G. (Seq)

Dr. P. GURGA
 Dr. P. GURGA
 Reg. No-1071

Unconfirmed Report Reviewed By:
 Cardiologist



ONEPLUS ULTRASOUND LAB
 47, Harsh Vihar, Pitampura,
 Delhi-110034
 Ph. 011-42480101, 95599913051
 E-mail: oneplusul@gmail.com

Filtered

25mm/sec 10mm/mV

CardiCom, INDIA

ONEPLUS ULTRASOUND LAB

47, HARSH VIHAR PITAMPURA DELHI 110034

Mr. PARVIND KUMAR

Age/Sex : 29/M

Ref. by : MEDIWHEEL

Indication1 :

Indication2 :

Indication3 :

ID : 994

H/Wt : 175/93

Recorded : 1-4-2023 9:39

TREADMILL TEST SUMMARY REPORT

Protocol: BRUCE

History:

Medication1 :

Medication2 :

Medication3 :

PHASE	PHASE TIME	STAGE TIME	SPEED (Km./Hr.)	GRADE (%)	H.R. (BPM)	B.P. (mmHg)	RPP X100	II	ST LEVEL (mm) V2	V5	METS
SUPINE STANDING					98 105	124/74 124/74	121 130	0.8 1.5	4.0 3.9	1.5 1.9	
STAGE 1	2:59	2:59	2.70	10.00	127	124/74	157	0.7	3.8	1.3	4.80
STAGE 2	5:59	2:59	4.00	12.00	150	140/80	210	0.6	4.1	1.2	7.10
STAGE 3	8:14	2:14	5.40	14.00	164	150/84	246	0.7	5.0	1.5	9.27
PEAK EXER	8:17	2:17			163	150/84	244	0.8	5.2	1.6	9.32
RECOVERY	2:59	2:59	0.00	0.00	113	126/76	142	0.9	3.0	0.9	

RESULTS

Exercise Duration : 8:17 Minutes

Max Heart Rate : 164 bpm 85 % of target heart rate 191 bpm

Max Blood Pressure : 150/84 mmHg

Max Work Load : 9.32 METS

Reason of Termination :

IMPRESSIONS

: Negative for indigabla ichin

Dr. P.N. GUPTA
MBBS MD
Cardiologist

ONEPLUS ULTRASOUND LAB
A7, Harsh Vihar, Pitampura, Faridabad
Delhi-110034
Ph: 011-42480101, 9399913051
E-mail: oneplusul@gmail.com

ONEPLUS ULTRASOUND LAB

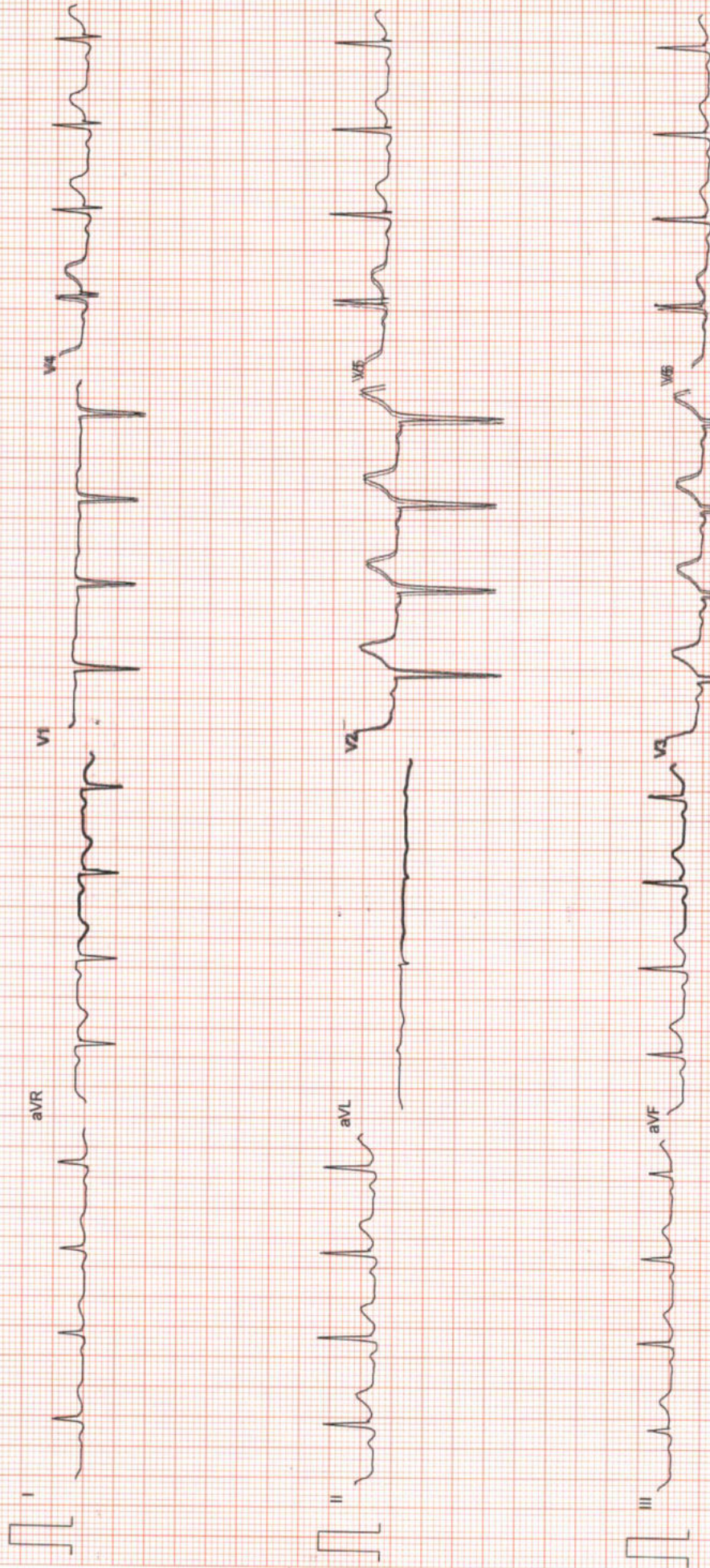
Mr. PARVIND KUMAR
I.D. : 994
AGE/SEX : 29/M
RECORDED : 1-4-2023 9:39

RATE : 98 BPM
B.P. : 124/74 mmHg

SUPINE
PRETEST

ST @ 10mm/mV
80ms PostJ

RAW E.C.G.



ONEPLUS ULTRASOUND LAB
47, Harsh Vihar, Pitam Pura,
Delhi-110034
Ph: 11-42460101, 9599913051
Email: oneplusul@gmail.com

Filtered

25mm/sec 10mm/mV

ONEPLUS ULTRASOUND LAB

ST @ 10mm/mV
80ms PostJ

Mr. PARVIND KUMAR

I.D. : 994

AGE/SEX : 29/M

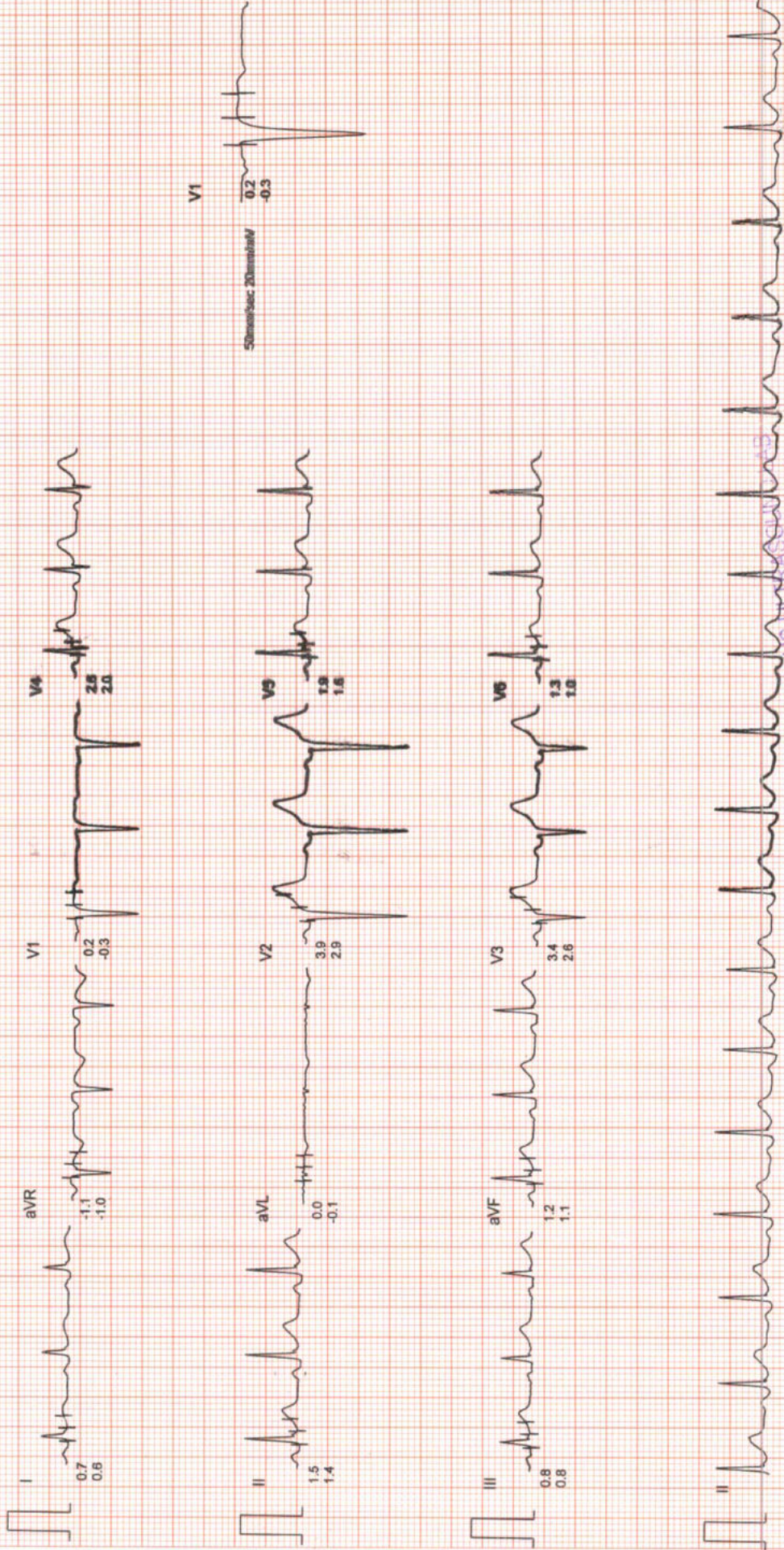
RECORDED : 1- 4-2023 9:39

RATE : 105 BPM

B.P. : 124/74 mmHg

STANDING
PRETEST

LINKED MEDIAN



ONEPLUS ULTRASOUND LAB
47, Harsh Vihar, Pitambara Pura,
Delhi-110034
Ph. 011-4248010, 9559913051
E-mail: oneplusul@oneplusul.com

Filtered

Computer Corrected Baseline

25mm/sec 10mm/mV

CardiCom, INDIA Ph. 091-731-2620740, TeleFax:091-731-2431214

ONEPLUS ULTRASOUND LAB

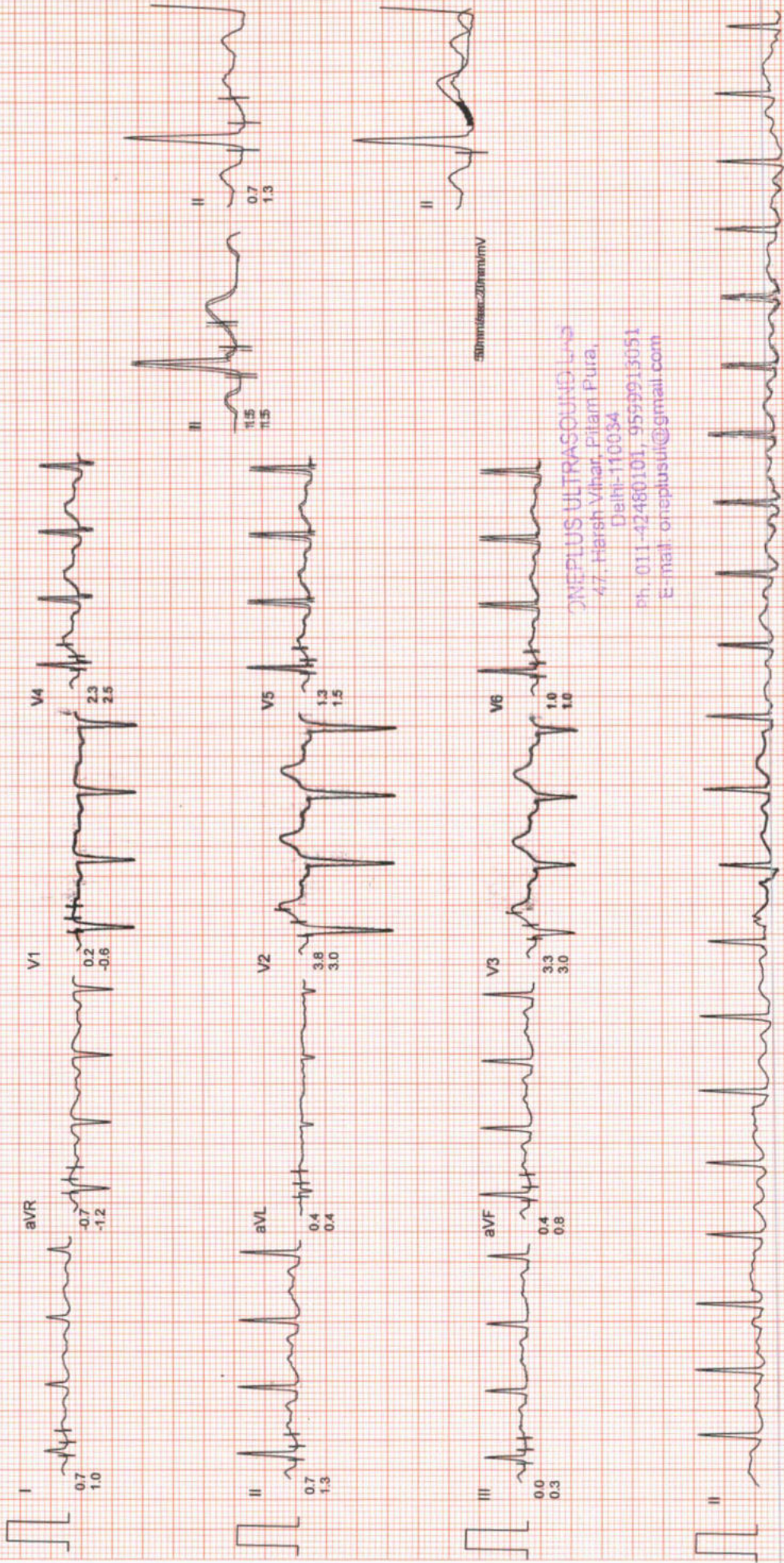
Mr. PARVIND KUMAR
I.D. : 994
AGE/SEX : 29/M
RECORDED : 1-4-2023 9:39

RATE : 127 BPM
B.P. : 124/74 mmHg

BRUCE
EXERCISE 1
PHASE TIME : 2:59
STAGE TIME : 2:59

ST @ 10mm/mV
80ms PostJ
SPEED : 2.7 Km./Hr.
GRADE : 10.0 %

LINKED MEDIAN



ONEPLUS ULTRASOUND LAB
47, Harsh Vihar, Pitam Pura,
Delhi-110034
Ph. 011-42481101, 9599915051
E-mail: oneplusul@gmail.com

ONEPLUS ULTRASOUND LAB

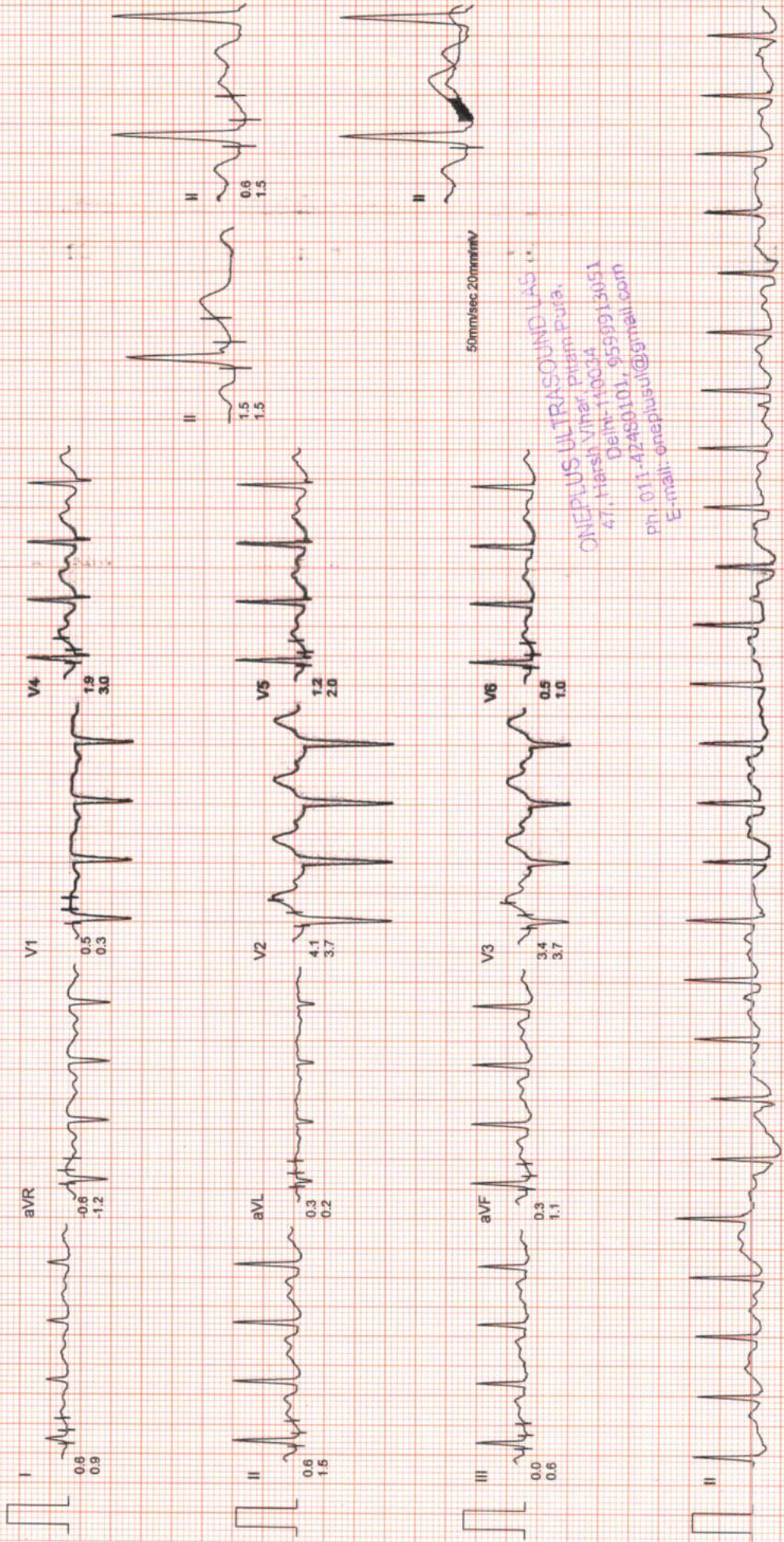
Mr. PARVIND KUMAR
I.D. : 994
AGE/SEX : 29/M
RECORDED : 1-4-2023 9:39

RATE : 150 BPM
B.P. : 140/80 mmHg

BRUCE
EXERCISE 2
PHASE TIME : 5:59
STAGE TIME : 2:59

ST @ 10mm/mV
80ms PostJ
SPEED : 4.0 Km./Hr.
GRADE : 12.0 %

LINKED MEDIAN



50mm/sec 20mm/mV

ONEPLUS ULTRASOUND LAB
47, Harsh Vihar, Pitam Pura,
Delhi-110034
ph: 011-42460101, 9559913051
E-mail: onepplusul@gmail.com

Filtered

Computer Corrected Baseline

25mm/sec 10mm/mV

CardiCom, INDIA Ph.:091-731-2620740, TeleFax:091-731-2431214

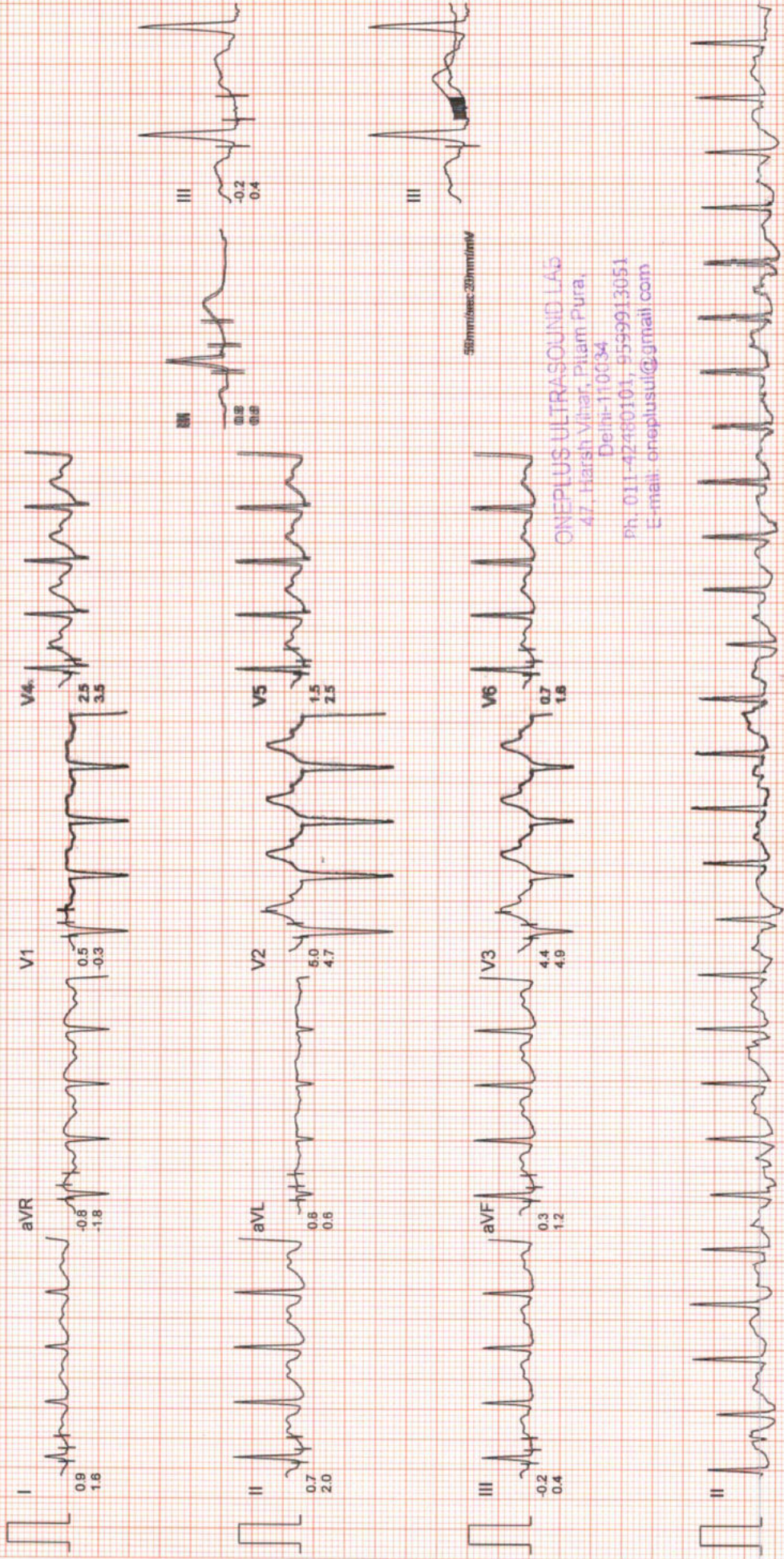
ONEPLUS ULTRASOUND LAB

Mr. PARVIND KUMAR
I.D. : 994
AGE/SEX : 29/M
RECORDED : 1-4-2023 9:39

BRUCE
EXERCISE 3
PHASE TIME : 8:14
STAGE TIME : 2:14

ST @ 10mm/mV
80ms PostJ
SPEED : 5.4 Km./Hr.
GRADE : 14.0 %

LINKED MEDIAN



ONEPLUS ULTRASOUND LAB
47, Harsh Vihar, Pitam Pura,
Delhi-110034
Ph. 011-42480101, 9599913051
E-mail: oneplusul@gmail.com

Filtered

Computer Corrected Baseline

25mm/sec 10mm/mV

CardiCom, INDIA Ph. 091-731-2620740, TeleFax 091-731-2431214



ONEPLUS ULTRASOUND LAB

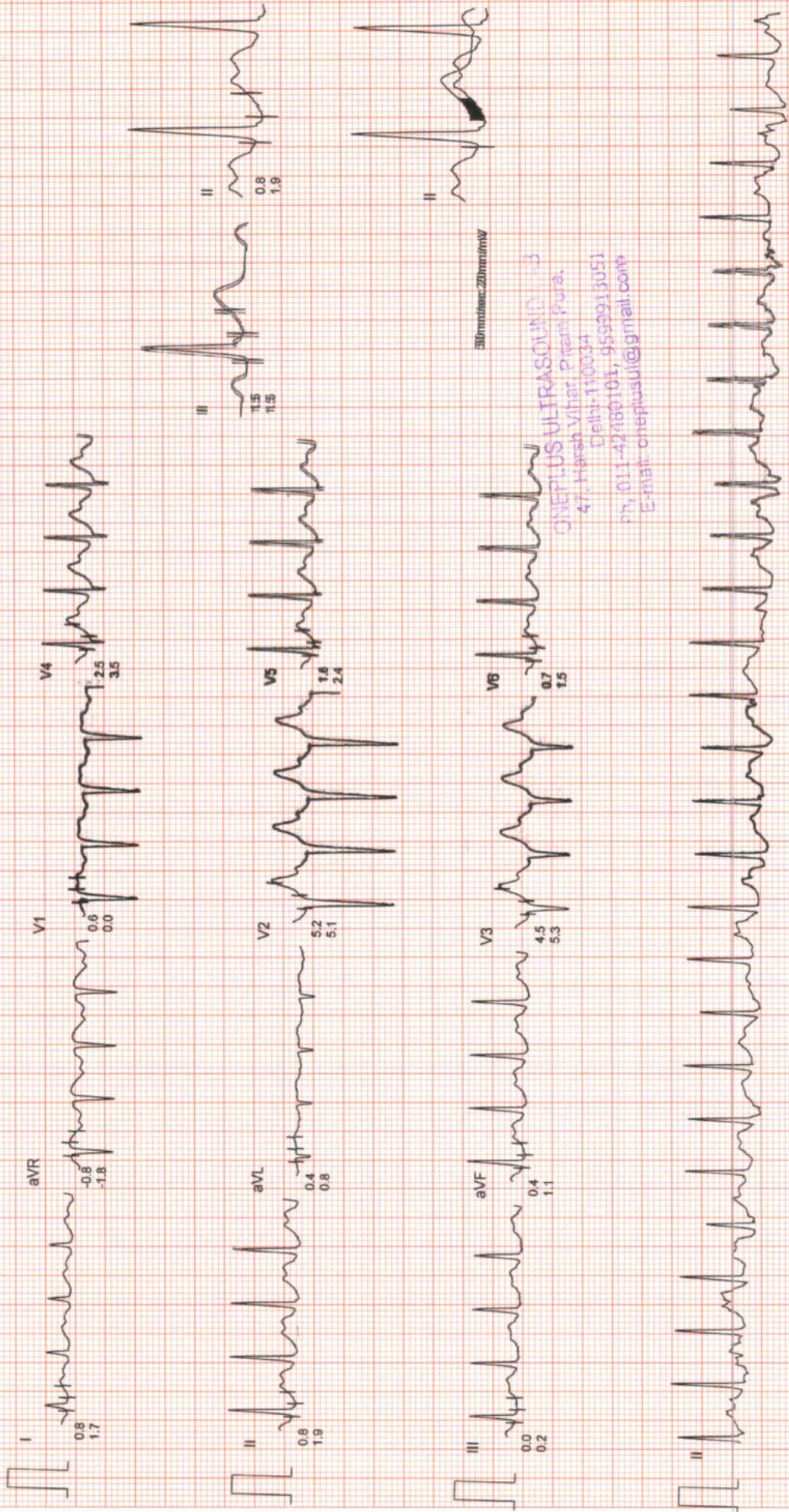
Mr. PARVIND KUMAR
I.D. : 994
AGE/SEX : 29/M
RECORDED : 1-4-2023 9:39

BRUCE
PEAK EXER
PHASE TIME : 8:17
STAGE TIME : 2:17

RATE : 163 BPM
B.P. : 150/84 mmHg

ST @ 10mm/mV
80ms PostJ
SPEED : 5.4 Km./Hr.
GRADE : 14.0 %

LINKED MEDIAN



30mm/sec 20mm/mV

ONEPLUS ULTRASOUND LAB
47, Harsh Vihar, Pitam Pura,
Delhi-110034
Ph: 011-42780101, 9599913051
E-mail: oneplusul@gmail.com

Filtered

Computer Corrected Baseline

25mm/sec 10mm/mV

ONEPLUS ULTRASOUND LAB

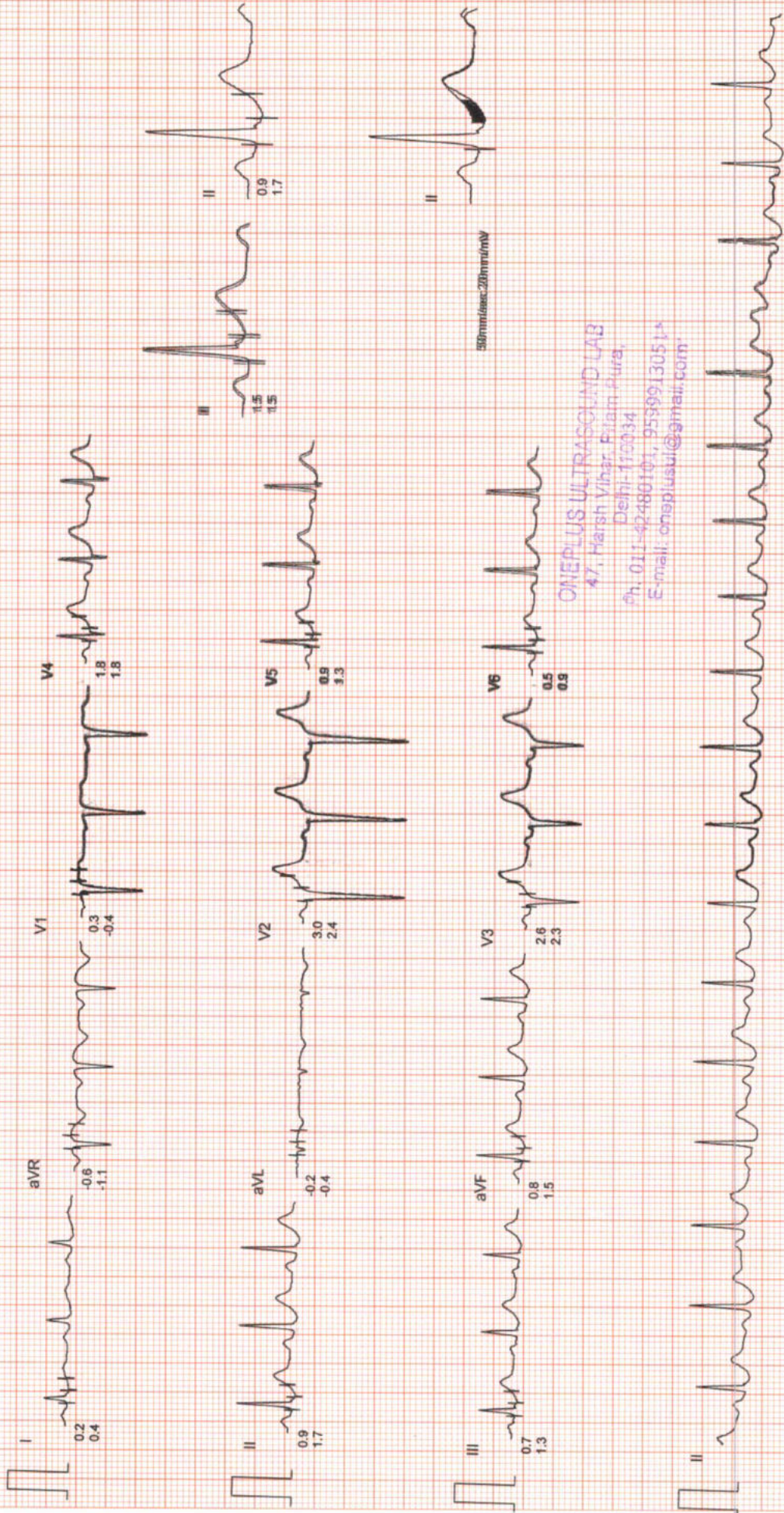
Mr. PARVIND KUMAR
I.D. : 994
AGE/SEX : 29/M
RECORDED : 1-4-2023 9:39

BRUCE
RECOVERY
PHASE TIME : 2:59

RATE : 113 BPM
B.P. : 126/76 mmHg

ST @ 10mm/mV
80ms PostJ
SPEED : 0.0 Km./Hr.
GRADE : 0.0 %

LINKED MEDIAN



ONEPLUS ULTRASOUND LAB
47, Harsh Vihar, Pitampura,
Delhi-110034
Ph. 011-4248101, 9599913051
E-mail: onepplusul@gmail.com

Filtered

Computer Corrected Baseline

25mm/sec 10mm/mV

50mm/sec 20mm/mV

ONEPLUS ULTRASOUND LAB

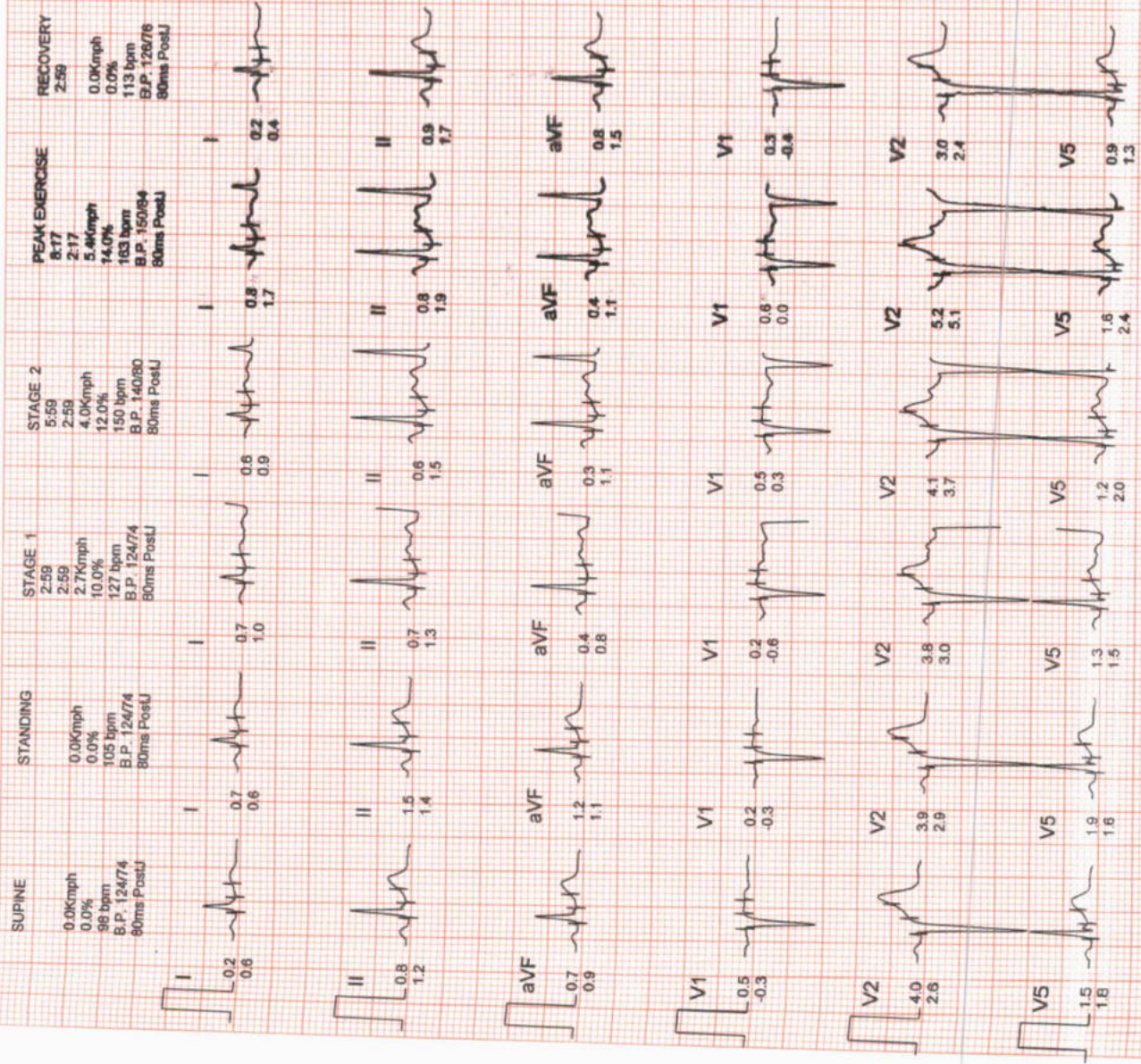
Mr. PARVIND KUMAR

I.D. : 994

AGE/SEX : 29/M

RECORDED : 1-4-2023 9:39

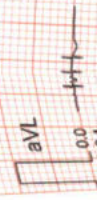
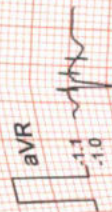
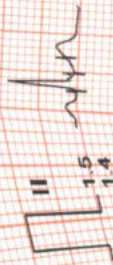
AVG E.C.G.



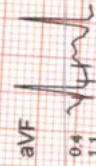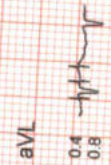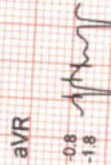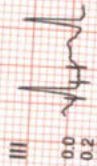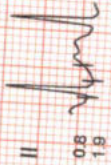
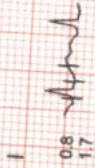ONEPLUS ULTRASOUND LAB
 47, Harsh Vihar, Pitam Pura,
 Delhi-110034
 Ph: 011-42480101, 9599913051
 Email: oneplusul@gmail.com

RECORDED : 1-4-2023 9:39
COMPARISON REPORT

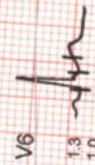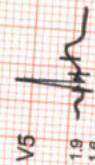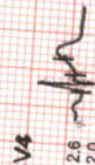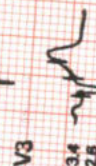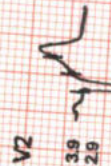
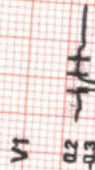STANDING
0.0Kmph
0.0%
105 bpm
B.P. 124/74
80ms PostU



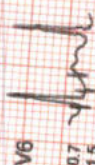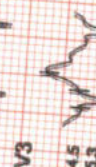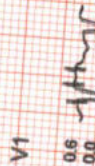PEAK EXERCISE
8:17
2:17
5.4Kmph
14.0%
163 bpm
B.P. 150/84
80ms PostU



STANDING
0.0Kmph
0.0%
105 bpm
B.P. 124/74
80ms PostU



PEAK EXERCISE
8:17
2:17
5.4Kmph
14.0%
163 bpm
B.P. 150/84
80ms PostU



ONEPLUS ULTRASOUND LAB
Dr. Harsh Vihar Prasad
Delhi-110024
Phone: 95597151
Email: oneplusul@gmail.com
011-42180101



Mr. PARVIND KUMAR

I.D. : 994

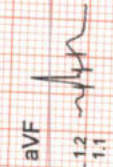
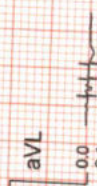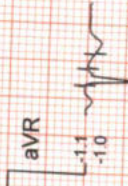
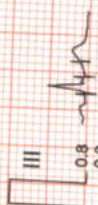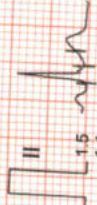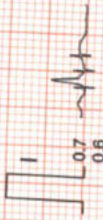ONEPLUS ULTRASOUND LAB

AGE/SEX : 29/M

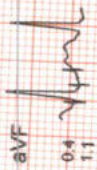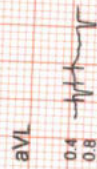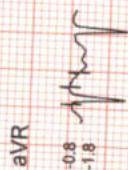
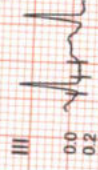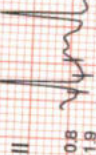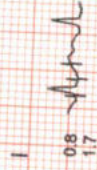RECORDED : 1-4-2023 9:39

COMPARISON REPORT

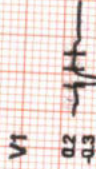



STANDING
 0.0Kmph
 0.0%
 105 bpm
 B.P. 124/74
 80ms PostJ



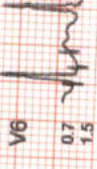

PEAK EXERCISE
 8:17
 2:17
 5.4Kmph
 14.0%
 163 bpm
 B.P. 150/84
 80ms PostJ



STANDING
 0.0Kmph
 0.0%
 105 bpm
 B.P. 124/74
 80ms PostJ



PEAK EXERCISE
 8:17
 2:17
 5.4Kmph
 14.0%
 163 bpm
 B.P. 150/84
 80ms PostJ



Dr. Rajesh Virender Rajam
 Cardiac Sonologist
 101, 142, Keshavnagar, Delhi-110034
 E-mail: onedialist@gmail.com
 Tel: 011-427480101, 9556912311
 Tel: 011-427480101, 9556912311

Name	: Mr. PARVIND KUMAR	Age/Sex	: 29 YRS/Male
Ref. By	: Dr. MEDIWHEEL	Lab No	: 012304010004
Date	: 01-Apr-2023	Patient ID	: LSHHI111718

ULTRASOUND EXAMINATION---WHOLE ABDOMEN

Liver is normal in size (14.6 cm) and outline with altered echopattern. Diffuse increase in echogenicity of liver parenchyma is noted, suggestive of fatty infiltration (grade I). No abscess or mass lesion seen. Hepatic veins, portal vein, IVC and aorta are normal. Intrahepatic biliary radicles are not dilated. CBD is normal in caliber.

Gall bladder is partially contracted, grossly normal.

Both kidneys are normal in size, shape, position, outline and echopattern. Corticomedullary differentiation is maintained. No pelvicalyceal dilation or calculus or mass lesion is seen.

Spleen is normal in size and echotexture. No mass lesion seen.

Pancreas is normal in size, outline and echotexture .

Urinary bladder is normal in shape and position. No evidence of intravesical stone or mass seen.

Prostate is normal in size, shape and echopattern.

Prostate measures 3.6 x 3.2 x 3.1 cm. **Weight of prostate is 19.3 grams.**

No abnormal bowel wall thickening seen in right iliac fossa.

No free fluid seen anywhere in abdomen.

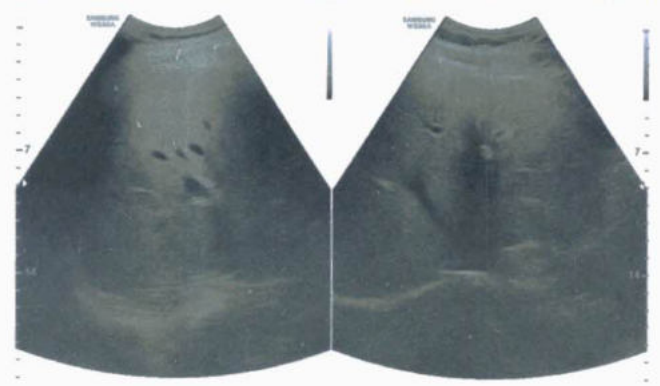
IMPRESSION: Fatty infiltration of liver (grade I) with no hepatomegaly.

Dr. POOJA GARG
MBBS, DMRD
Reg No. DMC/R/03398
Radiologist
DR. POOJA GARG
RADIOLOGIST
REG NO- DMC/R/03398

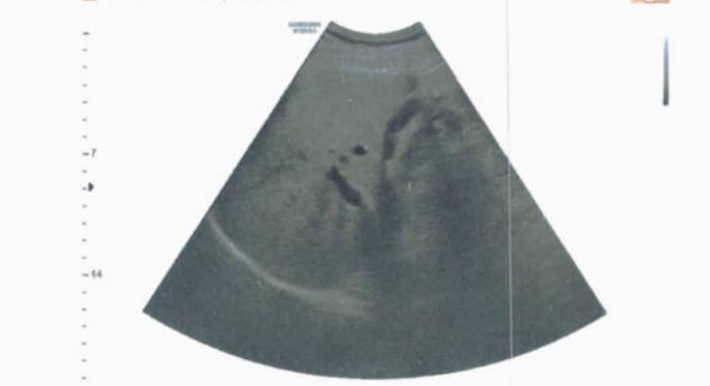Type By : darshita

47, Harsh Vihar, Pitampura, New Delhi-110034 | Ph.: 011-42480101, 9599913051
E-mail: oneplusul@gmail.com | Web.: www.oneplusul.in

MR PARVIND 29/M
OnePlus Ultrasound Lab MI 1.4 01-04-2023
CA1-7A / Abdomen / FR 21Hz Tls 0.1 11:10:45 AM



MR PARVIND 29/M
OnePlus Ultrasound Lab MI 1.4 01-04-2023
CA1-7A / Abdomen / FR 21Hz Tls 0.1 11:11:01 AM

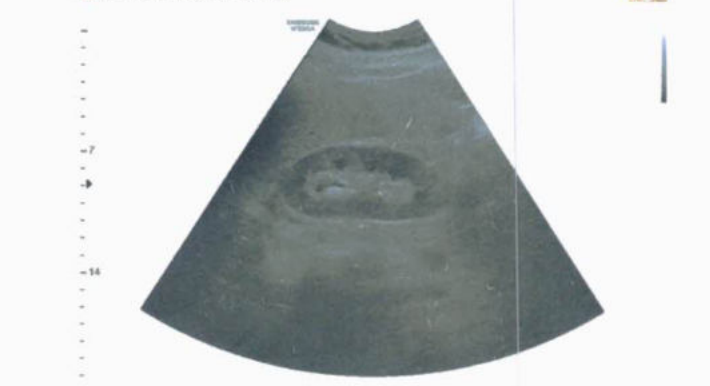

MR PARVIND 29/M
OnePlus Ultrasound Lab MI 1.4 01-04-2023
CA1-7A / Abdomen / FR 21Hz Tls 0.1 11:11:08 AM

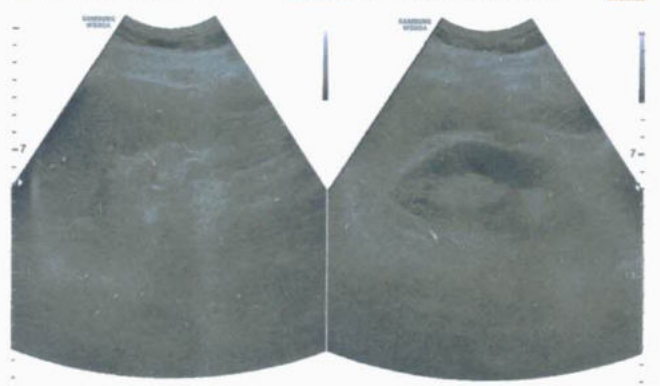


D1 14.60 cm

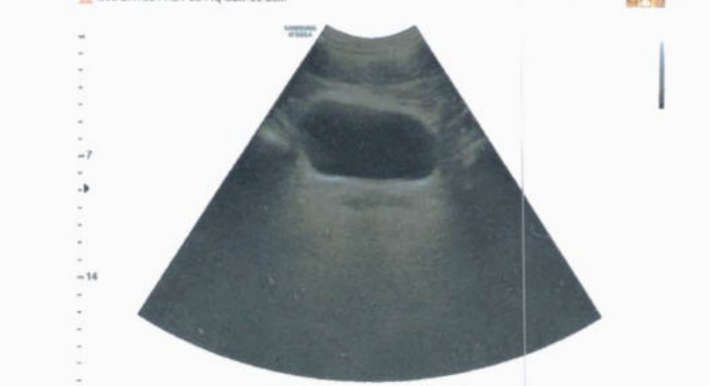
MR PARVIND 29/M
OnePlus Ultrasound Lab MI 1.4 01-04-2023
CA1-7A / Abdomen / FR 21Hz Tls 0.1 11:11:20 AM



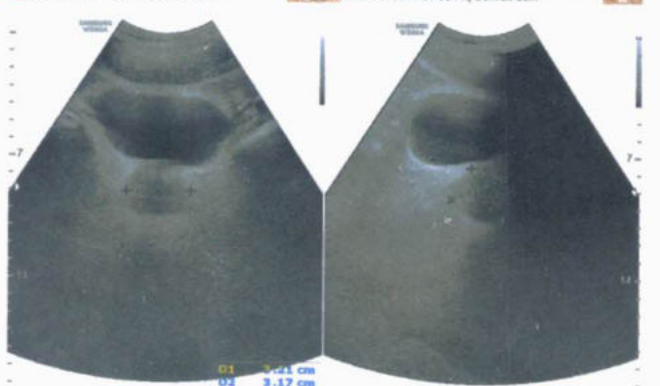MR PARVIND 29/M
OnePlus Ultrasound Lab MI 1.4 01-04-2023
CA1-7A / Abdomen / FR 21Hz Tls 0.1 11:11:46 AM



MR PARVIND 29/M
OnePlus Ultrasound Lab MI 1.4 01-04-2023
CA1-7A / Abdomen / FR 21Hz Tls 0.1 11:11:57 AM



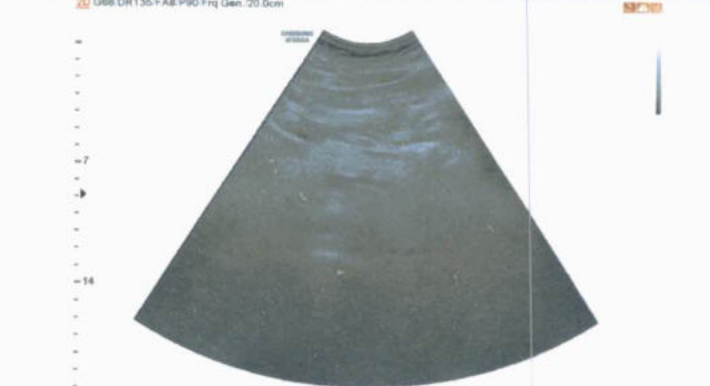MR PARVIND 29/M
OnePlus Ultrasound Lab MI 1.4 01-04-2023
CA1-7A / Abdomen / FR 21Hz Tls 0.1 11:12:18 AM



D1 9.21 cm
D2 3.17 cm
D3 3.65 cm
Vol. 19.38 ml

D1 3.21 cm
D2 3.17 cm

MR PARVIND 29/M
OnePlus Ultrasound Lab MI 1.4 01-04-2023
CA1-7A / Abdomen / FR 21Hz Tls 0.1 11:12:24 AM





OnePLUS Ultrasound Lab

— QUALITY FIRST... ALWAYS! —

Dr. Nitin Agarwal

Pathologist & Director
Ex. Sr. Res. MAMC
& Lok Nayak Hospital
Ex. Chief of Lab Dr. Lal Path Labs.

Dr. Pooja (Garg) Agarwal

Radiologist & Director
MAMC & Lok Nayak Hospital



NAME	:Mr. PARVIND KUMAR	Barcode No	:10141378
AGE/GENDER	:29 YRS/Male	SPECIMEN DATE	:01/Apr/2023 08:41AM
PATIENT ID	:111718	SPECIMEN RECEIVED	:01/Apr/2023 08:57AM
REFERRED BY	:Dr. MEDIWHEEL	REPORT DATE	:01/Apr/2023 04:08PM
CENTRE NAME	:ONEPLUS ULTRASOUND LAB	LAB NO.	:012304010004

Test Name	Result	Unit	Ref. Range
-----------	--------	------	------------

HAEMATOLOGY

Medi Wheel Health checkup < 40 Male

Glycosylated Hemoglobin (HbA1c)	5.3	%	Non Diabetic adults <5.7 Prediabetic (at risk) 5.7-6.4 Diabetes >6.4
--	-----	---	--

Estimated average blood glucose (eag)	105
--	-----

Reference range (mg/dl):

90 - 120:Excellent control, 121 - 150:Good Control, 151 - 180:Average Control, 181 - 210:Action Suggested

>211:Panic value

BLOOD GROUP (ABO)	B
Rh typing	POSITIVE

NOTE :

- * Apart from major A,B,H antigens which are used for ABO grouping and Rh typing, many minor blood group antigens exist. Agglutination may also vary according to titre of antigen and antibody.
- * So before transfusion, reconfirmation of blood group as well as cross-matching is needed.
- * Presence of maternal antibodies in newborns, may interfere with blood grouping.
- * Auto agglutination (due to cold antibody, falciparum malaria, sepsis, internal malignancy etc.) may also cause erroneous result.

CBC

Haemoglobin	15.2	g/dl	13.0-17.0
Total Leucocyte Count	7800	/cumm	4000-10000
Differential leucocyte count			
Neutrophils	69.8	%	40-80
Lymphocyte	24.80	%	20-40
Monocytes	3.00	%	2-10
Eosinophils	2.0	%	1-6
Basophils	0.4	%	0-2
RBC Count	5.00	million/cumm	4.5 - 5.5

Checked By.

Dr. NITIN AGARWAL
M.B.B.S., MD (Pathology)
DMC/R/01436
DR. NITIN AGARWAL
MBBS, MD (PATHOLOGIST)

47, Harsh Vihar, Pitampura, New Delhi-110034 | Ph.: 011-42480101, 9599913051

E-mail: oneplusul@gmail.com | Web.: www.oneplusul.in

Page 1 of 5



OnePLUS Ultrasound Lab

— QUALITY FIRST... ALWAYS! —

Dr. Nitin Agarwal

Pathologist & Director
Ex. Sr. Res. MAMC
& Lok Nayak Hospital
Ex. Chief of Lab Dr. Lal Path Labs.

Dr. Pooja (Garg) Agarwal

Radiologist & Director
MAMC & Lok Nayak Hospital



NAME	:Mr. PARVIND KUMAR	Barcode No	:10141378
AGE/GENDER	:29 YRS/Male	SPECIMEN DATE	:01/Apr/2023 08:41AM
PATIENT ID	:111718	SPECIMEN RECEIVED	:01/Apr/2023 08:57AM
REFERRED BY	:Dr. MEDIWHEEL	REPORT DATE	:01/Apr/2023 04:08PM
CENTRE NAME	:ONEPLUS ULTRASOUND LAB	LAB NO.	:012304010004

Test Name	Result	Unit	Ref. Range
PCV(Hematocrit)	50.1	%	40-50
MCV	100	fL	83-101
MCH	30.3	Pg	27-32
MCHC	30.3	G/dL	32-35
Platelet count	183000	/cumm	150000-450000
RDW-CV	16.3	%	11.4-14.0
ESR(WESTEGRENs METHOD)	12	mm in 1st hr	0-20

BIOCHEMISTRY

<u>Blood sugar fasting</u>	110	mg/dL	70-110
<u>Blood sugar pp</u>	94	mg/dL	70.0-140.0
<u>Bun (blood urea nitrogen)</u>	14.60	mg/dl	8.9-21.6
<u>Uric acid, serum</u>	4.6	mg/dl	3.5-7.2
<u>Creatinine, serum</u>	0.6	mg/dl	0.60-1.2

LFT(LIVER FUNCTION TEST)

Bilirubin Total	0.69	mg/dl	0.1-1.2
Bilirubin Conjugated	0.38	mg/dl	0-0.4
Bilirubin Unconjugated	0.31	mg/dl	up to 0.7
SGOT (AST)	32	U/L	0-46
SGPT (ALT)	38	U/L	0-49
Alkaline phosphatase	94	U/L	40-129
Gamma glutamyl transpeptidase	36	U/L	10-45
Total Protein	6.8	gm/dl	6.60 - 8.70
Albumin serum	3.9	g/dL	3.0-5.2
Globulin	2.90	gm/dl	1.8-3.4
Albumin/Globulin Ratio	1.34		1.10 - 2.50

LIPID PROFILE

Cholesterol	161	mg/dl	50-200
Triglycerides	159	mg/dL	25-150

Checked By.

DR. NITIN AGARWAL
MBBS, MD (PATHO)
DMC/R/01436

DR. NITIN AGARWAL
MBBS, MD (PATHOLOGIST)

47, Harsh Vihar, Pitampura, New Delhi-110034 | Ph.: 011-42480101, 9599913051

E-mail: oneplusul@gmail.com | Web.: www.oneplusul.in

Page 2 of 5

Clinical correlation is essential for final diagnosis. • If test results are unsatisfactory please contact personally or on phone. • This report is for perusal of doctors only. • All disputes Subject to Delhi Jurisdiction only. • Not for medicolegal purposes. • All congenital anomalies in a foetus may not be diagnosed in routine obstetric ultrasound.



OnePLUS Ultrasound Lab

— QUALITY FIRST... ALWAYS! —

Dr. Nitin Agarwal
Pathologist & Director
Ex. Sr. Res. MAMC
& Lok Nayak Hospital
Ex. Chief of Lab Dr. Lal Path Labs.

Dr. Pooja (Garg) Agarwal
Radiologist & Director
MAMC & Lok Nayak Hospital



NAME	:Mr. PARVIND KUMAR	Barcode No	:10141378
AGE/GENDER	:29 YRS/Male	SPECIMEN DATE	:01/Apr/2023 08:41 AM
PATIENT ID	:111718	SPECIMEN RECEIVED	:01/Apr/2023 08:57 AM
REFERRED BY	:Dr. MEDIWHEEL	REPORT DATE	:01/Apr/2023 04:08 PM
CENTRE NAME	:ONEPLUS ULTRASOUND LAB	LAB NO.	:012304010004

Test Name	Result	Unit	Ref. Range
HDL Cholesterol	47	mg/dL	40 - 60
LDL cholesterol	82	mg/dL	<130
VLDL cholesterol	31.8	mg/dL	5-40
Cholesterol/HDL Ratio	3.4		Low Risk 3.3-4.97 Average Risk 4.4-7.1 Moderate Risk 7.1-11.0 High Risk >11.0
LDL/HDL Ratio	1.8		0 - 3.55

According to ATP III and NCEP guidelines

Parameter	Normal	Desirable	Borderline	High
Total cholesterol	<200		200-239	240
Triglycerides	<150	150-199	200-499	500
LDL	Optimal <100 Near Optimal 100-129	130-159	160-180	190
HDL	<40 : LOW 60 : HIGH			

BUN/Creatinine ratio

Bun (blood urea nitrogen)	14.60	mg/dl	8.9-21.6
CREATININE	0.60	mg/dl	0.30-1.10
BUN/Creatinine ratio	24.33		10.0 - 20.0

ENDOCRINOLOGY

THYROID PROFILE(T3,T4,TSH)

Triiodothyronine total [t3]	0.95	ng/dl	0.52-1.9
Thyroxine total [t4]	6.50	µg/dl	4.4 - 10.8
TSH (Thyroid Stimulating Hormone)	7.00	µIU/ml	0.25-5.0

AGE WISE VARIATION IN TSH

Checked By.

Dr. NITIN AGARWAL
M B B S . MD (Path)
DMC/R/01436
DR. NITIN AGARWAL
MBBS,MD(PATHOLOGIST)

47, Harsh Vihar, Pitampura, New Delhi-110034 | Ph.: 011-42480101, 9599913051
E-mail: oneplusul@gmail.com | Web.: www.oneplusul.in

Page 3 of 5



OnePLUS Ultrasound Lab

— QUALITY FIRST... ALWAYS! —

Dr. Nitin Agarwal
Pathologist & Director
Ex. Sr. Res. MAMC
& Lok Nayak Hospital
Ex. Chief of Lab Dr. Lal Path Labs.

Dr. Pooja (Garg) Agarwal
Radiologist & Director
MAMC & Lok Nayak Hospital



NAME	:Mr. PARVIND KUMAR	Barcode No	:10141378
AGE/GENDER	:29 YRS/Male	SPECIMEN DATE	:01/Apr/2023 08:41AM
PATIENT ID	:111718	SPECIMEN RECEIVED	:01/Apr/2023 08:57AM
REFERRED BY	:Dr. MEDIWHEEL	REPORT DATE	:01/Apr/2023 04:08PM
CENTRE NAME	:ONEPLUS ULTRASOUND LAB	LAB NO.	:012304010004

Test Name	Result	Unit	Ref. Range
AGE	TSH(μIU/ml)	AGE	TSH(μIU/ml)
1-4 weeks	1.00 - 19.0	16-20 yrs	0.25 - 5.0
1-12 mths	1.70 - 9.1	21 - 80 yrs	0.25 - 5.0
1-5 yrs	0.80 - 8.2	I st trimester	0.25 - 5.0
6-10 yrs	0.25 - 5.0	II nd trimester	0.50 - 5.0
11-15 yrs	0.25 - 5.0	II rd trimester	0.4 - 6.0

Reference ranges - Interpretation of Diagnostic tests - (Jacques Wallach)

1. Primary hypothyroidism is accompanied by depressed serum T3 and T4 values and elevated serum TSH level.
2. Primary hyperthyroidism is accompanied by elevated serum T3 and T4 levels along with depressed TSH values.
3. Slightly elevated T3 levels may be found in pregnancy and estrogen therapy, while depressed levels may be encountered in severe illness, renal failure and during therapy with drugs like propranolol and propyl thiouracil.
4. Although elevated TSH levels are nearly always indicative of primary hypothyroidism, and may be seen in secondary thyrotoxicosis

CLINICAL PATHOLOGY

URINE ROUTINE

Physical examination

Quantity	30	ML
Colour	PALE YELLOW	
Transparency	CLEAR	CLEAR
Sp.gravity	1.015	1.010-1.030
pH	6.00	
Reaction	ACIDIC	ACIDIC

Chemical examination

Urine protein	NIL	NIL
Urine sugar	NIL	NIL
Bilirubin, urine	NEGATIVE	NEGATIVE
Urobilinogen	NORMAL	NORMAL
Ketones	NEGATIVE	NEGATIVE

Microscopic examination

Checked By.

Dr. NITIN AGARWAL
MBBS, MD (PATHOLOGY)
DMC/R/01436
DR. NITIN AGARWAL
MBBS, MD (PATHOLOGIST)

47, Harsh Vihar, Pitampura, New Delhi-110034 | Ph.: 011-42480101, 9599913051
E-mail: onepusul@gmail.com | Web.: www.oneplusul.in

Page 4 of 5

Clinical correlation is essential for final diagnosis. • If test results are unsatisfactory please contact personally or on phone. • This report is for perusal of doctors only. • All disputes Subject to Delhi Jurisdiction only. • Not for medicolegal purposes. • All congenital anomalies in a foetus may not be diagnosed in routine obstetric ultrasound.



OnePLUS Ultrasound Lab

— QUALITY FIRST... ALWAYS! —

Dr. Nitin Agarwal

Pathologist & Director
Ex. Sr. Res. MAMC
& Lok Nayak Hospital
Ex. Chief of Lab Dr. Lal Path Labs.

Dr. Pooja (Garg) Agarwal

Radiologist & Director
MAMC & Lok Nayak Hospital



NAME	:Mr. PARVIND KUMAR	Barcode No	:10141378
AGE/GENDER	:29 YRS/Male	SPECIMEN DATE	:01/Apr/2023 08:41AM
PATIENT ID	:111718	SPECIMEN RECEIVED	:01/Apr/2023 08:57AM
REFERRED BY	:Dr. MEDIWHEEL	REPORT DATE	:01/Apr/2023 04:08PM
CENTRE NAME	:ONEPLUS ULTRASOUND LAB	LAB NO.	:012304010004

Test Name	Result	Unit	Ref. Range
Pus cells.	1-2	/HPF	0-2
Epithelial cells	0-1	/HPF	NIL
R.B.C.	NIL	/HPF	NIL
Casts	NIL	/HPF	NIL
Crystals	NIL	/HPF	NIL
Bacteria	NIL	/HPF	NIL
Others.	NIL	NIL	NIL

*** End Of Report ***

Checked By.

Dr. NITIN AGARWAL
MBBS, MD (Path)
DMC/R/01436

DR. NITIN AGARWAL
MBBS, MD (PATHOLOGIST)

47, Harsh Vihar, Pitampura, New Delhi-110034 | Ph.: 011-42480101, 9599913051

E-mail: oneplusul@gmail.com | Web.: www.oneplusul.in

Page 5 of 5

Clinical correlation is essential for final diagnosis. • If test results are unsatisfactory please contact personally or on phone. • This report is for perusal of doctors only. • All disputes Subject to Delhi Jurisdiction only. • Not for medicolegal purposes. • All congenital anomalies in a foetus may not be diagnosed in routine obstetric ultrasound.



OnePLUS
Ultrasound Lab

— QUALITY FIRST... ALWAYS! —

Dr. Nitin Agarwal

Pathologist & Director
Ex. Sr. Res. MAMC
& Lok Nayak Hospital
Ex. Chief of Lab Dr. Lal Path Labs.

Dr. Pooja (Garg) Agarwal

Radiologist & Director
MAMC & Lok Nayak Hospital

Name	: Mr. PARVIND KUMAR	Age/Sex	: 29 YRS/Male
Ref. By	: Dr. MEDIWHEEL	Lab No	: 012304010004
Date	: 01-Apr-2023	Patient ID	: LSHHI111718

X-ray-Chest PA view

Bony cage and soft tissues are normal.

Cardiothoracic ratio is normal.

Mediastinum is normal.

Both hila are normal.

Both costophrenic angles are clear.

Both domes of diaphragm are normal.

Lung fields are clear. No parenchymal lesion seen.

IMPRESSION: Normal Study.

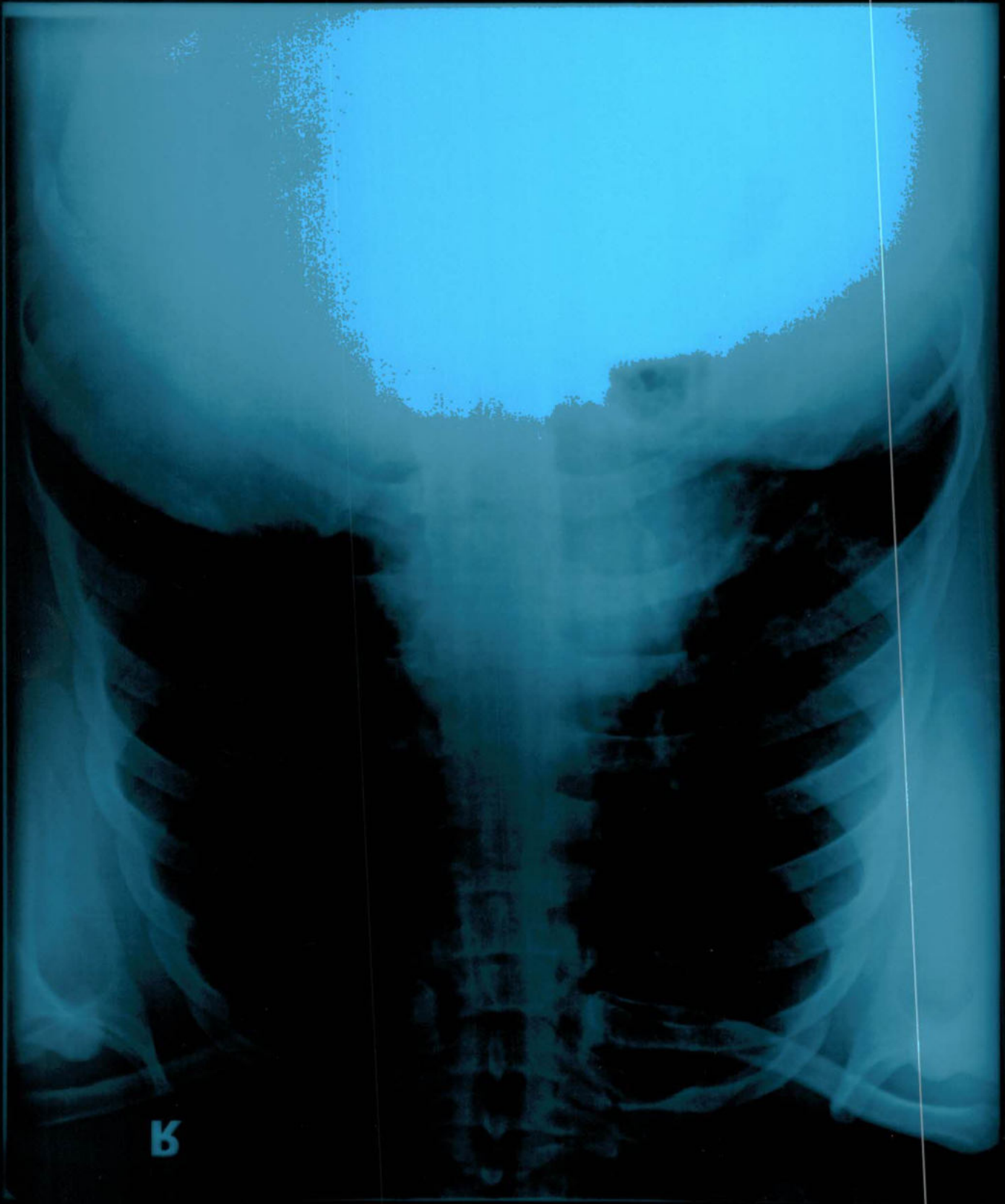
DR. POOJA GARG
RADIOLOGIST
REG NO- DMC/R/03398
M.B.B.S.
Radiologist

Type By : darshita

47, Harsh Vihar, Pitampura, New Delhi-110034 | Ph.: 011-42480101, 9599913051

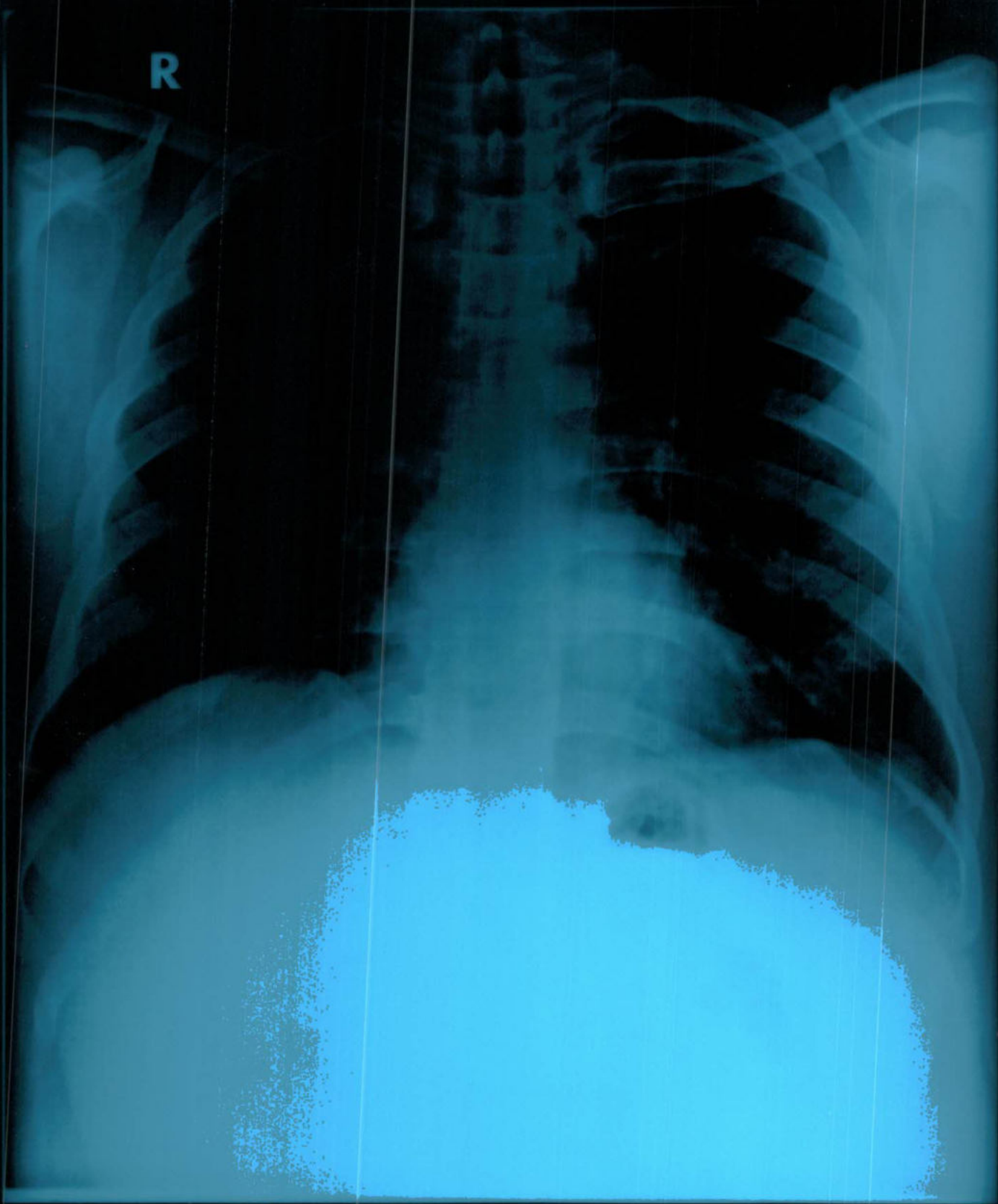
E-mail: oneplusul@gmail.com | Web.: www.oneplusul.in

ОИЕБГУС ПГТРАСОПИД ГАВ.АТ-НАРГН АИНАР РИТАМЬУРА
РАВЛИД КУМАР ЗАУМ 0110413033 M CHEST PA VIEW



B

R



PARVIND KUMAR 29Y/M 01/04/2023 M CHEST PA VIEW
ONEPLUS ULTRASOUND LAB 47-HARSH VIHAR.PITAMPURA