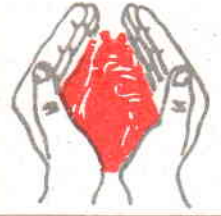




Shiva Cardiac Lab.

& Diagnostic Research Centre Pvt. Ltd.



Near Chaurasia Nursing Home, Chhipi Tank, Meerut.

Ph.: 2664558, 9412578957
7669508292, 8449796280

MR.NAVNEET KUMAR VERMA
44 YRS / MALE
REF BY : B.O.B.
JULY. 28. 2021

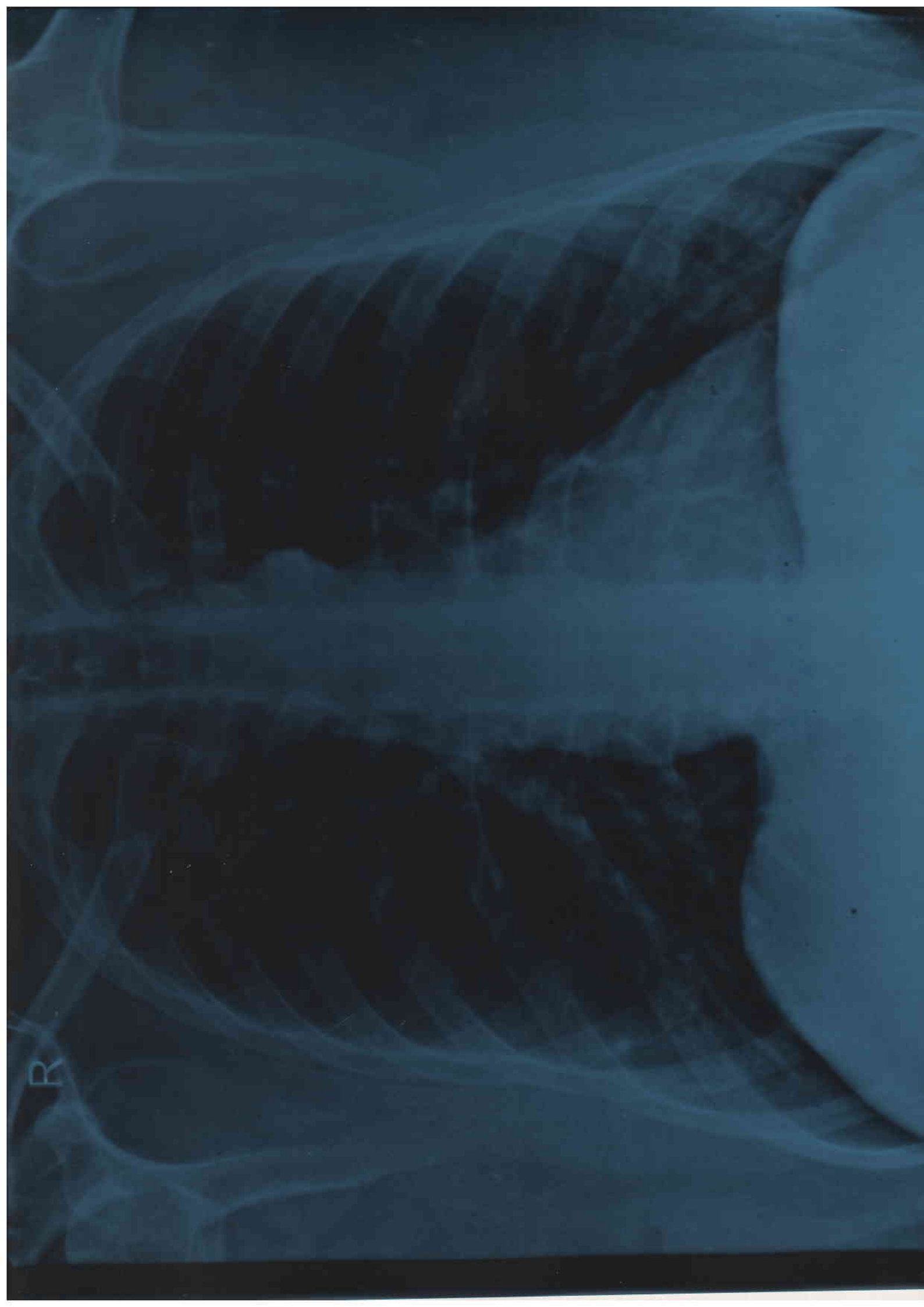
RADIOGRAPH CHEST PA VIEW (IN DEEP INSPIRATION)

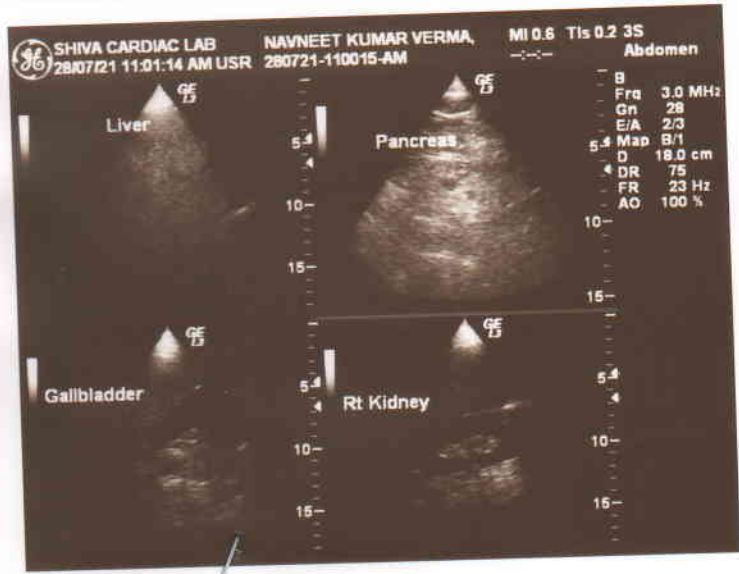
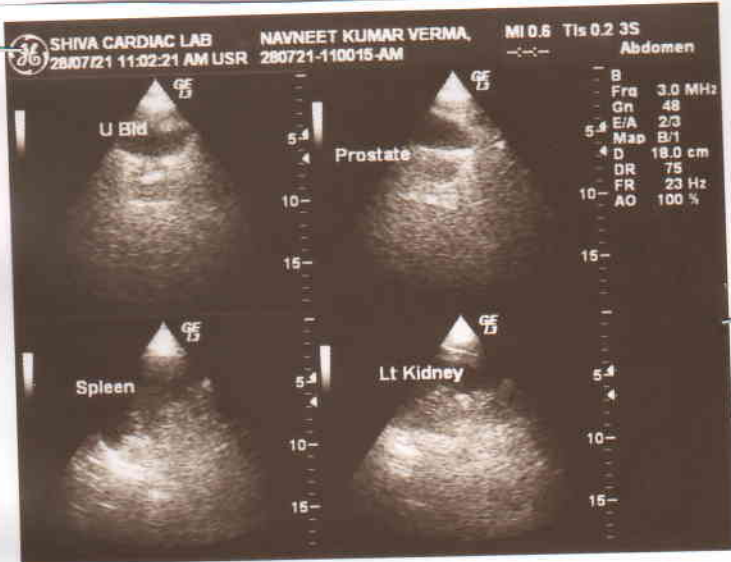
- * Bony cage and soft tissues are normal.
- * Trachea is central.
- * Both hila are normal.
- * Both CP angle are clear.
- * Cardiac size is normal.
- * Both domes of diaphragm are normal.
- * Both lungs fields are normal.
- * **Vascular markings are prominent.**

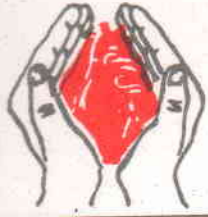CONSULTANT
DR. TANUJ GARG
MD.(RAD.)

NOTE : All modern Machines/Procedures have their limitation, if there is a variance clinically, this examination may be repeated or re-evaluated by other investigations.

NOT FOR MEDICO-LEGAL PURPOSE

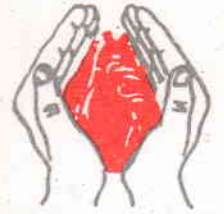





Shiva Cardiac Lab.

& Diagnostic Research Centre Pvt. Ltd.



Near Chaurasia Nursing Home, Chhipi Tank, Meerut.

Ph.: 2664558, 9412578957

7669508292, 8449796280

Name : MR.NAVNEET KUMAR VERMA
Age/sex : 44 YRS / MALE
Ref by : B.O.B
Date : 28.07.2021

ULTRASOGRAPHY WHOLE ABDOMEN

LIVER is normal in size, Grade 1 fatty changes seen.

Echotexture also normal

No focal abnormal echogenic lesion seen.

CBD is normal.(6mm) Portal vein also normal.

I.H. Biliary channels are not dilated. Dome movements are not restricted.

GALL BLADDER –

Is normal in size shape and echotexture.

Wall thickness normal.

No stone or mass seen.

KIDNEYS –

Both kidneys are normal in size shape & echo texture

Cortico-medulary distinction normal on Both side.

No stone seen both side.

No evidence of hydronephrosis seen on Both side.

PANCREAS is normal in size & shape and echo texture.

Head body and tail normal.

SPLEEN is normal in size.. No evidence of focal lesion.

PROSTATE is normal in size.

Echotexture is normal

Capsule is intact.

URINARY BLADDER

Is well distended with normal wall thickness and contour.

No calculus / growth seen

No lymph nodes , pleural effusion , or ascites is seen.

IMP- FATTY LIVER (GR 1).

CONSULTANT: 
DR S.CHARAN
MD.(SONOLOGIST)

NOTE : All modern Machines/Procedures have their limitation, if there is a variance clinically, this examination may be repeated or re-evaluated by other investigations.

NOT FOR MEDICO-LEGAL PURPOSE