

भारत सरकार
Government of India

केशवर पासवान
Keshwar Paswan

जन्म तिथि/DOB: 07/01/1970
पुरुष / Male

2986 6548 7805

आधार - आम आदमी का अधिकार

आधार
Unique Identification Authority of India

पता: S/O: सुखदेव पासवान
हाउस नं-668/9, गली नं-2
श्री नगर के पास
शकुर बस्ती नई दिल्ली, सरस्वती विहार
सरस्वती विहार, उत्तर पश्चिम, दिल्ली
110034

Address: S/O: Sukhdeo
Paswan, House no-668/9,
Gali no-2, Near Sri Nagar,
Shakur Basti New Delhi,
Saraswati Vihar, Saraswati
Vihar, North West Delhi,
Delhi, 110034

2986 6548 7805

1800 300 1947 help@uidai.gov.in www.uidai.gov.in

Dr. NITIN AGARWAL
MBBS, MD
Regn. No. DMC-R-1436


ONEPLUS ULTRASOUND LAB
47, Harsh Vihar, Pitam Pura,
Delhi-110034
Ph. 011-42480101, 9599913051
E-mail: oneplusul@gmail.com

1900

1900

1900

1900



[Handwritten signature]

[Handwritten signature]
Dr. NITIN AGARWAL
MBBS, MD
Regn. No. DMC-R-1436

ONEPLUS ULTRASOUND LAB
47, Harsh Vihar, Pitam Pura,
Delhi-110034
Ph. 011-42490101, 9599913051
E-mail: oneplusul@gmail.com



OnePLUS
Ultrasound Lab
— QUALITY FIRST... ALWAYS! —

Dr. Nitin Agarwal
Pathologist & Director
Ex. Sr. Res. MAMC
& Lok Nayak Hospital
Ex. Chief of Lab Dr. Lal Path Labs.

Dr. Pooja (Garg) Agarwal
Radiologist & Director
MAMC & Lok Nayak Hospital



NAME	:Mr. KESHAV PASWAN	Barcode No	:10137059
AGE/GENDER	:53 YRS/Male	SPECIMEN DATE	:03/Feb/2023 09:18AM
PATIENT ID	:108622	SPECIMEN RECEIVED	:03/Feb/2023 09:26AM
REFERRED BY	:Dr. MEDIWHEEL	REPORT DATE	:03/Feb/2023 03:09PM
CENTRE NAME	:ONEPLUS ULTRASOUND LAB	LAB NO.	:012302030011

Test Name	Result	Unit	Ref. Range
-----------	--------	------	------------

HAEMATOLOGY

Medi Wheel Health checkup < 40 Male

Glycosylated Hemoglobin (HbA1c)	5.5	%	Non Diabetic adults <5.7 Prediabetic (at risk) 5.7-6.4 Diabetes >6.4
--	-----	---	--

Estimated average blood glucose (eag)	111
Reference range (mg/dl):	

90 - 120:Excellent control, 121 - 150:Good Control, 151 - 180:Average Control, 181 - 210:Action Suggested

>211:Panic value

BLOOD GROUP (ABO)	AB
Rh typing	POSITIVE

NOTE :

- * Apart from major A,B,H antigens which are used for ABO grouping and Rh typing, many minor blood group antigens exist. Agglutination may also vary according to titre of antigen and antibody.
- * So before transfusion, reconfirmation of blood group as well as cross-matching is needed.
- * Presence of maternal antibodies in newborns, may interfere with blood grouping.
- * Auto agglutination (due to cold antibody, falciparum malaria, sepsis, internal malignancy etc.) may also cause erroneous result.

CBC

Haemoglobin	12.2	g/dl	13.0-17.0
Total Leucocyte Count	6300	/cumm	4000-10000
Differential leucocyte count			
Neutrophils	71.8	%	40-80
Lymphocyte	23.00	%	20-40
Monocytes	3.00	%	2-10
Eosinophils	2.0	%	1-6
Basophils	0.2	%	0-2
RBC Count	4.20	million/cumm	4.5 - 5.5

Checked By.

DR. NITIN AGARWAL
MBBS, MD (Pathologist)
M B B S . MD (Path)
DMC/R/01436

47, Harsh Vihar, Pitampura, New Delhi-110034 | Ph.: 011-42480101, 9599913051

E-mail: oneplusul@gmail.com | Web.: www.oneplusul.in

Page 1 of 6

Clinical correlation is essential for final diagnosis. * If test results are unsatisfactory please contact personally or on phone. * This report is for perusal of doctors only. * All disputes Subject to Delhi Jurisdiction only. * Not for medicolegal purposes. * All congenital anomalies in a foetus may not be diagnosed in routine obstetric ultrasound.



OnePLUS

Ultrasound Lab

— QUALITY FIRST... ALWAYS! —

Dr. Nitin Agarwal
Pathologist & Director
Ex. Sr. Res. MAMC
& Lok Nayak Hospital
Ex. Chief of Lab Dr. Lal Path Labs.

Dr. Pooja (Garg) Agarwal
Radiologist & Director
MAMC & Lok Nayak Hospital



NAME	:Mr. KESHAV PASWAN	Barcode No	:10137059
AGE/GENDER	:53 YRS/Male	SPECIMEN DATE	:03/Feb/2023 09:18AM
PATIENT ID	:108622	SPECIMEN RECEIVED	:03/Feb/2023 09:26AM
REFERRED BY	:Dr. MEDIWHEEL	REPORT DATE	:03/Feb/2023 03:09PM
CENTRE NAME	:ONEPLUS ULTRASOUND LAB	LAB NO.	:012302030011

Test Name	Result	Unit	Ref. Range
PCV(Hematocrit)	39.3	%	40-50
MCV	93.9	fL	83-101
MCH	29.2	Pg	27-32
MCHC	31.1	G/dL	32-35
Platelet count	112000	/cumm	150000-450000
RDW-CV	14.5	%	11.4-14.0
ESR(WESTEGRENs METHOD)	15	mm in 1st hr	0-20

BIOCHEMISTRY

<u>Blood sugar fasting</u>	107	mg/dL	70-110
<u>Blood sugar pp</u>	131	mg/dL	70.0-140.0
<u>Bun (blood urea nitrogen)</u>	11.20	mg/dl	8.4-25.7
<u>Uric acid, serum</u>	4.7	mg/dl	3.5-7.2
<u>Creatinine, serum</u>	0.7	mg/dl	0.60-1.2

LFT(LIVER FUNCTION TEST)

Bilirubin Total	0.44	mg/dl	0.1-1.2
Bilirubin Conjugated	0.29	mg/dl	0-0.4
Bilirubin Unconjugated	0.15	mg/dl	up to 0.7
SGOT (AST)	19	U/L	0-46
SGPT (ALT)	41	U/L	0-49
Alkaline phosphatase	89	U/L	40-129
Gamma glutamyl transpeptidase	25	U/L	10-45
Total Protein	7.0	gm/dl	6.60 - 8.70
Albumin serum	3.9	g/dL	3.0-5.2
Globulin	3.10	gm/dl	1.8-3.4
Albumin/Globulin Ratio	1.26		1.10 - 2.50

LIPID PROFILE

Cholesterol	96	mg/dl	50-200
Triglycerides	105	mg/dL	25-150

Checked By.

DR. NITIN AGARWAL
MBBS, MD (Path)
MAMC/R/01436
MBBS, MD (PATHOLOGIST)

47, Harsh Vihar, Pitampura, New Delhi-110034 | Ph.: 011-42480101, 9599913051

E-mail: oneplusul@gmail.com | Web.: www.oneplusul.in

Page 2 of 6

Clinical correlation is essential for final diagnosis. * If test results are unsatisfactory please contact personally or on phone. * This report is for perusal of doctors only. * All disputes Subject to Delhi Jurisdiction only. * Not for medicolegal purposes. * All congenital anomalies in a foetus may not be diagnosed in routine obstetric ultrasound.



OnePLUS

Ultrasound Lab

— QUALITY FIRST... ALWAYS! —

Dr. Nitin Agarwal
Pathologist & Director
Ex. Sr. Res. MAMC
& Lok Nayak Hospital
Ex. Chief of Lab Dr. Lal Path Labs.

Dr. Pooja (Garg) Agarwal
Radiologist & Director
MAMC & Lok Nayak Hospital



NAME	:Mr. KESHAV PASWAN	Barcode No	:10137059
AGE/GENDER	:53 YRS/Male	SPECIMEN DATE	:03/Feb/2023 09:18AM
PATIENT ID	:108622	SPECIMEN RECEIVED	:03/Feb/2023 09:26AM
REFERRED BY	:Dr. MEDIWHEEL	REPORT DATE	:03/Feb/2023 03:09PM
CENTRE NAME	:ONEPLUS ULTRASOUND LAB	LAB NO.	:012302030011

Test Name	Result	Unit	Ref. Range
HDL Cholesterol	45	mg/dL	40 - 60
LDL cholesterol	30	mg/dL	<130
VLDL cholesterol	21.0	mg/dL	5-40
Cholesterol/HDL Ratio	2.1		Low Risk 3.3-4.97 Average Risk 4.4-7.1 Moderate Risk 7.1-11.0 High Risk >11.0
LDL/HDL Ratio	0.7		0 - 3.55

According to ATP III and NCEP guidelines

Parameter	Normal	Desirable	Borderline	High
Total cholesterol	<200		200-239	240
Triglycerides	<150	150-199	200-499	500
LDL	Optimal <100 Near Optimal 100-129	130-159	160-180	190
HDL	<40 : LOW 60 : HIGH			

BUN/Creatinine ratio

Bun (blood urea nitrogen)	11.20	mg/dl	8.4-25.7
CREATININE	0.70	mg/dl	0.30-1.10
BUN/Creatinine ratio	16.00		10.0 - 20.0

ENDOCRINOLOGY

THYROID PROFILE(T3,T4,TSH)

Triiodothyronine total [t3]	0.78	ng/dl	0.52-1.9
Thyroxine total [t4]	4.90	µg/dl	4.4 - 10.8
TSH (Thyroid Stimulating Hormone)	2.50	µU/ml	0.25-5.0

AGE WISE VARIATION IN TSH

Checked By.

DR. NITIN AGARWAL
MBBS, MD (PATHOLOGY)
BBS, MD (Path)
MAMC/R/01436

47, Harsh Vihar, Pitampura, New Delhi-110034 | Ph.: 011-42480101, 9599913051

E-mail: oneplusul@gmail.com | Web.: www.oneplusul.in

Page 3 of 6

Clinical correlation is essential for final diagnosis. * If test results are unsatisfactory please contact personally or on phone. * This report is for perusal of doctors only. * All disputes Subject to Delhi Jurisdiction only. * Not for medicolegal purposes. * All congenital anomalies in a foetus may not be diagnosed in routine obstetric ultrasound.



OnePLUS

Ultrasound Lab

— QUALITY FIRST... ALWAYS! —

Dr. Nitin Agarwal
Pathologist & Director
Ex. Sr. Res. MAMC
& Lok Nayak Hospital
Ex. Chief of Lab Dr. Lal Path Labs.

Dr. Pooja (Garg) Agarwal
Radiologist & Director
MAMC & Lok Nayak Hospital



NAME	:Mr. KESHAV PASWAN	Barcode No	:10137059
AGE/GENDER	:53 YRS/Male	SPECIMEN DATE	:03/Feb/2023 09:18AM
PATIENT ID	:108622	SPECIMEN RECEIVED	:03/Feb/2023 09:26AM
REFERRED BY	:Dr. MEDIWHEEL	REPORT DATE	:03/Feb/2023 03:09PM
CENTRE NAME	:ONEPLUS ULTRASOUND LAB	LAB NO.	:012302030011

Test Name	Result	Unit	Ref. Range
AGE	TSH(μIU/ml)	AGE	TSH(μIU/ml)
1-4 weeks	1.00 - 19.0	16-20 yrs	0.25 - 5.0
1-12 mths	1.70 - 9.1	21 - 80 yrs	0.25 - 5.0
1-5 yrs	0.80 - 8.2	I st trimester	0.25 - 5.0
6-10 yrs	0.25 - 5.0	II nd trimester	0.50 - 5.0
11-15 yrs	0.25 - 5.0	II rd trimester	0.4 - 6.0

Reference ranges - Interpretation of Diagnostic tests - (Jacques Wallach)

1. Primary hypothyroidism is accompanied by depressed serum T3 and T4 values and elevated serum TSH level.
2. Primary hyperthyroidism is accompanied by elevated serum T3 and T4 levels along with depressed TSH values.
3. Slightly elevated T3 levels may be found in pregnancy and estrogen therapy, while depressed levels may be encountered in severe illness, renal failure and during therapy with drugs like propranolol and propyl thiouracil.
4. Although elevated TSH levels are nearly always indicative of primary hypothyroidism, and may be seen in secondary thyrotoxicosis

Checked By.

Dr. NITIN AGARWAL
MBBS, MD (P)
DMC/R/01436
NITIN AGARWAL
MBBS, MD (PATHOLOGIST)

47, Harsh Vihar, Pitampura, New Delhi-110034 | Ph.: 011-42480101, 9599913051

E-mail: oneplusul@gmail.com | Web.: www.oneplusul.in

Page 4 of 6



OnePLUS
Ultrasound Lab
— QUALITY FIRST... ALWAYS! —

Dr. Nitin Agarwal

Pathologist & Director
Ex. Sr. Res. MAMC
& Lok Nayak Hospital
Ex. Chief of Lab Dr. Lal Path Labs.

Dr. Pooja (Garg) Agarwal

Radiologist & Director
MAMC & Lok Nayak Hospital



NAME	:Mr. KESHAV PASWAN	Barcode No	:10137059
AGE/GENDER	:53 YRS/Male	SPECIMEN DATE	:03/Feb/2023 09:18AM
PATIENT ID	:108622	SPECIMEN RECEIVED	:03/Feb/2023 11:05AM
REFERRED BY	:Dr. MEDIWHEEL	REPORT DATE	:03/Feb/2023 12:56PM
CENTRE NAME	:ONEPLUS ULTRASOUND LAB	LAB NO.	:012302030011

Test Name	Result	Unit	Ref. Range
-----------	--------	------	------------

CLINICAL PATHOLOGY

URINE ROUTINE

Physical examination

Quantity	20		ML
Colour	PALE YELLOW		
Transparency	CLEAR		CLEAR
Sp.gravity	1.010		1.010-1.030
pH	6.00		
Reaction	ACIDIC		ACIDIC

Chemical examination

Urine protein	NIL		NIL
Urine sugar	NIL		NIL
Bilirubin, urine	NEGATIVE		NEGATIVE
Urobilinogen	NORMAL		NORMAL
Ketones	NEGATIVE		NEGATIVE

Microscopic examination

Pus cells.	1-2	/HPF	0-2
Epithelial cells	2-3	/HPF	NIL
R.B.C.	NIL	/HPF	NIL
Casts	NIL	/HPF	NIL
Crystals	NIL	/HPF	NIL
Bacteria	NIL	/HPF	NIL
Others.	NIL	NIL	NIL

Checked By.

Dr NITIN AGARWAL
M B B S , MD (Path)
DMC/R/01436
DR. NITIN AGARWAL
MBBS,MD(PATHOLOGIST)

47, Harsh Vihar, Pitampura, New Delhi-110034 | Ph.: 011-42480101, 9599913051

E-mail: oneplusul@gmail.com | Web.: www.oneplusul.in

Page 5 of 6

Clinical correlation is essential for final diagnosis. • If test results are unsatisfactory please contact personally or on phone. • This report is for perusal of doctors only. • All disputes Subject to Delhi Jurisdiction only. • Not for medicolegal purposes. • All congenital anomalies in a foetus may not be diagnosed in routine obstetric ultrasound.



OnePLUS Ultrasound Lab

— QUALITY FIRST... ALWAYS! —

Dr. Nitin Agarwal

Pathologist & Director
Ex. Sr. Res. MAMC
& Lok Nayak Hospital
Ex. Chief of Lab Dr. Lal Path Labs.

Dr. Pooja (Garg) Agarwal

Radiologist & Director
MAMC & Lok Nayak Hospital



NAME	:Mr. KESHAV PASWAN	Barcode No	:10137059
AGE/GENDER	:53 YRS/Male	SPECIMEN DATE	:03/Feb/2023 09:18AM
PATIENT ID	:108622	SPECIMEN RECEIVED	:03/Feb/2023 12:31PM
REFERRED BY	:Dr. MEDIWHEEL	REPORT DATE	:03/Feb/2023 03:09PM
CENTRE NAME	:ONEPLUS ULTRASOUND LAB	LAB NO.	:012302030011

Test Name	Result	Unit	Ref. Range
-----------	--------	------	------------

CLINICAL PATHOLOGY

STOOL ROUTINE

Physical examination

Colour	BROWNISH		
Consistency	SEMILOOSE		Semi Formed
Blood	ABSENT		Absent
Mucus	ABSENT		Absent

Chemical examination, stool

pH	6.50		
----	------	--	--

Microscopic examination

Pus cells	0-1	/HPF	
R.B.C.	NIL	/HPF	NIL
Ova	NIL		NIL
Cysts	NIL		NIL
Bacteria	PRESENT	/HPF	NIL
Others	NIL		

*** End Of Report ***

Checked By.

Dr. NITIN AGARWAL
MBBS, MD (Path)
DMC/R/01436
DR. NITIN AGARWAL
MBBS,MD(PATHOLOGIST)

47, Harsh Vihar, Pitampura, New Delhi-110034 | Ph.: 011-42480101, 9599913051

E-mail: oneplusul@gmail.com | Web.: www.oneplusul.in

Page 6 of 6

Clinical correlation is essential for final diagnosis. • If test results are unsatisfactory please contact personally or on phone. • This report is for perusal of doctors only. • All disputes Subject to Delhi Jurisdiction only. • Not for medicolegal purposes. • All congenital anomalies in a foetus may not be diagnosed in routine obstetric ultrasound.

ONEPLUS ULTRASOUND LAB

47, HARSH VIHAR, PITAMPURA, DELHI- 110034

Mr. KESHAV PASWAN
Age : 53/M
Ref. by : MEDIWHEEL
Indication1 :
Indication2 :
Indication3 :
COMMENTS : Normal ECG.

ID : 2096
H/Wt : 166/80
Recorded : 3-2-2023 10:36
Medication1 :
Medication2 :
Medication3 :

BPM : 80
BP : 136/86
P Axis : 37 deg
QRS Axis : 50 deg
T Axis : 40 deg

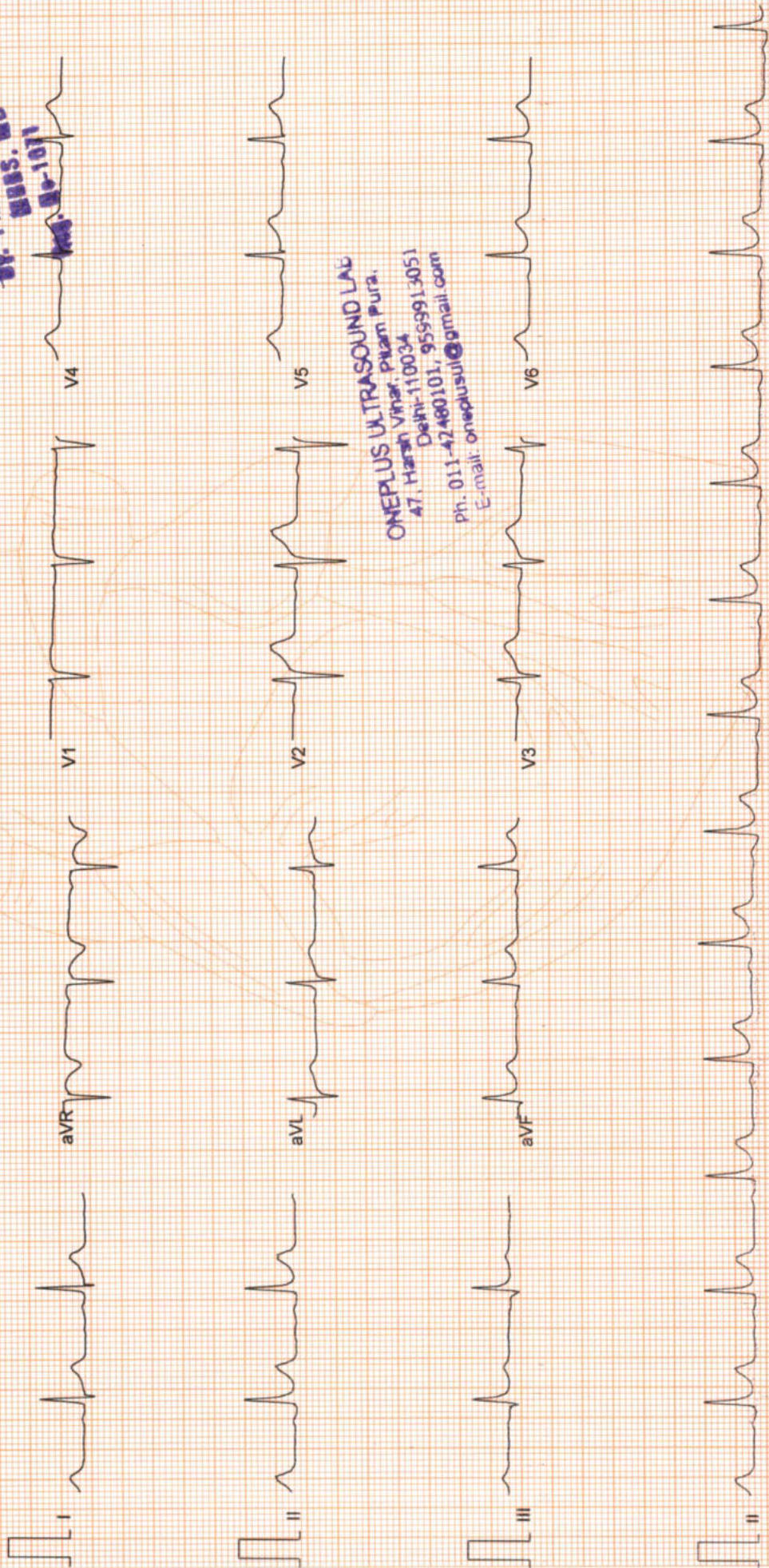
P duration : 90 msec
PR duration : 160 msec
QRS duration : 100 msec
QT interval : 310 msec
QTc interval : 345 msec

Raw E.C.G. (Seq)

Unconfirmed Report Reviewed By:

Cardiologist

Dr. P. E. GUPTA
MBBS. MD
Reg. No-1071



ONEPLUS ULTRASOUND LAB
47, Harsh Vihar, Pitampura,
Delhi-110034
Ph: 011-47480101, 9599913051
E-mail: oneplusul@gmail.com

ONEPLUS ULTRASOUND LAB

47, HARSH VIHAR PITAMPURA DELHI 110034

Mr. KESHAV PASWAN
Age/Sex : 53/M
Ref. by : MEDIWHEEL
Indication1 :
Indication2 :
Indication3 :

ID : 996
Ht/Wt : 168/80
Recorded : 3-2-2023 10:41

TREADMILL TEST SUMMARY REPORT
Protocol: BRUCE
History:
Medication1 :
Medication2 :
Medication3 :

PHASE	PHASE TIME	STAGE TIME	SPEED (Km./Hr.)	GRADE (%)	H.R. (BPM)	B.P. (mmHg)	RPP X100	II	ST LEVEL (mm) V2	V5	METS
STANDING SUPINE					79	136/86	107	0.8	2.1	0.8	
					79	136/86	107	0.8	2.1	0.8	
STAGE 1	2:59	2:59	2.70	10.00	107	136/86	145	0.9	3.3	1.4	4.80
STAGE 2	5:59	2:59	4.00	12.00	127	146/88	185	0.4	3.0	1.2	7.10
STAGE 3	7:29	1:29	5.40	14.00	145	160/90	232	0.5	2.4	0.8	8.54
PEAK EXER	7:39	1:39			148	160/90	236	0.3	2.5	0.7	8.70
RECOVERY	2:59	2:59	0.00	0.00	93	136/86	126	0.3	1.5	0.3	

RESULTS

Exercise Duration : 7:39 Minutes
Max Heart Rate : 148 bpm 88 % of target heart rate 167 bpm
Max Blood Pressure : 160/90 mmHg
Max Work Load : 8.70 METS
Reason of Termination :

Negative for ischemia

ONEPLUS ULTRASOUND LAB
47, Harsh Vihar, Pitam Pura,
Delhi-110034
Ph. 011-42460101, 9599915051
E-mail: onepul@ul@gmail.com

[Signature]
Dr. P.K. GUPTA
MBBS, MD
Reg. No-1071
Cardiologist

ONEPLUS ULTRASOUND LAB

Mr. KESHAV PASWAN
I.D. : 996

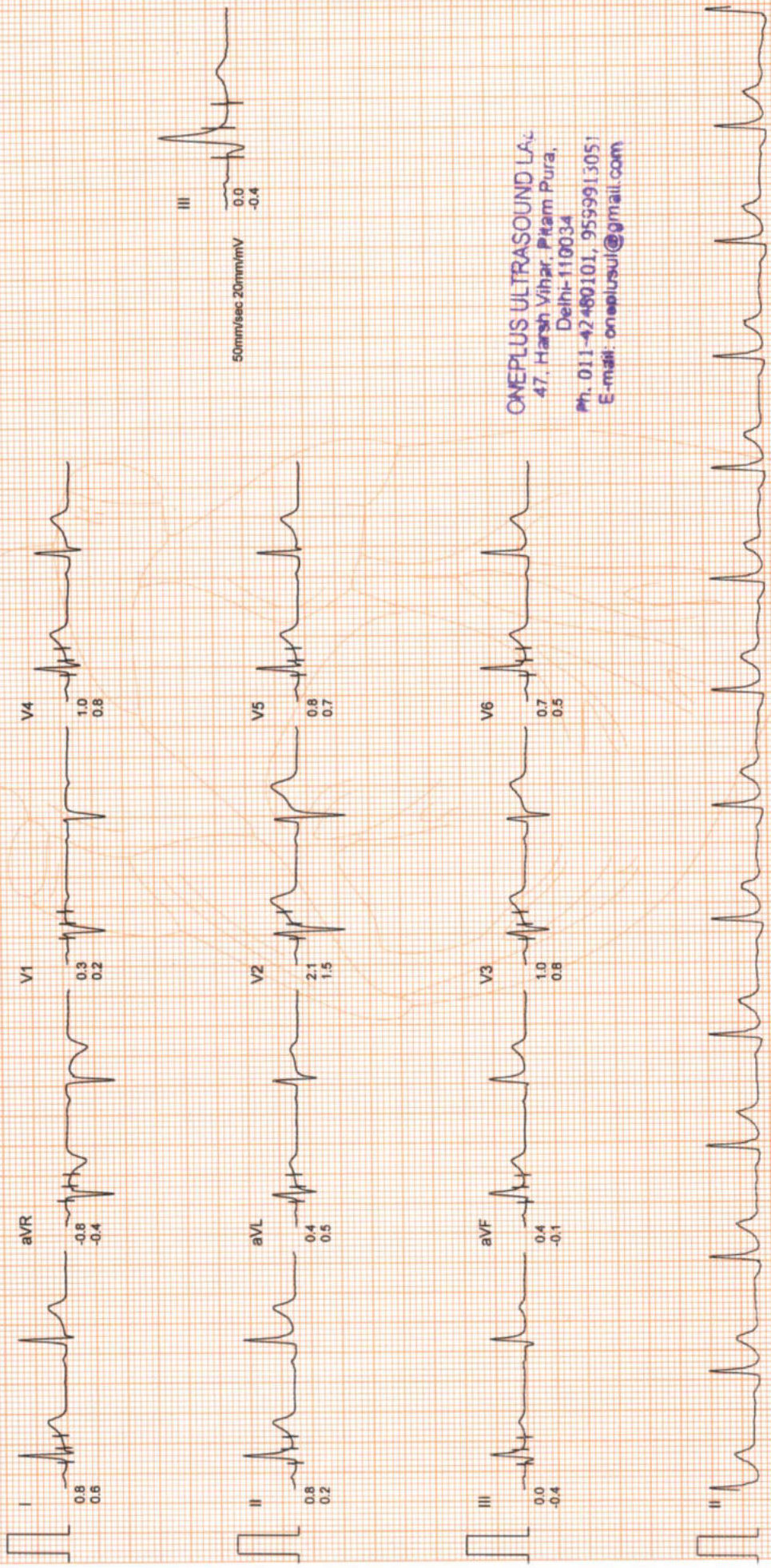
AGE/SEX : 53/M
RECORDED : 3-2-2023 10:41

RATE : 79 BPM
B.P. : 136/86 mmHg

ST @ 10mm/mV
80ms PostJ

STANDING
PRETEST

LINKED MEDIAN



ONEPLUS ULTRASOUND LAB.
47, Harsh Vihar, Pitam Pura,
Delhi-110034
Ph. 011-42480101, 9599913051
E-mail: onepulsul@gmail.com

ONEPLUS ULTRASOUND LAB

Mr. KESHAV PASWAN
I.D. : 996

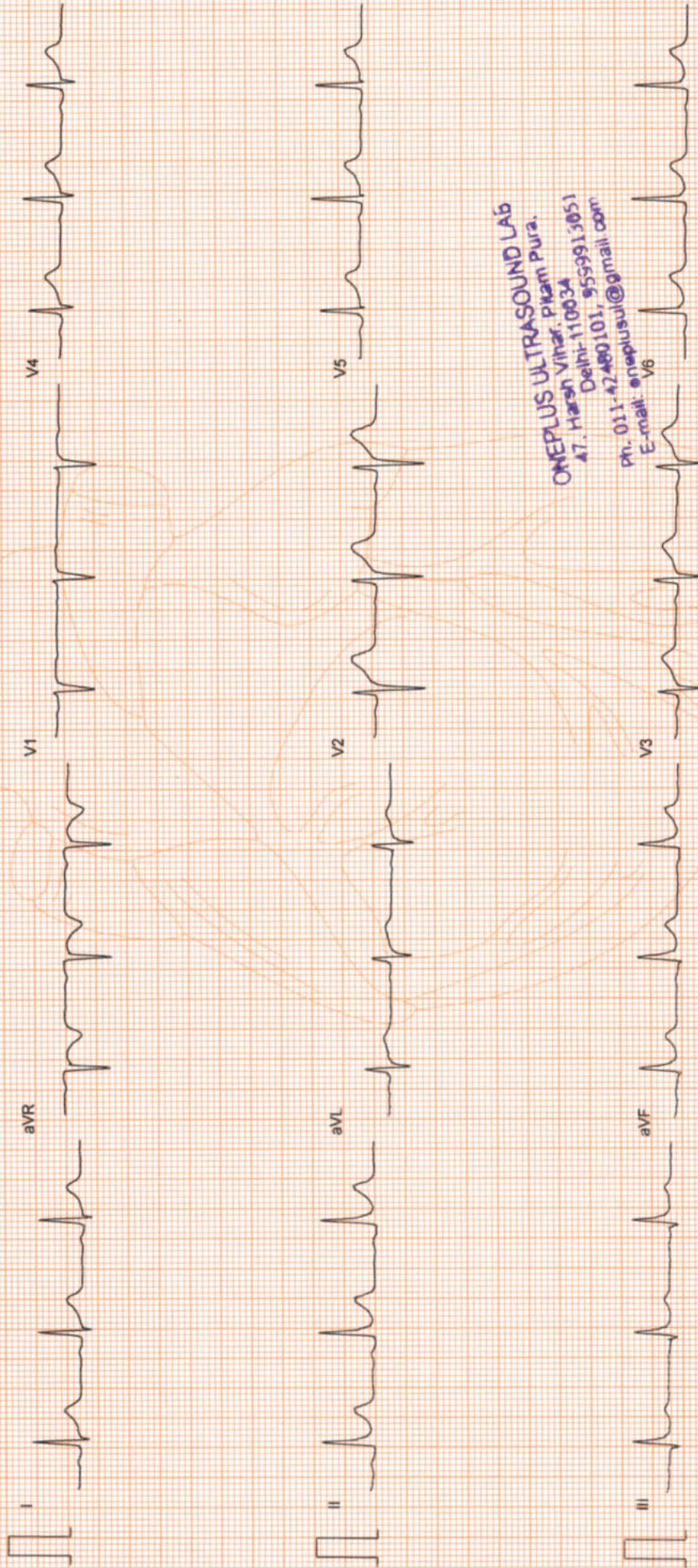
AGE/SEX : 53/M
RECORDED : 3-2-2023 10:41

RATE : 79 BPM
B.P. : 136/86 mmHg

ST @ 10mm/mV
80ms PostJ

SUPINE
PRETEST

RAW E.C.G.



ONEPLUS ULTRASOUND LAB
A7, Harsh Vihar, Pitam Pura,
Delhi-110034
Ph. 011-42480101, 9559913851
E-mail: oneplusul@gmail.com
V6

ONEPLUS ULTRASOUND LAB

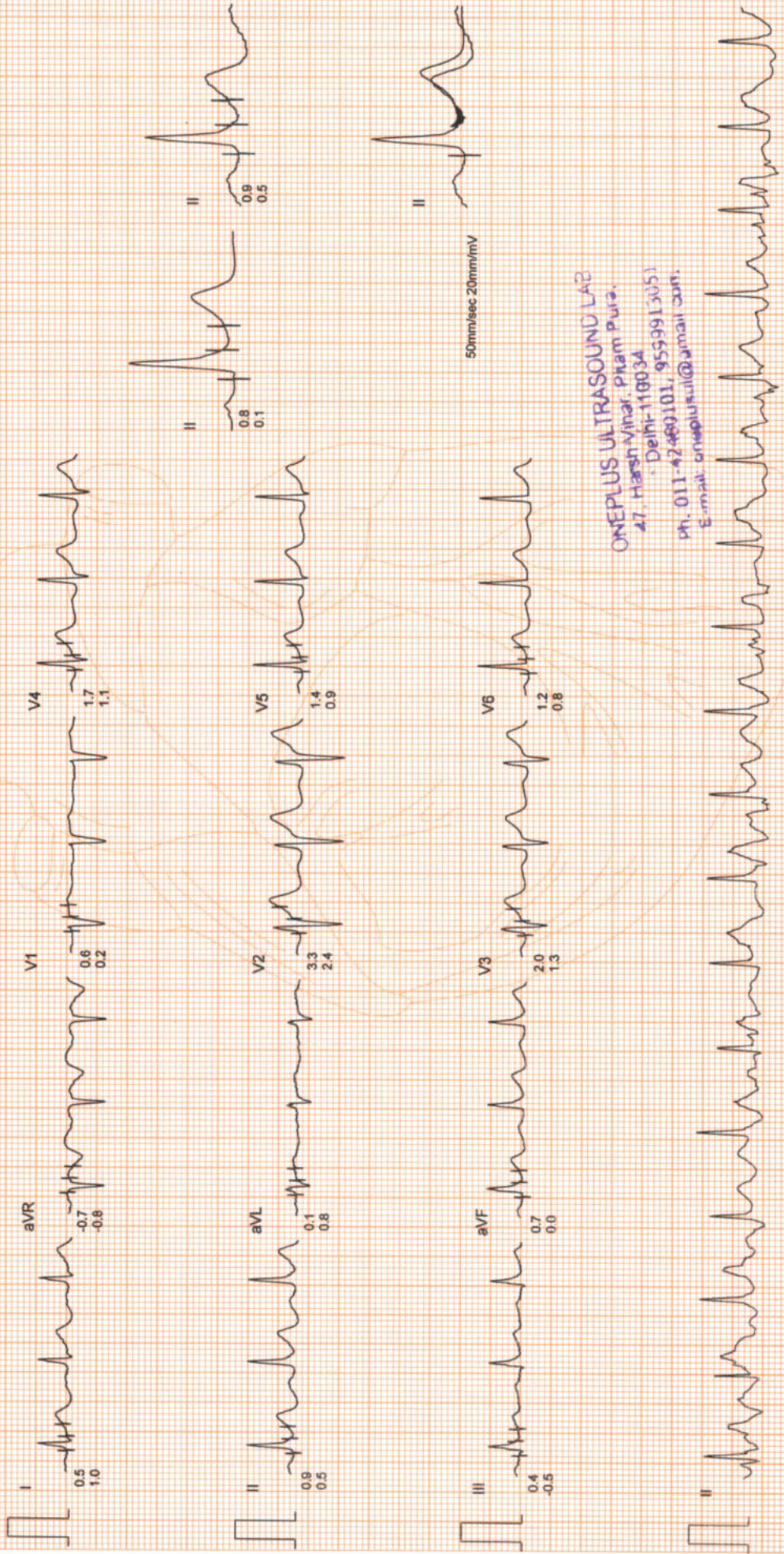
Mr. KESHAV PASWAN
I.D. : 996

AGE/SEX : 53/M
RECORDED : 3-2-2023 10:41

BRUCE
EXERCISE 1
PHASE TIME : 2:59
STAGE TIME : 2:59

ST @ 10mm/mV
80ms PostJ
SPEED : 2.7 Km./Hr.
GRADE : 10.0 %

LINKED MEDIAN



ONEPLUS ULTRASOUND LAB
47, Harsh Vihar, Pitam Pura,
Delhi-110034
Ph. 011-42469101, 9559913051
E-mail: oneplusul@ymail.com



ONEPLUS ULTRASOUND LAB

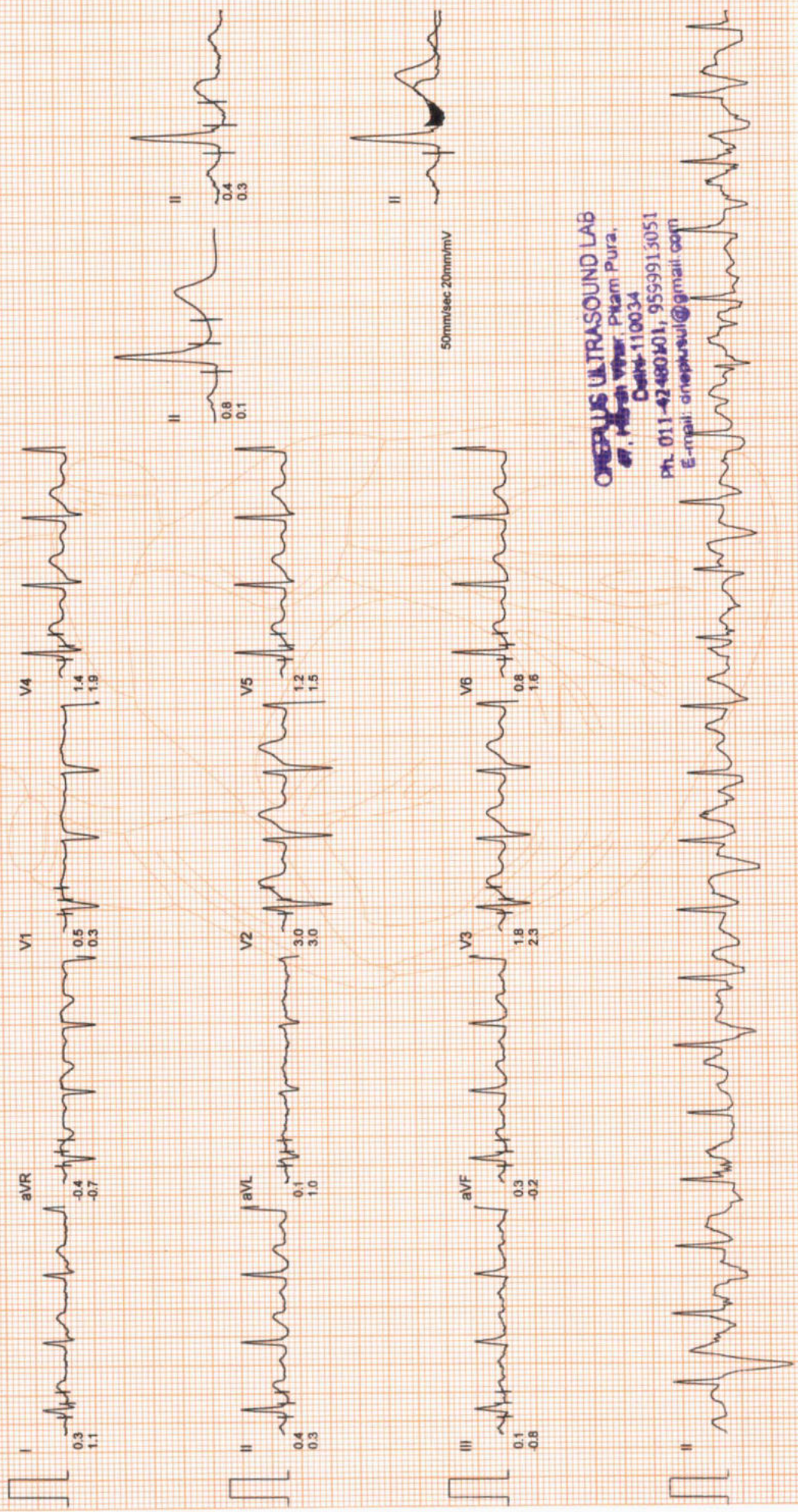
Mr. KESHAV PASWAN
I.D. : 996

AGE/SEX : 53/M
RECORDED : 3- 2-2023 10:41

BRUCE
EXERCISE 2
PHASE TIME : 5:59
STAGE TIME : 2:59

ST @ 10mm/mV
80ms PostJ
SPEED : 4.0 Km/Hr.
GRADE : 12.0 %

LINKED MEDIAN



ONEPLUS ULTRASOUND LAB
Dr. Mohan Kumar Pitam Pura,
Dattoli-110034
Ph. 011-42480401, 9559913051
E-mail: onepusul@gmail.com



ONEPLUS ULTRASOUND LAB

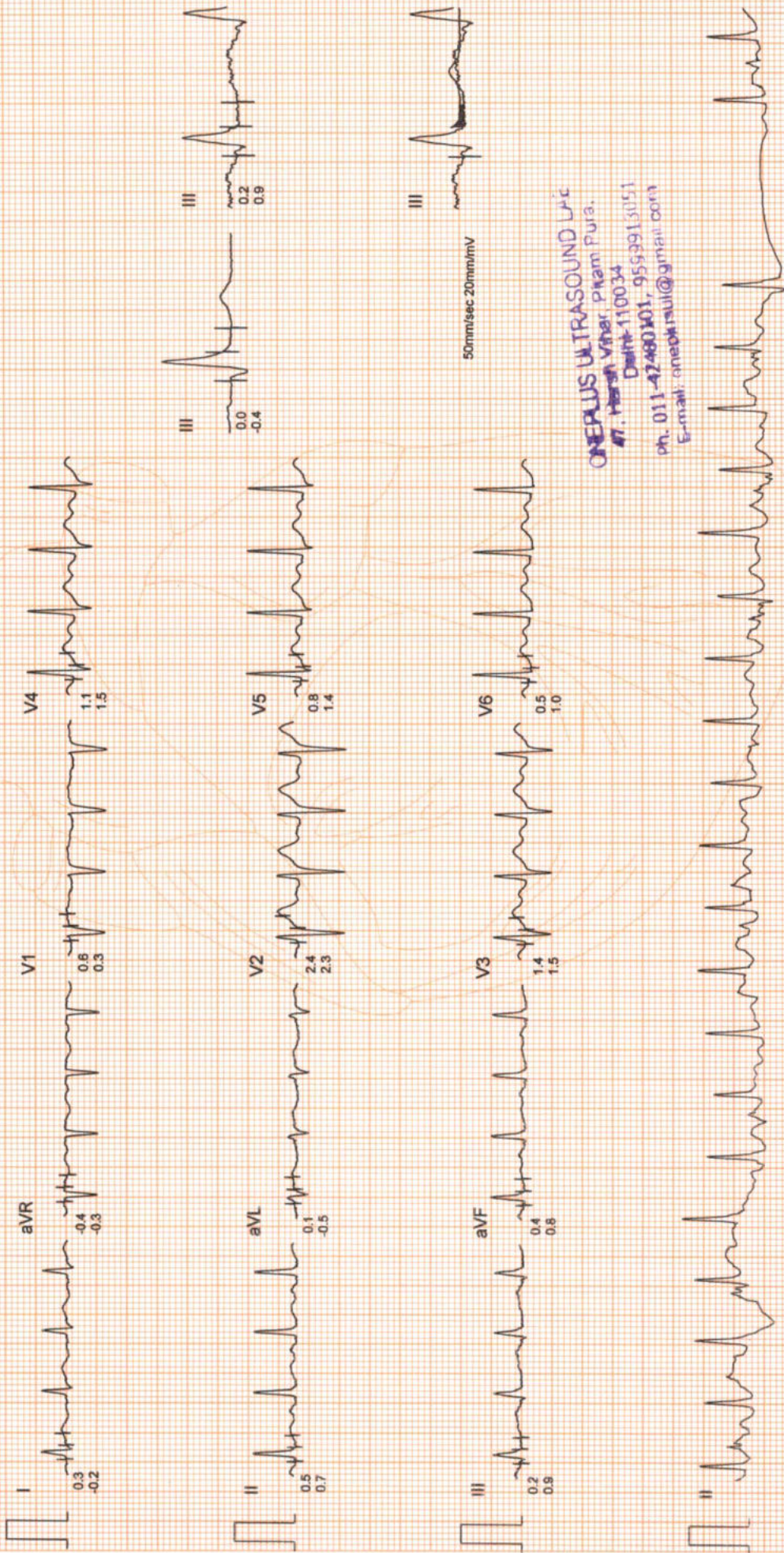
Mr. KESHAV PASWAN
I.D. : 996

AGE/SEX : 53/M
RECORDED : 3-2-2023 10:41
RATE : 145 BPM
B.P. : 160/90 mmHg

BRUCE
EXERCISE 3
PHASE TIME : 7:29
STAGE TIME : 1:29

ST @ 10mm/mV
80ms PostJ
SPEED : 5.4 Km./Hr.
GRADE : 14.0 %

LINKED MEDIAN



ONEPLUS ULTRASOUND Lab
47, Harsh Vihar, Pitam Pura,
Delhi-110034
Ph. 011-42460301, 9559913151
E-mail: oneplusul@ gmail.com

10

ONEPLUS ULTRASOUND LAB

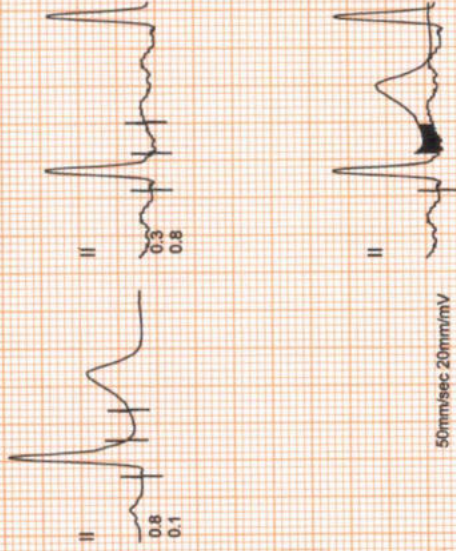
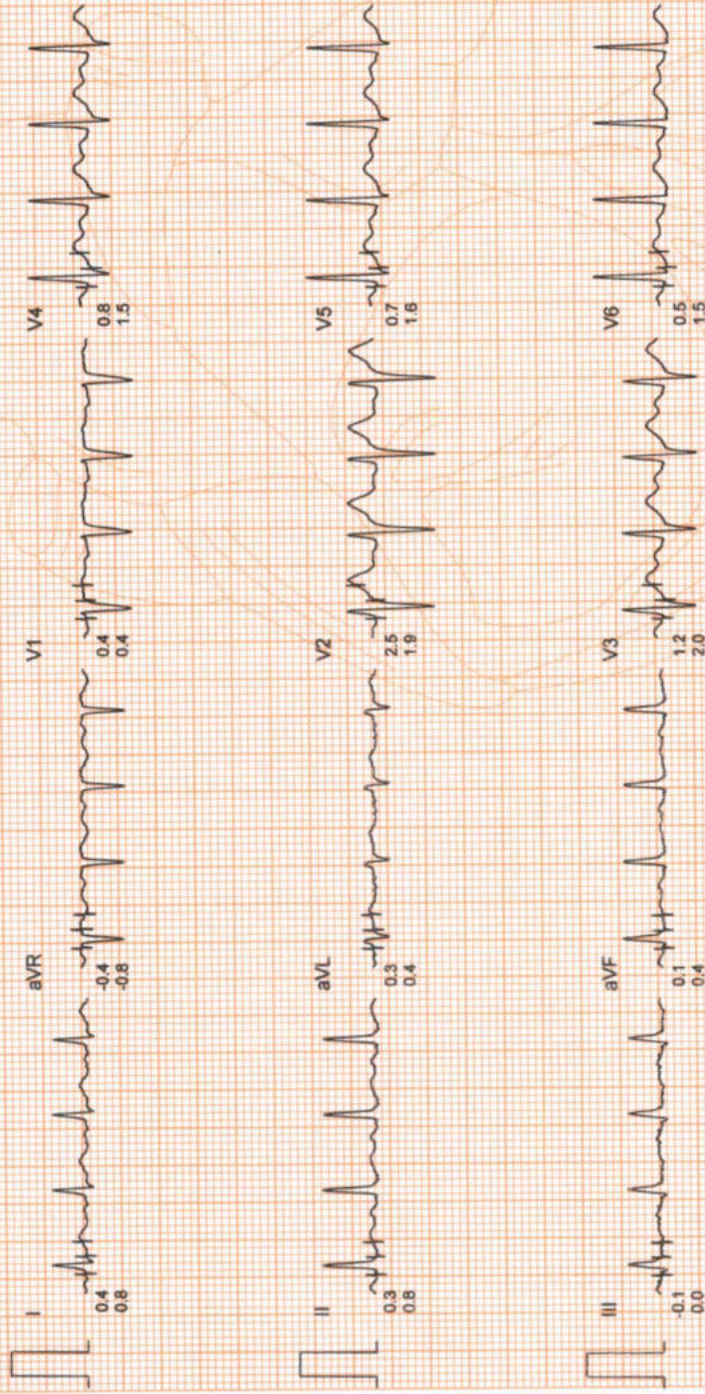
Mr. KESHAV PASWAN
I.D. : 996

AGE/SEX : 53/M
RECORDED : 3-2-2023 10:41

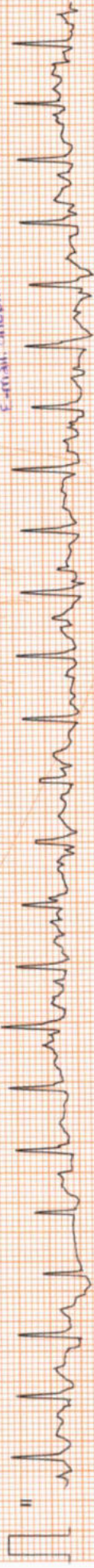PHASE TIME : 7:39
STAGE TIME : 1:39

ST @ 10mm/mV
80ms PostJ
SPEED : 5.4 Km./Hr.
GRADE : 14.0 %

LINKED MEDIAN



ONEPLUS ULTRASOUND LAB
47, Maran Vihar, Phariyapalli,
Dahli-110034
Ph. 011-42480101, 9552911051
E-mail: oneplusul@jmesa.co.in



ONEPLUS ULTRASOUND LAB

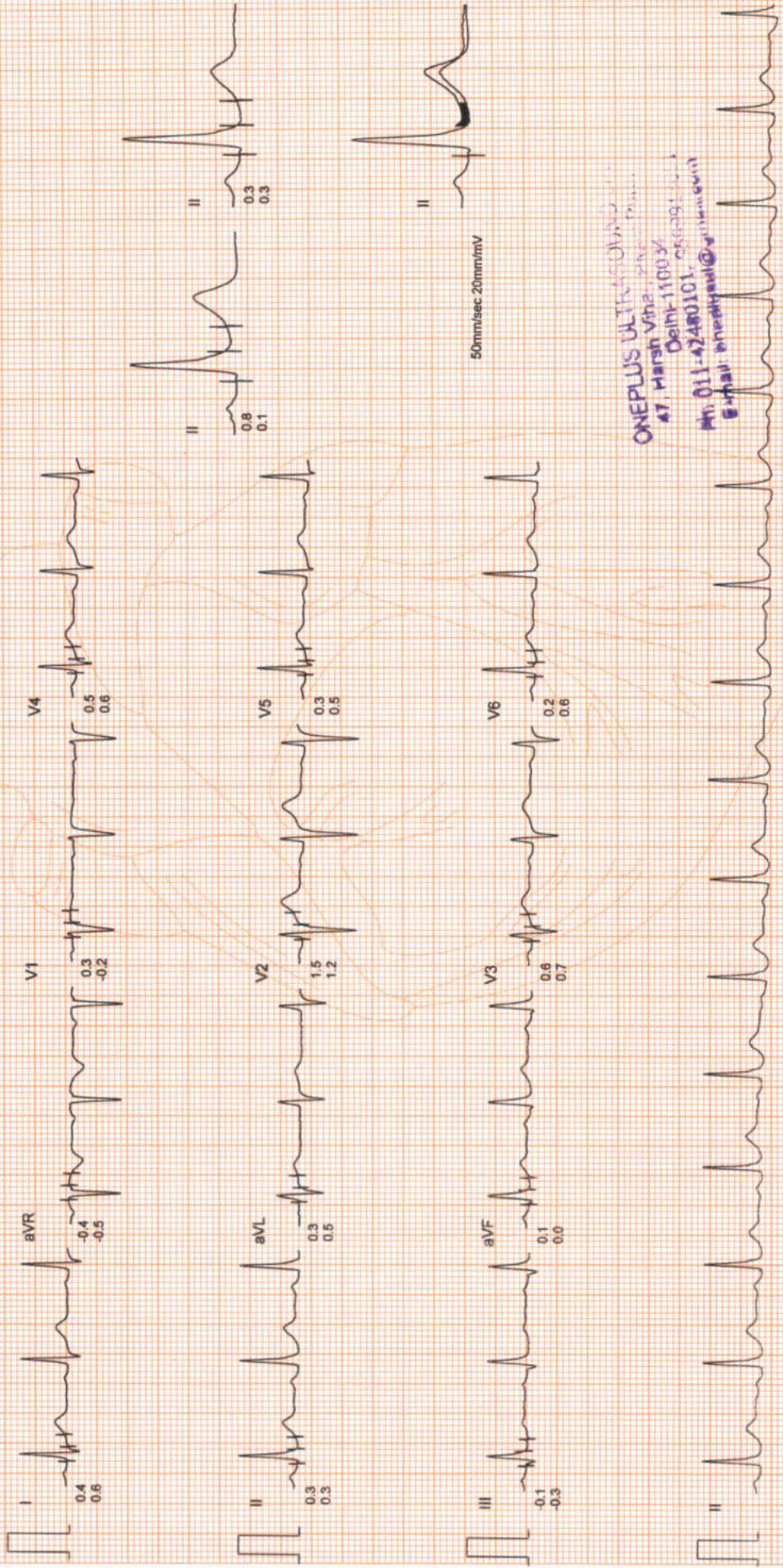
Mr. KESHAV PASWAN
I.D. : 996

AGE/SEX : 53/M
RECORDED : 3-2-2023 10:41

BRUCE
RECOVERY
PHASE TIME : 2:59

ST @ 10mm/mV
60ms Postd
SPEED : 0.0 Km./Hr.
GRADE : 0.0 %

LINKED MEDIAN



ONEPLUS ULTRASOUND LAB
47, Marsh Vihar, Phase II, Paschim
Delhi-110036
Ph: 011-42480101, 25509150
E-mail: keshavk@oneplusultrasound.com

50mm/sec 20mm/mV

ONEPLUS ULTRASOUND LAB

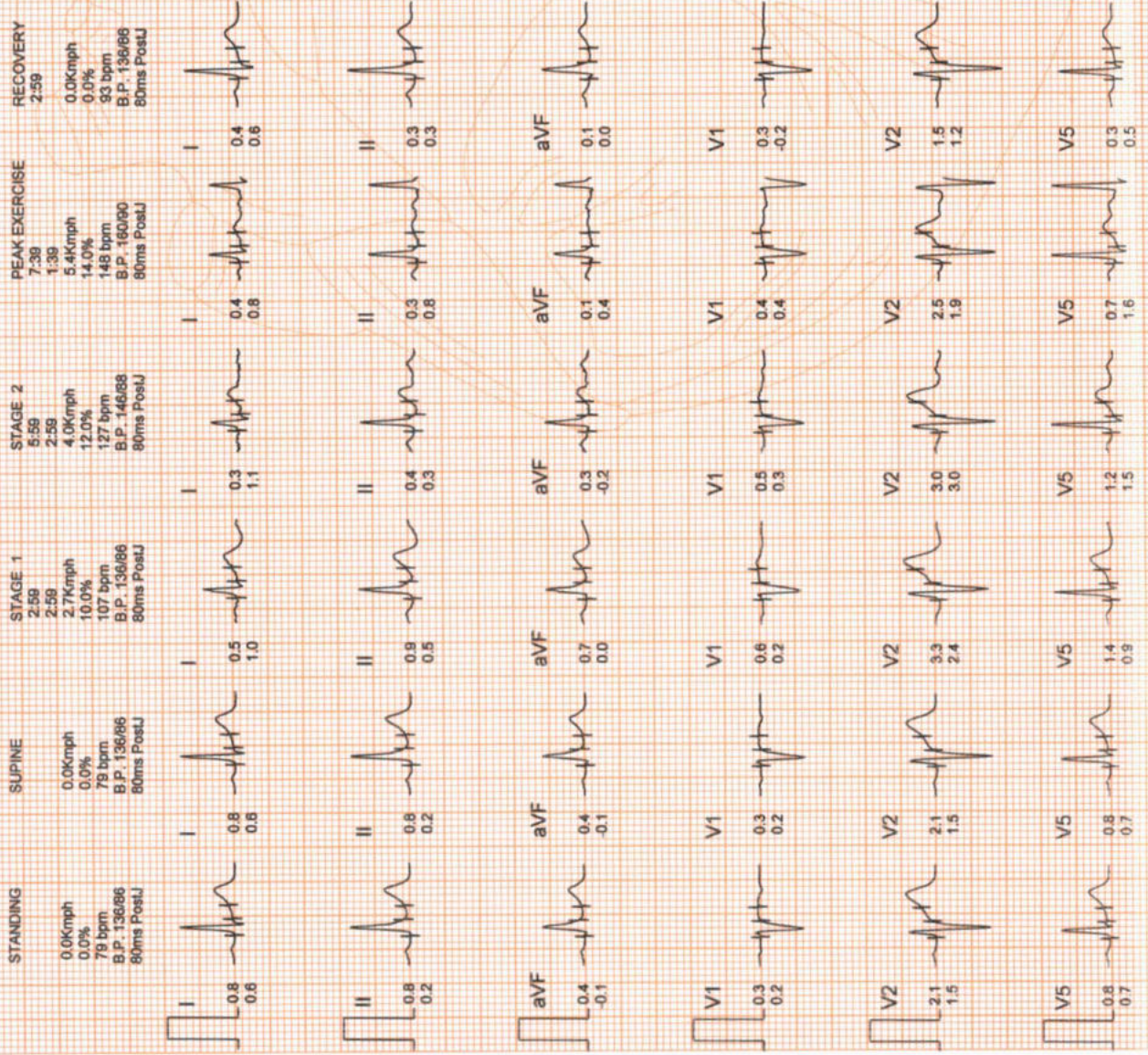
I.D. : 996

Mr. KESHAV PASWAN

RECORDED : 3-2-2023 10:41

AGE/SEX : 53/M

AVG E.C.G.



ONEPLUS ULTRASOUND LAB
 Dr. Harsh Vihar, Pitam Pura,
 Delhi-110034
 Ph: 011-42480101, 9599913031
 E-Mail: kshetramani@gmail.com

ONEPLUS ULTRASOUND LAB

AGE/SEX : 53/M

I.D. : 996

Mr. KESHAV PASWAN

RECORDED : 3-2-2023 10:41

COMPARISON REPORT

PEAK EXERCISE

7:39
1:39
5.4Kmph
14.0%
148 bpm
B.P. 160/80
80ms PostJ

SUPINE

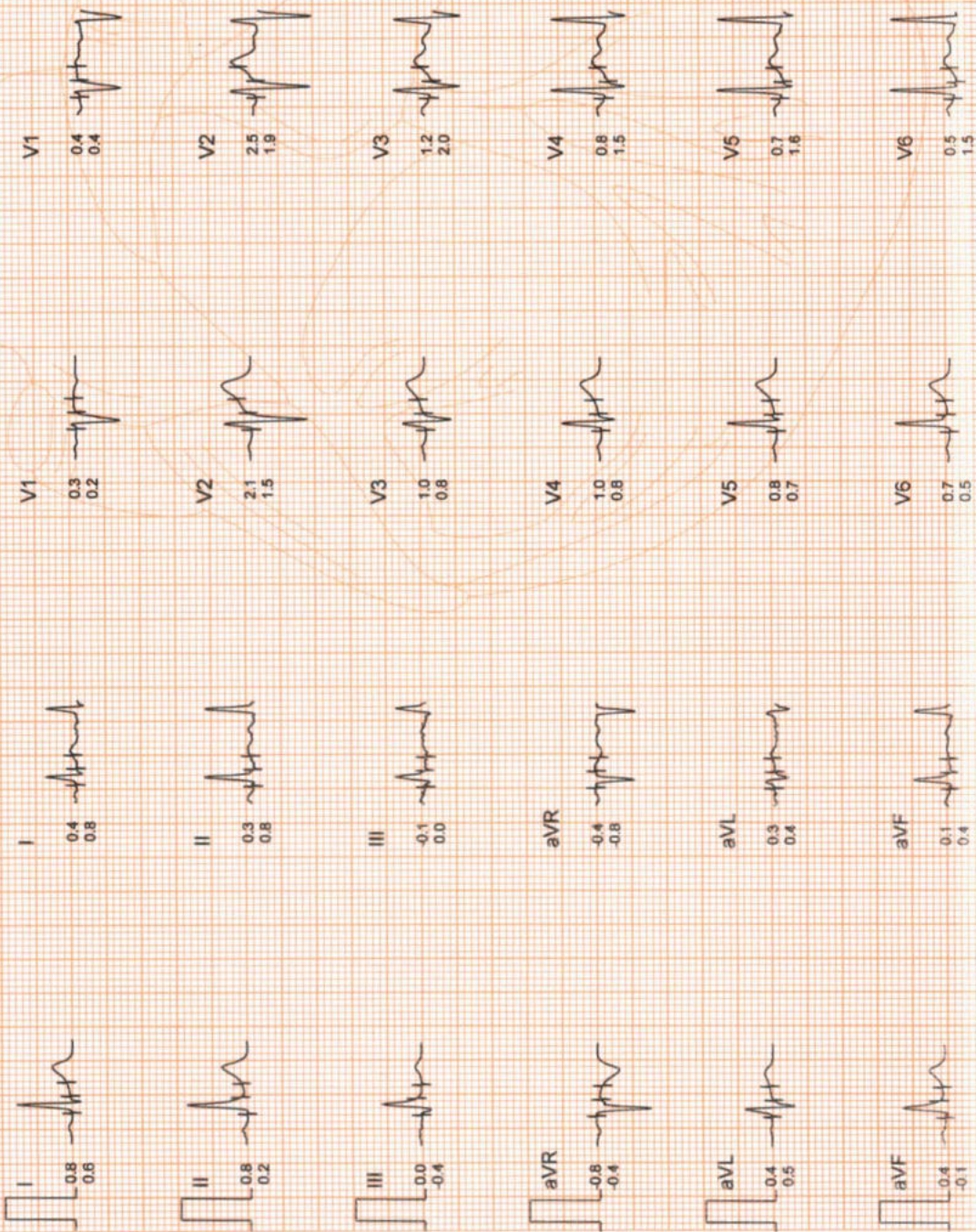
0.0Kmph
0.0%
75 bpm
B.P. 136/86
80ms PostJ

PEAK EXERCISE

7:39
1:39
5.4Kmph
14.0%
148 bpm
B.P. 160/80
80ms PostJ

SUPINE

0.0Kmph
0.0%
75 bpm
B.P. 136/86
80ms PostJ



ONEPLUS ULTRASOUND Lab
47, Harsh Vihar, Pitam Pura,
Delhi-110034
Ph. 011-42480101, 9559913051
E-mail: oneplusul@gnail.com

Name	: Mr. KESHAV PASWAN	Age/Sex	: 53 YRS/Male
Ref. By	: Dr. MEDIWHEEL	Lab No	: 012302030011
Date	: 03-Feb-2023	Patient ID	: LSHHI108622

ULTRASOUND EXAMINATION----WHOLE ABDOMEN

Liver is normal in size (14.3 cm) and outline with altered echopattern. **Diffuse increase in echogenicity of liver parenchyma is noted, suggestive of fatty infiltration (grade II).** No abscess or mass lesion seen. Hepatic veins, portal vein, IVC and aorta are normal. Intrahepatic biliary radicles are not dilated. CBD is normal in caliber (3.8 mm).

Gall bladder is not seen (Post op).

Both kidneys are normal in size, shape, position, outline and echopattern. Corticomedullary differentiation is maintained. No pelvicalyceal dilation or mass lesion is seen. **An exophytic simple cortical cyst (sized 55 x 51 mm) is seen at lower pole of right kidney. Few smaller simple cortical cysts are seen at upper and mid pole of left kidney, largest measuring upto 18 x 14 mm.**

Spleen is normal in size and echotexture. No mass lesion seen.

Pancreas is normal in size, outline and echotexture .

Urinary bladder is normal in shape and position. No evidence of intravesical stone or mass seen.

Prostate is normal in size, shape and echopattern.


Prostate measures 3.7 x 3.2 x 2.8 cm. **Weight of prostate is 18.0 grams.**

No abnormal bowel wall thickening seen in right iliac fossa.

No free fluid seen anywhere in abdomen.

IMPRESSION:

- **Fatty infiltration of liver (grade II) with no hepatomegaly.**

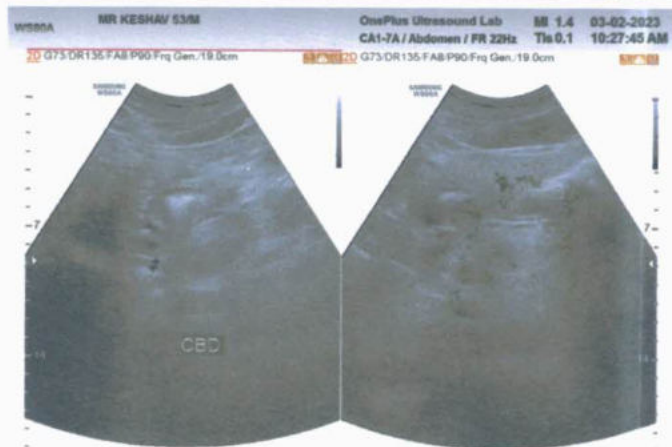
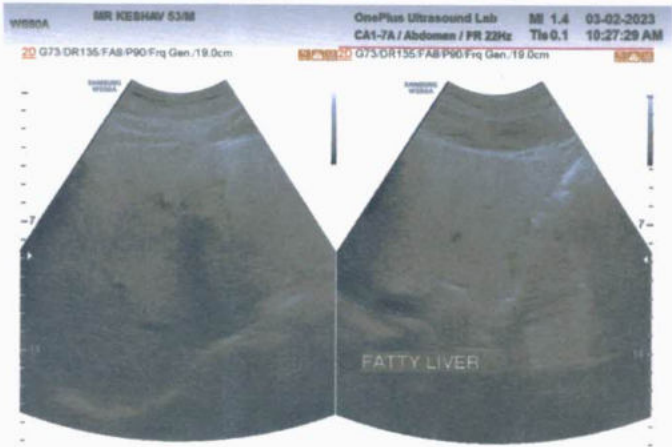

DR. POOJA GARG
RADIOLOGIST
REG NO- DMC/R/03398

DR. POOJA GARG
M.B.B.S., D.M.R.D
Reg No. DMC/R/03398
Radiologist

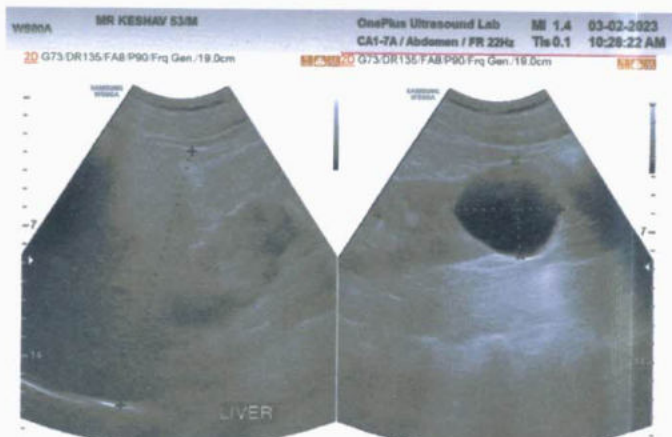
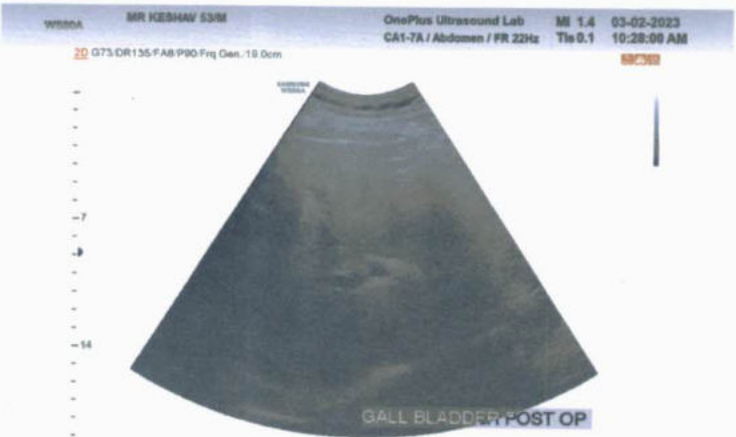Type By : darshita

47, Harsh Vihar, Pitampura, New Delhi-110034 | Ph.: 011-42480101, 9599913051

E-mail: oneplusul@gmail.com | Web.: www.oneplusul.in

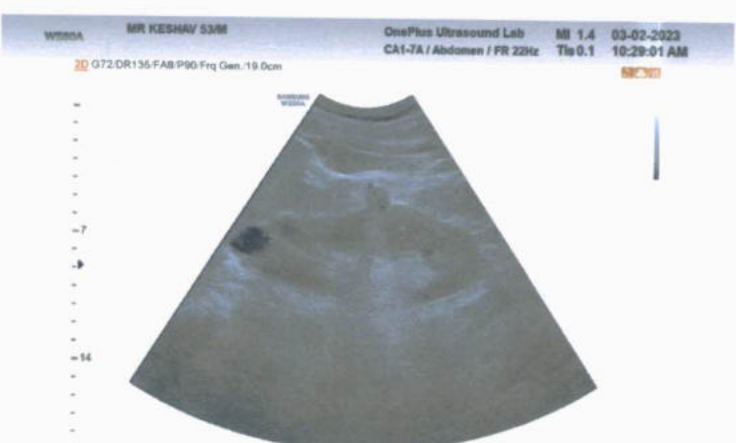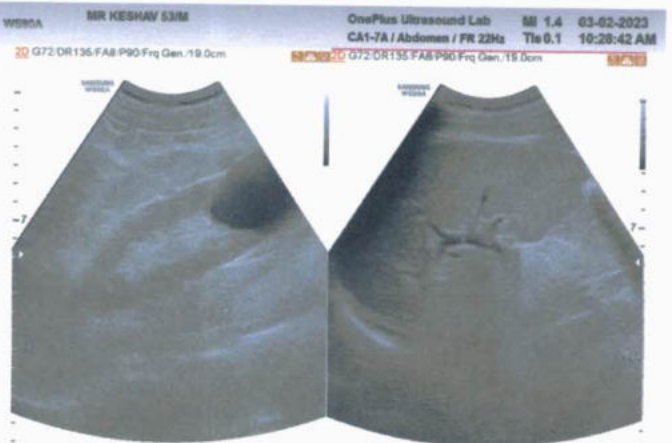


D1 0.38 cm

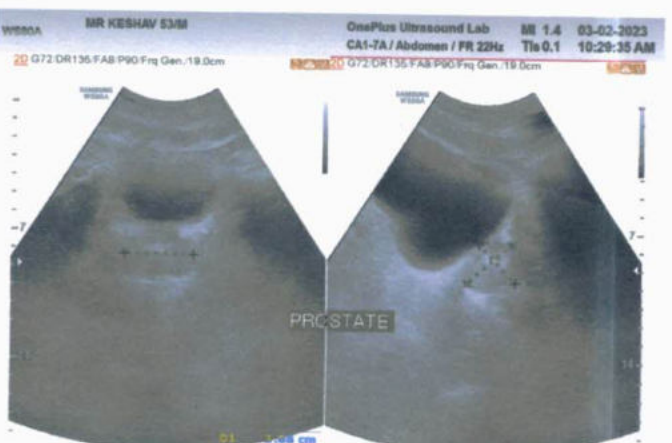
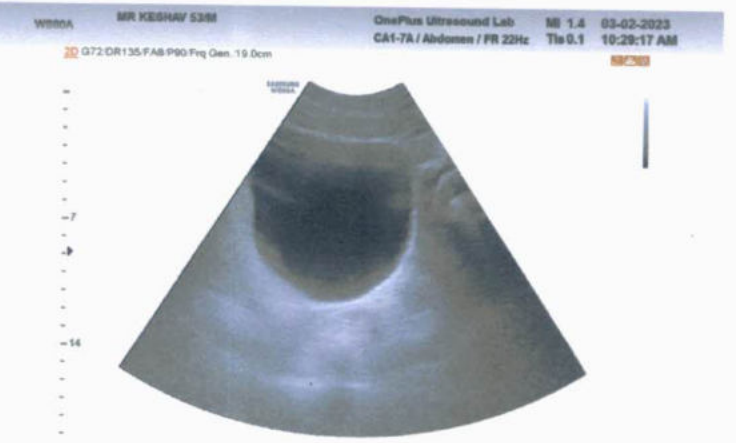


D3 14.32 cm

D1 8.94 cm
D2 8.17 cm



D1 1.82 cm
D2 1.40 cm



D1 3.08 cm
D2 3.21 cm
D3 3.72 cm
Vol. 18.02 ml


D1 2.89 cm
D2 3.21 cm



NAME: [illegible] ID: [illegible]
 DATE: [illegible] TIME: [illegible]
 LOCATION: [illegible]



NAME: [illegible] ID: [illegible]
 DATE: [illegible] TIME: [illegible]
 LOCATION: [illegible]



NAME: [illegible] ID: [illegible]
 DATE: [illegible] TIME: [illegible]
 LOCATION: [illegible]



NAME: [illegible] ID: [illegible]
 DATE: [illegible] TIME: [illegible]
 LOCATION: [illegible]



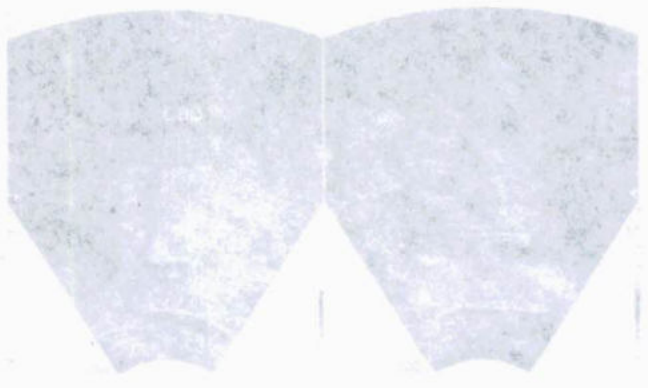
NAME: [illegible] ID: [illegible]
 DATE: [illegible] TIME: [illegible]
 LOCATION: [illegible]



NAME: [illegible] ID: [illegible]
 DATE: [illegible] TIME: [illegible]
 LOCATION: [illegible]



NAME: [illegible] ID: [illegible]
 DATE: [illegible] TIME: [illegible]
 LOCATION: [illegible]



NAME: [illegible] ID: [illegible]
 DATE: [illegible] TIME: [illegible]
 LOCATION: [illegible]



OnePLUS
Ultrasound Lab
— QUALITY FIRST... ALWAYS! —

Dr. Nitin Agarwal

Pathologist & Director
Ex. Sr. Res. MAMC
& Lok Nayak Hospital
Ex. Chief of Lab Dr. Lal Path Labs.

Dr. Pooja (Garg) Agarwal

Radiologist & Director
MAMC & Lok Nayak Hospital

Name	: Mr. KESHAV PASWAN	Age/Sex	: 53 YRS/Male
Ref. By	: Dr. MEDIWHEEL	Lab No	: 012302030011
Date	: 03-Feb-2023	Patient ID	: LSHHI108622

X-ray-Chest PA view

Bony cage and soft tissues are normal.

Cardiothoracic ratio is normal.

Mediastinum is normal.


Both hila are normal.

Both costophrenic angles are clear.

Both domes of diaphragm are normal.

Lung fields are clear. No parenchymal lesion seen.

IMPRESSION: Normal Study.


DR. POOJA GARG
RADIOLOGIST
REG NO- DMC/R/03398
Dr. POOJA GARG
M.B.B.S., D.M.R.D
Reg No. DMC/R/03398
Radiologist

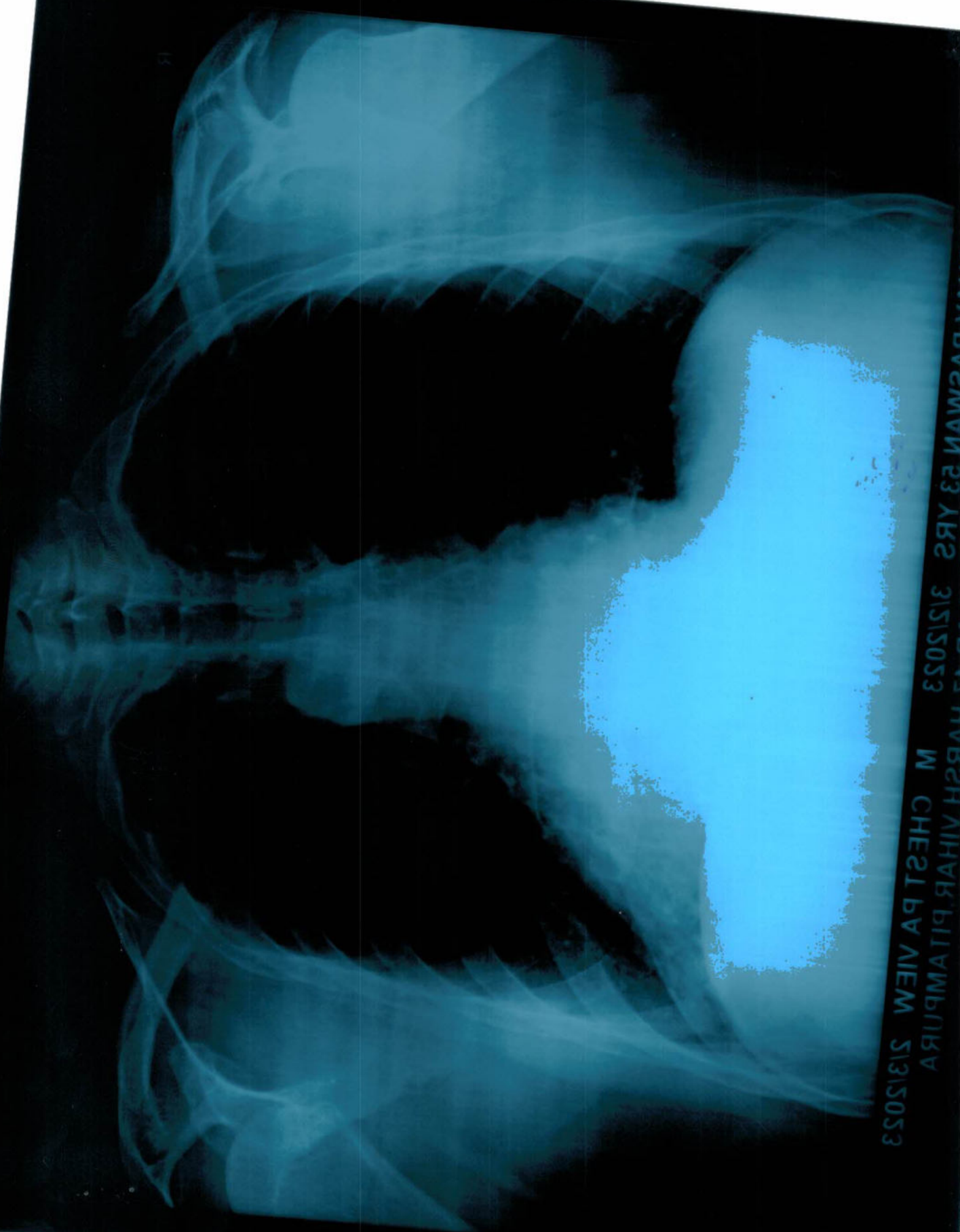
Type By : darshita

47, Harsh Vihar, Pitampura, New Delhi-110034 | Ph.: 011-42480101, 9599913051

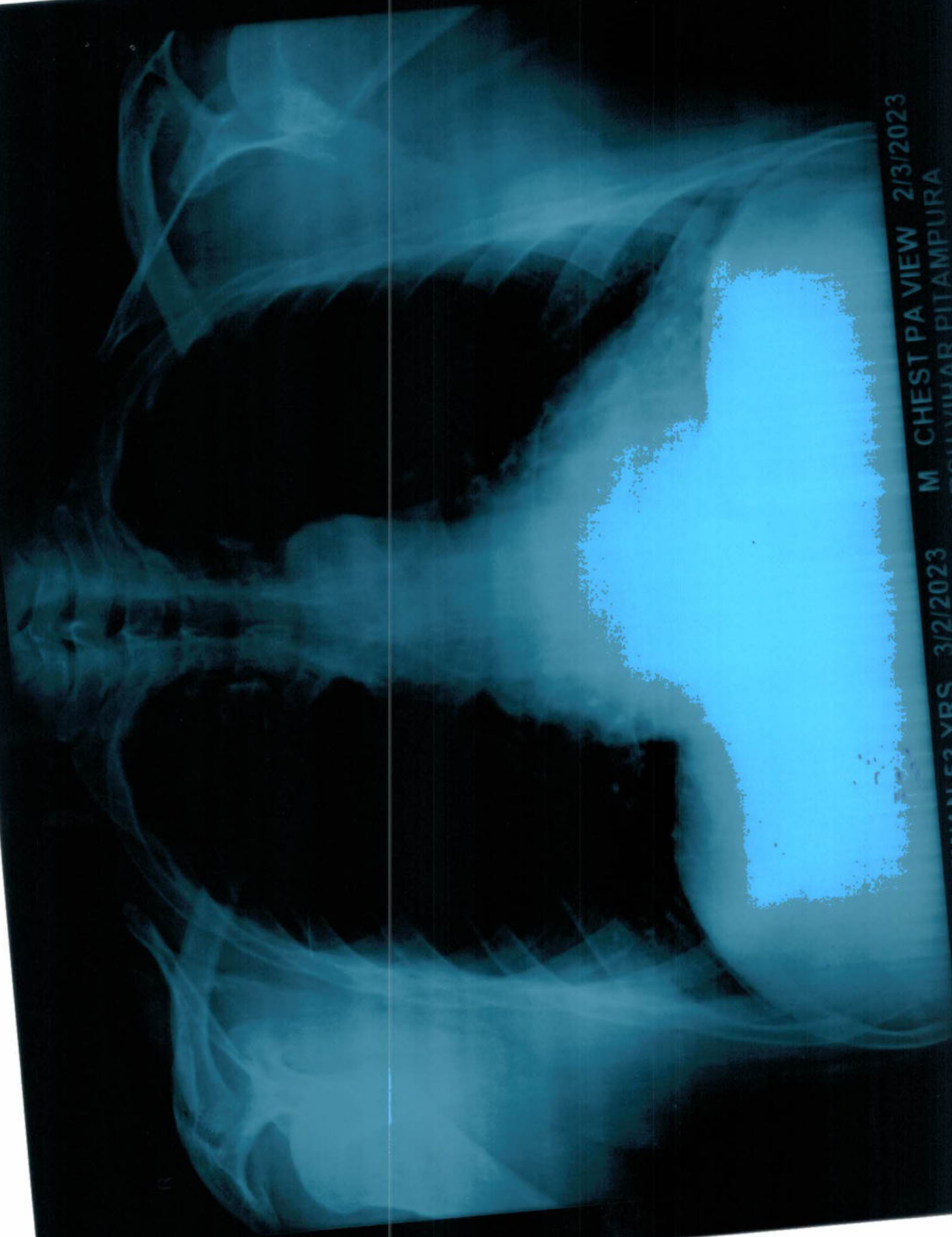
E-mail: oneplusul@gmail.com | Web.: www.oneplusul.in

Clinical correlation is essential for final diagnosis. • If test results are unsatisfactory please contact personally or on phone. • This report is for perusal of doctors only.
• All disputes Subject to Delhi Jurisdiction only. • Not for medicolegal purposes. • All congenital anomalies in a foetus may not be diagnosed in routine obstetric ultrasound.





ONEPLUS ULTRASOUND I BV 43 HARSH NIVAR PITALPURA
MR KESHAV PASWAN 23 YRS 31/5/053 M CHEST PA NEM 51/3/5053



MR. KESHAV PASWAN 53 YRS 3/2/2023 M CHEST PA VIEW 2/3/2023
ONEPLUS ULTRASOUND LAB. 47 HARSH VIHAR PITAMPURA