



Savita

Superspeciality Hospital
(A Unit of Solace Healthcare Pvt. Ltd.)

Parivar Char. Basta, Waghodia-Dabhoi Ring Road, Vadodara-390019

☎ 0265-2578844 / 2578849 ✉ mh@savitahospital.com 🌐 savitahospital.com

Examination By Ophthalmologist

Name :	ROSHNI SHARMA	Age :	35/FEMALE
Reg.No :	20230308952	DOE :	11/03/2023

Present Complaints :	NIL
Medical History :	NIL
Examination Of Eye :	NIL

External Examination :	WNL	WNL
Ati Seg Examination :	WNL	WNL
Schiotz Tonometry IOP :	WNL	WNL
Fundus :	NILL	

Without Glass	Distant Vision : 6/6	6/6
	Near Vision : N6	N6
With Glass	Distant Vision :	
	Near Vision :	
Colour Vision (With Ishihara Chart) :	WNL	
Advice :	NIL	



DR CHETAN CHAUHAN



Savita

Superspeciality Hospital
(A Unit of Solace Healthcare Pvt. Ltd.)

Parivar Char Rasta, Waghodia-Dabhoi Ring Road, Vadodara-390019

☎ 0265-2578844 / 2578849 ✉ mh@savitahospital.com 🌐 savitahospital.com

PHYSICIAN EXAMINATION

Name :	ROSHNI SHARMA	Age :	35/FEMALE
Reg.No :	20230308952	DOE :	11/03/2023

Physical Examination:

Height:	170CM	Weight:	66 KG	PULSE:	68	Temperature:	NORMAL
----------------	--------------	----------------	------------------	---------------	-----------	---------------------	---------------

BMI :	22.8	BP :	108/60	SPO2	99%
--------------	-------------	-------------	---------------	-------------	------------

Chief Complaint :	NO COMPLAINTS
Past History :	NOT SIGNIFICANT
General Examination :	NAD
Systemic Examination :	NAD
INVESTIGATION :	NAD
ADVICE :	TAB:ALLEGRA 1TAB SOS LACTOCALAMINE LOTION LA. SOS.

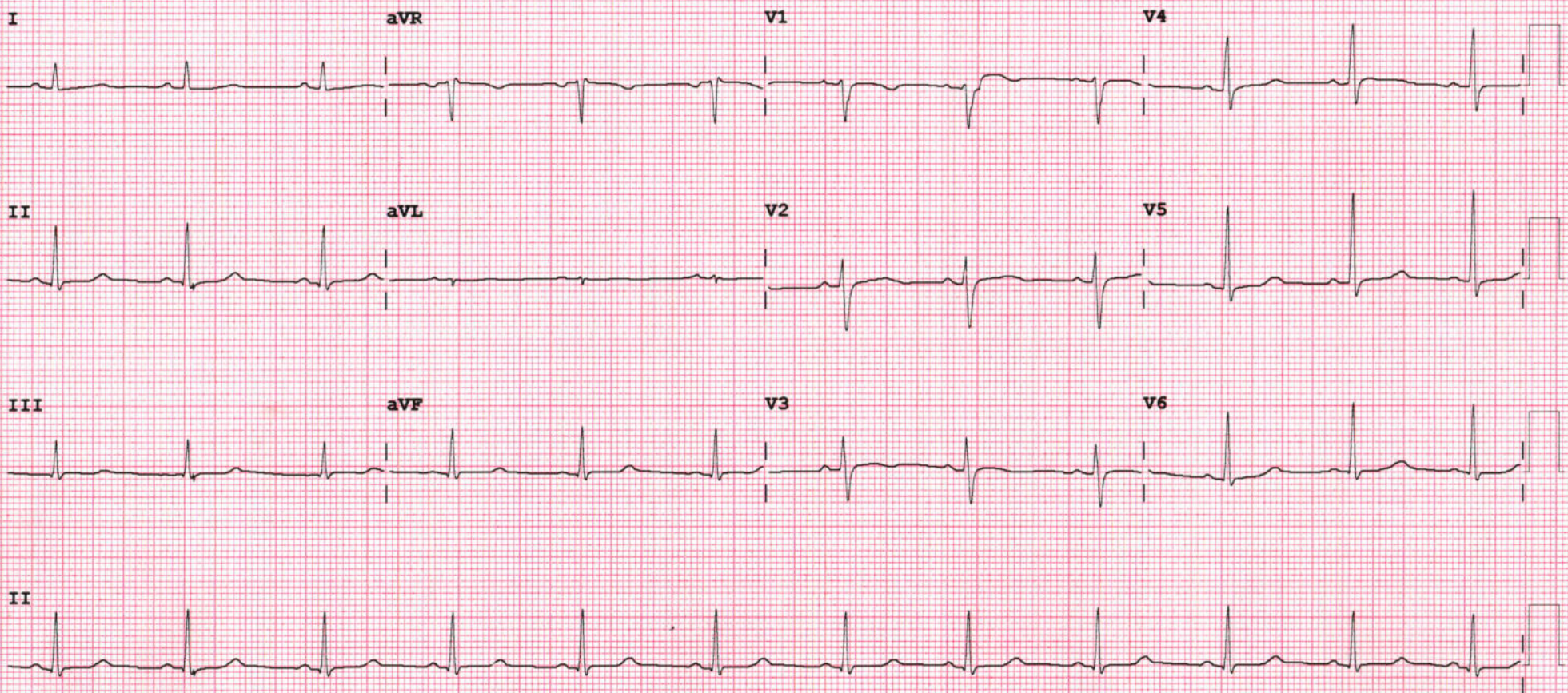


DR. SAURABH JAIN

Rate 71
PR 148
QRSD 94
QT 424
QTc 461

--AXIS--
P 21
QRS 59
T 62

12 Lead; Standard Placement



Device: Speed: 25 mm/sec Limb: 10 mm/mV Chest: 10.0 mm/mV Elect. Off F 50~ 0.50-150 Hz W PH09 P?



Savita

Superspeciality Hospital
(A Unit of Solace Healthcare Pvt. Ltd.)

Parivar Char Rasta, Waghodia-Dabhoi Ring Road, Vadodara-390019

☎ 0265-2578844 / 2578849 ✉ mh@savitahospital.com 🌐 savitahospital.com

2D ECHO & COLOUR DOPPLER REPORT

Name : ROSHNI SHARMA Age/sex: 35 /female Date :11/3/23

Observations :

Normal LV size & normal systolic function. LVEF 60% (Visual)

No RWMA.

No LV diastolic dysfunction.

Trivial MR. No MS.

No AR. No AS.

Trivial TR. No PAH. Pasp = 33 mmHg.

Normal sized LA, RA & RV with normal RV systolic function.

Normal MPA. Intact IAS & IVS.

No intracardiac clot & vegetation.

No PDA & Coarctation.

Normal pericardium, no pericardial effusion.

IVC normal.

AO: 22 mm LA: 33 mm IVS:10/14 mm PW:10/15 mm LVID:40/24 mm

Conclusion :

Normal LV & RV systolic function. LVEF 60 % (visual)

No RWMA.

Mild MR. No PAH.

Dr Chirag Sheth

MD, DM. (CARDIOLOGY)

Dr. Krishnakant Sharma

MD, DNB. (CARDIOLOGY)



Dr. Nirav Bhalani.

MD, DNB. (CARDIOLOGY)



Unipath Specialty Laboratory (Baroda) LLP- Platinum Complex, Opp. HDFC Bank, Nr. Radha Krishna char rasta, Akota, Vadodara - 390020
Mobile: 7228800500 / 8155028222 | Email: info.baroda@unipathlp.in



TEST REPORT

Reg. No. : 30301006017 Reg. Date : 11-Mar-2023 12:11 Collected On : 11-Mar-2023 12:11
Name : Ms. ROSHNI SHARMA Approved On : 11-Mar-2023 13:54
Age : 35 Years Gender : Female Ref. No. : Dispatch At :
Ref. By : Tele No. :
Location : SAVITA SUPERSPECIALTY HOSPITAL @ WAGHODIYA ROAD

Test Name	Results	Units	Bio. Ref. Interval
THYROID FUNCTION TEST			
T3 (triiodothyronine) <i>Method:CLIA</i>	0.88	ng/mL	0.6 - 1.81
T4 (Thyroxine) <i>Method:CLIA</i>	10.60	µg/dL	4.5 - 12.6
TSH (ultra sensitive) <i>Method:CLIA</i>	1.216	µIU/mL	0.55 - 4.78
Sample Type:Serum			

Comments:

Thyroid stimulating hormone (TSH) is synthesized and secreted by the anterior pituitary in response to a negative feedback mechanism involving concentrations of FT3 (free T3) and FT4 (free T4). Additionally, the hypothalamic tripeptide, thyrotropin-releasing hormone (TRH), directly stimulates TSH production. TSH stimulates thyroid cell production and hypertrophy, also stimulate the thyroid gland to synthesize and secrete T3 and T4. Quantification of TSH is significant to differentiate primary (thyroid) from secondary (pituitary) and tertiary (hypothalamus) hypothyroidism. In primary hypothyroidism, TSH levels are significantly elevated, while in secondary and tertiary hypothyroidism, TSH levels are low.

TSH levels During Pregnancy :

- First Trimester : 0.1 to 2.5 µIU/mL
- Second Trimester : 0.2 to 3.0 µIU/mL
- Third trimester : 0.3 to 3.0 µIU/mL

Reference : Carl A.Burtis,Edward R.Ashwood,David E.Bruns. Tietz Textbook of Clinical Chemistry and Molecular Diagnostics. 5th Edition. Philadelphia: WB Saunders,2012:2170

----- End Of Report -----

This is an electronically authenticated report.

Test done from collected sample.


Printed On: 11-Mar-2023 13:55

Dr. Vishal Jhaveri
M.B.B.S, D.C.P
Reg. G-13041

We are open 24 x 7 & 365 days


Page 1 of 1
LLP Identification Number: AAN-893



Patient Name :	Roshni . Sharma	Sample No. :	20230316103 
Patient ID :	20230308952	Visit No. :	OPD20230326840
Age / Sex :	35y/Female	Coll. Date :	11/03/2023 08:54
Consultant :	DR SAURABH JAIN	S. Coll. Date :	11/03/2023 12:55
Ward :	-	Report Date :	11/03/2023 15:52


Urine R/M

Investigation	Result	Normal Value
Quantity - :	20 ml	
Colour - :	Straw	
Reaction (pH) :	5.0	4.6-8.0
Turbidity :	Clear	
Deposit :	Absent	Absent
Sp.Gravity :	1.010	1.005-1.010
Protein :	Absent	Absent
Glucose :	Absent	Absent
Bile Salts :	Absent	Absent
Bile pigments :	Absent	Absent
Ketones :	Absent	Absent
Urobilinogen :	Absent	
Blood :	Absent	Absent
Pus Cells :	0-1 /hpf	0-5/hpf
Red Blood Cells :	0-1 /hpf	Absent
Epithelial Cells :	1-2 /hpf	



Dr.Mehul Desai
M.B.D.C.P
Reg.No.G-9521




Patient Name : Roshni . Sharma	Sample No. : 20230316103 
Patient ID : 20230308952	Visit No. : OPD20230326840
Age / Sex : 35y/Female	Coll. Date : 11/03/2023 08:54
Consultant : DR SAURABH JAIN	S. Coll. Date : 11/03/2023 12:55
Ward : -	Report Date : 11/03/2023 15:52

Lipid Profile


Investigation	Result	Normal Value
Sample :	Fasting	
Sample Type :	Normal	
Cholesterol (Chol) :	180 mg/dl	Low risk : < 200 Moderate risk : 200 - 239 High risk : > or = 240
Triglyceride :	68 mg/dl	Normal : < 200.0 High : 200 - 499 Very High : > or = 500
HDL Cholesterol :	46 mg/dl	Low risk : >or = 60 mg/dL High risk : Up to 35 mg/dL
LDL :	120.4 mg/dl [L]	131.0 to 159.0(N) < 130.0(L) > 159.0(H)
VLDL :	13.6 mg/dl	Up to 0 to 34 mg/dl
LDL/HDL Ratio :	2.62	Low risk : 0.5 to 3.0 Moderate risk : 3.0 to 6.0 Elevted level high > 6.0
Total Chol / HDL Ratio :	3.91	Low Risk : 3.3 to 4.4 Average Risk : 4.4 to 7.1 Moderate Risk : 7.1 to 11.0 High Risk : > 11.0
Total Lipids :	594 mg/dl	400 to 700 mg/dl

Note :- Lipemic samples give high triglyceride value and falsely low LDL value.




Dr. Mehul Desai
M.B.D.C.P
Reg.No.G-9521



Patient Name :	Roshni . Sharma	Sample No. :	20230316103 
Patient ID :	20230308952	Visit No. :	OPD20230326840
Age / Sex :	35y/Female	Coll. Date :	11/03/2023 08:54
Consultant :	DR SAURABH JAIN	S. Coll. Date :	11/03/2023 12:55
Ward :	-	Report Date :	11/03/2023 15:52

LFT (Liver Function Test)

Investigation	Result	Normal Value
Total Bilirubin :	0.8 mg/dl	0.2 to 1.0 mg/dl
Direct Bilirubin :	0.2 mg/dl	0.0 to 0.2 mg/dl
Indirect Bilirubin :	0.6 mg/dl	0.0 to 0.8 mg/dl
AST (SGOT) :	22 U/L	5 to 34 U/L
ALT (SGPT) :	46 U/L	0 to 55 U/L
Total Protein (TP) :	6.2 g/dL [L]	6.4 to 8.3, g/dl
Albumin (ALB) :	4.2 g/dl	3.5 to 5.2 g/dl
Globulin :	2 g/dl	2.3 to 3.5 g/dl
A/G Ratio :	2.1	
Alkaline Phosphatase (ALP) :	68 U/L	40 to 150 U/L
GAMMA GT. :	45 U/L [H]	7 to 35 U/L



Dr. Mehul Desai
M.B.D.C.P
Reg.No.G-9521



Patient Name : Roshni . Sharma

Sample No. : 20230316103



Patient ID : 20230308952

Visit No. : OPD20230326840

Age / Sex : 35y/Female

Coll. Date : 11/03/2023 08:54

Consultant : DR SAURABH JAIN

S. Coll. Date : 11/03/2023 12:55

Ward : -


Report Date : 11/03/2023 15:52

RENAL FUNCTION TEST

Investigation	Result	Normal Value
Creatinine :	1.3 mg/dl	0.6 - 1.4 mg/dl
Urea :	28 mg/ dl	13 - 45 mg/dl
Uric Acid :	3.7 mg/dl	3.5 - 7.2 mg/dl
Calcium :	8.8 mg/dl	8.5 - 10.5
Phosphorus :	3.8 mg/dl	1.5 - 6.8

Dr.Mehul Desai
M.B.D.C.P
Reg.No.G-9521



Patient Name : Roshni . Sharma	Sample No. : 20230316103 
Patient ID : 20230308952	Visit No. : OPD20230326840
Age / Sex : 35y/Female	Coll. Date : 11/03/2023 08:54
Consultant : DR SAURABH JAIN	S. Coll. Date : 11/03/2023 12:55
Ward : -	Report Date : 11/03/2023 15:52

Blood Group


Investigation	Result	Normal Value
BLOOD GROUP :		
ABO	A	
Rh	Negative	

FBS & PPBS

Investigation	Result	Normal Value
Blood Sugar (FBS) :	78 mg/dl	74 - 100 mg/dl
Urine Sugar (FUS) :	Nil	
Blood Sugar (PP2BS) :	68 mg/dl [L]	70 to 120 mg/dl
Urine Sugar (PP2US) :	Nil	


HBA1C

Investigation	Result	Normal Value
Glycosylated Hb :	5.4 %	Near Normal Glycemia : 6 to 7 Excellent Control : 7 to 8 Good Control : 8 to 9 Fair Control : 9 to 10 Poor Control : > 10
Average Plasma Glucose of Last 3 Months :	108.28	




Dr.Mehul Desai
M.B.D.C.P
Reg.No.G-9521



Patient Name :	Roshni . Sharma	Sample No. :	20230316103 
Patient ID :	20230308952	Visit No. :	OPD20230326840
Age / Sex :	35y/Female	Coll. Date :	11/03/2023 08:54
Consultant :	DR SAURABH JAIN	S. Coll. Date :	11/03/2023 12:55
Ward :	-	Report Date :	11/03/2023 15:52

CBC, ESR

Investigation	Result	Normal Value
Hemoglobin :	11.2 gm/dl [L]	12.5 to 16.0 gm/dl
P.C.V. :	35.1 % [L]	37.0 to 47.0 %
M.C.V. :	80.5 fL	78 to 100 fL
M.C.H. :	25.7 pg [L]	27 to 31 pg
M.C.H.C. :	31.9 g/dl [L]	32 to 36 g/dl
RDW :	12.6 %	11.5 to 14.0 %
RBC Count :	4.36 X 10 ⁶ / cumm	4.2 to 5.4 X 10 ⁶ / cumm
Polymorphs :	71 % [H]	38 to 70 %
Lymphocytes :	27 %	15 to 48 %
Eosinophils :	1 %	0 to 6 %
Monocytes :	1 % [L]	3 to 11 %
Basophils :	0 %	0.0 to 1.0 %
Total :	100	< 100 > 100
WBC Count :	7200 /cmm	4000 to 10000 /cmm
Platelets Count :	262000 /cmm	1,50,000 to 4,50,000 /cmm
ESR - After One Hour :	17 mm/hr	1 to 20 mm/hr



Dr. Mehul Desai
M.B.D.C.P
Reg.No.G-9521



Patient name	ROSHNI SHARMA
Age / Sex	35 Y/F
Date	Saturday, 11 March 2023

ULTRASOUND OF ABDOMEN

LIVER appears normal in size (12.2 cm) and shows normal parenchymal echogenicity. No evidence of focal lesion. No evidence of dilated IHBR or portal vein. CBD appears normal.

GALL BLADDER is distended. No evidence of abnormal wall thickening or any significant calculus within.

PANCREAS appears normal. MPD is WNL

SPLEEN appears normal in size (9.4 cm) and shows normal parenchymal echogenicity. No evidence of focal lesion.

BOTH KIDNEYS appear normal in size (RK: 9.6 cm & LK: 9.3 cm), shape and position.

Show normal cortical echogenicity. Corticomedullary differentiation is maintained.

No evidence of calculus or hydronephrosis on either side.

URINARY BLADDER is partially full. No evidence of abnormal wall thickening or any significant calculus within.

UTERUS appears normal in size and position. CET is WNL. No evidence of focal lesion noted.

Bilateral ovaries appear normal in size. No evidence of focal or obvious mass lesion noted.

BOWEL LOOPS appear normal and show normal peristalsis

No evidence of LYMPHADENOPATHY noted.

No evidence of ASCITES noted.

IMPRESSION:

- NO SIGNIFICANT ABNORMALITY AT PRESENT SCAN.

DR SHARAD RUNGTA
MD RADIOLOGY

Not all pathologies can be detected on radiograph. Further radiographic evaluation is suggested if required.



NAME: ROSHNI SHARMA	AGE/SEX: 35 YRS/F
DATE: Saturday, March 11, 2023	

CHEST XRAY (PA)

Both lung fields appear normal.

Both hila appear normal

Bilateral costo-phrenic angles appear grossly clear

Mediastinum and cardiac shadow appear normal

Bony thorax appears unremarkable

No evidence of free gas under domes of diaphragm

IMPRESSION:

- NO SIGNIFICANT ABNORMALITY NOTED IN LUNG FIELDS
- NORMAL CARDIAC SHADOW

DR SHARAD RUNGTA
MD RADIOLOGY

Not all pathologies can be detected on radiograph. Further radiographic evaluation is suggested if required.

