



ISO Certified (9001-2008)  
Late R. T. Bhoite Smruti Arogya Pratisthan's

# GIRIRAJ HOSPITAL

(State Govt. Recognised Hospital)



## PADMASHREE DR. APPASAHEB PAWAR HEART CARE CENTRE

DR. RAMESH R. BHOITE M.D.

Chairman

Reg.No.Mah.Soc.Act 1860/9888/95 Pune  
Bombay Public Trust Act. 1950/F/10595 Pune  
I.T.ded. U/S 80 G/PN 165 Rule 216/95/96  
F.C.R.A. 083930350

Only for Clinical Use

### CARDIAC COLOR DOPPLER

Patients Name- Mr Ganesh Sahebrao Shinde

Age/Sex: 33Year/male

Ref.: - Dr. Ramesh Bhoite

Date – 04<sup>th</sup> April,2023

#### Findings: -

MV – MVA adequate, No MR

AV – No AS (AVG: 14 mmHg)/ No AR

TV – No TR, No PH (RVSP/TR: 14 mmHg)

PV – Normal

No Clot / Vegetation


No RWMA

Grade I DD

**Measurements** (mm); -AO-20, LA-32, IVS-10, LVPW-10, LVIDd-42, LVIDs-30 LVEF – 60%

#### Impression:

- No RWMA
- Normal LV systolic function LVEF 60%

  
Dr. Varun Deokate  
MD (MED) (JJ, Mumbai),  
DM (Card) (KEM, Mumbai)



34 Years

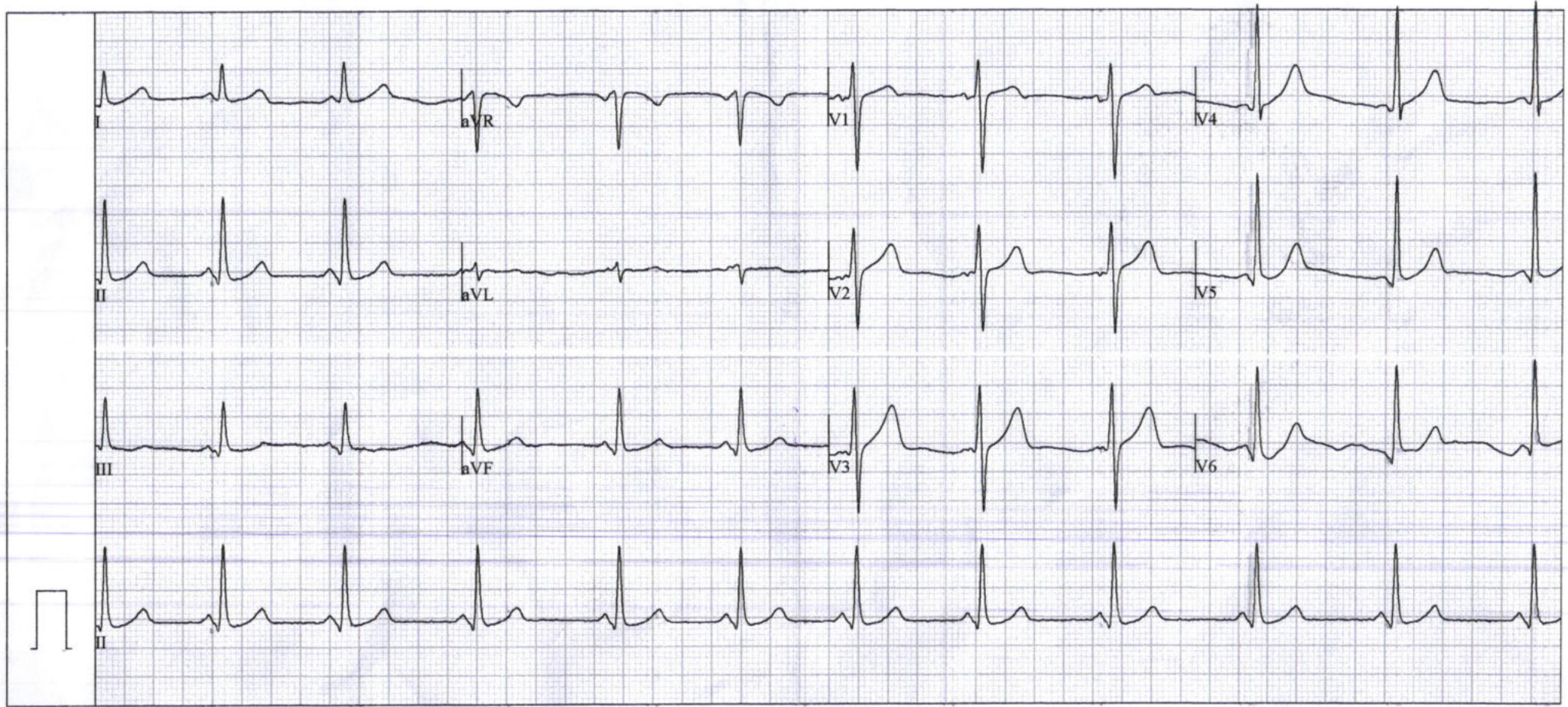
Male

QRS : 78 ms  
QT / QTcBaz : 384 / 408 ms  
PR : 106 ms  
P : 94 ms  
RR / PP : 886 / 882 ms  
P / QRS / T : 57 / 66 / 56 degrees

Sinus rhythm with sinus arrhythmia with short PR  
Minimal voltage criteria for LVH, may be normal variant  
Borderline ECG

*R. Bhoite*  
**DR. RAMESH R. BHOITE, M.D.**  
Cardiologist  
Giriraj Hospital & Intensive Care Unit  
Indapur Road, Baramati-413102

*R. Bhoite*  
*ECG - Normal*







# GIRIRAJ DIAGNOSTIC CENTRE

Ultrasonography, Whole Body Colour Doppler Ultrasound, Echocardiography.



**NAME** : MR. GANESH SHINDE **AGE/SEX** : 34 YEARS/M  
**REF BY** : MEDIWHEEL COMPANY **DATE** : 04-04-2023

## USG STUDY OF ABDOMEN & PELVIS

**LIVER:-** appears normal in size shape & shows normal parenchymal reflectivity. No e/o focal mass lesion or any neoplasm seen in liver. Portal vein & CBD are normal.

**GALL BLADDER:** is well distended. No calculus is seen within it. Its wall thickness is normal. No peri gb collection.

**PANCREAS:** normal in size and shape. No focal lesion or calcifications are seen within it. The pancreatic duct is normal.

**SPLEEN:** in size & shows normal echotexture. No focal lesion is seen.

**BOTH KIDNEYS:** -appear normal size, shape, position & echotexture.

No calculus or mass lesion or scarring seen in both kidneys. Cortical echogenicity and thickness appears normal in both kidneys. Cortico-medullary differentiation is well maintained in both kidneys.

**RIGHT KIDNEY** - measures 8.5x3.4 cm , **LEFT KIDNEY** - measures 9.4x4.4 cm

**URINARY BLADDER** - is well distended. The wall thickness is normal. No vesicle calculus is seen

**PROSTATE** - appears normal in shape, size and echotexture.

Visualized small bowel loops appear non dilated. Gaseous distension of large bowel loops.

No free fluid is seen in abdomen and pelvis.

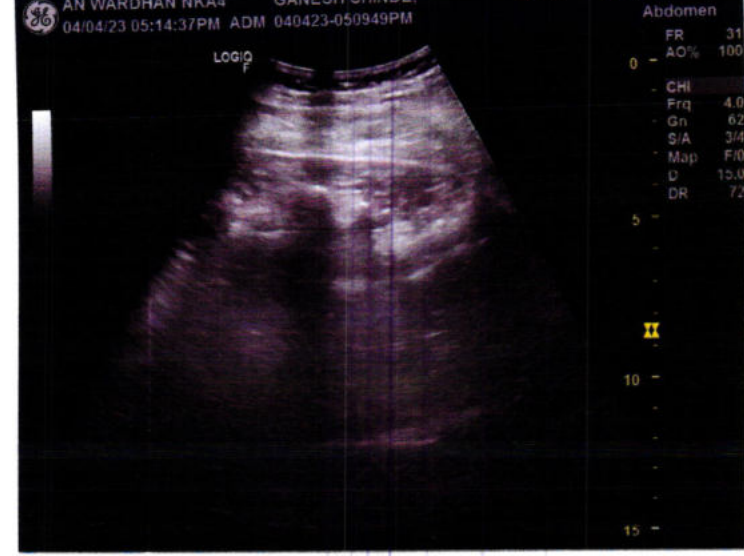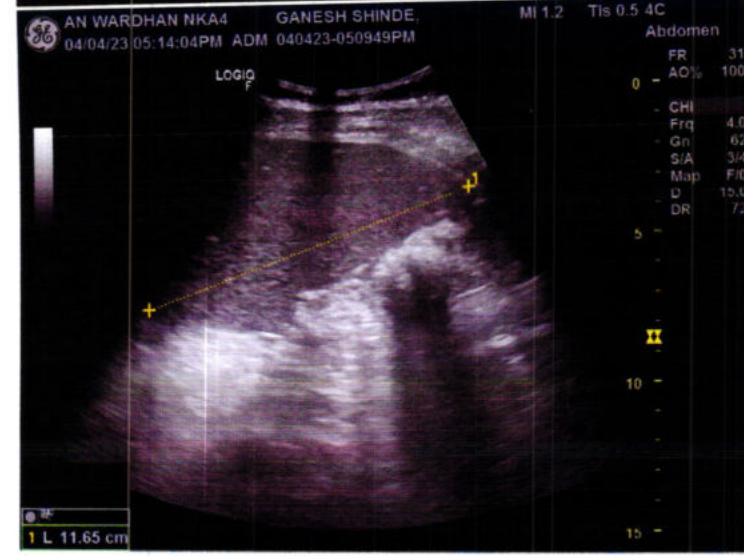
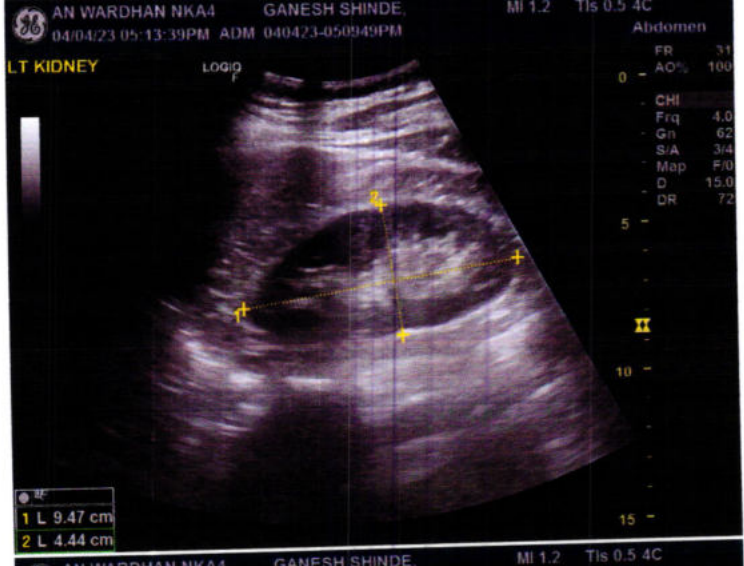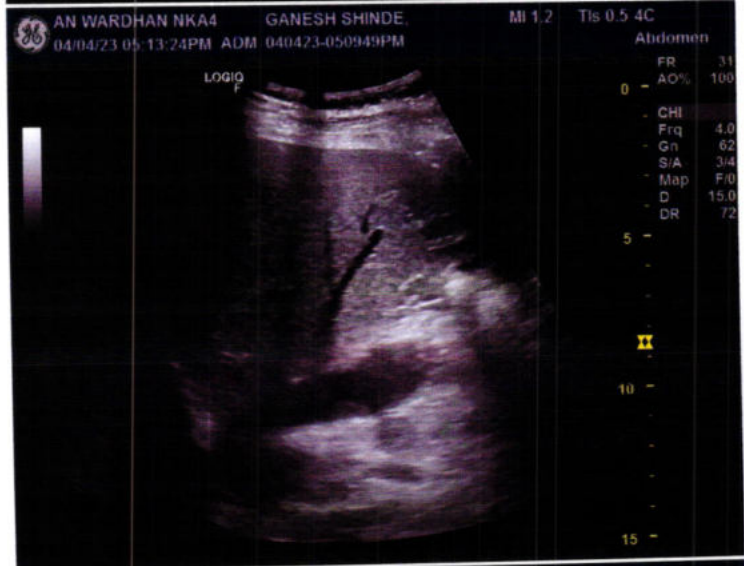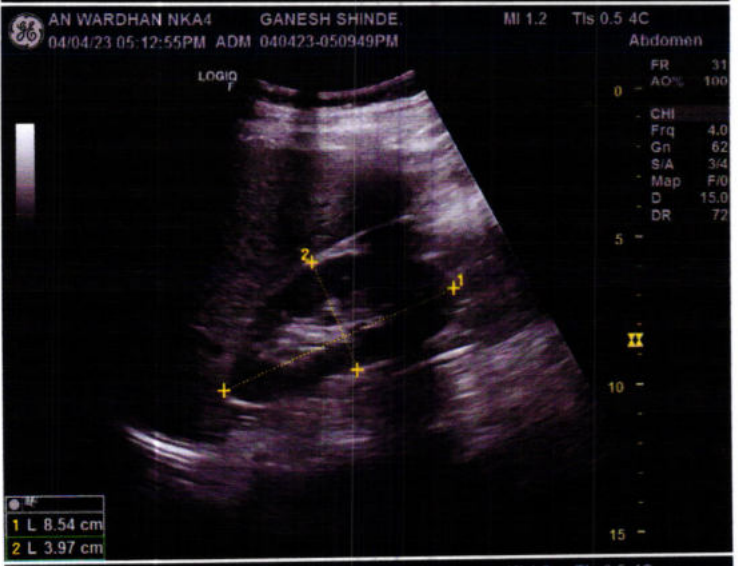
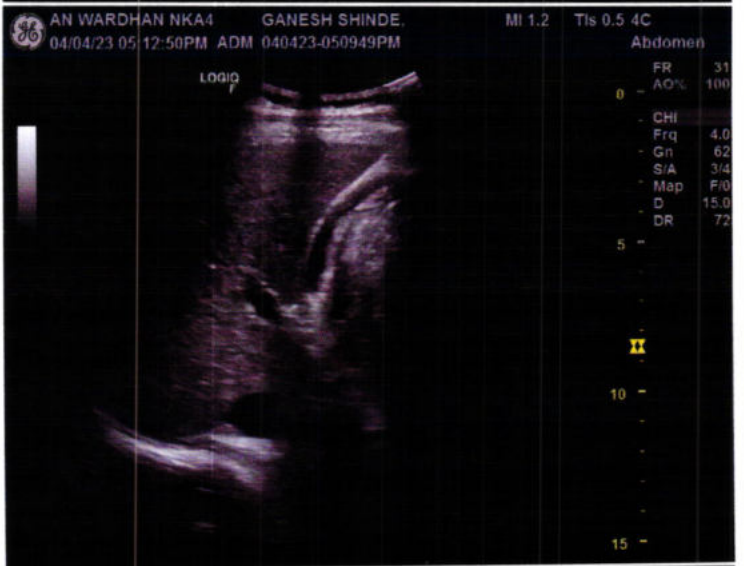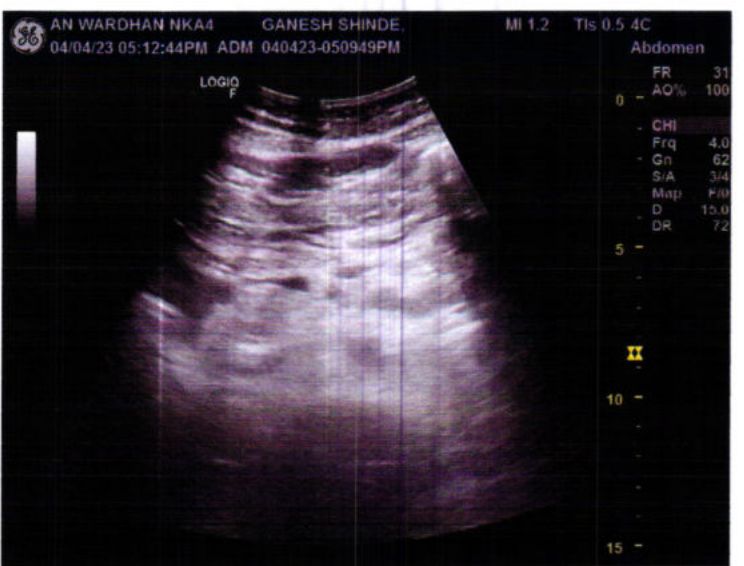
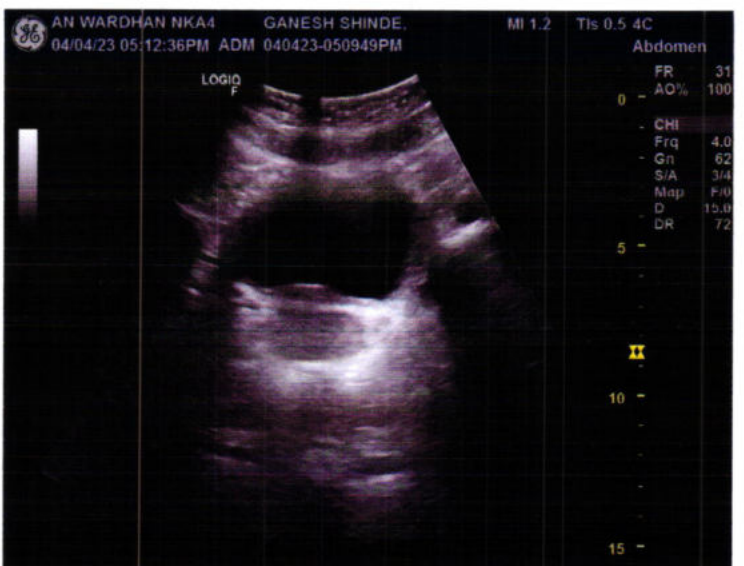No significant abdominal lymphadenopathy.

## CONCLUSION :-

❖ **Normal USG abdomen and pelvis study.**

**DR.MUGDHA SURAJ BHAGAT**  
**CONSULTANT RADIOLOGIST**







# GIRIRAJ DIAGNOSTIC CENTRE

Ultrasonography, Whole Body Colour Doppler Ultrasound, Echocardiography.



PATIENT NAME GANESH SHINDE REFER DOCTOR MEDIWHEEL COMPANY

AGE | GENDER 34 YEAR(S) OLD/MALE SCAN DATE APR 04 2023

## X-RAY CHEST PA VIEW

**CLINICAL PROFILE: NO ACTIVE COMPLAINT.**

**OBSERVATION:**

Both lung fields is normal.

Both hilar shadows and costophrenic angles are normal.

Heart shadow appears normal in size.

Bony thorax and both domes of diaphragm appear normal.

No evidence of cervical rib is seen on either side.

**IMPRESSION:**

- NO SIGNIFICANT ABNORMALITY.

**DR. AMMAR MODI**

MD RADIOLOGY

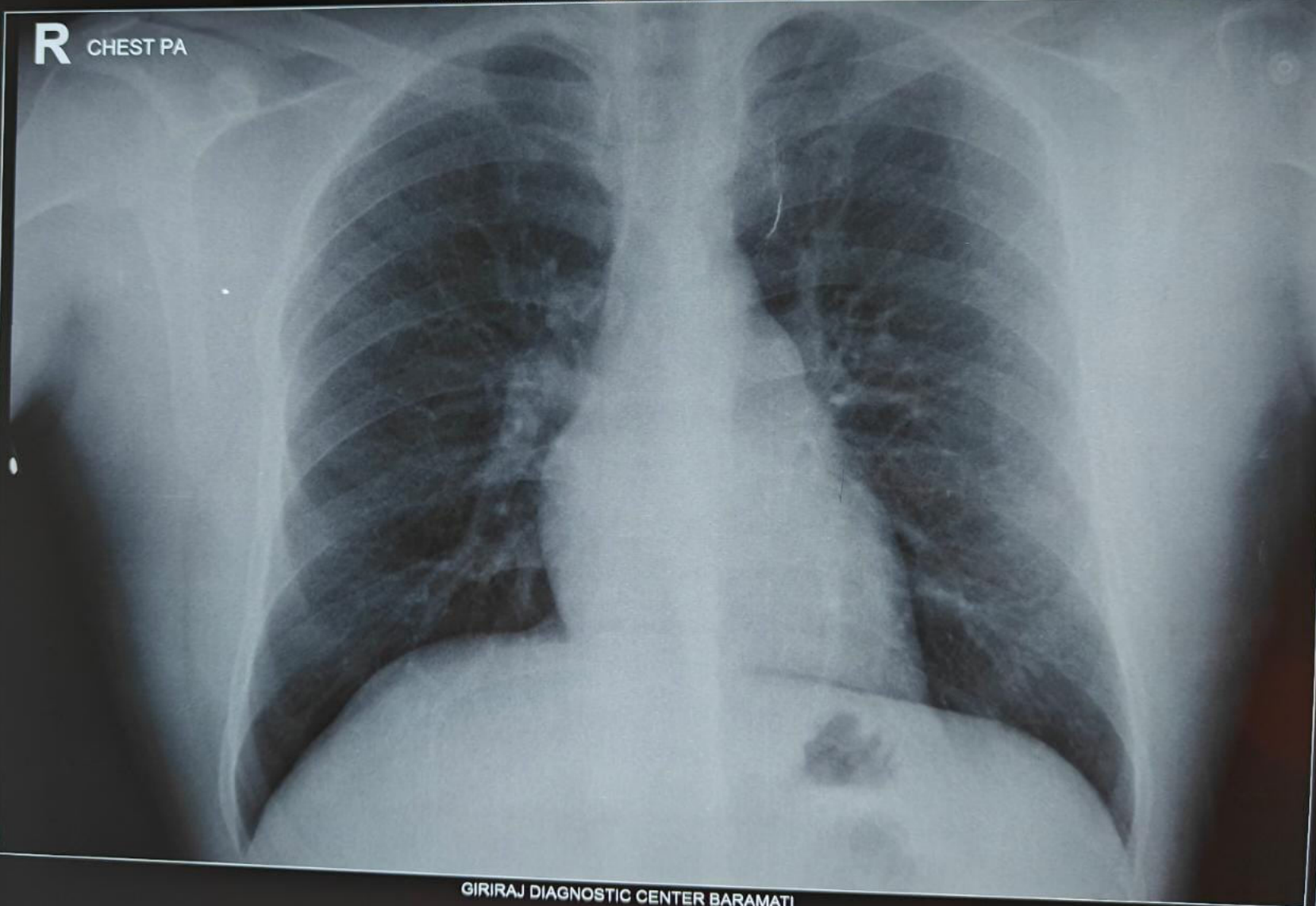
CONSULTANT RADIOLOGIST

GANESH SHINDE | DOB: Jan 01 1989 |



GANESH SHINDE/PAT008569/34 years/M/04-Apr-2023

**R** CHEST PA



GIRIRAJ DIAGNOSTIC CENTER BARAMATI