

Facilities:

All clinical Biomedical & Hematology Investigations including Bone Marrow Examination
VPT, Podiascan & Complete Foot Care (First Time in Purvanchal)
All Hormonal Investigation by Chemiluminescent Method
Visceral Fat by (AB-140) Ambulatory BP Monitoring
CGMS & Insulin Pump Available
PFT, 2D-ECHO (Color Doppler), Holter, TMT, Cardiac-3 available
VIA, VILI, Colposcopy available
Special Endocrinological Investigation Protocols.

ISO 9001:2008 Certified
Mobile: 9389994334, 9554572190, 9453837595



Panacea Pathology

Clinical Reference Lab

Persistence, Preparedness and Precision
EQAS (CMC Vellore Attached) & IQAS System
पूर्वांचल की सर्वोत्तम गुणवत्ता वाली पैथोलॉजी

PATIENT NAME : NISHA SINHA

AGE/GENDER : 38YRS/FEMALE

REFD BY DR. : ARCO FEMI HEALTHCARE LTD.

RECEIVED DATE : 25-03-2023 (10:00 AM)

SAMPLE : BLOOD & URINE

REPORT DATE : 25-03-2023 (07:00 PM)

PATHOLOGY REPORT

COMPLETE BLOOD COUNT (CBC)

TEST	LAB TEST VALUES	NORMAL RANGE
HEMOGRAM		
HEMOGLOBIN (FLOW CYTOMETRY)	10.1	13 – 16 gm/dl
TOTAL LEUCOCYTE COUNT (TLC)	8,400	4000 – 11000
RBC COUNT	4.52	3.5 – 5.5
PCV (HCT)	34.0	37 – 47
MCV	75.2	80 – 95
MCH	22.4	28 – 34
MCHC	29.6	30 – 36
PLATELET COUNT	2,25,000	1,50,000 – 4,00,000
E.S.R. (WINTROBE FIRST HOURS)	15.0	20 mm/1 st hr
DIFFERENTIAL LEUCOCYTE		
NEUTROPHILS	63	40 – 75%
LYMPHOCYTES	32	20 – 45%
EOSINOPHILS	03	1 – 6%
MONOCYTES	02	2 – 8%
BASOPHILS	00	< 2%

RANDOM/FASTING BLOOD SUGAR

TEST	LAB TEST VALUES	NORMAL RANGE
RBS/FBS		
RANDOM BLOOD SUGAR	110.0	125-140 mg/dl
FASTING BLOOD SUGAR	87.0	70-125 mg/dl

GLYCOSYLATED HEMOGLOBIN (HBA1C)

TEST	LAB TEST VALUES	NORMAL RANGE
HBA1C	5.7	Normal : <5.97 % Good Control : 5.97 – 6.81% Fair Control : 6.81 – 7.65% Poor Control : >7.65%

PAGE 1

Lab Technician

PANACEA HOSPITAL
A UNIT OF AARON HEALTH CARE PVT. LTD
REG. NO.: AL-1500
B.36/44, B-4, KABIR NAGAR
DURGAKUND, VARANASI
M.D. Pathology

Timing : 8.00 a.m. to 9.00 p.m. (Sunday 8.00 a.m. to 3.00 p.m.)

This Report is not valid for medico legal purpose

Note: These tests have technical limitations. Clinico-pathological interpretation is necessary. In case of any disparity test may be repeated immediately.

Address : 36/44 FK Kabir Nagar, Durgakund, Varanasi – 221005

Email: dramishra@gmail.com, drpallaviojha@gmail.com Website: panaceahospital.org

Facilities:
 All clinical Biomedical & Hematology Investigations including Bone Marrow Examination
 VPT, Podiascan & Complete Foot Care (First Time in Purvanchal)
 All Hormonal Investigation by Chemiluminescent Method
 Visceral Fat by (AB-140) Ambulatory BP Monitoring
 CGMS & Insulin Pump Available
 PFT, 2D-ECHO (Color Doppler), Holter, TMT, Cardiac-3 available
 VIA, VILI, Colposcopy available
 Special Endocrinological Investigation Protocols.

ISO 9001:2008 Certified
 Mobile: 9389994334, 9554572190, 9453837595



Panacea Pathology

Clinical Reference Lab

Persistence, Preparedness and Precision
 EQAS (CMC Vellore Attached) & IQAS System
 पूर्वांचल की सर्वोत्तम गुणवत्ता वाली पैथोलॉजी

PATIENT NAME : NISHA SINHA	AGE/GENDER : 38YRS/FEMALE
REFD BY DR. : ARCO FEMI HEALTHCARE LTD.	RECEIVED DATE : 25-03-2023 (10:00 AM)
SAMPLE : BLOOD & URINE	REPORT DATE : 25-03-2023 (07:00 PM)

PATHOLOGY REPORT

LIPID PROFILE, SERUM

TEST	LAB TEST VALUES	NORMAL RANGE
BLOOD CHEMISTRY		
TOTAL CHOLESTEROL (SERUM)	158.0	Desirable:- < 200 mg/dl Borderline:- 200 – 239 mg/dl High:- > 240 mg/dl
TRIGLYCERIDES (SERUM)	148.0	35 – 170 mg/dl
HDL CHOLESTEROL (SERUM)	45.0	35.30 – 79.50 mg/dl
LDL CHOLESTEROL (SERUM)	95.0	< 130 mg/dl
VLDL	29.6	< 40 mg/dl
CHOLESTROL/HDL RATIO	3.5	< 3.0 Low Risk Ratio 3.0 – 5.0 Avg Risk > 5.0 High Risk
LDL/HDL RATIO	2.1	< 3 Ratio

BLOOD GROUP

TEST	LAB TEST VALUES
BLOOD GROUP ABO & RH FACTOR	
BLOOD GROUP	"B"
RH FACTOR	POSITIVE

LIVER PROFILE TEST, SERUM

TEST	LAB TEST VALUES	NORMAL RANGE
BIO CHEMISTRY		
TOTAL BILIRUBIN	0.68	0.0 – 1.1 mg/dl
DIRECT BILIRUBIN	0.24	0.0 – 0.2 mg/dl
INDIRECT BILIRUBIN	0.44	< 0.90 mg/dl
SGOT (AST)	29.0	0 – 52 mg/dl
SGPT (ALT)	30.0	0 – 39 mg/dl
GGT (GYT)	24.0	< 55 U/L

THYROID PROFILE (T3, T4, TSH)

TEST	LAB TEST VALUES	NORMAL RANGE
THYROID FUNCTION TEST		
T3	1.02	0.60 – 1.81 ng/ml
T4	8.12	4.50 – 10.90 ug/dl
TSH	3.15	0.39 – 6.10 uIU/mL

PAGE 2

Lab Technician

PANACEA HOSPITAL
 (A UNIT OF AAROA HEALTH CARE PVT. LTD)
 REG. NO.: 814500
 M.D., Pathology
 B.36/44, B-4, KABIR NAGAR
 DURGAKUND, VARANASI

Timing : 8.00 a.m. to 9.00 p.m. (Sunday 8.00 a.m. to 3.00 p.m.)

This Report is not valid for medico legal purpose

Note: These tests have technical limitations. Clinico-pathological interpretation is necessary. In case of any disparity test may be repeated immediately.

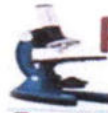Address : 36/44 FK Kabir Nagar, Durgakund, Varanasi – 221005

Email: dramishra@gmail.com, drpallaviojha@gmail.com Website: panaceahospital.org

Facilities:

All clinical Biomedical & Hematology Investigations including Bone Marrow Examination
 VPT, Podiascan & Complete Foot Care (First Time in Purvanchal)
 All Hormonal Investigation by Chemiluminescent Method
 Visceral Fat by (AB-140) Ambulatory BP Monitoring
 CGMS & Insulin Pump Available
 PFT, 2D-ECHO (Color Doppler), Holter, TMT, Cardiac-3 available
 VIA, VILI, Colposcopy available
 Special Endocrinological Investigation Protocols.

ISO 9001:2008 Certified
 Mobile: 9389994334, 9554572190, 9453837595



Panacea Pathology

Clinical Reference Lab

Persistence, Preparedness and Precision
 EQAS (CMC Vellore Attached) & IQAS System
 पूर्वांचल की सर्वोत्तम गुणवत्ता वाली पैथोलॉजी

PATIENT NAME : NISHA SINHA

AGE/GENDER : 38YRS/FEMALE

REFD BY DR. : ARCO FEMI HEALTHCARE LTD.

RECEIVED DATE : 25-03-2023 (10:00 AM)

SAMPLE : BLOOD & URINE

REPORT DATE : 25-03-2023 (07:00 PM)

PATHOLOGY REPORT

RENAL & KIDNEY PROFILE, SERUM

TEST	LAB TEST VALUES	NORMAL RANGE
RENAL FUNCTION TESTS		
BLOOD UREA NITROGEN (BUN)	8.54	10 – 50 mg/dl
SERUM CREATININE	0.67	0.60 – 1.60 mg/dl
URIC ACID	3.94	3.60 – 7.70 mg/dl
ALKALINE PHOSPHATASE (ALP)	89.0	142 – 353 mg/dl
TOTAL PROTIENS	7.49	0 – 39 mg/dl
ALBUMIN	4.30	3.8 – 5.4 mg/dl
SERUM GLOBULIN	3.19	2.1 – 3.5 mg/dl
AG RATIO	1.34	-
CALCIUM	9.0	8.80 – 10.20
PHOSPHORUS	3.02	2.50 – 5.00
SERUM SODIUM NA+	140.0	135.00 – 155.00 mEq/Ltr
SERUM POTASIUUM K+	4.32	3.60 – 5.50 mEq/Ltr
ICALCIUM	1.24	1.10 – 1.35 mmol/L
SERUM CHLORIDE CL+	105.9	98.00 – 110.00 mEq/Ltr

URINE ROUTINE EXAMINATION

TEST	LAB TEST VALUES	NORMAL RANGE
PHYSICAL EXAMINATION		
QUANTITY	30	ML
COLOUR	STRAW	PALE YELLOW
APPEARANCE	CLEAR	CLEAR
SPECIFIC GRAVITY	1.020	1.01 – 1.03
PH	6.5	4.7 – 7.5
CHEMICAL EXAMINATION		
GLUCOSE	Not Detected	Not Detected
PROTEIN	NIL	Not Detected
MICROSCOPIC EXAMINATION		
PUS CELLS	NIL	0-5
RBC	Not Detected	Not Detected
EPITHELIAL CELLS	01-05	0-5
CASTS	Not Detected	Not Detected
CRYSTALS	Not Detected	Not Detected
BACTERIA	Not Detected	Not Detected

----- End of Report -----

Lab Technician

PANACEA HOSPITAL
 (A UNIT OF AAROH HEALTH CARE PVT. LTD)
 REG. NO. : AL-1500
 M.D. Pathology
 B.36/44, B-4, KABIR NAGAR
 DURGAKUND, VARANASI

Timing : 8.00 a.m. to 9.00 p.m. (Sunday 8.00 a.m. to 3.00 p.m.)

This Report is not valid for medico legal purpose

Note: These tests have technical limitations. Clinico-pathological interpretation is necessary. In case of any disparity test may be repeated immediately.

Address : 36/44 FK Kabir Nagar, Durgakund, Varanasi – 221005

Email: dramishra@gmail.com, drpallaviojha@gmail.com Website: panaceahospital.org



PANACEA HOSPITAL

B 36/44 F.K KABIR NAGAR, DURGAKUND
TOLLFREE NO-18001233070.
Whatsapp No - 8795832852
www.piire.org



OP Slip

Print Date : 25-Mar-2023 10:13AM



UHID No :- UD-22230004165	OP No :- OP-22230015229	OP Date :- 25 Mar 2023 10:12AM
Patient Name :- Mrs NISHA SINHA	Age/Sex :- 38 Y/Female	Mobile No :- 9956814283
Husband :-	Department :- OBST. & GYNAECOLOGY	
Pay Type :- Cash	Consultant :- Dr VANDANA SINGH (MBBS,MS)	
Token No :- NOR. - 2	Paid/Bal :- 0.00 /30.00	
Patient Type :- Normal		
Address :- BANK OF BARODA, varanasi		

BP :- 110/80
 height :- 149
 Weight (kg) :- 65.9
 BMI :-
 SpO2 - 97
 PR - 98

Rx

Pre Diabetes
Asthma

Rx. Diet 1400 kcal (9 CS)

Tab. Diabems (5.0) AD

Revs. Aste PR (20)

Es. ~~Monlem-Rx~~ 1/2

Amal (6)

AD (10)

↓
(SUNITIN)

Printed By : Mr NITIN YADAV
Created By : Mr NITIN YADAV

Dr. Nisha Sinha

Tab FLY 180mg A/D.

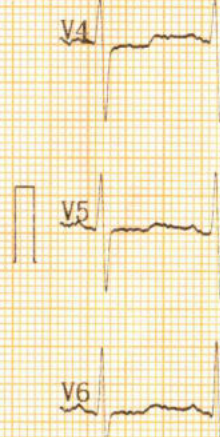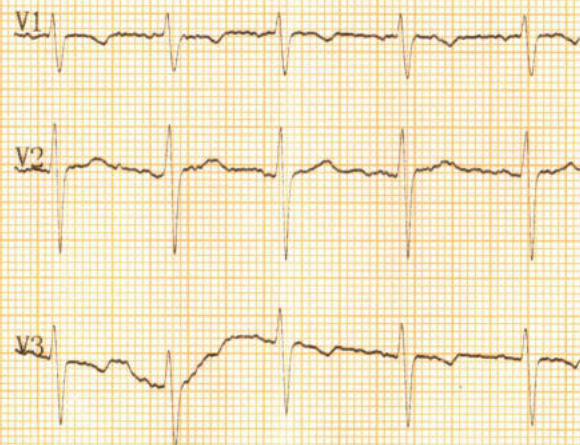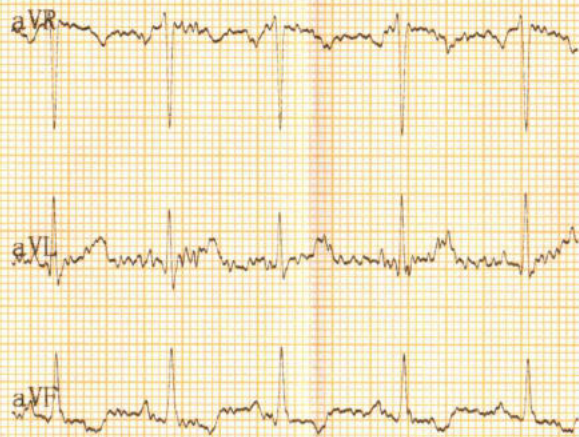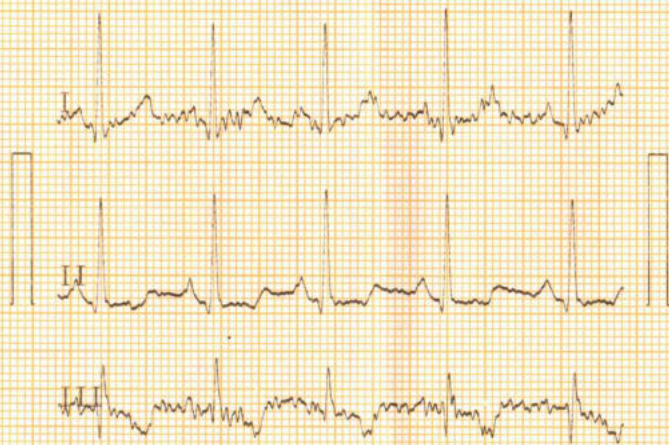BPL

AUTO 20mm/mV

20mm/mV

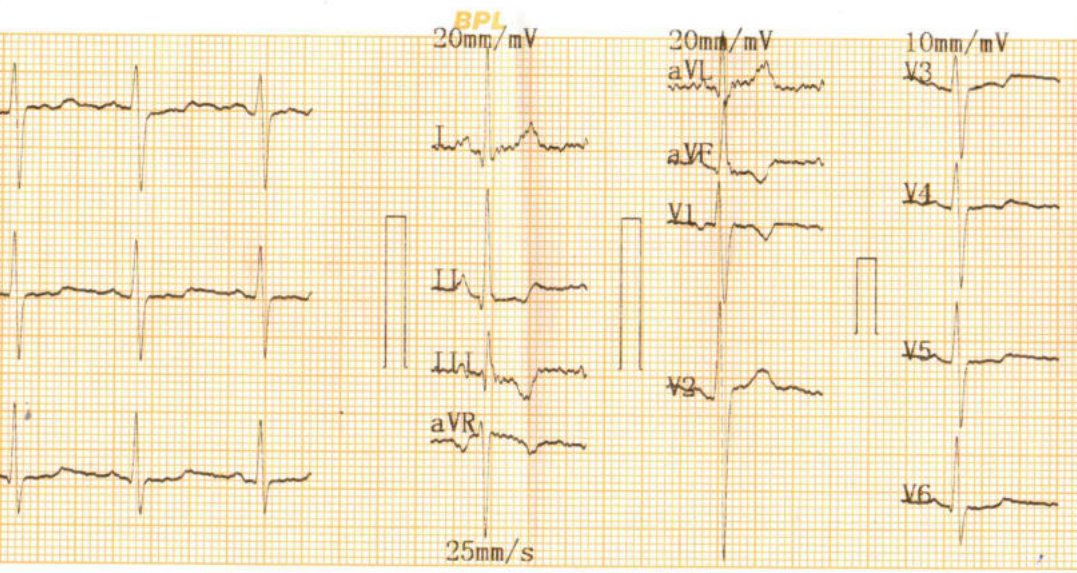
10mm/mV

10mm/mV



25mm/s AC50Hz+EMG35Hz+DFT

CARDIART



2022-03-25 11:02

ID :
 Name : *Misha Sinha*
 Sex : *female* Age : *38 yrs*
 Height : _____ Weight : _____ kg
 SYS : _____
 DIA : _____

HR : 96 bpm
 PR Interval : 148 ms
 P Duration : 120 ms
 QRS Duration : 90 ms
 T Duration : 199 ms
 QT/QTc : 339/428 ms
 P/QRS/T Axis : 50.4/47.5/-21.9 deg
 R(V5)/S(V1) : 0.80/0.51 mV
 R(V5)+S(V1) : 1.31 mV

<< Conclusions >>

Normal Sinus Rhythm;
 Cardiac electric axis normal;
 II III aVF V4 V6 Abnormal T wave;
 Report need physician confirm
ECG is within normal limits

Pallavi
DR. PALLAVI MISHRA
 MBBS, MD (GENERAL MEDICINE)
 MCI Reg. No. 52033

Physician _____



Call Now - 1800-123-3070

PANACEA HOSPITAL

A shelter for many hearts A Home for many lives

(An ISO 9001:2008 Certified Organisation)

Lab Attached with CMC Vellore Under EQAS Scheme

PATIENT'S NAME : MRS NISHA SINHA

AGE/SEX: 38 Y/F

REF. BY : Dr. ASHUTOSH MISHRA(MD)

Saturday, March 25, 2023

Echo - Cardiography

MITRAL VALVE Doppler	AML - normal morphology MV Flow - E - 1.1 A-1.4 E/A=1.28	PML - normal morphology MVA - 3.0 cm ² Mitral Regurgitation - No
TRICUSPID VALVE Doppler	Normal TV Flow -No	Tricuspid Regurgitation -No
PULMONARY VALVE Doppler	Normal PV Flow -No	Pulmonary Regurgitation - No
AORTIC VALVE Doppler	Trileaflet-No AV Flow - no	Aortic Regurgitation - no
MEASUREMENT	Aorta - 26.8 (20-38) mm IVS ed - 9.1 (6 -12) mm LVID ed - 41.1 (35 - 55) mm LVPW ed - 12.6 (6 -12) mm OA - 7 (> 5) mm	LA - 29.1 (24-32) mm IVS es -12.0 (6 - 12) mm LVID es - 28.6 (24 - 40) mm LVPW es - 12.6 (6 -12) mm EPSS - 4 (< 9) mm


CONCLUSION

All cardiac chamber dimensions are WNL
No valvular abnormalities
Good LV systolic function present Modified Simpson's method (4C, 2C) (LVEF-59%)
No diastolic dysfunction present (E/A = 1.28) by tissue Doppler (E/e'=6.2)
No RWMA
No pericardial effusion
Intact IAS / IV
No PAH
No intra cardiac mass /thrombus /vegetation

IMPRESSION

Normal Echocardiogram


Niraj Mishra
Physician Assistant
(PIIRE)


DR. PALLAVI MISHRA
MBBS, MD (GENERAL MEDICINE),
MCI Reg.No. 52033
Dr. Pallavi Mishra
MBBS, MD (MED) Lucknow
Echocardiography Specialist, MIAE
Non-invasive cardiologist
Women Cardiologist
Diabetocardiologist

Address : Kabir Nagar (Near Sanjay Shiksha Niketan), Durgakund, Varanasi

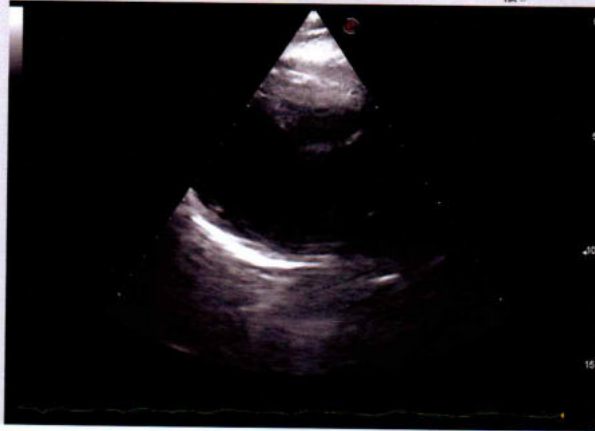Mobile : 9554572190 / 9453837595 / Recpn. 9389994334

E-mail : dramishra@gmail.com, drpallaviojha@gmail.com, Website: www.piire.org

NISHA SINHA,F

25 03 2023 05:42:28 PM

TEI D 160 mm XM C2- P 80% MI 0.9
PRC 6/3/24 PRS 1 TIS 0.5

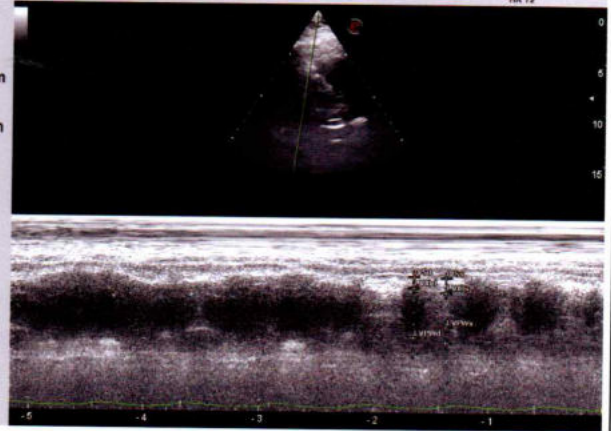


NISHA SINHA,F

25 03 2023 05:42:28 PM

TEI D 160 mm XM C2- M F PENL G -- P 80% MI 0.7
PRC 6/3/24 PRS 1 TIB 0.5

LV
RVIDd --- mm
IVSd 9.1 mm
LVVDd 41.1 mm
LVPWd 12.6 mm
IVSs 12.0 mm
LVIDs 28.6 mm
LVPWs 12.6 mm
EF 59 %
%LV FS 31 %
HR eca 72 bpm
%IVS 31 %
%PW 0 %
LVMass 172 g
LVMI ---
S-PWD --- ms
FloPrV --- m/s
E/Vp ---

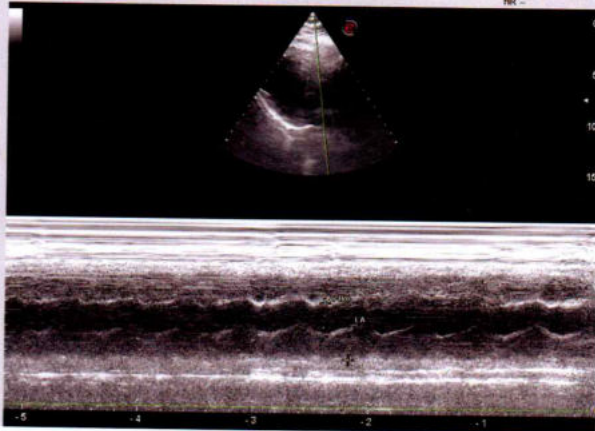


NISHA SINHA,F

25 03 2023 05:42:28 PM

TEI D 160 mm XM C2- M F PENL G -- P 80% MI 0.7
PRC 6/3/24 PRS 1 TIB 0.5

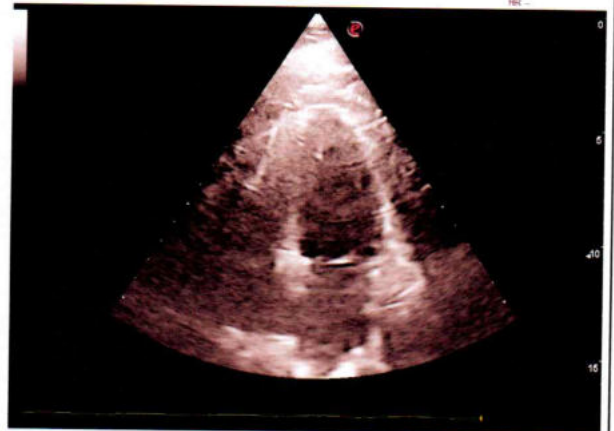
Aorta/LA
Ao Dm 26.8 mm
LA 29.1 mm
AV Op --- mm
LVET --- ms
Ao PEP --- ms
PEP/ET ---
R-R --- ms
AVCoap --- mm
LA/Ao 1.09
AV EI ---



NISHA SINHA,F

25 03 2023 05:42:28 PM

TEI D 160 mm XM C2- M F PENL G -- P 80% MI 0.7
PRC 6/3/24 PRS 1 TIB 0.5

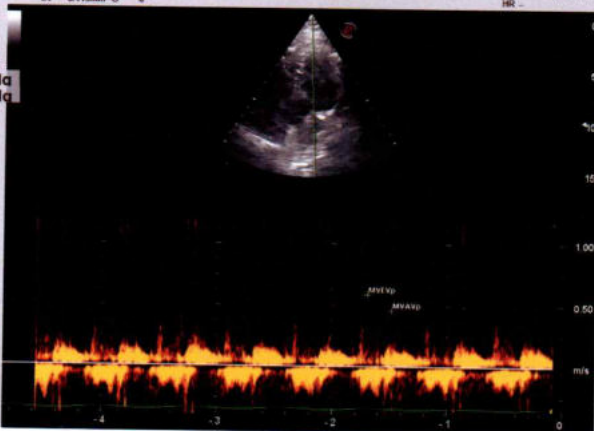


NISHA SINHA,F

25 03 2023 05:42:28 PM

TEI D 160 mm XM C2- PW F 2.5 MHz G -- P 80% MI 0.4
PRC 6/3/24 PRS 1 PRF 5.1 MHz WF 150 Hz TIS 0.5
SV 3/11mm Q IP PRC 4/1 TIB 1.1

MV
MV VTI --- m
MVEVp 0.59 m/s
MVAVp 0.46 m/s
MVEGp 1.4 mmHg
MVA Gp 0.8 mmHg
MVMn --- m/s
MGmn --- mmHg
MV Pht --- ms
MVApht --- cm²
MV E/A 1.28
MV AT --- ms
MV DT --- ms
IVRT --- ms
IVCT --- ms
A Dur --- ms
LVET --- ms
LIMP ---





Call Now - 1800-123-3070

PANACEA HOSPITAL

A shelter for many hearts A Home for many lives

(An ISO 9001:2008 Certified Organisation)

Lab Attached with CMC Vellore Under EQAS Scheme

PATIENT'S NAME : NISHA SINHA AGE/SEX: 38 Y/F
REF. BY : Dr. ASHUTOSH MISHRA(MBBS, M.S.) Saturday, March 25, 2023

U/S. WHOLE ABDOMEN

- LIVER** : Liver is normal in size, shape & echotexture. Intra hepatic biliary radicals are normal. Portal venous channels are normal.
- C.B.D.** : C.B.D. is normal in caliber.
- PANCREAS** : Pancreas is normal in size, shape and echotexture. No evidence of any inflammatory disease or mass.
- SPLEEN** : Spleen is normal in size, shape and echotexture.
- Rt. KIDNEY** : Normal in size, shape and echotexture. Renal sinus is normal
Cortico medullary differentiation is normal. P. C. system is normal.
- Lt. KIDNEY** : Normal in size, shape and echotexture. Renal sinus is normal
Cortico medullary differentiation is normal. P. C. system is normal.
- URI. BLADDER** : Urinary bladder is normal in size, position. Wall thickness normal.
No evidence of calculus or mass.
- UTERUS** : Normal in size ,shape & echotexture. Endometrial echo is normal.
- OVARIES** : Rt. Ovary:- Normal in size.
Lt. Ovary:-Normal in size.
No free fluid seen in P. O. D.
- IMPRESSION** : **NO OBVIOUS SONOLOGICAL ABNORMALITY SEEN.**

DR. R. TIWARI
(M.B.B.S., M.D.(KGMU, LKO)
(RADIOLOGIST).

Thanks for reference.

Address : Kabir Nagar (Near Sanjay Shiksha Niketan), Durgakund, Varanasi

Mobile : 9554572190 / 9453837595 / Recpn. 9389994334

E-mail : dramishra@gmail.com, drpallaviojha@gmail.com, Website: www.piire.org

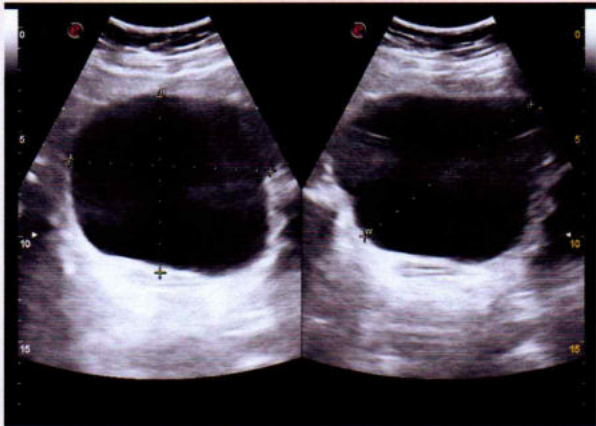
NISHA SINHA 38Y/F

25 03 2023 12:06:13 PM

ABDOMINAL
AC2541 ABD

B GEN M G —
TEI D 160 mm X/M C2/-
PRC 19/2/3/5 PRS 4

Urinary Bladder
L 96.1 mm
H 84.2 mm
W 101.7 mm
Vol 430.7 ml

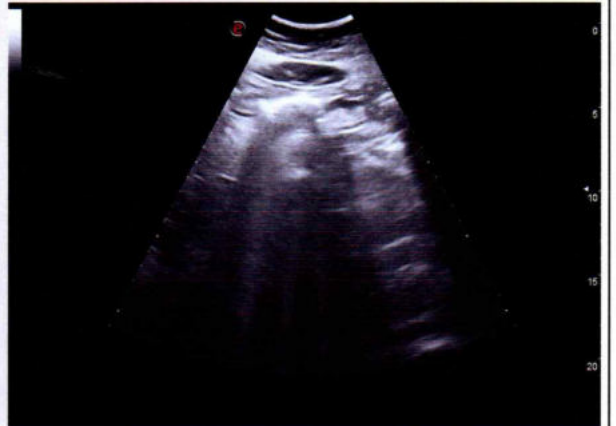

NISHA SINHA 38Y/F

25 03 2023 12:06:13 PM

ABDOMINAL
AC2541 ABD

B GEN M G —
TEI D 211 mm X/M C2/-
PRC 19/2/3/5 PRS 4

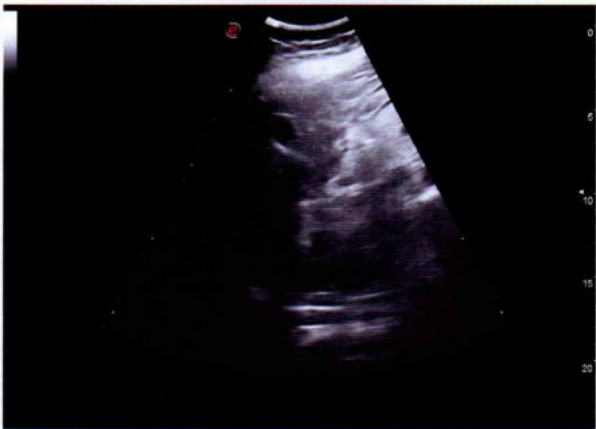

NISHA SINHA 38Y/F

25 03 2023 12:06:13 PM

ABDOMINAL
AC2541 ABD

B GEN M G —
TEI D 211 mm X/M C2/-
PRC 19/2/3/5 PRS 4

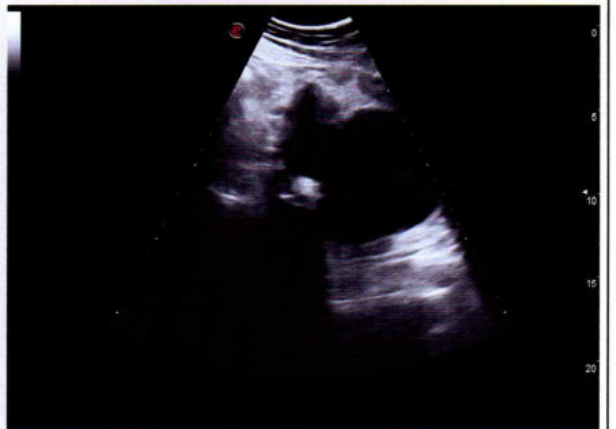

NISHA SINHA 38Y/F

25 03 2023 12:06:13 PM

ABDOMINAL
AC2541 ABD

B GEN M G —
TEI D 211 mm X/M C2/-
PRC 19/2/3/5 PRS 4

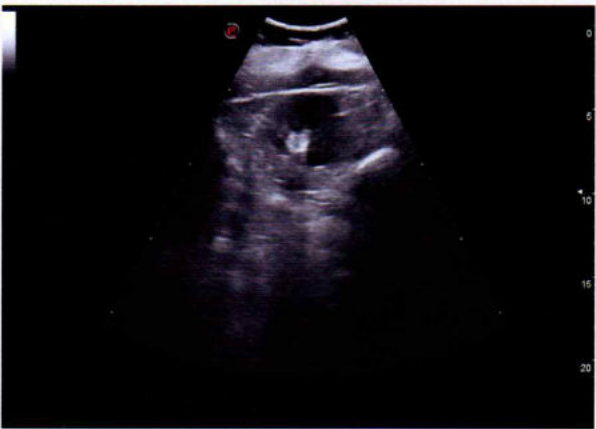

NISHA SINHA 38Y/F

25 03 2023 12:06:13 PM

ABDOMINAL
AC2541 ABD

B GEN M G —
TEI D 211 mm X/M C2/-
PRC 19/2/3/5 PRS 4





PANACEA HOSPITAL

A shelter for many hearts A Home for many lives

(An ISO 9001:2008 Certified Organisation)

Lab Attached with CMC Vellore Under EQAS Scheme

NAME:NISHA SINHA

AGE/SEX: 37 YR/FEMALE

REFBY:DR.ASHUTOSH MISHRA(MD)

DATE:25/03/2023

X-RAY CHEST PA

BOTH LUNG FIELDS AND PLEURAE:

Both lungs show normal bronchovascular pattern.

Right & left hila are normal

No focal mass or calcification is seen

There is no evidence of any fluid in the both the pleural cavities.

Both domes of diaphragms are normal in position.

MEDIASTINUM:

Trachea is central in position.

Cardiac silhouette is of normal size and configuration.

No evidence of pericardial effusion.

No significant lymphadenopathy is seen.

Visualized skeleton is normal.

NO SIGNIFICANT RADIOGRAPHIC ABNORMALITY.

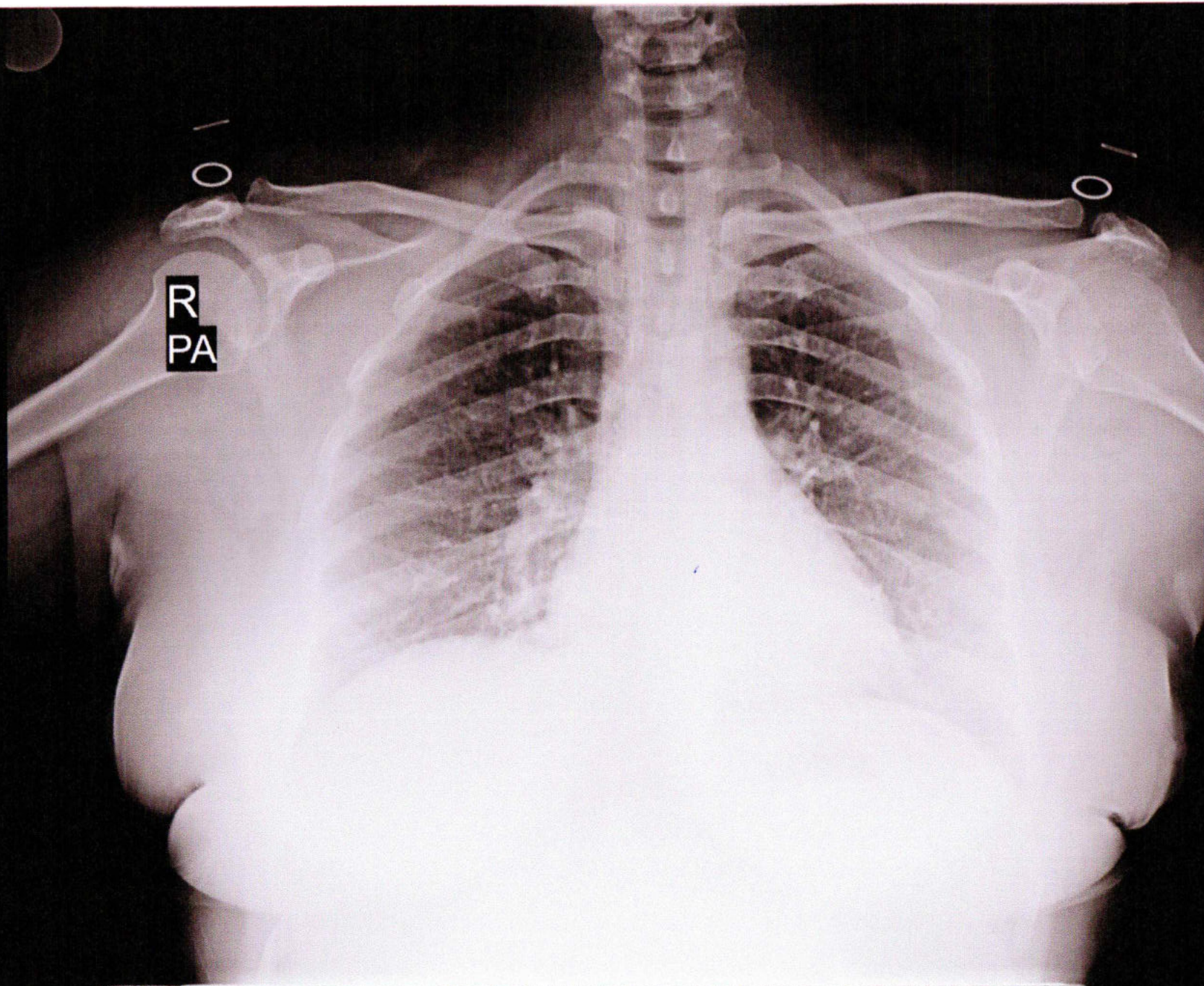
(Signature)
REPORTED BY

DR. Rahul Kumar Tiwari
MBBS, MD (Radio Diagnosis)
Reg.No. 57557

Address : Kabir Nagar (Near Sanjay Shiksha Niketan), Durgakund, Varanasi

Mobile : 9554572190 / 9453837595 / Recpn. 9389994334

E-mail : dramishra@gmail.com, drpallaviojha@gmail.com, Website: www.piire.org



NISHA SINHA 38Y\F 4165 O CHEST P.A. 25-Mar-23 10:43 AM

PANACEA HOSPITAL, KABIR NAGAR, DURGAKUND, VARANASI