

CERTIFICATE OF MEDICAL FITNESS

This is to certify that I have conducted the clinical examination of

Mrs. DODDI UMARANI on 23/07/23 After reviewing the medical history on clinical examination it has been found that he/she is

Medically Fit	<input checked="" type="checkbox"/> Yes	<input type="checkbox"/> No
---------------	---	-----------------------------

Fit with restrictions/recommendations

Though following restrictions have been revealed, in my opinion, these are not impediments to the job.

1.....

2.....

3.....

However the employee should follow the advice/medication that has been communicated to him/her.

Review after

Currently Unfit.

Review after.....

Recommended Unfit

.....

Dr.
Medical Officer
The Apollo Clinic, Chandanagar



P. Sangeetha
Dr. P. SANGEETHA
 M.B.B.S. MD (Gen. Med)
 Regd No. TSMC/ FMR/ 19993
 Consultant Physician

This certificate is not meant for medico-legal purposes

Apollo Health and Lifestyle Limited

(CIN - U85110TG2000PLC046089) Regd. Office: 7-1-617/A, 7th Floor, Imperial Towers, Ameerpet, Hyderabad-500016, Telangana. | Email ID: enquiry@apollohl.com

APOLLO CLINICS NETWORK TELANGANA & AP

Hyderabad (AS Rao Nagar | Chanda Nagar | Jubilee Hills | Kondapur | Manikonda | Nallakunta | Nizampet | Uppal)
 Vizag (Seethamma Peta)

Online appointments: www.apolloclinic.com

TO BOOK AN APPOINTMENT

 **1860 500 7788**

PRESCRIPTION

Besaid Bata Show Room ,Madinaguda opp SBI Bank Hyderabad .040-23046745

Name: D UMA RANI Date: 23-09-2023

Age: 37

UHID: _____ PH NO _____

	SPHE	CYL	AXIS	ADD	CVA
RIGHT	-2.5				20/20
LEFT	-2				20/20

Single Vision

Biofocal

Progressive

Glass

K-Biofocal

Normal Progressive

CR-39

D- Biofocal

Internal Progressive

Polycarbonate

(Glass/CR)

ARC

High Index

Photochromic

Contact Lenses:

Daily Disposables

Monthly Disposables

Quarterly Disposables

Yearly DM

Tori- ca BP

Cosmetics

Colour Vision Test:

RE: NORMAL

LE NORMAL

NEXT EXAMINATIONS : 1 YEAR

Month / Year

Signature

Apollo Health and Lifestyle Limited

(CIN - U85110TG2000PLC046089) Regd. Office: 7-1-617/A, 7th Floor, Imperial Towers, Ameerpet, Hyderabad-500016, Telangana. | Email ID: enquiry@apollohl.com

APOLLO CLINICS NETWORK TELANGANA & AP

Hyderabad (AS Rao Nagar | Chanda Nagar | Jubilee Hills | Kondapur | Manikonda | Nallakunta | Nizampet | Uppal)

Vizag (Seethamma Peta)

Online appointments: www.apolloclinic.com

TO BOOK AN APPOINTMENT

 **1860 500 7788**

Name <u>Mrs. D. Uma Rani</u>	Date <u>23/9/23</u>
Age <u>37y</u>	UHID No. <u>172549.</u>
<input type="checkbox"/> Male <input checked="" type="checkbox"/> Female	Ref. Physician <u>Arcofemj</u>
Ref. Diagnosis	

Echocardiogram Report

Echogenicity Poor Adequate Good

Ht. _____ Wt. _____ BSA _____

DIMENSIONS		NORMAL	DIMENSIONS		NORMAL
Ao (ed)	<u>2.3</u> cm	(1.5cm / m2)	IVS (Ed)	<u>1.2</u> cm	(0.6 - 1.2 cm)
LA (es)	<u>3.4</u> cm	(1.5cm / m2)	LVPW (Ed)	<u>1.1</u> cm	(0.6 - 1.1 cm)
RVID (ed)	_____ cm	(0.9 cm / m2)	EF	<u>65%</u>	(0.62 - 0.85)
LVID (ed)	<u>4.0</u> cm	(2.6 - 3.4 cm / m2)	% FD	<u>33%</u>	(2.8% - 42%)
LVID (es)	<u>2.4</u> _____				

MORPHOLOGICAL DATA

Mitral Valve AML _____
 PML _____
 Aortic Valve _____
 Tricuspid valve _____
 Pulmonary valve _____
 Right ventricle _____

Interatrial septum _____
 Interventricular septum Intact
 Pulmonary artery _____
 Aorta _____
 Right atrium _____
 Left atrium _____

THE APOLLO CLINIC
PHYSICAL EXAMINATION FORM

DarcoFem 3
- mediwheel

BILL DATE : 23/9/20 UHID: 172549

BILL NO: 81266

PATIENT NAME : Mrs. Umarani, D.

AGE: 37 y

Weight : 63.1 Kgs

Height : 158. Cms

Chest Measurement :

(in)

(out)

Abdomen :

Pulse : 80 / bpm

B.P : 120/70 / mm Hg

SpO2 - 99.1

Waist - 90 cm

Hip - 103 cm

BMI - 25

Umarani P

Acrow CE

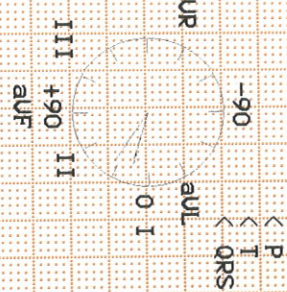
HR 80 bpm

Measurement Results:

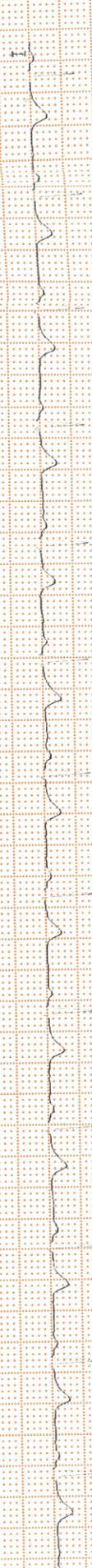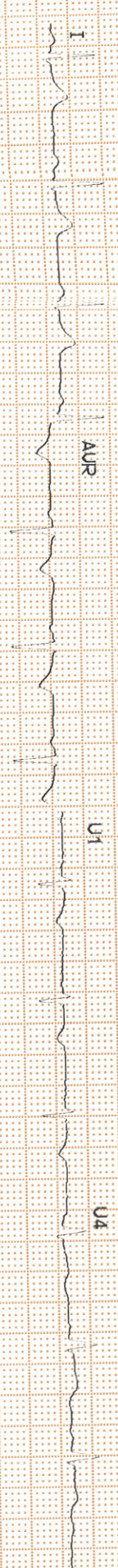
QRS	90	ms
QT/QTcB	378 /	435 ms
PR	116	ms
P	90	ms
RR/pp	748 /	750 ms
P/QRS/T	17 /	35 / 18 degrees

Interpretation:
12SL - Interpretation:
Normal sinus rhythm
Normal ECG

NSA



Unconfirmed report.



Patient Name	: Mrs. DODDI UMARANI	Age/Gender	: 37 Y/F
UHID/MR No.	: CCHA.0000172549	OP Visit No	: CCHAOPV308397
Sample Collected on	:	Reported on	: 23-09-2023 13:19
LRN#	: RAD2106011	Specimen	:
Ref Doctor	: SELF		
Emp/Auth/TPA ID	: 114805		

DEPARTMENT OF RADIOLOGY

ULTRASOUND - WHOLE ABDOMEN

Liver appears normal in size and echotexture. No focal lesion is seen. PV and CBD normal. No dilatation of the intrahepatic biliary radicals. **Liver measures** : 13.0 cm.

Gall bladder is well distended. No evidence of calculus. Wall thickness appears normal. No evidence of periGB collection. No evidence of focal lesion is seen.

Spleen is normal. No focal lesion seen. Splenic vein is normal. **Spleen measures** : 8 cm.

Pancreas appears normal in echopattern. No focal/mass lesion/calcification. No evidence of peripancreatic free fluid or collection. Pancreatic duct appears normal.

Both the kidneys appear normal in size, shape and echopattern. Cortical thickness and CM differentiation are maintained. No calculus / hydronephrosis seen on either side. **Right kidney measures** : 95 x 40 mm . , **Left kidney measures** : 100 x 40 mm .

Urinary Bladder is well distended and appears normal. No evidence of any wall thickening or abnormality. No evidence of any intrinsic or extrinsic bladder abnormality detected.

Uterus appears normal in size. It shows normal shape & echo pattern.

Uterus measures : 18 x 30 x 35 mm.

Endometrial echo-complex appears normal and **measures** 11 mm.

No intra/extra uterine gestational sac seen.

Both ovaries appear normal in size, shape and echotexture.

Right ovary measures : 30 x 20 mm . , **Left ovary measures** : 27 x 16 mm.

Dominant follicle measures 15 mm seen in Left ovary .


IMPRESSION:-

1 . No Significant Abnormality Detected.

Patient Name : Mrs. DODDI UMARANI

Age/Gender : 37 Y/F

(The sonography findings should always be considered in correlation with the clinical and other investigation finding where applicable.) It is only a professional opinion, Not valid for medico legal purpose.



Dr. G HEMALATHA
MBBS,DNB
Radiology

Patient Name : Mrs. DODDI UMARANI

Age/Gender : 37 Y/F

UHID/MR No. : CCHA.0000172549

OP Visit No : CCHAOPV308397

Sample Collected on :

Reported on : 23-09-2023 10:49

LRN# : RAD2106011

Specimen :

Ref Doctor : SELF

Emp/Auth/TPA ID : 114805

DEPARTMENT OF RADIOLOGY

X-RAY CHEST PA

Both lung fields and hila are normal .

No obvious active pleuro-parenchymal lesion seen .


Both costophrenic and cardiophrenic angles are clear .

Both diaphragms are normal in position and contour .

Thoracic wall and soft tissues appear normal.

CONCLUSION :

No obvious abnormality seen



Dr. G HEMALATHA
MBBS,DNB
Radiology

Fwd: Health Check up Booking Confirmed Request(bobE45046),Package Code-PKG10000317, Beneficiary Code-26651

UmaraniDoddi UmaraniDoddi <umaraniDoddi@gmail.com>

Sat 9/23/2023 7:16 AM

To: Chandanagar Apolloclinic <chandanagar@apolloclinic.com>

----- Forwarded message -----

From: **Mediwheel** <wellness@mediwheel.in>

Date: Sat, 9 Sep, 2023, 4:31 pm

Subject: Health Check up Booking Confirmed Request(bobE45046),Package Code-PKG10000317, Beneficiary Code-26651

To: <umaraniDoddi@gmail.com>

Cc: <customercare@mediwheel.in>

011-41195959

[Email:wellness@mediwheel.in](mailto:wellness@mediwheel.in)

Dear **MS. DODDI UMARANI,**

Please find the confirmation for following request.

Booking Date	: 24-08-2023
Package Name	: Arcofemi MediWheel Full Body Health Annual Plus Check Female 2D : ECHO (Metro)
Name of Diagnostic/Hospital	: Apollo Clinic
Address of Diagnostic/Hospital	: Suresh Square, Opposite SBI Bank, Madeenaguda, Serilingampally Mandal, Chanda Nagar -500050
Contact Details	: (040) 2304 6744 - 45,46,48/6309937232
City	: Hyderabad
State	: Telangana
Pincode	: 500050

Appointment Date : 23-09-2023

Confirmation Status : Confirmed

Preferred Time : 09:30:AM

Comment : APPOINTMENT TIME 9:00AM

Instructions to undergo Health Check:

1. Please ensure you are on complete fasting for 10-To-12-Hours prior to check.
2. During fasting time do not take any kind of medication, alcohol, cigarettes, tobacco or any other liquids (except Water) in the morning.
3. Bring urine sample in a container if possible (containers are available at the Health Check centre).
4. Please bring all your medical prescriptions and previous health medical records with you.
5. Kindly inform the health check reception in case if you have a history of diabetes and cardiac problems.


For Women:


1. Pregnant Women or those suspecting are advised not to undergo any X-Ray test.
2. It is advisable not to undergo any Health Check during menstrual cycle.

Request you to reach half an hour before the scheduled time.

In case of further assistance, Please reach out to Team Mediwheel.

© 2023-2024, Arcofemi Healthcare Limited.




 **बैंक ऑफ बरोडा**
Bank of Baroda

नाम डूदी उमरानी
Name Doodi Umarani

EC No 114805


सहायक अधिकारी
Assistant Branch




Doodi Umarani
Assistant Branch

Patient Name : Mrs. DODDI UMARANI Age : 37 Y/F
UHID : CCHA.0000172549 OP Visit No : CCHAOPV308397
Conducted By: : Dr. A RAVINDRA Conducted Date : 23-09-2023 13:54
Referred By : SELF

2D-ECHO WITH COLOUR DOPPLER

Dimensions:

Ao (ed)	2.3 CM
LA (es)	3.4 CM
LVID (ed)	4.0 CM
LVID (es)	2.4 CM
IVS (Ed)	1.2 CM
LVPW (Ed)	112 CM
EF	65.00%
%FD	33.00%
MITRAL VALVE :	NORMAL
AML	NORMAL
PML	NORMAL
AORTIC VALVE	NORMAL
TRICUSPID VALVE	NORMAL
RIGHT VENTRICLE	NORMAL
INTER ATRIAL SEPTUM	INTACT
INTER VENTRICULAR SEPTUM	INTACT
AORTA	NORMAL
RIGHT ATRIUM	NORMAL
LEFT ATRIUM	NORMAL
Pulmonary Valve	NORMAL
PERICARDIUM	NO EFFUSION
LEFT VENTRICLE: NO RWMA	

Patient Name	: Mrs. DODDI UMARANI	Age	: 37 Y/F
UHID	: CCHA.0000172549	OP Visit No	: CCHAOPV308397
Conducted By:	: Dr. A RAVINDRA	Conducted Date	: 23-09-2023 13:54
Referred By	: SELF		

COLOUR AND DOPPLER STUDIES:- MILD MR/ TRIVIAL TR/ NO AR/ PR

PWD: A>E AT MITRAL INFLOW

E/A-E: 0.8m/sec A: 0.7m/sec

VELOCITY ACROSS THE PULMONIC VALVE UPTO
0.7m/sec

VELOCITY ACROSS THE AV UPTO 1.2m/sec

IMPRESSION:-

MILD CONCENTRIC LVH,

NORMAL CARDIAC CHAMBERS,

NO RWMA,

MILD MR / TRIVIAL MR/ NO AR,

GOOD LV FUNCTION,

MILD MR/ TRIVIAL TR/ NO AR,

NO PE CLOT VEGS.

Ravindra A,

Patient Name	: Mrs. DODDI UMARANI	Age	: 37 Y/F
UHID	: CCHA.0000172549	OP Visit No	: CCHAOPV308397
Reported By:	: Dr. A RAVINDRA	Conducted Date	: 23-09-2023 15:06
Referred By	: SELF		

ECG REPORT

Observation :-

1. Normal Sinus Rhythm.
2. Heart rate is 80 beats per minutes.
3. No pathological Q wave or S-T,T changes seen.
4. Normal P,Q,R,S,T waves and axis.
5. No evidence of chamber, hypertrophy or enlargement see

Impression:

NORMAL RESTING ECG.

----- END OF THE REPORT -----



Dr. A RAVINDRA

Patient Name	: Mrs. DODDI UMARANI	Age	: 37 Y/F
UHID	: CCHA.0000172549	OP Visit No	: CCHAOPV308397
Reported By:	: Dr. A RAVINDRA	Conducted Date	: 23-09-2023 15:06
Referred By	: SELF		

ECG REPORT

Observation :-

1. Normal Sinus Rhythm.
2. Heart rate is 80 beats per minutes.
3. No pathological Q wave or S-T,T changes seen.
4. Normal P,Q,R,S,T waves and axis.
5. No evidence of chamber, hypertrophy or enlargement see

Impression:

NORMAL RESTING ECG.

----- END OF THE REPORT -----



Dr. A RAVINDRA