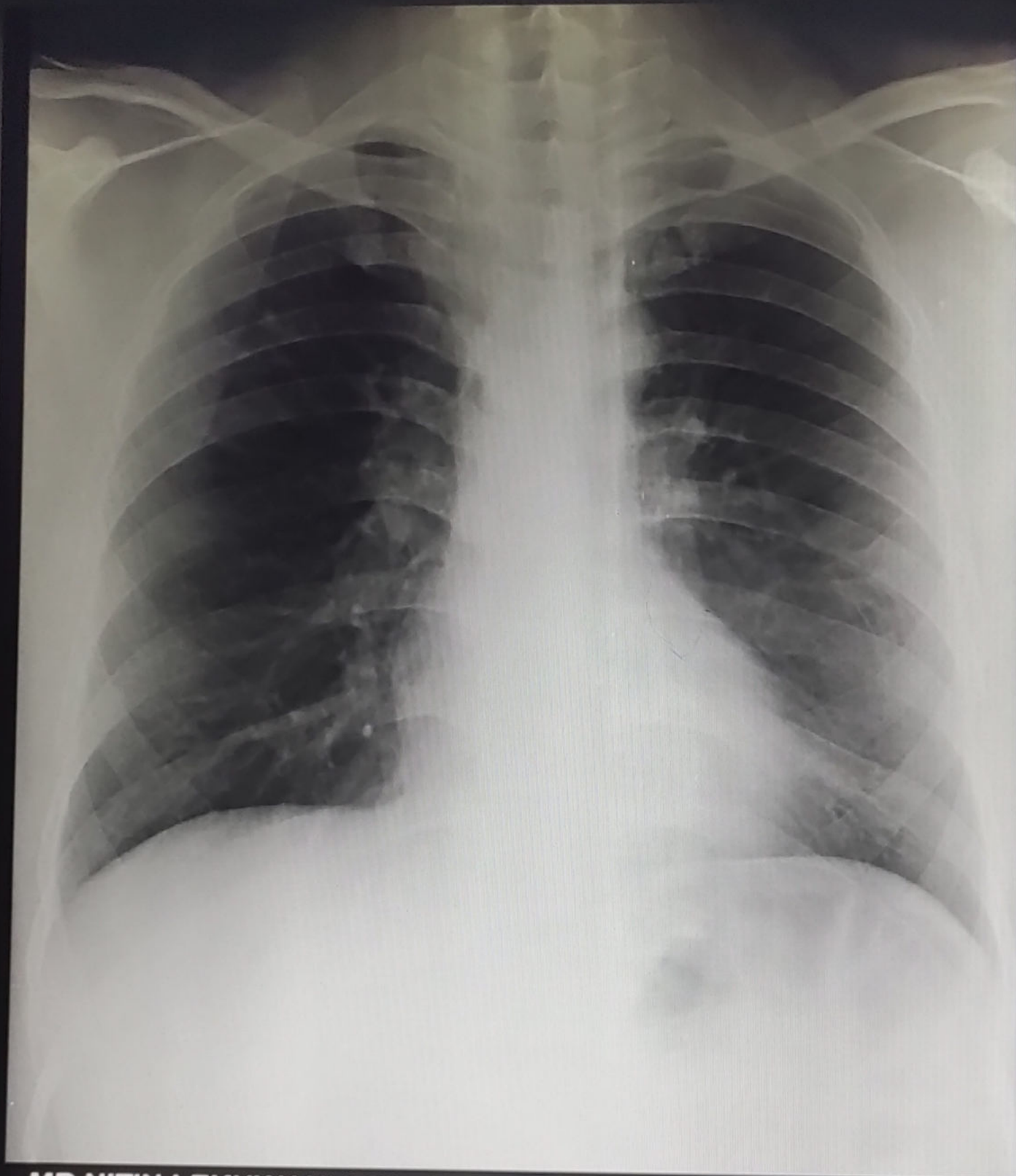

MR NITIN LEKHWANI 32Y 1164 CHEST,FRN P->A 09-May-22
DIWAKAR DIAGNOSTIC CENTRE , ARERA COLONY ,BHOPAL




दिवाकर डायग्नोस्टिक सेंटर

E-7/636, पंजाब नेशनल बैंक के पास, मैन रोड, अरेरा कॉलोनी भोपाल (म.प्र.)

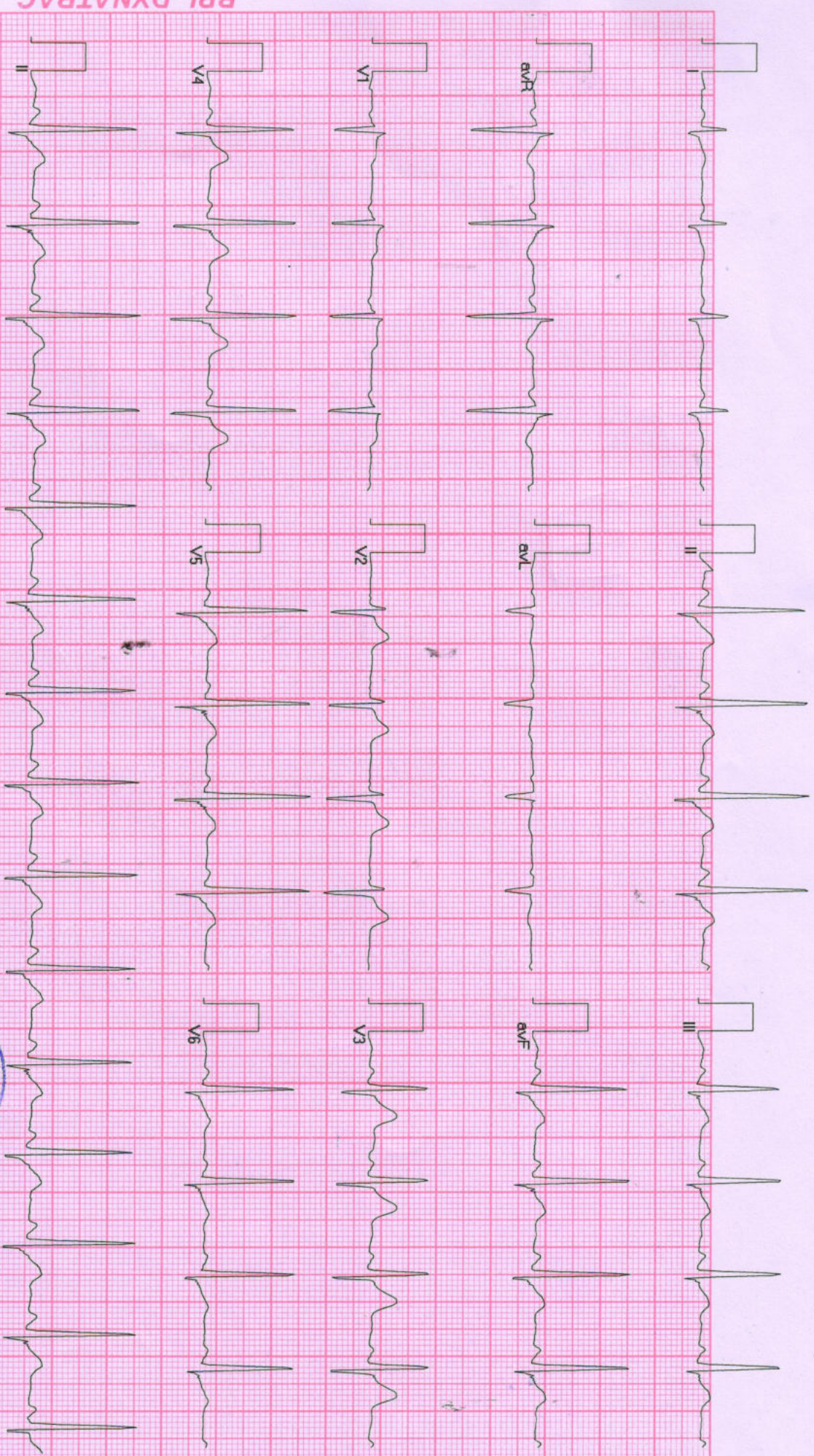
फोन: 0755-2465288, 0755-3520545 मो: 9826340190

R
Dr. B. M. Agarwal
MBBS, DCP
Consultant Pathologist



	बैंक ऑफ़ बड़ोदा Bank of Baroda
नाम Name	Nitin Lekhwani
कर्मचारी कुट क. Employee Code No.	180480
जारीकर्ता प्राधिकारी Issuing Authority	<i>Pranshu</i>
घरक के हस्ताक्षर Signature of Holder	<i>Nitin</i>

AD
AD



BPL-DYNATRAC

101





दिवाकर डायग्नोस्टिक सेंटर

E-7/636, पंजाब नेशनल बैंक के पास, मैन रोड, अरेरा कॉलोनी भोपाल (म.प्र.)

फोन: 0755-2465288, 0755-3520545 मो: 9826340190

Pt.Name :-	Mr. Nitin Lekhwani
Age :-	40y/M
Refd. By :-	BOB
Lab.pNo.:-	125
Date :-	09/05/2022

REPORT

Tricia Central

Thoracic cage normal

Both Lungs Field Clear.

Both hilers normal

Cardiac border normal

Both cp angles clear

Both domes and diaphragm normal

IMPRESSION

-NO CARDIO PULMONARY PATHOLOGY

-COORELATE WITH CLINICAL FINDINGS.




B
Dr. B. M. Agarwal
MD, Radiology
Consultant Radiologist
Radiologist

Pt.Name :-	Mr. Nitin Lekhwani
Age :-	40y/M
Refd. By :-	BOB
Lab.pNo.:-	125
Date :-	09/05/2022

EXAMINATION OF BLOOD

<u>TEST</u>	<u>RESULT</u>	<u>NORMAL VALUE</u>
PSA	4.97 ng/ml.	0.21-6.77 ng/ml.




Dr. B. M. Agarwal
 MBBS, DCP
 Consultant Pathologist

All test have technical limitation. Collaborative clinic pathological interpretation is mandatory. In case of disparity test may be repeated immediately. Typographic mistakes should be get correct instantly. This report is not valid for medico legal purpose



दिवाकर डायग्नोस्टिक सेंटर

E-7/636, पंजाब नेशनल बैंक के पास, मैन रोड, अरेरा कॉलोनी भोपाल (म.प्र.)

फोन: 0755-2465288, 0755-3520545 मो: 9826340190

Pt.Name :-	Mr. Nitin Lekhwani
Age :-	40y/M
Refd. By :-	BOB
Lab.pNo.:-	125
Date :-	09/05/2022

EXAMINATION OF BLOOD

Thyroid profile

<u>TEST</u>	<u>RESULT</u>	<u>NORMAL VALUE</u>
T3 - TOTAL	98.2	82-213 ng/dL
T4 - TOTAL	6.89	6.09-12.23 ug/dL
THYROID STIMULATING HORMONE (TSH)	2.66	0.45-4.25 ul/mL

Interpretation:

TSH Levels will be elevated in primary hypothyroidism, TSH levels will be low in Hyperthyroidism there is decreased production of thyroid hormones by the thyroid hence the person may experience symptoms such as weight gain, constipation, cold intolerance and fatigue. Iodine deficiency and Hashimoto thyroiditis is the most common cause of hypothyroidism It makes Thyroid stimulating hormone. If TSH levels are abnormally high it could mean you have an underactive thyroid or hypothyroidism.

B
Dr. B. M. Agarwal
MBBS, DCP

Pathologist Consultant Pathologist

All test have technical limitation. Collaborative clinic pathological interpretation is mandatory. In case of disparity test may be repeated immediately. Typographical mistakes should be get correct instantly. This report is not valid for medico legal purpose





दिवकर डायग्नोस्टिक सेंटर

E-7/636, पंजाब नेशनल बैंक के पास, मैन रोड, अरेरा कॉलोनी भोपाल (म.प्र.)


फोन: 0755-2465288, 0755-3520545 मो: 9826340190

Pt.Name :-	Mr. Nitin Lekhwani
Age :-	40y/M
Refd. By :-	BOB
Lab.pNo.:-	125
Date :-	09/05/2022

URINE ANALYSIS

<u>A. PHYSICALEXAMINATION</u>		<u>C. MICROSCOPIEXAMINATION</u>	
1. Colour	Pale Yellow	Pus Cells	2-4/HPF
2. Appearance	Clear	R.B.C.	Nil
3. Specific Gravity	Q.N.S.	Epithelial Cell	1-2/HPF
<u>B. CHEMICAL EXAMINATION</u>		Cast	Nil
1.Reaction	Acidic	Crystals(Cal.Oxa)	Nil
2.Albumin	Nil	Bacteria	Nil
3.Sugar	Nil	Amorphous	Nil
4.Bile Salts	Absent	T. Vaginatis	Nil

URINE COTININE	Negative	By Card method
----------------	----------	----------------



Dr. B. M. Agarwal
MBBS, DCP
Consultant Pathologist

All test have technical limitation. Collaborative clinic pathological interpretation is mandatory. In case of disparity test may be repeated immediately. Typographic mistakes should be get correct instantly. This report is not valid for medico legal purp



दिवाकर डायग्नोस्टिक सेंटर

E-7/636, पंजाब नेशनल बैंक के पास, मैन रोड, असेरा कॉलोनी भोपाल (म.प्र.)


फोन: 0755-2465288, 0755-3520545 मो: 9826340190

Pt.Name :-	Mr. Nitin Lekhwani
Age :-	40y/M
Refd. By :-	BOB
Lab.pNo.:-	125
Date :-	09/05/2022

EXAMINATION OF BLOOD

TEST	RESULT	NORMAL VALUE
Haemoglobin	15.7mgs%	Female 12-16gms%, Male 14-18gms%
Red Cell count	5.2	4.5-5.6 million /cumm
Platelet Count	2.92	1.5-5.6 Lac/cumm
Leucocytes per.cu.mm	8100/cumm	5000-11000/cumm
Neutrophils	57%	50-70%
Lymphocytes	33%	20-40%
Eosinophils	06%	0-7%
Monocytes	04%	2-8%
PCV	42.6	37-47
MCV	80.5	76-96
MCH	31.6	27-32
MCHC	33.8	31-35
ESR	04	Male 0-9, Female 0-20mm/FHR
Blood Group	"B" Positive	
S.Bilirubin(Total)	0.89	0.2-1.0mg/dl
Direct	0.35	0.0-0.25mg/dl
Indirect	0.54	
SGOT	31.8	5-35U/L
SGPT	38.0	8-40U/L
Alk Phosphatase	10.6	3-13 KA units
S. Protein(Total)	7.0	6.0-8.0mg%
Albumin	4.0	3.7-5.3mg%
Globulin	3.0	1.5 to 3.5 mg%
AG Ratio	1.23	1.-2.0
Blood Urea Nitrogen (BUN)	16.1	7-20 mg/dl
S.Creatine	1.2	0.5-1.4mg/dl
S. Uric Acid	6.1	3.5-7.5mg%
Calcium	9.1	8.5-10.5 gm/dl
GGTP	33.2	5-35 UL/dl
Fasting Blood Sugar	79.8	70 to 110mg/dl
Post Prandial Blood Sugar	138.9	Up to 15mg/dl
Total Serum Cholesterol	165.8	100-250 mg%
Serum Triglyceride	178.5	Up to 160 mg%
Serum Cholesterol HDL	46.5	Up to 65 mg%
Serum CholesterolLDL	83.6	Up to 125 mg%
VLDL	35.7	Up to 30 mg%
TC/HDL Ratio	3.20	
Glycosylated Hemoglobin HBA1c	5.6	Below - 6.0 % -Non Diabetic control 6-7 % -Excellent control Above- 8 % -Poor control

All test have technical limitation. Collaborative clinic pathological interpretation is mandatory. In case of disparity test may be repeated immediately



Dr. B. M. Agarwal
Pathologist MBBS, DCP
Consultant Pathologist



डॉ. सविता क्लिनिक



34, भूतल, मोहिनी अदिति आर्केड, शाहपुरा मस्जिद के पास
भरत नगर रोड, ई-7/194, अरेरा कॉलोनी, भोपाल - 462038

Mob. : 8989649694, 9516333619

Clinic Registration : CL/5392/Jun/2017

PNDT Registration : MPPCPNDT/BPL/2017/206

Name : Mrs. Nitita Lekhwani Age 32 yrs. / Mo.
R/B Health check-up No. Date 9/5/2022

WHOLE ABDOMES ULTRASOUND REPORT

Indication: Health check-up

Liver appears normal in size and shape with normal outline. Normal/
~~increased~~ perenchymal echogenicity is noted. No E/O focal lesion/ IHBR
dilatation is seen. Hepatic veins and portal veins appear normal.

No E/O subdiaphragmatic Collection.

Gall Bladder is physiologically well distended. No. E/O echogenic foci in GB
lumen. GB wall is normal / ~~thickened~~. No E/O pericholecystic collection.
Common duct reveals normal course and caliber.

Pancreas appear normal in size, shape and echo texture with smooth
contour. No peripancreatic pathology seen. (~~Not seen due to gases~~)

Spleen is normal in size and echo texture.

IVC and aorta appear to be normal.

No evidence of lymphadenopathy is noted.

No evidence of free fluid is noted.

Right Kidney is normal in size. size, shape and position. Corticomedullary
differentiation (CMD) is well maintained. Normal cortical thickness is
noted. No E/O hydronephrosis or calculus is noted.

Small calculus 1.57 cm x 1.57 cm size
noticed in lower 2 renal pole. PTO

Dr. P. Savita, MD

MBBS, MD (O&G) Reg. No. 9971

स्त्री रोग विशेषज्ञ

Dr. Jayant Yadav, MD

MBBS, MD (Radiologist) Reg. No. 4166

रेडियोलॉजिस्ट

Left Kidney is normal in size, shape and position. CMD is well maintained. Normal cortical thickness is noted. No E/O hydronephrosis or calculus is noted. *1.46 cm size small cw. Noted in med pb*

Urinary Bladder is well distended (physiological). its contents are echo free. No E/O bladder wall thickening is noted. ~~Post-void residue is insignificant.~~

Prostate is normal in size. Shape and echo texture with smooth outline. No E/O focal lesion is noted.

Uterus is ante/ retro verted and normal in size, shape and echotexture with smooth outline. No E/O focal lesion is noted. Endometrial echo appear normal. Cervical and vaginal shadows appear normal.

Right Ovary appears enlarged / Normal in size, shape and echo texture.

Left Ovary appears enlarged / Normal in size, shape and echo texture.

Impression : ~~Normal study.~~ *Right Ren cw. 5.7cm*
Left Ren cw. 4.6cm size.

~~Advised clinical Correlation.~~ *Further evaluation*

Dr. P. Savita, MD
MBBS, MD (O&G) Reg. No. 9971
स्त्री रोग विशेषज्ञ

Dr. Jayant Yadav, MD
MBBS, MD (Radiologist) Reg. No. 4166
रेडियोलॉजिस्ट

maintained.
calculus is
noted

