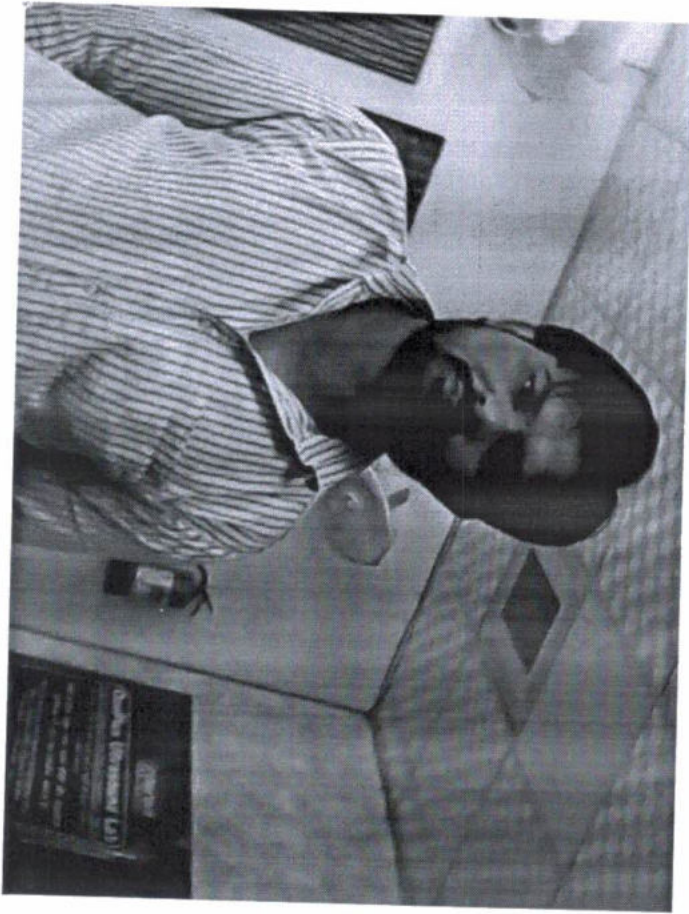

Dr. NITIN AGARWAL
MBBS, MD
Regn. No. DMC-R-1436

Harvi

ONEPLUS ULTRASOUND LAB
47, Harsh Vihar, Pitam Pura,
Delhi-110034
Ph. 011-42480101, 9599913051
E-mail: oneplusul@gmail.com

ONEPLUS ULTRASOUND LAB

47, HARSH VIHAR, PITAMPURA, DELHI- 110034

Mr. RAVI

Age : 29/M

Ref. by : MEDIWHEEL

Indication1 :

Indication2 :

Indication3 :

COMMENTS : Normal ECG.

ID : 2138

HWHT : 178/82

Recorded : 13-3-2023 9:47

Medication1 :

Medication2 :

Medication3 :

BPM : 84

BP : 12/80

P Axis : 69 deg

QRS Axis : 82 deg

T Axis : 35 deg

P duration : 86 msec

PR duration : 123 msec

QRS duration : 100 msec

QT interval : 310 msec

QTc interval : 352 msec

Raw E.C.G.(Seq)

Unconfirmed Report Reviewed By: *[Signature]*

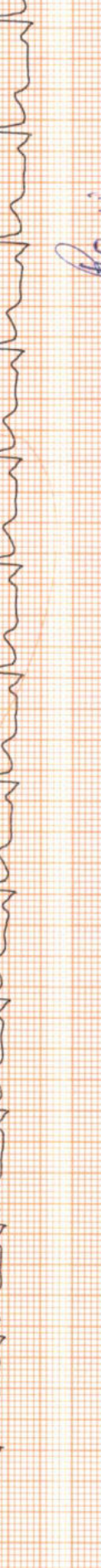
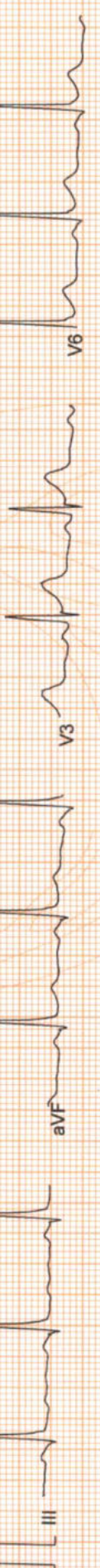
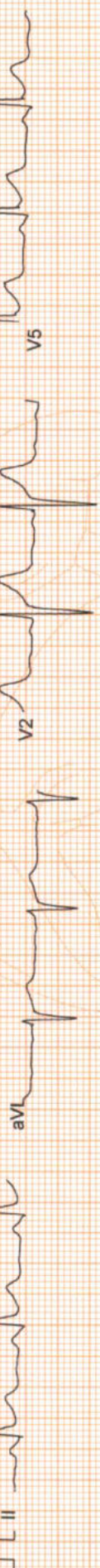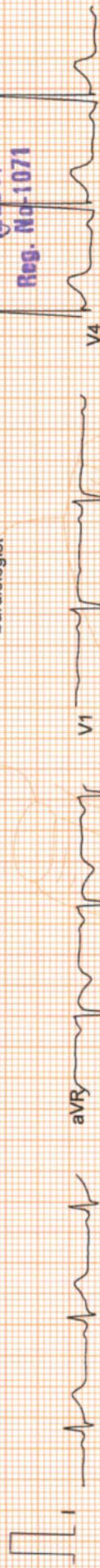Cardiologist

[Signature]

DR. P. A. DEPTA

MBBS, MD

Reg. No-1071



ONEPLUS ULTRASOUND LAB

47, Harsh Vihar, Pitam Pura,

Delhi-110034

Ph. 011-42480101, 9559913051

E-mail: oneplusul@gmail.com

Ravi

Filtered

25mm/sec 10mm/mV

GREEN INDIA

CardiCom, INDIA

ONEPLUS ULTRASOUND LAB

47, HARSH VIHAR PITAMPURA DELHI 110034

Mr. RAVI ID : 989
 Age/Sex : 29/M H/Wt : 178/82
 Ref. by : MEDIWHEEL Recorded : 13-3-2023 9:49
 Indication1 :
 Indication2 :
 Indication3 :
 TREADMILL TEST SUMMARY REPORT
 Protocol: BRUCE
 History:
 Medication1 :
 Medication2 :
 Medication3 :

| PHASE | PHASE TIME | STAGE TIME | SPEED (Km./Hr.) | GRADE (%) | H.R. (BPM) | B.P. (mmHg) | RPP X100 | II | ST LEVEL (mm) V2 | V5 | METS |
|-----------------|------------|------------|-----------------|-----------|------------|------------------|----------|------------|------------------|------------|-------|
| STANDING SUPINE | | | | | 80 81 | 120/80 120/80 | 96 97 | 0.9 0.9 | 2.5 2.5 | 1.3 1.2 | |
| STAGE 1 | 2:59 | 2:59 | 2.70 | 10.00 | 96 | 130/82 | 124 | 0.8 | 2.5 | 1.4 | 4.80 |
| STAGE 2 | 5:59 | 2:59 | 4.00 | 12.00 | 105 | 142/84 | 149 | 0.6 | 2.3 | 1.2 | 7.10 |
| STAGE 3 | 8:59 | 2:59 | 5.40 | 14.00 | 120 | 150/86 | 180 | 0.6 | 2.2 | 1.1 | 10.00 |
| STAGE 4 | 11:59 | 2:59 | 6.70 | 16.00 | 151 | 162/88 | 244 | 0.3 | 3.0 | 1.4 | 14.00 |
| STAGE 5 | 12:29 | 0:29 | 8.00 | 18.00 | 167 | 170/90 | 283 | 0.5 | 2.6 | 1.2 | 14.97 |
| PEAK EXER | 12:30 | 0:30 | | | 167 | 170/90 | 283 | 0.5 | 2.6 | 1.2 | 15.01 |
| RECOVERY | 2:59 | 2:59 | 0.00 | 0.00 | 95 | 126/82 | 119 | 0.5 | 1.9 | 0.9 | |

RESULTS

Exercise Duration : 12.30 Minutes
 Max Heart Rate : 167 bpm 87 % of target heart rate 191 bpm
 Max Blood Pressure : 170/90 mmHg
 Max Work Load : 15.01 METS
 Reason of Termination :

IMPRESSIONS : *Negative for ischemia*

Dr. P.K. GUPTA
 MBBS, MD
 Reg. No-1071
 Cardiology

ONEPLUS ULTRASOUND LAB
 47, Harsh Vihar Pitam Pura,
 Delhi-110034
 Ph. 011-47480101, 9559913051
 E-mail: oneplusul@gmail.com

Ravi

ONEPLUS ULTRASOUND LAB

STANDING
PRETEST

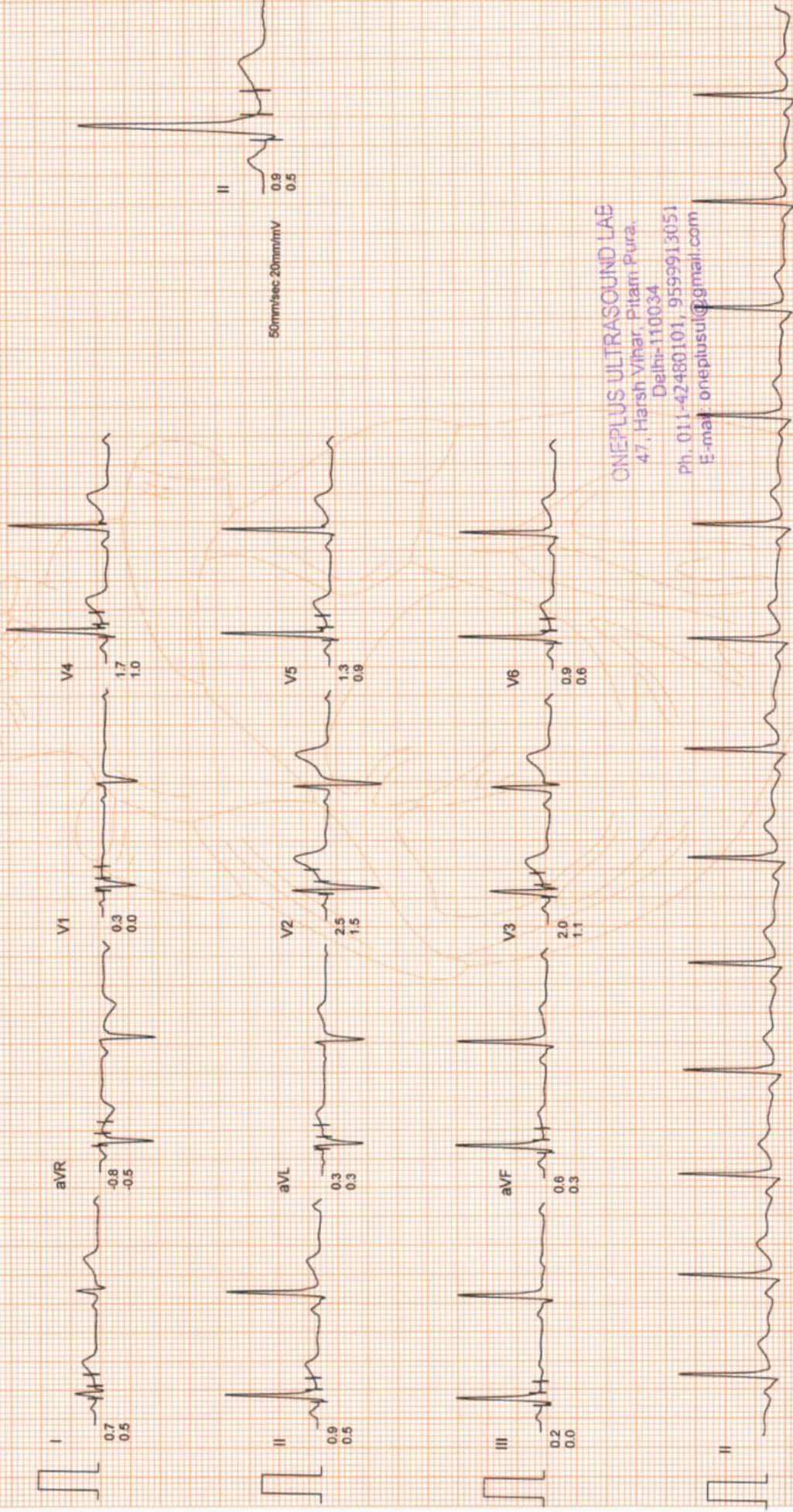
ST @ 10mm/mV
80ms PostJ

Mr. RAVI
I.D. : 989
AGE/SEX : 29/M
RECORDED : 13-3-2023 9:49

RATE : 80 BPM

B.P. : 120/80 mmHg

LINKED MEDIAN



50mm/sec 20mm/mV

ONEPLUS ULTRASOUND LAB
47, Harsh Vihar, Pitam Pura,
Delhi-110034
Ph. 011-42480101, 9599913051
E-mail: oneplusul@gmail.com

Filtered

Computer Corrected Baseline

25mm/sec 10mm/mV

GREEN INDIA

CardiCom, INDIA Ph: 091-731-2620740, TeleFax: 091-731-2431214

ONEPLUS ULTRASOUND LAB

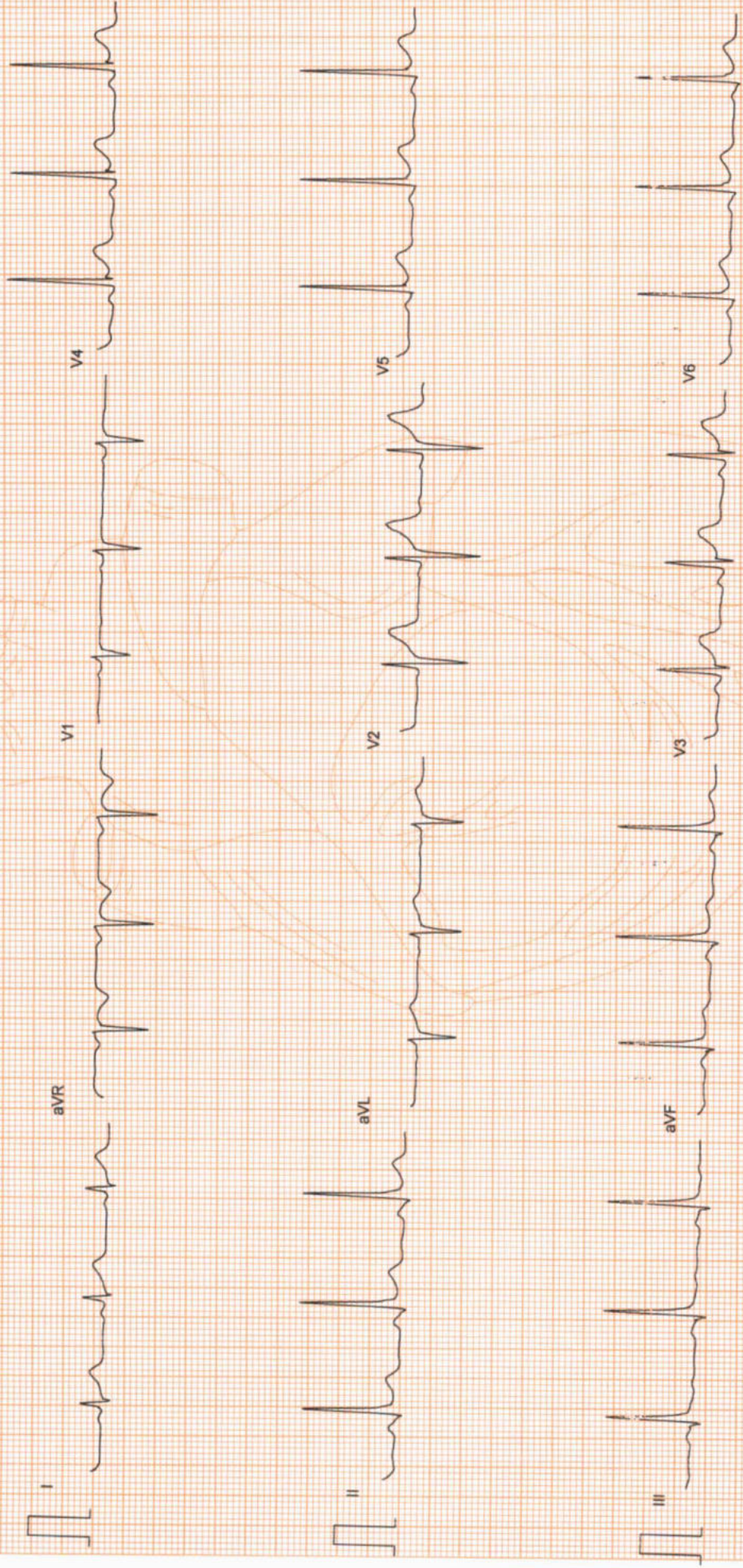
Mr. RAVI
I.D. : 989
AGE/SEX : 29/M
RECORDED : 13-3-2023 9:49

SUPINE
PRETEST

ST @ 10mm/mV
80ms PostJ

RATE : 81 BPM
B.P. : 120/80 mmHg

RAW E.C.G.



ONEPLUS ULTRASOUND LAB
47, Harsh Vihar, Pitam Pura,
Delhi-110034
Ph. 011-42480101, 9599913051
E-mail: oneplusul@gmail.com

Filtered

25mm/sec 10mm/mV

GREEN INDIA

CardiCom, INDIA Ph..091-731-2620740, Telefax:091-731-2431214

ONEPLUS ULTRASOUND LAB

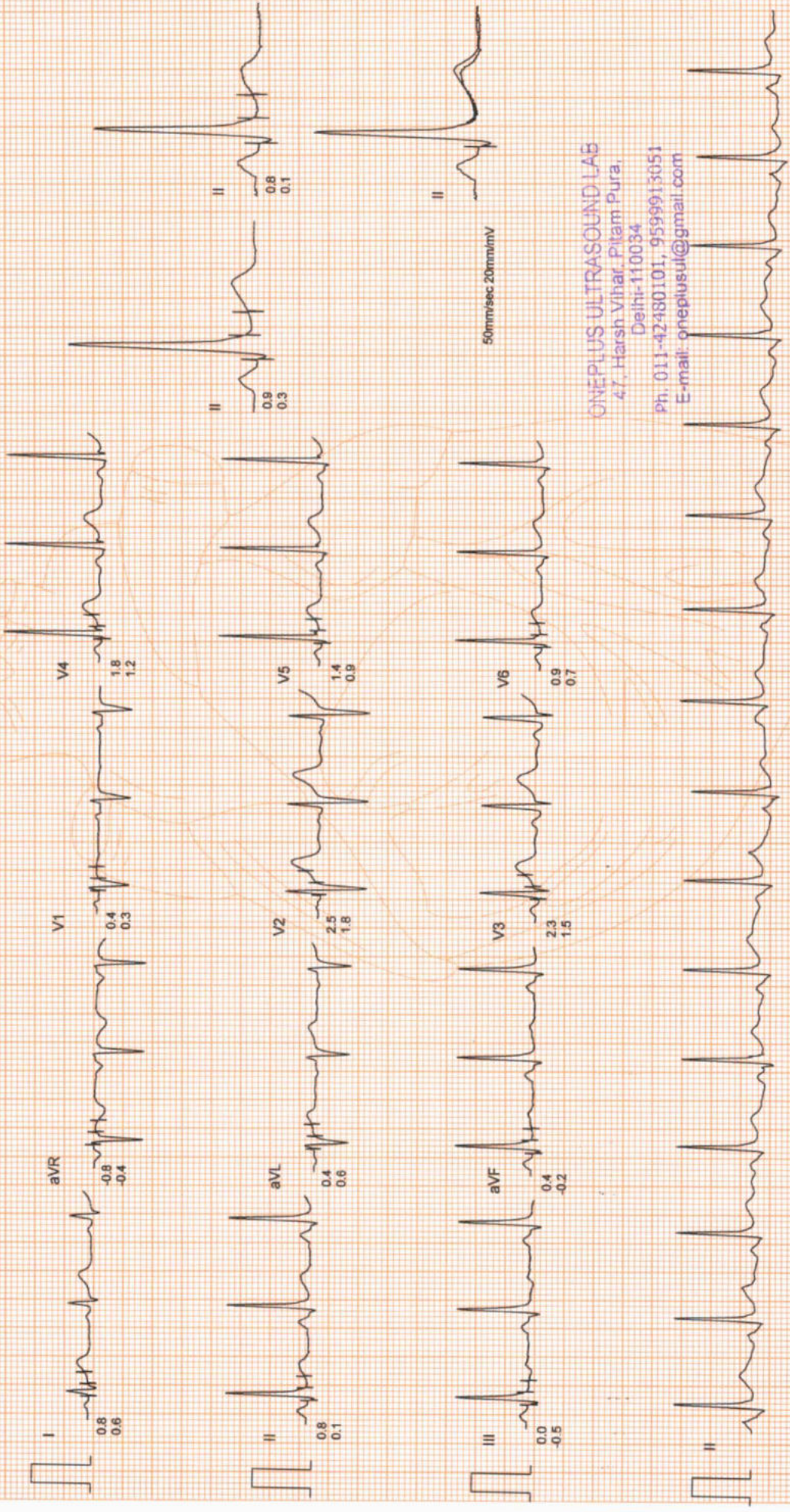
Mr. RAVI
I.D. : 989
AGE/SEX : 29/M
RECORDED : 13-3-2023 9:49

RATE : 96 BPM
B.P. : 130/82 mmHg

BRUCE
EXERCISE 1
PHASE TIME : 2:59
STAGE TIME : 2:59

ST @ 10mm/mV
80ms PostJ
SPEED : 2.7 Km./Hr.
GRADE : 10.0 %

LINKED MEDIAN



ONEPLUS ULTRASOUND LAB
47, Harsh Vihar, Pitam Pura,
Delhi-110034
Ph. 011-42480101, 9599913051
E-mail: oneplusul@gmail.com

Filtered

Computer Corrected Baseline

25mm/sec 10mm/mV

50mm/sec 20mm/mV

GREEN INDIA
CardiCom, INDIA Ph.-091-731-2620740, TeleFax:091-731-2431214

ONEPLUS ULTRASOUND LAB

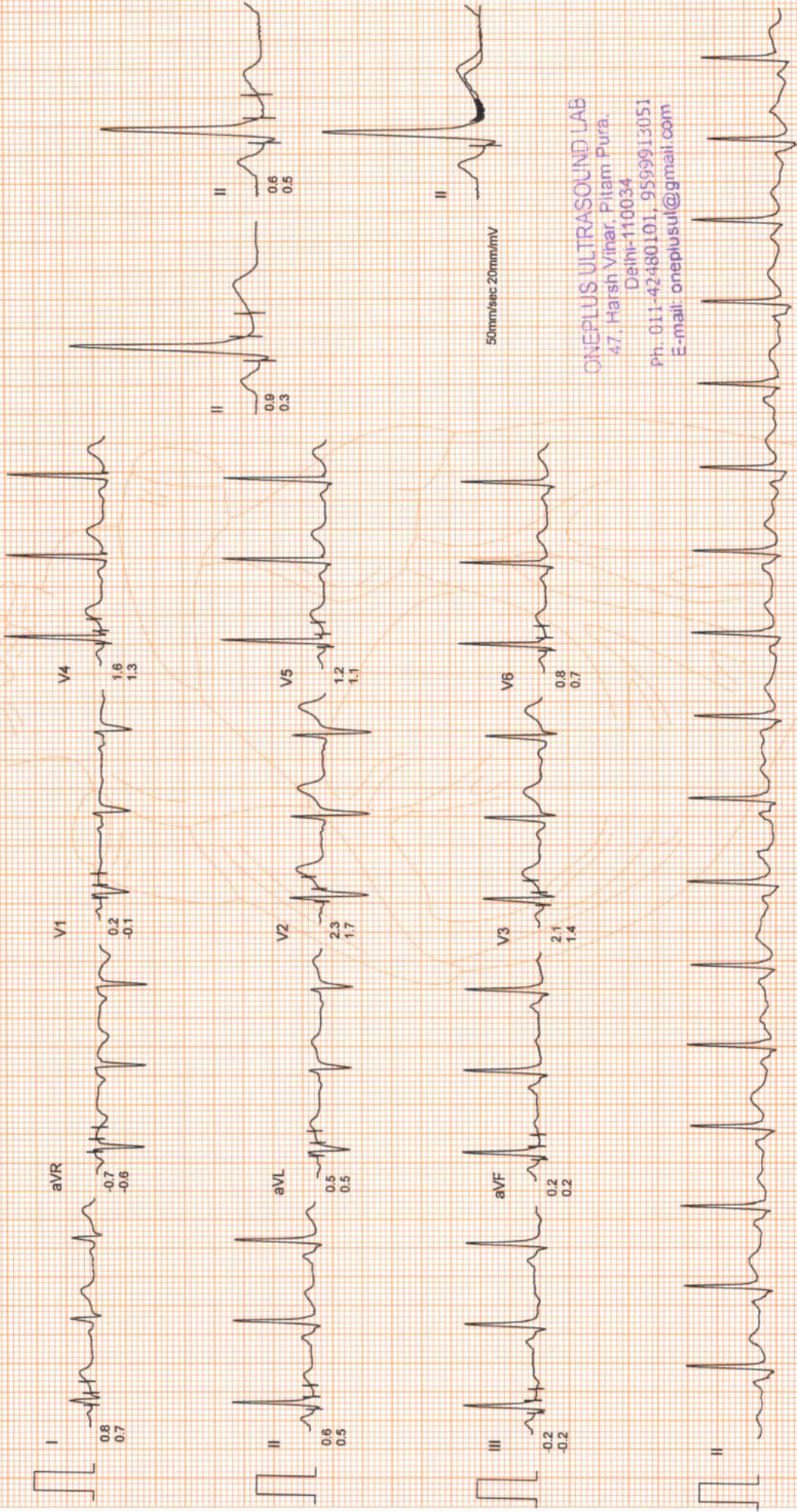
Mr. RAVI
I.D. : 989
AGE/SEX : 29/M
RECORDED : 13- 3-2023 9:49

RATE : 105 BPM
B.P. : 142/84 mmHg

BRUCE
EXERCISE 2
PHASE TIME : 5:59
STAGE TIME : 2:59

ST @ 10mm/mV
80ms PostJ
SPEED : 4.0 Km./Hr.
GRADE : 12.0 %

LINKED MEDIAN



50mm/sec 20mm/mV

ONEPLUS ULTRASOUND LAB
47, Harsh Vihar, Pitam Pura,
Delhi-110034
Ph. 011-42480101, 9599913051
E-mail: oneplusul@gmail.com

ONEPLUS ULTRASOUND LAB

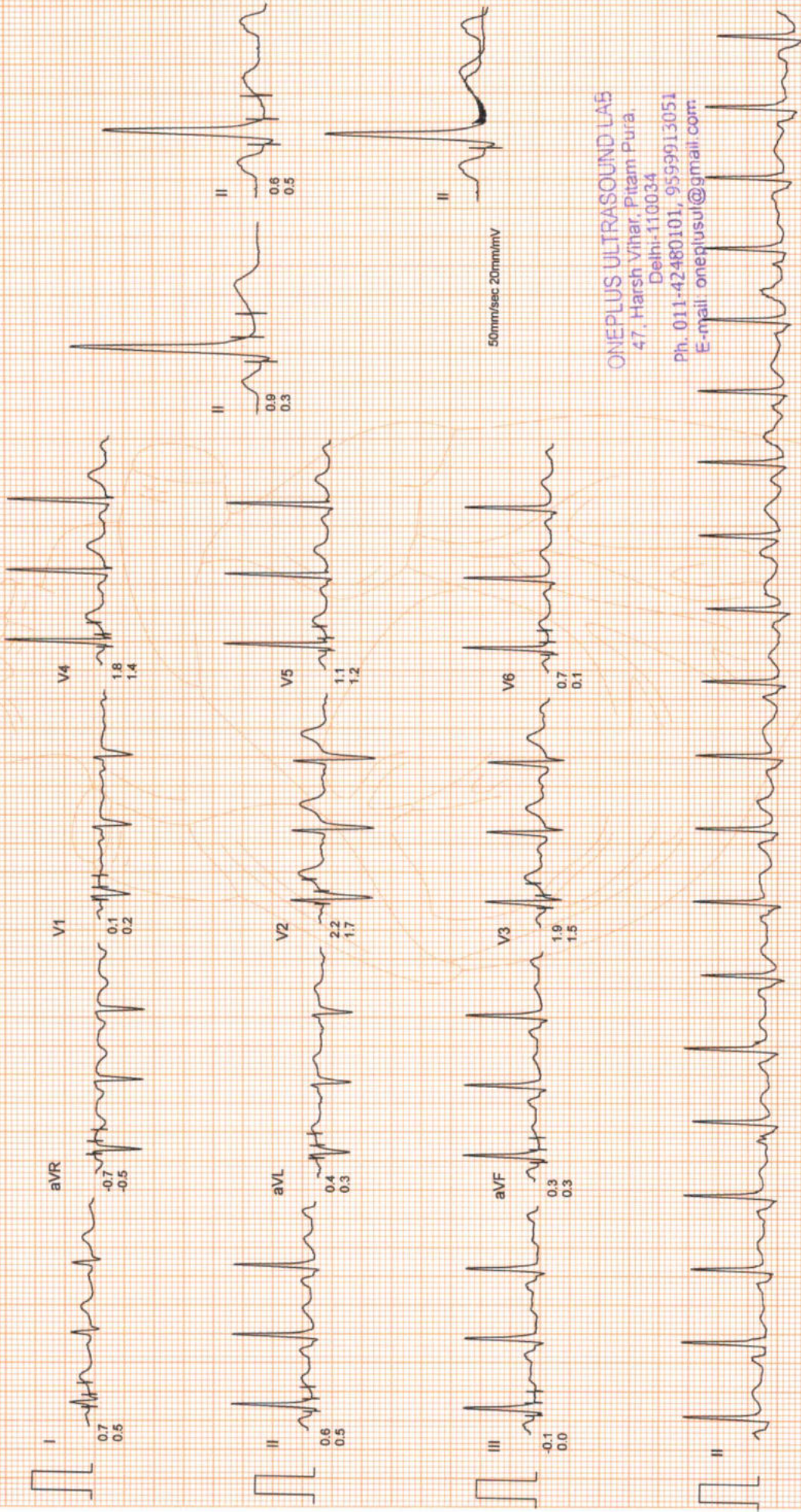
Mr. RAVI
 I.D. : 989
 AGE/SEX : 29/M
 RECORDED : 13- 3-2023 9:49

RATE : 120 BPM
 B.P. : 150/86 mmHg

BRUCE
 EXERCISE 3
 PHASE TIME : 8:59
 STAGE TIME : 2:59

ST @ 10mm/mV
 80ms PostJ
 SPEED : 5.4 Km/Hr.
 GRADE : 14.0 %

LINKED MEDIAN



50mm/sec 20mm/mV

ONEPLUS ULTRASOUND LAB
 47, Harsh Vihar, Pitam Pura,
 Delhi-110034
 Ph. 011-42480101, 9599913051
 E-mail: oneplusul@gmail.com

Filtered

Computer Corrected Baseline

25mm/sec 10mm/mV

GREEN INDIA

CardiCorr, INDIA Ph.:091-731-2620740, TeleFax:091-731-2431214

ONEPLUS ULTRASOUND LAB

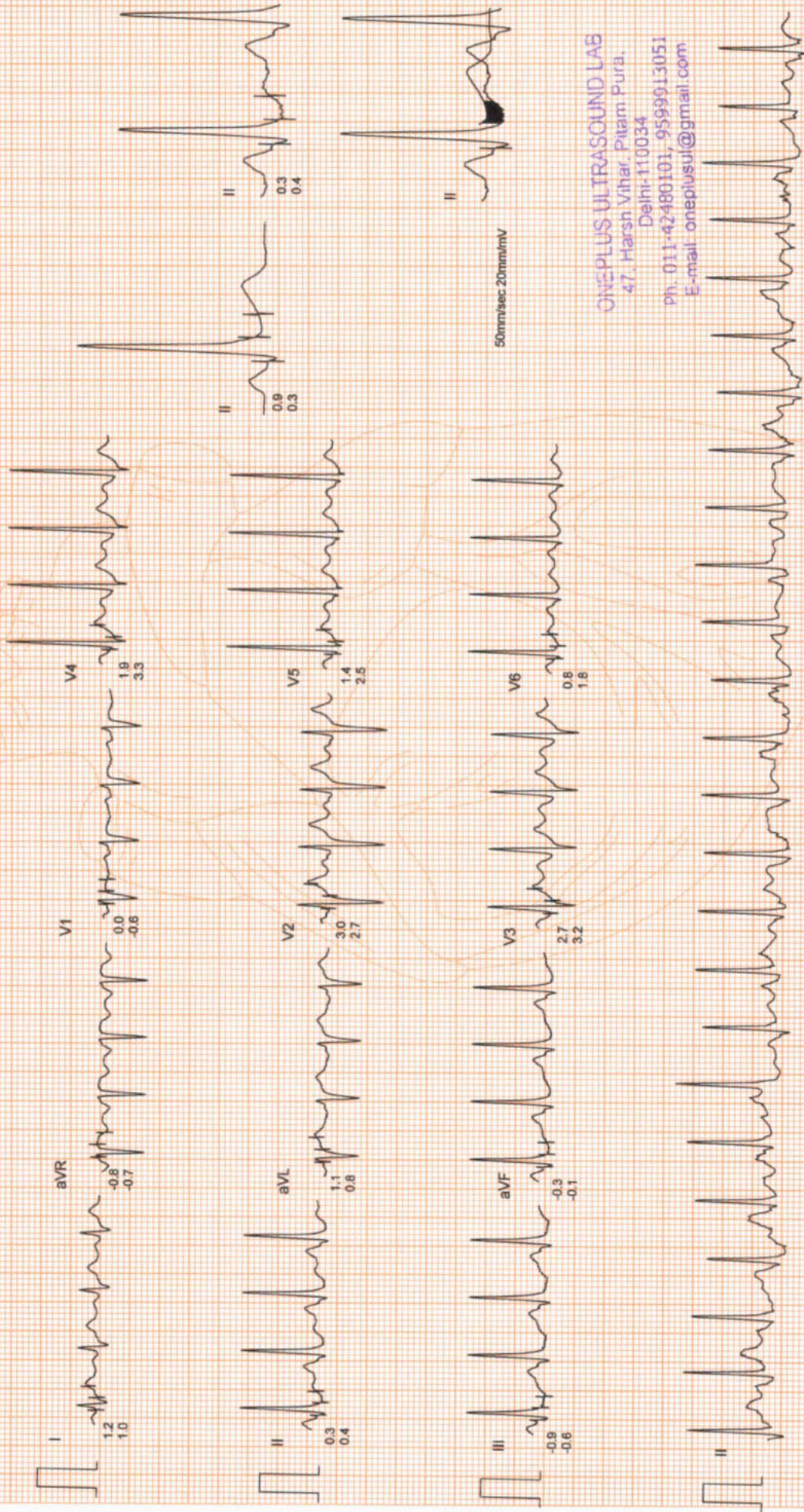
Mr. RAVI
I.D. : 989
AGE/SEX : 29/M
RECORDED : 13- 3-2023 9:49

BRUCE
EXERCISE 4
PHASE TIME : 11:59
STAGE TIME : 2:59

RATE : 151 BPM
B.P. : 162/88 mmHg

ST @ 10mm/mV
80ms PostJ
SPEED : 6.7 Km./Hr.
GRADE : 16.0 %

LINKED MEDIAN



50mm/sec 20mm/mV

ONEPLUS ULTRASOUND LAB
47, Harsh Vihar, Pitam Pura,
Delhi-110034
Ph. 011-42480101, 9599913051
E-mail: oneplusul@gmail.com

Filtered

Computer Corrected Baseline

25mm/sec 10mm/mV

ONEPLUS ULTRASOUND LAB

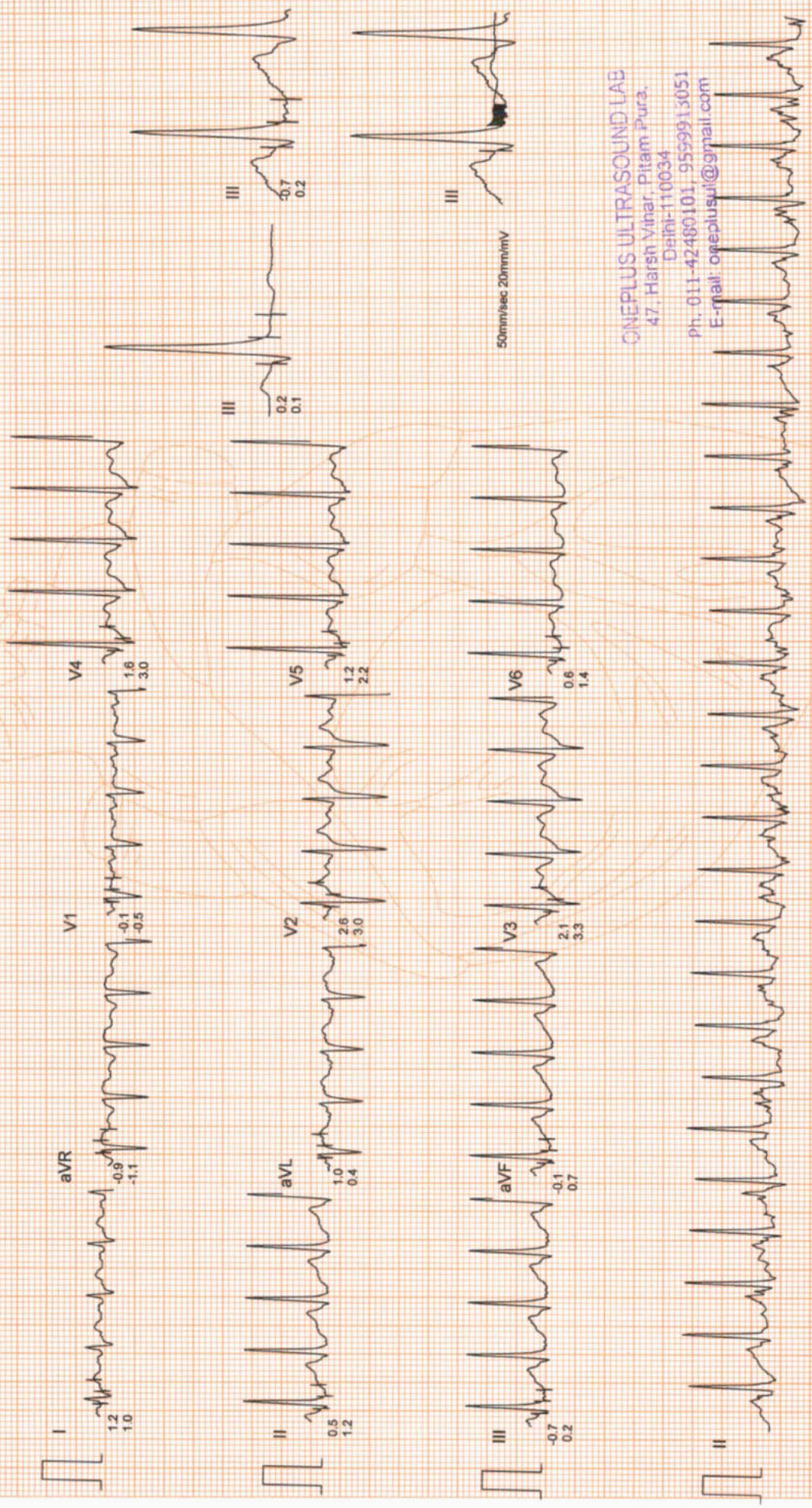
Mr. RAVI
I.D. : 989
AGE/SEX : 29/M
RECORDED : 13- 3-2023 9:49

RATE : 167 BPM
B.P. : 170/90 mmHg

BRUCE
EXERCISE 5
PHASE TIME : 12:29
STAGE TIME : 0:29

ST @ 10mm/mV
80ms PostJ
SPEED : 8.0 Km/Hr.
GRADE : 18.0 %

LINKED MEDIAN



ONEPLUS ULTRASOUND LAB
47, Harsh Vihar, Pitam Pura,
Delhi-110034
Ph. 011-42480101, 9599913051
E-mail: oneplusul@gmail.com

Filtered

Computer Corrected Baseline

25mm/sec 10mm/mV

CardiCom, INDIA Ph.: 091-731-2620740, TeleFax: 091-731-2431214

GREEN INDIA

ONEPLUS ULTRASOUND LAB

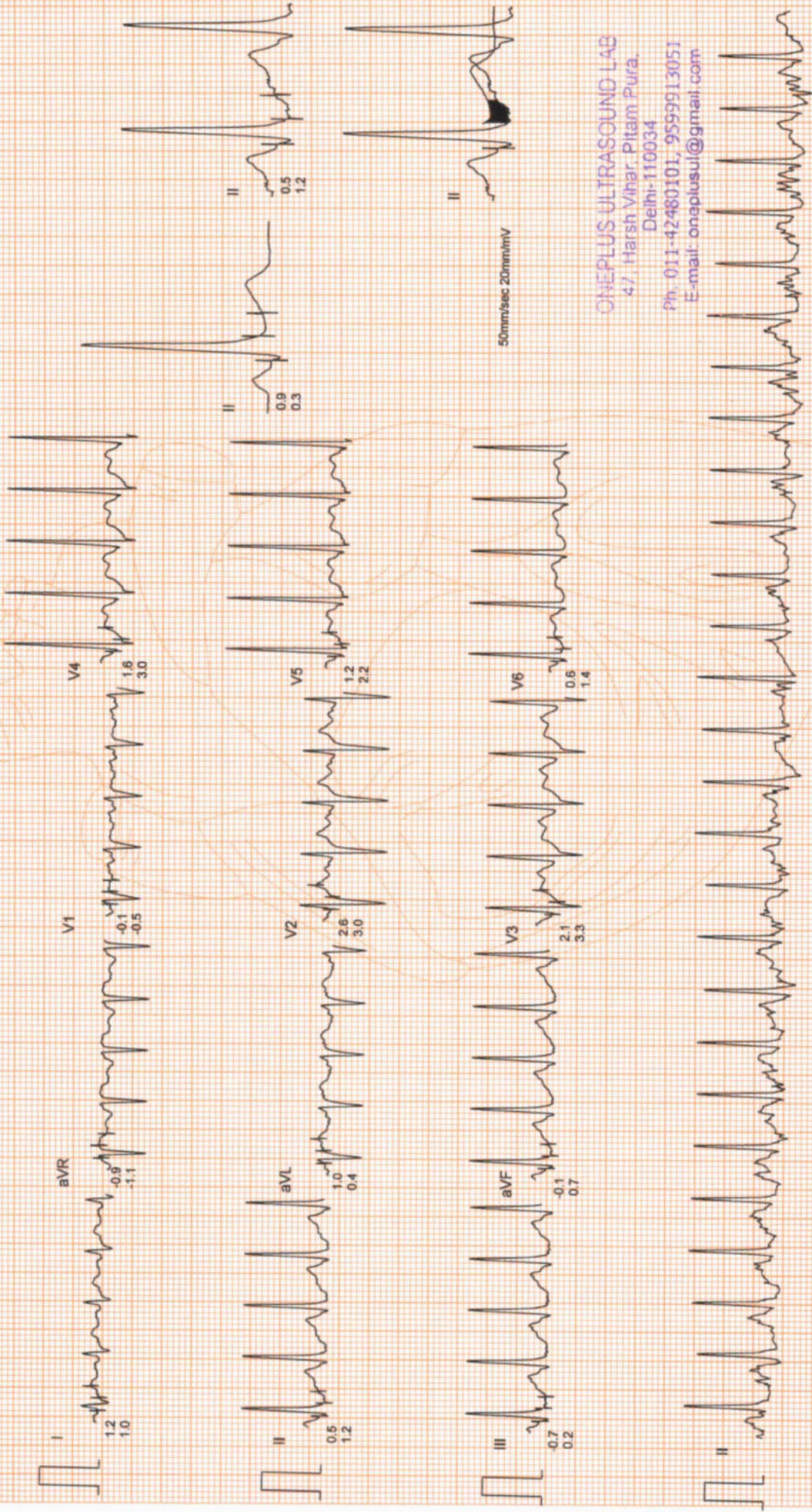
Mr. RAVI
I.D. : 989
AGE/SEX : 29/M
RECORDED : 13-3-2023 9:49

RATE : 167 BPM
B.P. : 170/90 mmHg

BRUCE
PEAK EXER
PHASE TIME : 12:30
STAGE TIME : 0:30

ST @ 10mm/mV
80ms PostJ
SPEED : 8.0 Km./Hr.
GRADE : 18.0 %

LINKED MEDIAN



ONEPLUS ULTRASOUND LAB
47, Harsh Vihar, Pitam Pura,
Delhi-110034
Ph: 011-42480101, 9599913051
E-mail: onepusul@gmail.com

ONEPLUS ULTRASOUND LAB

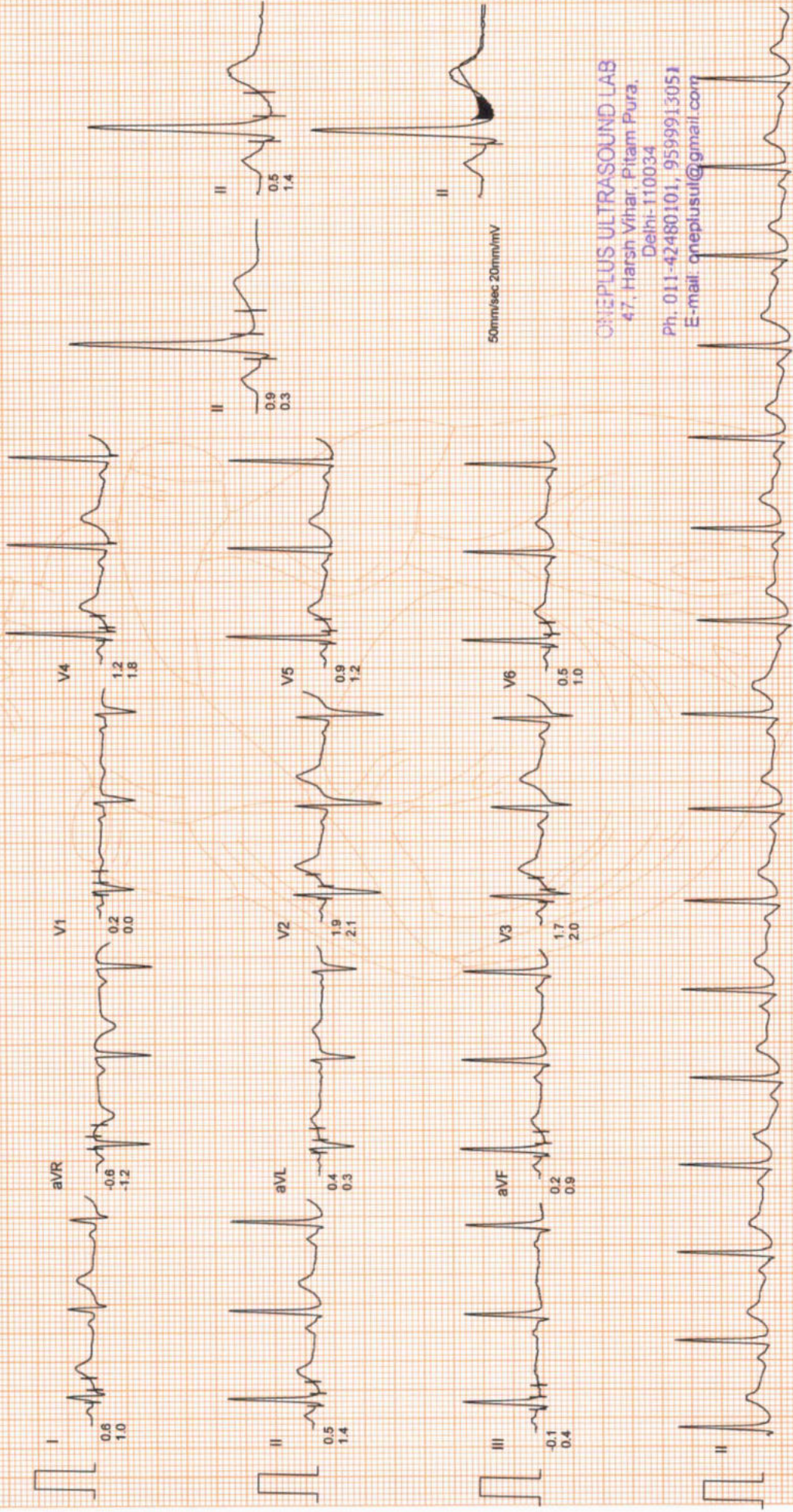
Mr. RAVI
I.D. : 989
AGE/SEX : 29/M
RECORDED : 13-3-2023 9:49

BRUCE
RECOVERY
PHASE TIME : 2:59

RATE : 95 BPM
B.P. : 126/82 mmHg

ST @ 10mm/mV
80ms PostJ
SPEED : 0.0 Km./Hr.
GRADE : 0.0 %

LINKED MEDIAN



ONEPLUS ULTRASOUND LAB
47, Harsh Vihar, Pitam Pura,
Delhi-110034
Ph. 011-42480101, 9599913051
E-mail: oneplusul@gmail.com

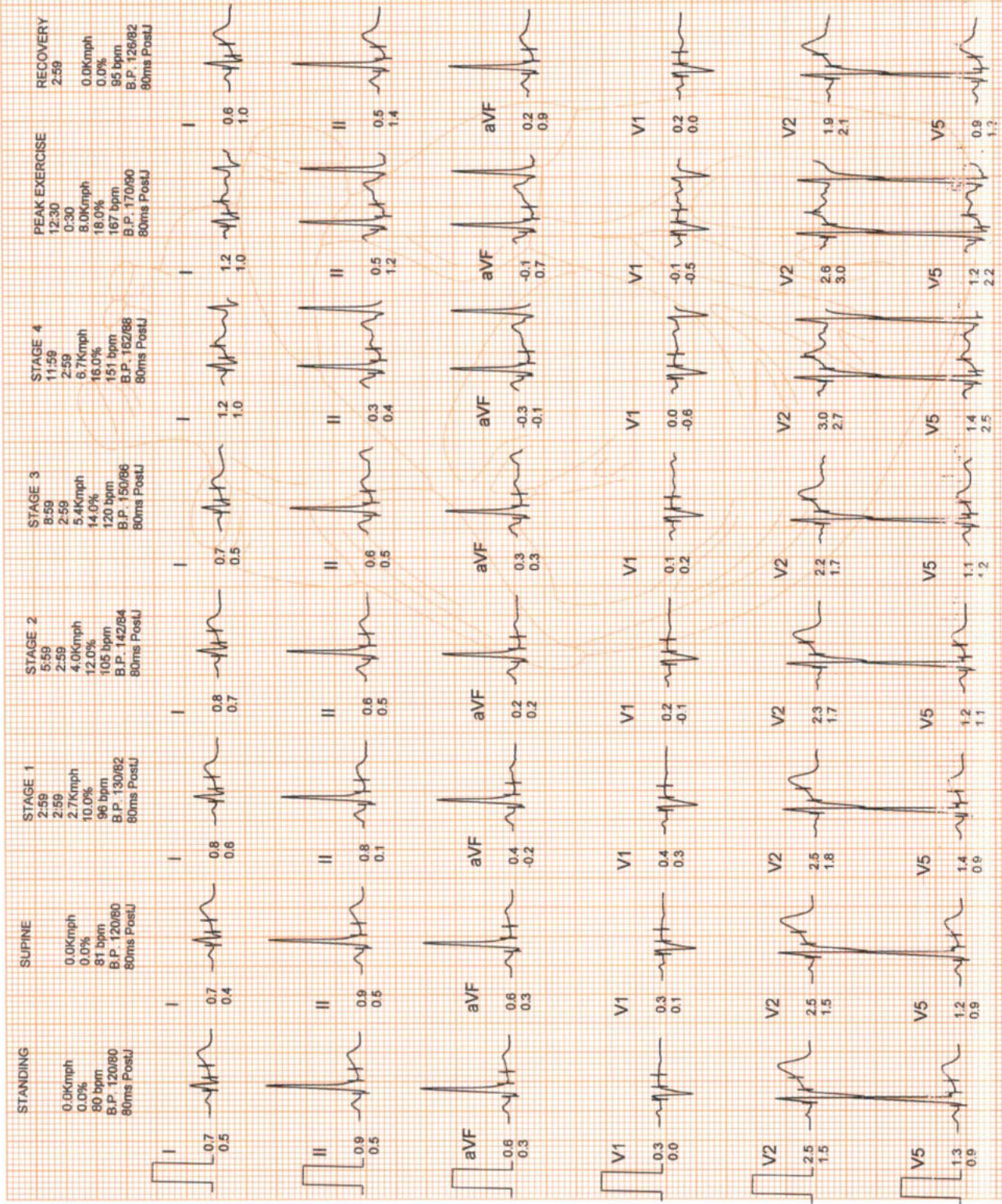
ONEPLUS ULTRASOUND LAB

I.D. : 989

AGE/SEX : 29/M

RECORDED : 13-3-2023 9:49

AVG E.C.G.



ONEPLUS ULTRASOUND LAB
 47, Harsh Vihar, Pitam Pura,
 Delhi-110034
 Ph. 011-42480101, 9599913051
 E-mail: oneplusul@gmail.com

ONEPLUS ULTRASOUND LAB

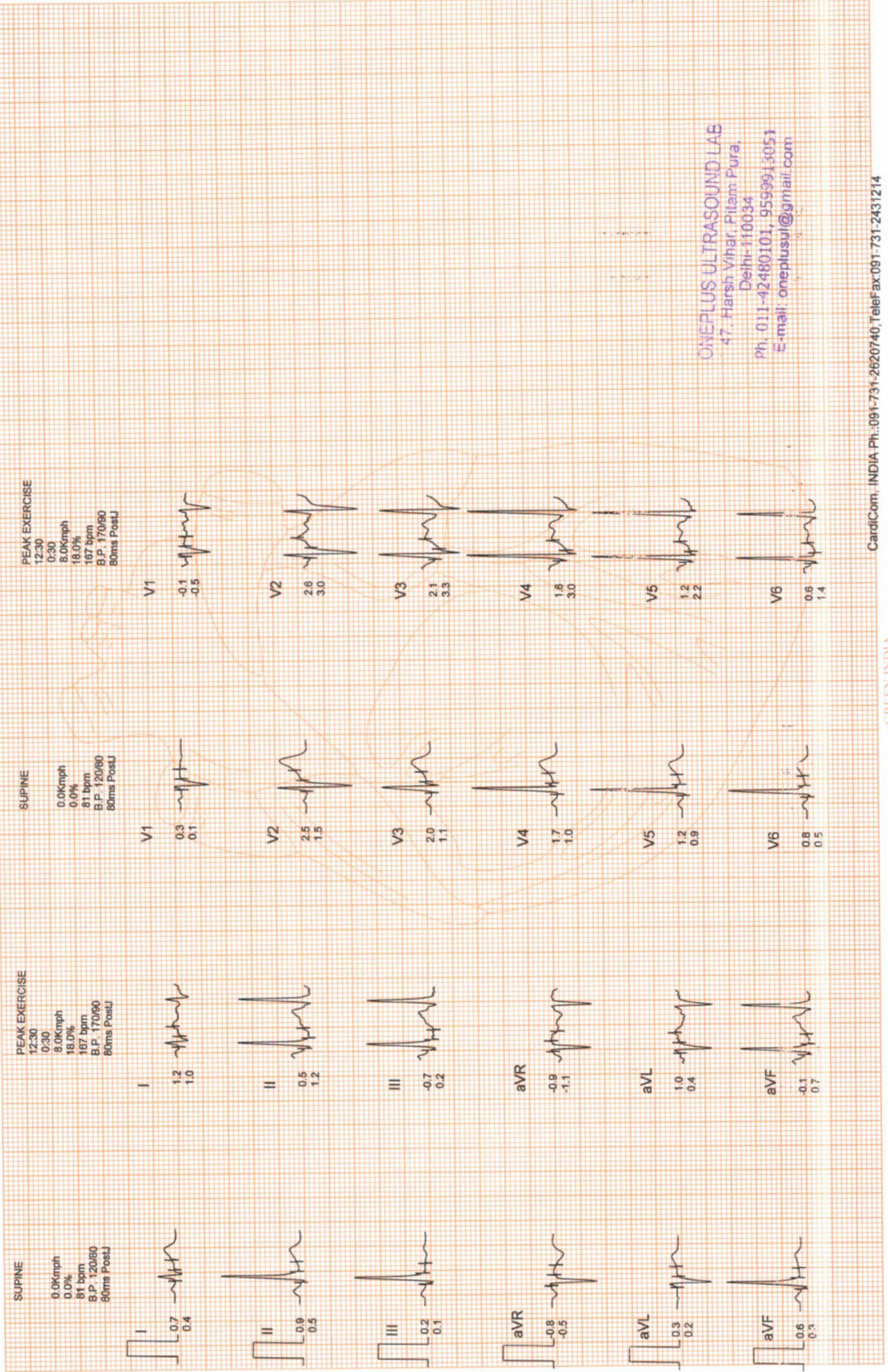
Mr. RAVI

I.D. : 989

AGE/SEX : 29/M

RECORDED : 13-3-2023 9:49

COMPARISON REPORT



ONEPLUS ULTRASOUND LAB
 47, Harsh Vihar, Pitam Pura,
 Delhi-110034
 Ph. 011-42480101, 9599913051
 E-mail: oneplusul@gmail.com

| | | | |
|----------------|-----------------|-------------------|----------------|
| Name | : Mr. RAVI | Age/Sex | : 29 YRS/Male |
| Ref. By | : Dr. MEDIWHEEL | Lab No | : 012303130004 |
| Date | : 13-Mar-2023 | Patient ID | : LSHHI110587 |

ULTRASOUND EXAMINATION----WHOLE ABDOMEN

Liver is mildly enlarged in size (15.9 cm) and normal in outline with altered echopattern. Diffuse increase in echogenicity of liver parenchyma is noted, suggestive of fatty infiltration (grade II). No abscess or mass lesion seen. Hepatic veins, portal vein, IVC and aorta are normal. Intrahepatic biliary radicles are not dilated. CBD is normal in caliber.

Gall bladder is well distended with anechoic lumen. Wall thickness is normal.

Both kidneys are normal in size, shape, position, outline and echopattern. Corticomedullary differentiation is maintained. No pelvicalyceal dilation or calculus or mass lesion is seen.

Spleen is normal in size and echotexture. No mass lesion seen.

Pancreas is normal in size, outline and echotexture.

Urinary bladder is normal in shape and position. No evidence of intravesical stone or mass seen.

Prostate is normal in size, shape and echopattern.

Prostate measures 3.2 x 3.0 x 2.6 cm. **Weight of prostate is 13.5 grams.**

No abnormal bowel wall thickening seen in right iliac fossa.

No free fluid seen anywhere in abdomen.

IMPRESSION: Fatty infiltration of liver (grade II) with mild hepatomegaly.

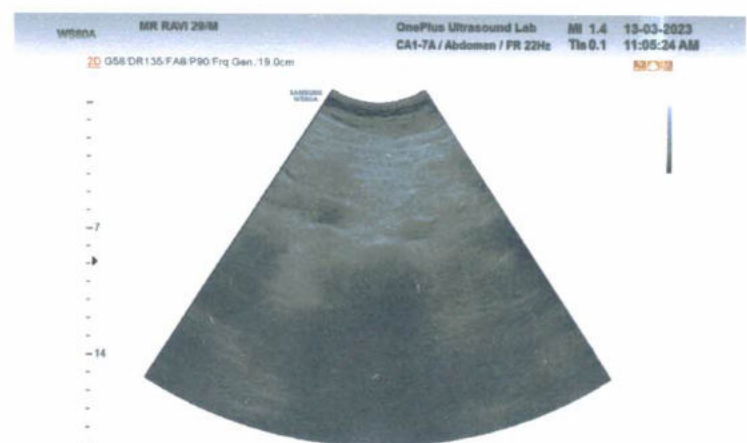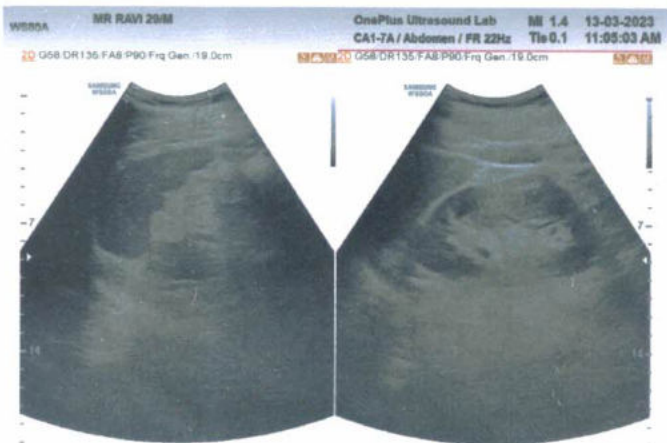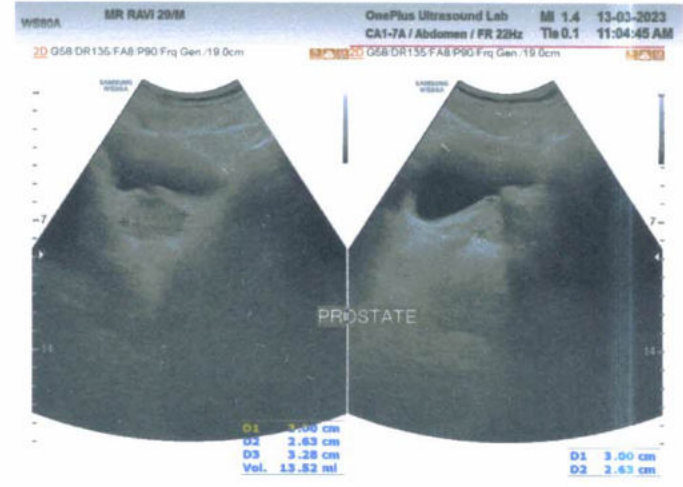
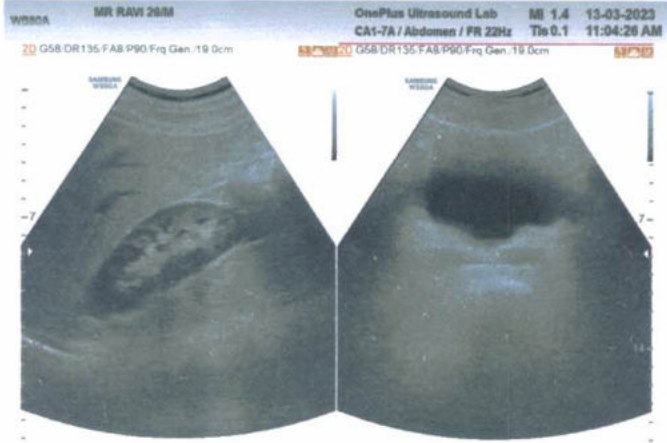
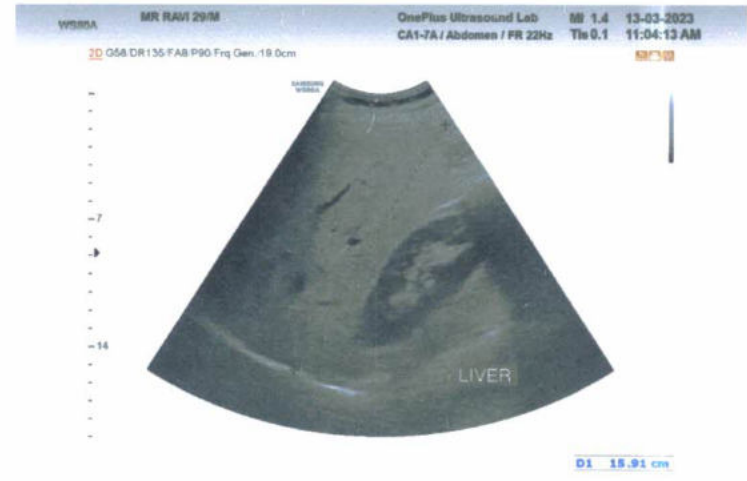
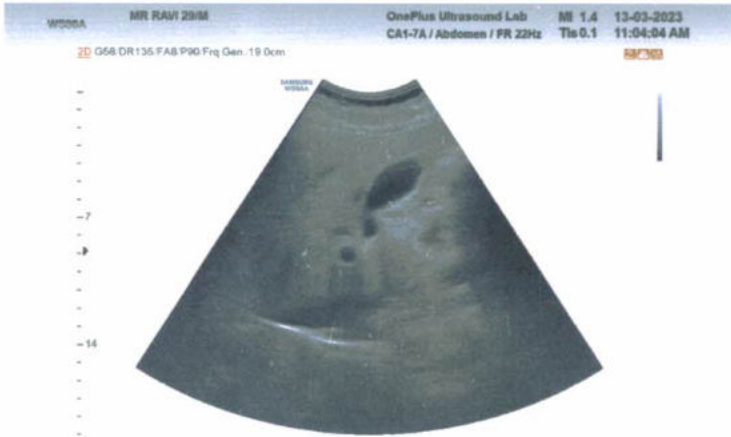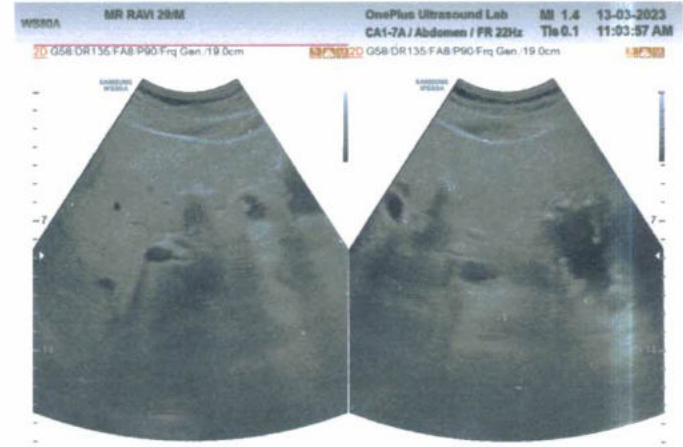
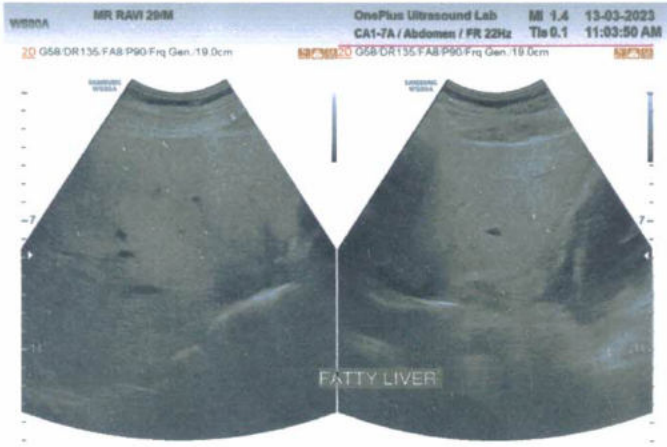
Dr. POOJA GARG
M.B.B.S., D.M.R.D.
Reg No. DMC/R/03398
Radiologist



Type By : darshita

47, Harsh Vihar, Pitampura, New Delhi-110034 | Ph.: 011-42480101, 9599913051

E-mail: oneplusul@gmail.com | Web.: www.oneplusul.in





OnePLUS Ultrasound Lab

— QUALITY FIRST... ALWAYS! —

Dr. Nitin Agarwal
Pathologist & Director
Ex. Sr. Res. MAMC
& Lok Nayak Hospital
Ex. Chief of Lab Dr. Lal Path Labs.

Dr. Pooja (Garg) Agarwal
Radiologist & Director
MAMC & Lok Nayak Hospital



| | | | |
|-------------|-------------------------|-------------------|----------------------|
| NAME | :Mr. RAVI | Barcode No | :10139839 |
| AGE/GENDER | :29 YRS/Male | SPECIMEN DATE | :13/Mar/2023 09:08AM |
| PATIENT ID | :110587 | SPECIMEN RECEIVED | :13/Mar/2023 09:21AM |
| REFERRED BY | :Dr. MEDIWHEEL | REPORT DATE | :13/Mar/2023 04:37PM |
| CENTRE NAME | :ONEPLUS ULTRASOUND LAB | LAB NO. | :012303130004 |

| Test Name | Result | Unit | Ref. Range |
|-----------|--------|------|------------|
|-----------|--------|------|------------|

HAEMATOLOGY

Medi Wheel Health checkup < 40 Male

| | | | |
|--|-----|---|--|
| Glycosylated Hemoglobin (HbA1c) | 5.5 | % | Non Diabetic adults <5.7 Prediabetic (at risk) 5.7-6.4 Diabetes >6.4 |
|--|-----|---|--|

Estimated average blood glucose (eag) 111

Reference range (mg/dl):

90 - 120:Excellent control, 121 - 150:Good Control, 151 - 180:Average Control, 181 - 210:Action Suggested

>211:Panic value

Checked By.

Dr. NITIN AGARWAL
M B B S , MD (Pathology) DR. NITIN AGARWAL
DMC/R/01436 MBBS,MD(PATHOLOGIST)

47, Harsh Vihar, Pitampura, New Delhi-110034 | Ph.: 011-42480101, 9599913051

E-mail: oneplusul@gmail.com | Web.: www.oneplusul.in

Page 1 of 7



OnePLUS Ultrasound Lab

— QUALITY FIRST... ALWAYS! —

Dr. Nitin Agarwal
Pathologist & Director
Ex. Sr. Res. MAMC
& Lok Nayak Hospital
Ex. Chief of Lab Dr. Lal Path Labs.

Dr. Pooja (Garg) Agarwal
Radiologist & Director
MAMC & Lok Nayak Hospital



| | | | |
|-------------|-------------------------|-------------------|----------------------|
| NAME | :Mr. RAVI | Barcode No | :10139839 |
| AGE/GENDER | :29 YRS/Male | SPECIMEN DATE | :13/Mar/2023 09:08AM |
| PATIENT ID | :110587 | SPECIMEN RECEIVED | :13/Mar/2023 09:21AM |
| REFERRED BY | :Dr. MEDIWHEEL | REPORT DATE | :13/Mar/2023 11:33AM |
| CENTRE NAME | :ONEPLUS ULTRASOUND LAB | LAB NO. | :012303130004 |

| Test Name | Result | Unit | Ref. Range |
|-----------|--------|------|------------|
|-----------|--------|------|------------|

HAEMATOLOGY

BLOOD GROUP (ABO) O
Rh typing POSITIVE


NOTE :

- * Apart from major A,B,H antigens which are used for ABO grouping and Rh typing, many minor blood group antigens exist. Agglutination may also vary according to titre of antigen and antibody.
- * So before transfusion, reconfirmation of blood group as well as cross-matching is needed.
- * Presence of maternal antibodies in newborns, may interfere with blood grouping.
- * Auto agglutination (due to cold antibody, falciparum malaria, sepsis, internal malignancy etc.) may also cause erroneous result.

CBC

| | | | |
|-------------------------------------|--------|--------------|---------------|
| Haemoglobin | 15.1 | g/dl | 13.0-17.0 |
| Total Leucocyte Count | 7500 | /cumm | 4000-10000 |
| Differential leucocyte count | | | |
| Neutrophils | 63.1 | % | 40-80 |
| Lymphocyte | 29.10 | % | 20-40 |
| Monocytes | 5.80 | % | 2-10 |
| Eosinophils | 1.4 | % | 1-6 |
| Basophils | 0.6 | % | 0-2 |
| RBC Count | 4.90 | million/cumm | 4.5 - 5.5 |
| PCV(Hematocrit) | 47.5 | % | 40-50 |
| MCV | 97.3 | fL | 83-101 |
| MCH | 31.0 | Pg | 27-32 |
| MCHC | 31.8 | G/dL | 32-35 |
| Platelet count | 333000 | /cumm | 150000-450000 |
| RDW-CV | 13.4 | % | 11.4-14.0 |
| ESR(WESTGRENs METHOD) | 15 | mm in 1st hr | 0-20 |

Checked By.


Dr. NITIN AGARWAL
M B B S , MD (Path)
DMC/R/01436
MBBS,MD(PATHOLOGIST)

47, Harsh Vihar, Pitampura, New Delhi-110034 | Ph.: 011-42480101, 9599913051

E-mail: oneplusul@gmail.com | Web.: www.oneplusul.in

Page 2 of 7



OnePLUS Ultrasound Lab

— QUALITY FIRST... ALWAYS! —

Dr. Nitin Agarwal

Pathologist & Director
Ex. Sr. Res. MAMC
& Lok Nayak Hospital
Ex. Chief of Lab Dr. Lal Path Labs.

Dr. Pooja (Garg) Agarwal

Radiologist & Director
MAMC & Lok Nayak Hospital



| | | | |
|-------------|-------------------------|-------------------|----------------------|
| NAME | :Mr. RAVI | Barcode No | :10139839 |
| AGE/GENDER | :29 YRS/Male | SPECIMEN DATE | :13/Mar/2023 09:08AM |
| PATIENT ID | :110587 | SPECIMEN RECEIVED | :13/Mar/2023 09:21AM |
| REFERRED BY | :Dr. MEDIWHEEL | REPORT DATE | :13/Mar/2023 04:37PM |
| CENTRE NAME | :ONEPLUS ULTRASOUND LAB | LAB NO. | :012303130004 |

| Test Name | Result | Unit | Ref. Range |
|-----------|--------|------|------------|
|-----------|--------|------|------------|

BIOCHEMISTRY

| | | | |
|-----------------------------------|-------|-------|------------|
| <u>Blood sugar fasting</u> | 82 | mg/dL | 70-110 |
| <u>Blood sugar pp</u> | 135 | mg/dL | 70.0-140.0 |
| <u>Bun (blood urea nitrogen)</u> | 11.50 | mg/dl | 8.9-21.6 |
| <u>Uric acid, serum</u> | 4.6 | mg/dl | 3.5-7.2 |
| <u>Creatinine, serum</u> | 0.60 | mg/dl | 0.60-1.2 |

LFT(LIVER FUNCTION TEST)

| | | | |
|-------------------------------|------|-------|-------------|
| Bilirubin Total | 0.58 | mg/dl | 0.1-1.2 |
| Bilirubin Conjugated | 0.28 | mg/dl | 0-0.4 |
| Bilirubin Unconjugated | 0.30 | mg/dl | up to 0.7 |
| SGOT (AST) | 25 | U/L | 0-46 |
| SGPT (ALT) | 40 | U/L | 0-49 |
| Alkaline phosphatase | 102 | U/L | 40-129 |
| Gamma glutamyl transpeptidase | 26 | U/L | 10-45 |
| Total Protein | 7.4 | gm/dl | 6.60 - 8.70 |
| Albumin serum | 4.2 | g/dL | 3.0-5.2 |
| Globulin | 3.20 | gm/dl | 1.8-3.4 |
| Albumin/Globulin Ratio | 1.31 | | 1.10 - 2.50 |

LIPID PROFILE

| | | | |
|-----------------------|------|-------|--|
| Cholesterol | 210 | mg/dl | 50-200 |
| Triglycerides | 112 | mg/dL | 25-150 |
| HDL Cholesterol | 44 | mg/dL | 40 - 60 |
| LDL cholesterol | 144 | mg/dL | <130 |
| VLDL cholesterol | 22.4 | mg/dL | 5-40 |
| Cholesterol/HDL Ratio | 4.8 | | Low Risk 3.3-4.97 Average Risk 4.4-7.1 Moderate Risk 7.1-11.0 High Risk >11.0 |

Checked By.

Dr. NITIN AGARWAL
MBBS, MDR
DMC/R/01430
DR. NITIN AGARWAL
MBBS, MD(PATHOLOGIST)

47, Harsh Vihar, Pitampura, New Delhi-110034 | Ph.: 011-42480101, 9599913051

E-mail: oneplusul@gmail.com | Web.: www.oneplusul.in

Page 3 of 7

Clinical correlation is essential for final diagnosis. • If test results are unsatisfactory please contact personally or on phone. • This report is for perusal of doctors only. • All disputes Subject to Delhi Jurisdiction only. • Not for medicolegal purposes. • All congenital anomalies in a foetus may not be diagnosed in routine obstetric ultrasound.



OnePLUS Ultrasound Lab

— QUALITY FIRST... ALWAYS! —

Dr. Nitin Agarwal

Pathologist & Director

Ex. Sr. Res. MAMC

& Lok Nayak Hospital

Ex. Chief of Lab Dr. Lal Path Labs.

Dr. Pooja (Garg) Agarwal

Radiologist & Director

MAMC & Lok Nayak Hospital



| | | | |
|-------------|-------------------------|-------------------|----------------------|
| NAME | :Mr. RAVI | Barcode No | :10139839 |
| AGE/GENDER | :29 YRS/Male | SPECIMEN DATE | :13/Mar/2023 09:08AM |
| PATIENT ID | :110587 | SPECIMEN RECEIVED | :13/Mar/2023 09:21AM |
| REFERRED BY | :Dr. MEDIWHEEL | REPORT DATE | :13/Mar/2023 04:37PM |
| CENTRE NAME | :ONEPLUS ULTRASOUND LAB | LAB NO. | :012303130004 |

| Test Name | Result | Unit | Ref. Range |
|---------------|--------|------|------------|
| LDL/HDL Ratio | 3.3 | | 0 - 3.55 |

According to ATP III and NCEP guidelines

| Parameter | Normal | Desirable | Borderline | High |
|-------------------|--------------------------------------|-----------|------------|------|
| Total cholesterol | <200 | | 200-239 | 240 |
| Triglycerides | <150 | 150-199 | 200-499 | 500 |
| LDL | Optimal <100 Near Optimal 100-129 | 130-159 | 160-180 | 190 |
| HDL | <40 : LOW 60 : HIGH | | | |

BUN/Creatinine ratio

| | | | |
|----------------------------|-------|-------|-------------|
| Bun (blood urea nitrogen) | 11.50 | mg/dl | 8.9-21.6 |
| CREATININE | 0.60 | mg/dl | 0.30-1.10 |
| BUN/Creatinine ratio | 19.17 | | 10.0 - 20.0 |

ENDOCRINOLOGY

THYROID PROFILE(T3,T4,TSH)

| | | | |
|-----------------------------------|------|--------|------------|
| Triiodothyronine total [t3] | 0.78 | ng/dl | 0.52-1.9 |
| Thyroxine total [t4] | 8.40 | µg/dl | 4.4 - 10.8 |
| TSH (Thyroid Stimulating Hormone) | 1.45 | µIU/ml | 0.25-5.0 |

AGE WISE VARIATION IN TSH

| AGE | TSH(µIU/ml) | AGE | TSH(µIU/ml) |
|-----------|-------------|----------------------------|-------------|
| 1-4 weeks | 1.00 - 19.0 | 16-20 yrs | 0.25 - 5.0 |
| 1-12 mths | 1.70 - 9.1 | 21 - 80 yrs | 0.25 - 5.0 |
| 1-5 yrs | 0.80 - 8.2 | I st trimester | 0.25 - 5.0 |
| 6-10 yrs | 0.25 - 5.0 | II nd trimester | 0.50 - 5.0 |
| 11-15 yrs | 0.25 - 5.0 | II rd trimester | 0.4 - 6.0 |

Checked By.

Dr. NITIN AGARWAL
M B B S, MD (Path)
DMC/R/01436

DR. NITIN AGARWAL
MBBS, MD (PATHOLOGIST)

47, Harsh Vihar, Pitampura, New Delhi-110034 | Ph.: 011-42480101, 9599913051

E-mail: oneplusul@gmail.com | Web.: www.oneplusul.in

Page 4 of 7



OnePLUS Ultrasound Lab

— QUALITY FIRST... ALWAYS! —

Dr. Nitin Agarwal

Pathologist & Director
Ex. Sr. Res. MAMC
& Lok Nayak Hospital
Ex. Chief of Lab Dr. Lal Path Labs.

Dr. Pooja (Garg) Agarwal

Radiologist & Director
MAMC & Lok Nayak Hospital



| | | | |
|-------------|-------------------------|-------------------|----------------------|
| NAME | :Mr. RAVI | Barcode No | :10139839 |
| AGE/GENDER | :29 YRS/Male | SPECIMEN DATE | :13/Mar/2023 09:08AM |
| PATIENT ID | :110587 | SPECIMEN RECEIVED | :13/Mar/2023 09:21AM |
| REFERRED BY | :Dr. MEDIWHEEL | REPORT DATE | :13/Mar/2023 04:37PM |
| CENTRE NAME | :ONEPLUS ULTRASOUND LAB | LAB NO. | :012303130004 |

| Test Name | Result | Unit | Ref. Range |
|-----------|--------|------|------------|
|-----------|--------|------|------------|

Reference ranges - Interpretation of Diagnostic tests - (Jacques Wallach)

1. Primary hypothyroidism is accompanied by depressed serum T3 and T4 values and elevated serum TSH level.
2. Primary hyperthyroidism is accompanied by elevated serum T3 and T4 levels along with depressed TSH values.
3. Slightly elevated T3 levels may be found in pregnancy and estrogen therapy, while depressed levels may be encountered in severe illness, renal failure and during therapy with drugs like propranolol and propyl thiouracil.
4. Although elevated TSH levels are nearly always indicative of primary hypothyroidism, and may be seen in secondary thyrotoxicosis

Checked By.

Dr. NITIN AGARWAL
M.B.B.S., MD (Path)
DMC/R/01436
DR. NITIN AGARWAL
MBBS, MD (PATHOLOGIST)

47, Harsh Vihar, Pitampura, New Delhi-110034 | Ph.: 011-42480101, 9599913051

E-mail: oneplusul@gmail.com | Web.: www.oneplusul.in

Page 5 of 7



OnePLUS
Ultrasound Lab
— QUALITY FIRST... ALWAYS! —

Dr. Nitin Agarwal
Pathologist & Director
Ex. Sr. Res. MAMC
& Lok Nayak Hospital
Ex. Chief of Lab Dr. Lal Path Labs.

Dr. Pooja (Garg) Agarwal
Radiologist & Director
MAMC & Lok Nayak Hospital



| | | | |
|-------------|-------------------------|-------------------|----------------------|
| NAME | :Mr. RAVI | Barcode No | :10139839 |
| AGE/GENDER | :29 YRS/Male | SPECIMEN DATE | :13/Mar/2023 09:08AM |
| PATIENT ID | :110587 | SPECIMEN RECEIVED | :13/Mar/2023 09:21AM |
| REFERRED BY | :Dr. MEDIWHEEL | REPORT DATE | :13/Mar/2023 03:06PM |
| CENTRE NAME | :ONEPLUS ULTRASOUND LAB | LAB NO. | :012303130004 |

| Test Name | Result | Unit | Ref. Range |
|-----------|--------|------|------------|
|-----------|--------|------|------------|

CLINICAL PATHOLOGY

URINE ROUTINE

Physical examination

| | | | |
|--------------|-------------|--|-------------|
| Quantity | 20 | | ML |
| Colour | PALE YELLOW | | |
| Transparency | CLEAR | | CLEAR |
| Sp.gravity | 1.015 | | 1.010-1.030 |
| pH | 6.50 | | |
| Reaction | ACIDIC | | ACIDIC |

Chemical examination

| | | | |
|------------------|----------|--|----------|
| Urine protein | NIL | | NIL |
| Urine sugar | NIL | | NIL |
| Bilirubin, urine | NEGATIVE | | NEGATIVE |
| Urobilinogen | NORMAL | | NORMAL |
| Ketones | NEGATIVE | | NEGATIVE |

Microscopic examination

| | | | |
|-------------------|-----|------|-----|
| Pus cells. | 2-3 | /HPF | 0-2 |
| Epithelial cells | 0-1 | /HPF | NIL |
| R.B.C. | NIL | /HPF | NIL |
| Casts | NIL | /HPF | NIL |
| Crystals | NIL | /HPF | NIL |
| Bacteria | NIL | /HPF | NIL |
| Others. | NIL | NIL | NIL |

Checked By.

Dr. NITIN AGARWAL
M.B.B.S., MD (PATHOLOGY)
DMC/R/01438
DR. NITIN AGARWAL
MBBS, MD (PATHOLOGIST)

47, Harsh Vihar, Pitampura, New Delhi-110034 | Ph.: 011-42480101, 9599913051
E-mail: oneplusul@gmail.com | Web.: www.oneplusul.in



OnePLUS
Ultrasound Lab
— QUALITY FIRST... ALWAYS! —

Dr. Nitin Agarwal
Pathologist & Director
Ex. Sr. Res. MAMC
& Lok Nayak Hospital
Ex. Chief of Lab Dr. Lal Path Labs.

Dr. Pooja (Garg) Agarwal
Radiologist & Director
MAMC & Lok Nayak Hospital



| | | | |
|-------------|-------------------------|-------------------|----------------------|
| NAME | :Mr. RAVI | Barcode No | :10139839 |
| AGE/GENDER | :29 YRS/Male | SPECIMEN DATE | :13/Mar/2023 09:08AM |
| PATIENT ID | :110587 | SPECIMEN RECEIVED | :13/Mar/2023 03:20PM |
| REFERRED BY | :Dr. MEDIWHEEL | REPORT DATE | :13/Mar/2023 04:50PM |
| CENTRE NAME | :ONEPLUS ULTRASOUND LAB | LAB NO. | :012303130004 |

| Test Name | Result | Unit | Ref. Range |
|-----------|--------|------|------------|
|-----------|--------|------|------------|

CLINICAL PATHOLOGY

STOOL ROUTINE

Physical examination

| | | | |
|-------------|------------|--|-------------|
| Colour | BROWNISH | | |
| Consistency | SEMI LOOSE | | Semi Formed |
| Blood | ABSENT | | Absent |
| Mucus | ABSENT | | Absent |

Chemical examination, stool

| | | | |
|----|------|--|--|
| pH | 6.50 | | |
|----|------|--|--|

Microscopic examination

| | | | |
|-----------|---------|------|-----|
| Pus cells | 2-3 | /HPF | |
| R.B.C. | NIL | /HPF | NIL |
| Ova | NIL | | NIL |
| Cysts | NIL | | NIL |
| Bacteria | PRESENT | /HPF | NIL |
| Others | NIL | | |

*** End Of Report ***

Checked By.

Dr. NITIN AGARWAL
MBBS, MD (Pathology)
DMC/R/01438
DR. NITIN AGARWAL
MBBS, MD (PATHOLOGIST)

47, Harsh Vihar, Pitampura, New Delhi-110034 | Ph.: 011-42480101, 9599913051

E-mail: oneplusul@gmail.com | Web.: www.oneplusul.in

Page 7 of 7

Clinical correlation is essential for final diagnosis. • If test results are unsatisfactory please contact personally or on phone. • This report is for perusal of doctors only.
• All disputes Subject to Delhi Jurisdiction only. • Not for medicolegal purposes. • All congenital anomalies in a foetus may not be diagnosed in routine obstetric ultrasound.



OnePLUS
Ultrasound Lab
— QUALITY FIRST... ALWAYS! —

Dr. Nitin Agarwal

Pathologist & Director
Ex. Sr. Res. MAMC
& Lok Nayak Hospital
Ex. Chief of Lab Dr. Lal Path Labs.

Dr. Pooja (Garg) Agarwal

Radiologist & Director
MAMC & Lok Nayak Hospital

| | | | |
|---------|-----------------|------------|----------------|
| Name | : Mr. RAVI | Age/Sex | : 29 YRS/Male |
| Ref. By | : Dr. MEDIWHEEL | Lab No | : 012303130004 |
| Date | : 13-Mar-2023 | Patient ID | : LSHHI110587 |

X-ray-Chest PA view

Bony cage and soft tissues are normal.
Cardiothoracic ratio is normal.
Mediastinum is normal.
Both hila are normal.
Both costophrenic angles are clear.
Both domes of diaphragm are normal.
Lung fields are clear. No parenchymal lesion seen.

IMPRESSION: Normal Study.

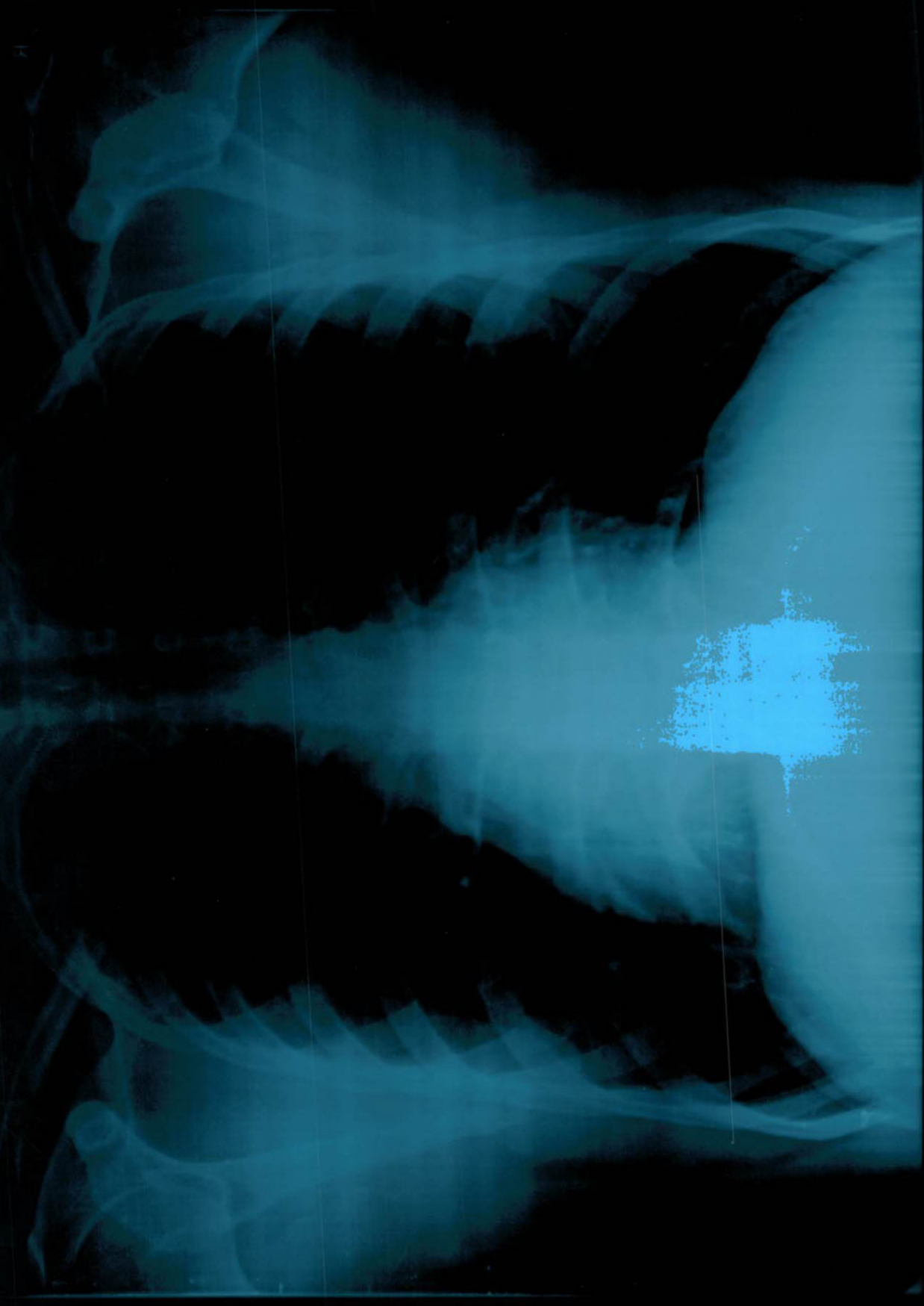
Dr. POOJA GARG
M.B.B.S., D.M.R.D.
Reg No. DMC/R/03398
Radiologist
DR. POOJA GARG
RADIOLOGIST
REG NO- DMC/R/03398

Type By : pooja

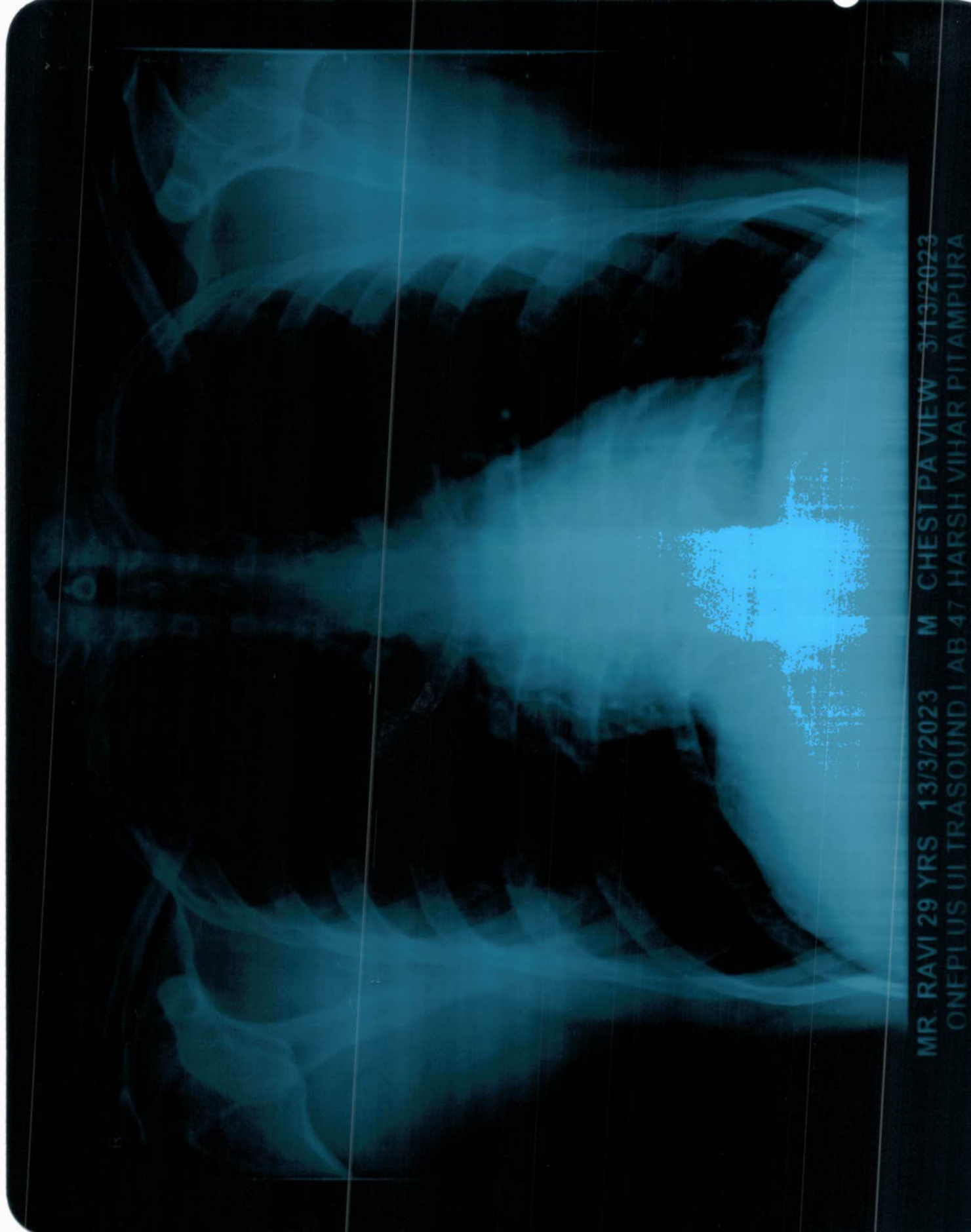
47, Harsh Vihar, Pitampura, New Delhi-110034 | Ph.: 011-42480101, 9599913051

E-mail: oneplusul@gmail.com | Web.: www.oneplusul.in

ONEPLUS UI TRASOUND I AB AL HARSH VIHAR PITAMPURA
MR RAVI SA YRS 13/3/5053 M CHEST PA VIEW 31/3/5053



H



MR. RAVI 29 YRS 13/3/2023 M CHEST PA VIEW 3/13/2023
ONEPLUS UI TRASOUND I AB 47 HARSH VIHAR PITAMPURA