


mediwheel

Handwritten signature

భారత ప్రభుత్వం
 GOVERNMENT OF INDIA


బ్రహ్మానంద్ ధవాలేశ్వరపు
 Brahmanand Dhavaleswarapu

18/09/1962



పుట్టిన సంవత్సరం/Year of Birth: 1962
 పురుషుడు / Male

6389 1078 0745



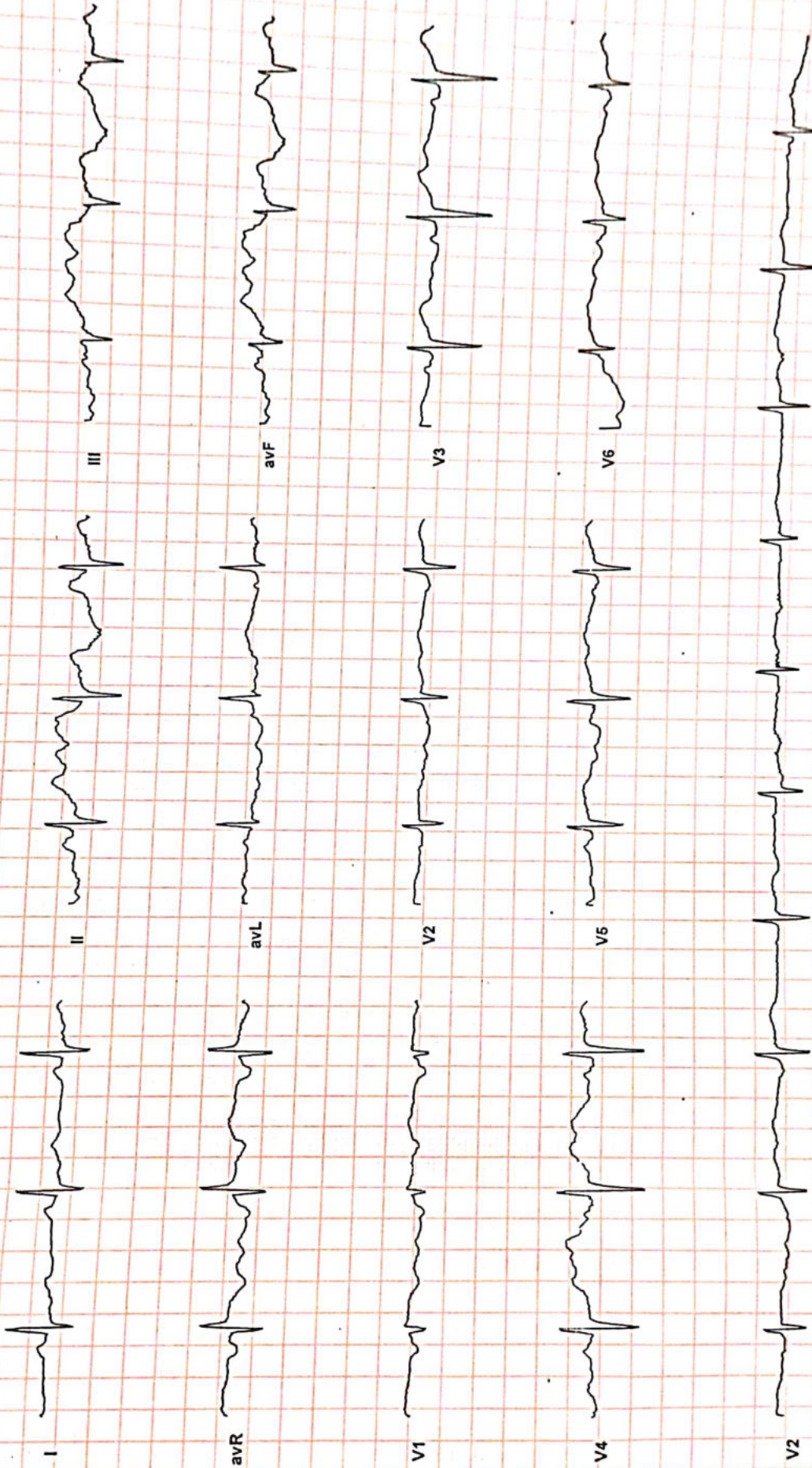
ఆధార్ - సామాన్యుని హక్కు

Handwritten signature

60/M

DR. PLUS HEALTHCARE CENTRE
 NATHANI HEIGHTS, B-WING
 42, MUMBAI CENTRAL (EAST)

DR. HARI CHHABLANI
 C.P.(RESP MEDICINE) FGDHIM, FGDMLS
 FELLOW INTENSIVE CARE
 M.M.C REG. NO. - 91702



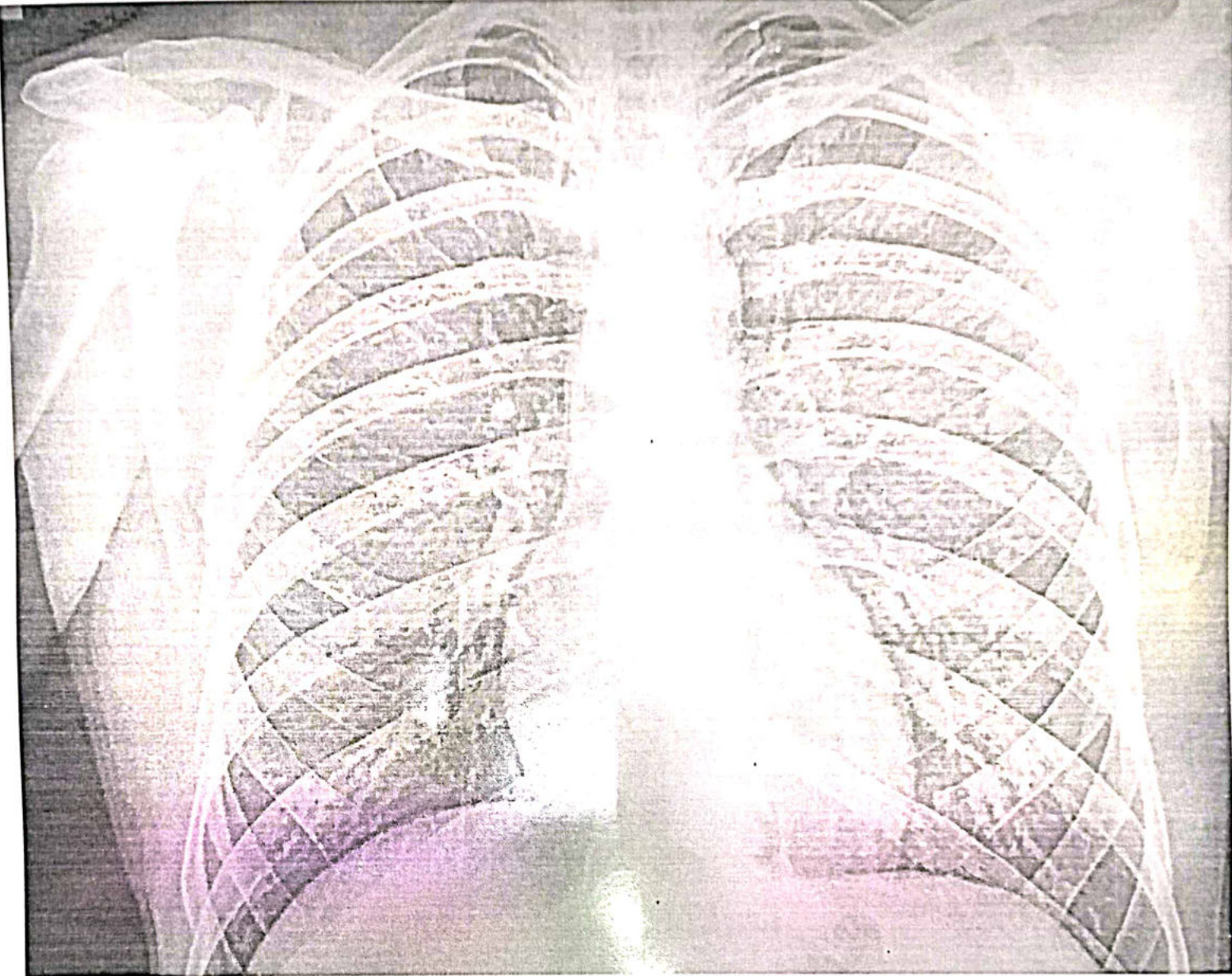
PHC-
DR. PURVI CHHABLANI
Reported By: DR. PURVI CHHABLANI
Consultant Physician, Intensive
Card No 7790F

WHL

BRAHMANAND DHAVALSWARAPU

60/M

24/09/22



'DR. PLUS HEALTHCARE CENTRE'
NATHANI HEIGHTS', B-WING,
42, MUMBAI CENTRAL (EAST)



Dr-Plus Healthcare Centre

NATHANI HEIGHTS, B-Wing, Shop No. 51, Ground Floor, Opp. Mumbai Central Station (East), Mumbai - 400 008.

Patient's Name : BRAHMANAND DHAVALESWARAPU

Report Date : 24/09/2022

Referred By : SELF

Age : 60 Years

Sex : MALE

X- RAY CHEST

BOTH THE LUNG FIELED ARE CLEAR.

THE HILAR SHADOWS APPEAR NORMAL.

THE COSTO-PHRENIC ANGELS ARE CLEAR.

THE CARDIAC SHADOWS APPEAR NORMAL.

THE TRACHEAL IS CENTRAL IN POSITION.

THE BONY CAGE APPEARS NORMAL.

IMPRESSION : THE ABOVE EXAMINATION IS WITHIN NORMAL LIMITS.

DR. A. J. MAZUMDAR

MD. DMRE, MDRD

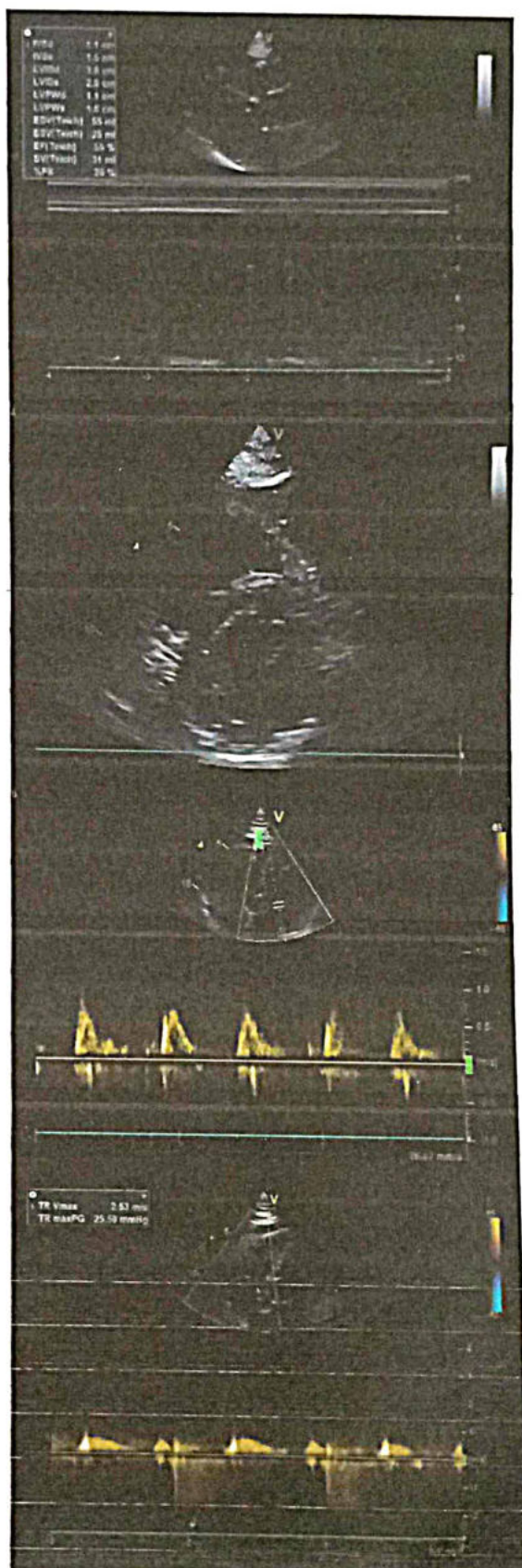

DR. PLUS HEALTHCARE CENTRE
NATHANI HEIGHTS, B-WING
42, MUMBAI CENTRAL (EAST)

Name BRAHMANANAD DHAVALSWARATU

Sex Male

Age 60

Date 24/09/2022



TR Vmax 2.53 m/s
TR maxPG 25.19 mmHg



NAME : BRAHMANAND DHAIVALESWARAPU 60/M

DATE:24/09/2022

REF BY : SELF

2D-ECHO. AND COLOR DOPPLER REPORT

- NORMAL CARDIAC VALVES WITH TRIVIAL TR.
- NORMAL CARDIAC CHAMBERS
- NO E/O REGIONAL WALL MOTION ABNORMALITY.WITH NORMAL LVEF OF 60 %.
- E/O MILD PULMONARY HYPERTENSION .PASP 31 mmHg by TR jet.
- E/O MILD LEFT VENTRICULAR HYPERTROPHY.
- E/O MILD DIASTOLIC DYSFUNCTION.
- NO E/O PERICARDIAL EFFUSION.
- NO E/O INTRACARDIAC CLOT OR VEGETATION
- INTACT IAS / IVS
- CONVENTIONL DOPPLER :

E TO A RATIO IS LESS THAN ONE IN LV INFLOW.


THERE IS NO GRADIENT ACROSS AV,LVOT OR RVOT

PASP FROM TR JET IS 31 mm OF Hg.

- COLOUR DOPPLER:

TRIVIAL TR

EF Slope	101	mm/sec		
Opening Amplitude	22			
Posterior leaflet				
E.P.S.S	02	mm		
Mitral valve prolapse				
Vegetations				
TRICUSPID VALVE	OBSERVED	NORMAL VALUES		
PULMONARY VALVE	OBSERVED	NORMAL VALUES		
EF Slope				
'A' Wave				
Midsystolic notch				
Flutter				
Other Findings				
AORTIC VALVE	OBSERVED	NORMAL VALUES		
Cuspal opening	19	mm		
Closure line	Central			
Eccentricity index	1			
Other Findings				
DIMENSIONS	OBSERVED	NORMAL VALUES		
1. Lvd (Diastolic)	36	26-52		
2. Lvd (Systolic)	26	24-42mm		
3. RVD (Diastolic)	17	7-23mm		
4. IVST (Diastolic)	11	6-11mm		
5. IVST (Systolic)	15			
6. LVPWT (Diastolic)	11	6-11mm		
7. LVPWT (Systolic)	16			
8. Aortic root	33	22-37mm		
9. left Atrium	34	19-40mm		
	STRUCTURE	REGURG GRADING	VELOCITY m/sec	STENOSIS GRADIENT mm/Hg
			Max mean	Peak mean
MITRAL VALVE	NORMAL	0/3	/	/
TRICUSPID VELVE	NORMAL	TRIVIAL	/	/
PULMONARY VELVE	NORMAL	0/4	/	/
AORTIV VALVE	NORMAL	0/4	/	/


DR.P.H.CHHABLANI
M.B.B.S, DNB.(MEDICINE)
CONSULTANT PHYSICIAN AND CARDIOLOGIST.

DR. PURVI CHHABLANI

M.B.B.S, DNB. (Medicine)
Consultant Physician and Intensive
Reg No 7769F



Dr-Plus Healthcare Centre

NATHANI HEIGHTS, B-Wing, Shop No. 51, Ground Floor, Opp. Mumbai Central Station (East), Mumbai - 400 008.

Full Name :

BRAHMANAND DHAVALSWARAPU 60/M

24/09/2022

HAEMOGRAM

		Normal Range	
1.	Red Blood Cell Count	4.6	[M : 4.5 - 5.6 / F : 3.5 - 5.5/cu.mm]
2.	Hb%	15.1	[M: 14-18 / F : 11-16%]
3.	Hematocrit	42.6	[M : 40-53 / F : 30-47 %]
4.	Indices:		
(a)	MCV(Mean Corpuscular Volume)	90.2	[79-101 cu.mi.]
(b)	MCH(Mean Corpuscular Hb)	27.9	[27-32 pg]
(c)	MCHC(Mean Corpuscular Hb Concentration)	33.6	[32-38%]
5.	Morphology		
	Macrocytes : --	Microcytes: --	Hypochromia: --
	Poikilocytosis: --	Anisocytosis: --	
6.	Target cells: --		
	Spherocytes: --	Elliptocytes: --	
7.	TOTALW.B.C.Count	6,500	{4000-11000/cu.mm}
Differential Count			
a)	Neutrophils :	60	[45 - 70%]
b)	Lymphocytes :	29	[20 - 45%]
e)	Basophils :	01	[00 - 01%]
c)	Eosinophils:	04	[01 - 06%]
d)	Monocytes:	06	[00 - 08%]
8.	Platelets :3.02		1.5-4.5 Lacks/cu.mm
9.	Erythrocyte Sedimentation Rate (ESR): 10		Up to 20 mm at end of hour
			Method : Westergrens

ROUTINE URINE EXAMINATION (RUA)

1. Physical Examination:

(i)	Colour:	YELLOW	(ii)	Sediment:	CLEAR
(iii)	Transparency:	CLEAR	(iv)	Reaction:	ACIDIC
(v)	Specific gravity	1.015			

2. Chemical Examination:

(i)	Protein :	NIL	(ii)	Sugar:	NIL
(iii)	Bile salt:	NIL	(iv)	Bile pigment:	NIL

3. Microscopic Examination:

(i)	Red Blood Cells:	ABSENT	(ii)	Epithelial Cells:	1 TO 2/ HPF
(iii)	Crystals:	ABSENT	(iv)	Pus Cells:	1 TO 2/HPF
(v)	Casts:	ABSENT	(vi)	Deposits:	ABSENT
(vii)	Bacteria's :	ABSENT			

DR. RAKESH PATKAR
M.D., D.I.B. (Pathology)
Reg. No. 2013/05/1000



Dr-Plus Healthcare Centre

NATHANI HEIGHTS, B-Wing, Shop No. 51, Ground Floor, Opp. Mumbai Central Station (East), Mumbai - 400 008.

Full Name
Life to be assured:

BRAHMANAND DHAVALSWARAPU

60/M

24/09/2022

	Type of Test	Actual Reading	Normal Range
1	Fasting Blood Sugar	84.6	70-100 mg%
2	PPBS	112.4	110 TO 140 mg%
3	Total Cholesterol	194.9	120-200 mg%
4	VERY LOW DENSINTY LEVEL(VLDL)	12.3	10-30 mg/dl
5	High Density Lipid (HDL)	52.4	40-60 mg%
6	Low Density Lipid (LDL)	130.2	Upto 150
7	S. Triglycerides	114.6	50-150 mg%
8	CHOL/HDL	3.7	Upto 5
9	HDL/LDL	0.4	
10	S. Creatinine	0.9	0.5-1.2 mg%
11	Blood Urea Nitrogen (BUN)	17.8	7-21 mg%
12	BUN/CREAT RATIO	19.7	
13	S. Proteins	6.8	6.0-7.9 mg%
14	(a) Albumin	3.8	3.5-5.5 mg%
15	(b) Globulin	3.0	2.0-3.5 mg%
16	A/G RATIO	1.2	
17	S. Bilirubin	1.0	0.3-1.3mg%
18	(a) Direct	0.6	0.0-0.8 mg%
19	(b) Indirect	0.4	0.0-0.5 mg%
20	SGOT (AST)	23.5	05-34 IU
21	SGPT (ALT)	38.4	05-40 IU
22	GGTP (GGT)	40.3	05-50 IU
23	SGOT/SGPT	0.6	
24	HBA1C	5.4	UPTO 6.5
25	S. Alkaline Phosphatase	101.8	30-115 IU
26	T3	157.2.	80-180ng/dl
27	T4	5.0	4.6-12 ug/dl
28	TSH	2.0	0.4-4.0 mIU/L
29	SERUM URIC ACID	4.5	2.5-7.2mg/dl
30	URINE SUGAR PP	ABSENT	
31	URINE SUGAR FASTING	ABSENT	
32	BLOOD GROUP	"A POSITIVE "	

DR. RAKESH PATKAR
M.D., D.N.B. (Pathology)
Reg. No. 2013/05/1660



Dr. Hari Chhablani

Cardiometabolic Physician & Intensivist
M.B.B.S., F.C.C.P. (RESP. MED.), PGDHHM,
PGDMLS, FELLOW INTENSIVE CARE MED.

ATTACHED TO : Wockhardt Hospital • Saifee Hospital • Apollo Spectra Hospital

NATHANI HEIGHTS, B-Wing, Shop No. 42, Ground Floor, Opp. Mumbai Central Station (East),
Mumbai - 400 008. • Cell : 98206 46163 • E : drharichhablani@gmail.com

PHYSICIAN REPORT

NAME : BRAHMANAND DHAVALSWARAPU

60/M

DATE : 24/09/2022

PRESENTING COMPLAINS : NIL

PAST HISTORY : COVID-19 POSITIVE IN -JAN.2022 ,HOME QUARANTINED .

FAMILY HISTORY: NOT SIGNIFICANT.

TREATMENT :

HABITS: NIL

HT.- 162 CM. WT.- 75 Kg. BMI.-28

P: 62/MIN ., REGULAR BP: 118/80

EYE EXAMINATION : NEAR VISION -R/E- N18 , L/E- N12 ,

DISTANT VISION -R/E - 6/18 , L/E -6/12

COLOR VISION : NORMAL

RS: CLEAR

CVS: S1,S2 REGULAR

PA: SOFT

CNS: CLINICALLY NAD

ENT EXAMINATION : WNL

LABS: ATTACHED

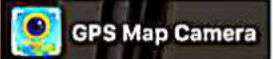2-D- ECHO : ATTACHED

ECG: ATTACHED

X-RAY : ATTACHED

IMPRESSION : : FIT ON CLINICAL MEDICAL EXAMINATION .


DR. HARI CHHABLANI
M.B.B.S., F.C.C.P. (RESP. MED.) PGDHHM, PGDMLS
FELLOW INTENSIVE CARE
MMC REG. NO. - 91702



Mumbai, Maharashtra, India

Shop No 65, Nathani Heights, Marzban Parsi Colony, Dalal Estate, Mumbai Central, Mumbai, Maharashtra 400008, India

Lat 18.968785°

Long 72.819976°

24/09/22 09:17 AM GMT +05:30

