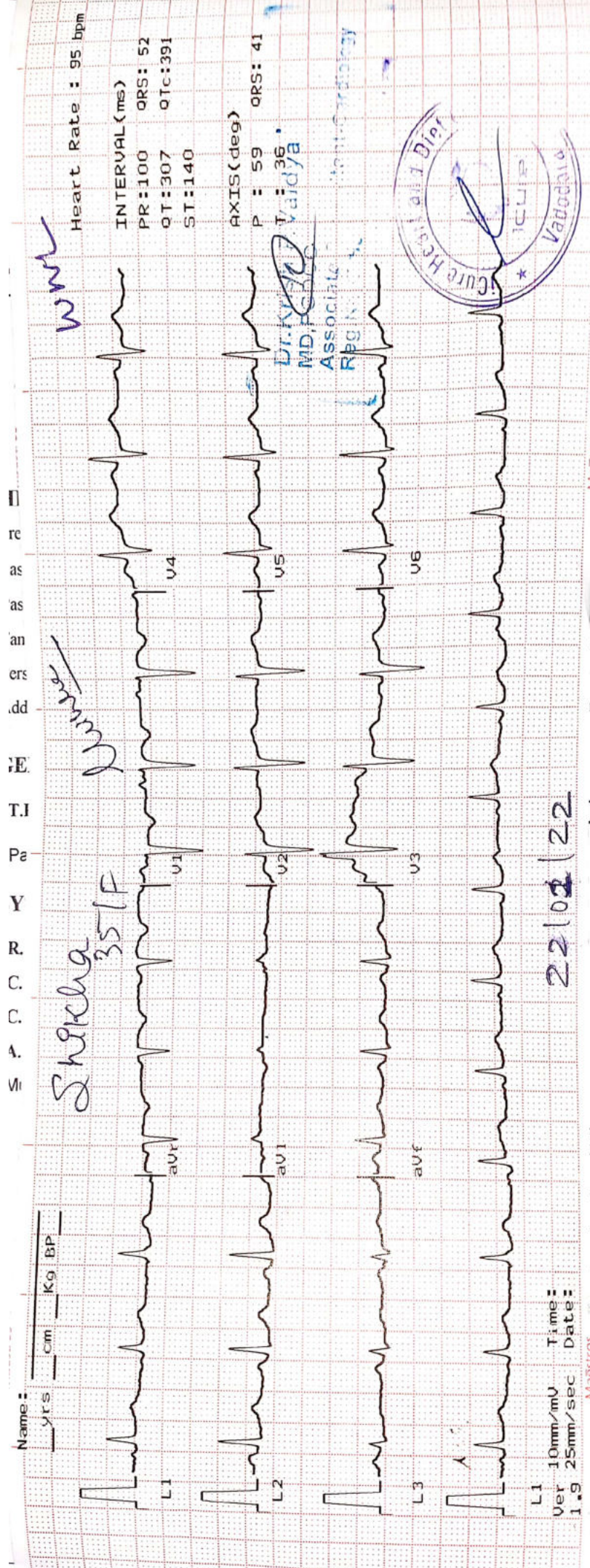

# Heart & General Clinic

iCure Heart & Diet Clinic, 402, Epsilon tower, opp Pasha bhai park, Race course, Vadodara

## :: PERSONAL HEALTH REPORT ::

NAME

Shikha

DATE 22/01/22

SR. NO.

SEX. Female

AGE 35/

HEIGHT - 143 cm

WEIGHT 86 kg

### HISTORY

Present History

: NA

Past Hlness History

: NA Diabetes/Hypertension/Tuberculosis/Asthma/Epilepsy

Past Occupational History

: NA

Family History

: Father & Mother HEN

Personal History

: NA

Addiction

: NA Tobacco/Gutkha/Smoking/Alcohol

### GENERAL EXAMINATION

T.P.R. : 75 min

B.P. : 130/90 mm Hg

Pallor/Icterus/Cyanosis/Varicosity/Lymph Nodes/Thyroid/Oedema/NVE/Other :

### SYSTEMIC EXAMINATION

R.S.

: NA

C.V.S

: NA

C.N.S

: NA

A.S.

: NA

Musculo-skelet System

: NA

E.N.T. Ex.	Dental Ex.	Skin Ex.	Psychic Ex.	ACUITY OF VISION		RT EYE	LT EYE
				Without Glass	DISTANT	6/ 6	6/ 6
NA	NA	NA	NA	Near		6/ 6	6/ 6
				With Glass	DISTANT	6/ -	6/ -
				Near		6/ -	6/ -
				COLOUR BLINDNESS N/A			

REMARK

ADVICE

The Worker is FIT/UNFIT for the assigned job.

Dr. Krish P. Vaidya

MD, PGDCC

Associate Consultant-Cardiology

Reg. No. G-50510

DR. KRISH VAIDYA

MD G-50510, CIH







भारत सरकार  
Government of India



आधार

भारत सरकार  
Government of India

भारतीय विशिष्ट पहचान प्राधिकरण  
Unique Identification Authority of India

नामांकन क्रम/ Enrolment No.: 0000/00458/80489


Download Date: 17/12/2020

To  
शिक्षा  
Shikha  
W/O Rahul Kumar Kashyap  
Birla Boarding By Lane  
Mount Motor Gali  
Ratu Road  
R/0-68  
Hehal  
Hehal  
Ranchi Jharkhand - 834005  
7250461535

Issue Date: 21/09/2017

Validity unknown

Download Date: 17/12/2020



आपका आधार क्रमांक / Your Aadhaar No. :

5854 1815 5104

VID : 9198 1063 4272 7289

मेरा आधार, मेरी पहचान



भारत सरकार  
Government of India



आधार

Download Date: 17/12/2020



शिक्षा  
Shikha  
जन्म तिथि/DOB: 17/03/1987  
महिला/ FEMALE

Issue Date: 21/09/2017

5854 1815 5104

VID : 9198 1063 4272 7289

मेरा आधार, मेरी पहचान



Government of India



AADHAAR

सूचना

- आधार पहचान का प्रमाण है, नागरिकता का नहीं।
- सुरक्षित QR कोड / ऑफलाइन XML / ऑनलाइन ऑथेंटिकेशन से पहचान प्रमाणित करें।
- यह एक इलेक्ट्रॉनिक प्रक्रिया द्वारा बना हुआ पत्र है।

INFORMATION

- Aadhaar is a proof of identity, not of citizenship.
- Verify identity using Secure QR Code/ Offline XML/ Online Authentication.
- This is electronically generated letter.

- आधार देश भर में मान्य है।
- आधार कई सरकारी और गैर सरकारी सेवाओं को पाना आसान बनाता है।
- आधार में मोबाइल नंबर और ईमेल ID अपडेट रखें।
- आधार को अपने स्मार्ट फोन पर रखें, mAadhaar App के साथ।

- Aadhaar is valid throughout the country.
- Aadhaar helps you avail various Government and non-Government services easily.
- Keep your mobile number & email ID updated in Aadhaar.
- Carry Aadhaar in your smart phone – use mAadhaar App.



भारतीय विशिष्ट पहचान प्राधिकरण  
Unique Identification Authority of India




AADHAAR

पता:

राहुल कुमार कश्यप, बिरला बोर्डिंग बाइ गलि, माउंट मोटर गली, आर/0-68, रातु मार्ग, हेहल, रांची, झारखण्ड - 834005

Address:

W/O Rahul Kumar Kashyap, Birla Boarding By Lane, Mount Motor Gali, R/0-68, Ratu Road, Hehal, Ranchi, Jharkhand - 834005



5854 1815 5104

VID : 9198 1063 4272 7289

1947



help@uidai.gov.in



www.uidai.gov.in

*Chinoo  
for broadband connectivity*





बैंक ऑफ बड़ोदा  
Bank of Baroda



नाम : शिखा  
Name : SHIKHA

कर्मचारी कूट क्र. 94275  
E.C. No. : 94275

जारीकर्ता अधिकारी, डी.जी.ए.डी. वाराणसी क्षेत्र  
Issuing Authority, DGIJ Jharkhand Region

धारक के हस्ताक्षर  
Signature of Holder

2





  
**Heart & General Clinic**

## 2D Echocardiography & Color Doppler Report

iCure Hear care, 402, Epsilon tower, opp Pasha bhai park, Race course, Vadodara

Name :Mrs Shikha Age/ Sex : 35yrs/female		Date: 22/01/2022
MEASUREMENTS		OBSERVED
AORTIC ROOT	[ 22-33 ]	29
LEFT ATRIUM	[ 29-40 ]	31
LEFT VENTRICLE [ ES ]	[ 22-37 ]	28
LEFT VENTRICLE [ ED ]	[ 39-51 ]	42
RIGHT VENTRICLE [ ED ]	[ 13-24 ]	21
I.V.S THICKNESS	[ 8 - 10 ]	09
L.V.P.WALL THICKNESS[ ED ]	[ 8 - 10 ]	09
I.V.S / L.V.P.W RATIO		-
L V EJECTION FRACTION	[ 50-70 ]	60%
FRACTIONAL SHORTENING	[ 27- 43 ]	40%

**MOTION:**

I.V.S.: Normal

L.V.P.W: Normal

**VALVES:**

ANTERIOR MITRAL

POSTERIOR MITRAL

LEAFLET : NORMAL

LEAFLET : NORMAL

EF - SLOPE : NORMAL

STRUCTURE : NORMAL

DE EXCN : NORMAL

MOTION : NORMAL

EPSS : NORMAL

SUB VAL FUSION : NORMAL

AORTIC VALVE : NORMAL

TRICUSPID VALVE : NORMAL

PULMONARY VALVE : NORMAL

RVOT : NORMAL

OTHER ABNORMALITIES : NIL

CALCIFICATION: NIL

**DOPPLER EVALUATION:**

Structure	Flow Velocity	
MV	E - 1.96	A- 2.15
AV	1.4	
TV	1.8	
PV	1.9	
SHUNT	NIL	

Dr.Krish P.Vaidya  
MD,PGDCC  
Associate Consultant-Cardiology  
Reg.No.G-50510



**Dr. Krish Vaidya**  
MD. G-50510



**CONCLUSION:**

Normal LV systolic function. [LV EF – 60%]  
No RWMA  
Normal Cardiac Chambers  
NO LVDD  
No MR, No MS  
No AR, No AS  
Normal values & blood flow velocities.  
No TR, NO PAH  
No e/o PE / PAH / clot / shunt.



**Dr. Krish P. Vaidya**  
MD, PGCC  
Associate Consultant-Cardiology  
Reg. No. G-50510  
**Dr. Krish Vaidya**  
MD. G-50510



# JKV LABORATORY



Name : SHIKHA  
Ref By : ICURE HEART & DIET CLINIC

Age/Sex : 46 Yrs./F  
Date : 22/01/2022  
Report ID. : 13

## THYROID FUNCTIONS

<u>TEST</u>	<u>RESULT</u>	<u>UNIT</u>	<u>REFERENCE INTERVAL</u>
Total Triiodothyronine - T3	: 0.76	ng/mL	0.58 -1.59 ng/mL
Total Thyroxine - T4	: 5.40	ng/mL	4.87 - 11.72 microgram%
Thyroid Sti. Hormone -TSH	: 2.30	ng/mL	0.49 to 4.67 IU/mL

END OF REPORT



**DR JIGAR SHAH (G23327)**  
**M.D. Pathologist**

Time : 7 a.m. to 9.00 p.m. ● Emergency 24 Hrs.

FF-5, Pancham Elite, Khodiyar Nagar, New V.I.P. Road, Vadodara-390 022.  
☎ 8320343731 / 9601969303 ✉ jkvlaboratory2021@gmail.com

Test Report are subject to technical limitations & should be clinically correlated. Laboratory may be contacted whenever required.

Free Home Service





# JKV LABORATORY



Name : SHIKHA  
Ref By : ICURE HEART & DIET CLINIC

Age/Sex : 46 Yrs./F  
Date : 22/01/2022  
Report ID. : 13

## Hb A1C REPORT

<u>TEST</u>	<u>RESULT</u>	<u>UNIT</u>	<u>REFERENCE INTERVAL</u>
Hb A1C - Glycated Hb Glycated Haemoglobin	: 5.4	%	Non Diabetic : 4.3 - 6.3 % Good Control : 6.4 - 7.5 % Moderate Control : 7.5 - 9.0 % Poor Control : 9.0 % & Above
Avg. Blood Glucose Level	: 115	mg/dL	
Estimated Average Glucose eAG	: 108	mg%	

## EXAMINATION OF URINE

Sample	: FASTING
<b><u>PHYSICAL EXAMINATION</u></b>	
Quantity	: 10 mL
Colour	: PALE YELLOW
Transparency	: CLEAR
Specific Gravity	: 1.030
Reaction	: ACIDIC
Deposits	: ABSENT
<b><u>CHEMICAL EXAMINATION</u></b>	
Albumin	: NIL
Sugar	: NIL
Acetone	: ABSENT
Bile Salts	: ABSENT
Bile Pigments	: ABSENT
Urobilinogen	: NORMAL : ~ < 1.0 mg/dL
Occult Blood	: ABSENT
Nitrate	: ABSENT
<b><u>MICROSCOPIC EXAMINATION</u></b>	
Pus Cells	: 0-1 / hpf
RBC	: NIL
Epithelial Cells	: NIL
Crystals	: NIL
Amorphous Phosphate	: NIL
Cast	: NIL



**DR JIGAR SHAH (G23327)**  
**M.D. Pathologist**

Time : 7 a.m. to 9.00 p.m. • Emergency 24 Hrs.

FF-5, Pancham Elite, Khodiyar Nagar, New V.I.P. Road, Vadodra-390 022.

8320343731 / 9601969303 | jkvlaboratory2021@gmail.com

Test Report are subject to technical limitations & should be clinically correlated. Laboratory may be contacted whenever required.

Free Home Service





# JKV LABORATORY



Name : SHIKHA  
Ref By : ICURE HEART & DIET CLINIC

Age/Sex : 46 Yrs./F  
Date : 22/01/2022  
Report ID. : 13

## BIOCHEMISTRY

<u>TEST</u>	<u>RESULT</u>	<u>UNIT</u>	<u>REFERENCE INTERVAL</u>
Blood Urea	: 33.00	mg/dL	10 - 50 mg/dL
Serum Creatinine	: 0.91	mg/dL	0.6 - 1.4 mg/dL
Serum Uric Acid	: 3.42	mg/dL	2.4 - 5.7 mg/dL
<b><u>SERUM PROTEIN</u></b>			
Serum Protein Total	: 7.30	g/dL	6.6 - 8.3 g/dL
Albumin	: 4.60	g/dL	3.50 - 5.00 g/dL
Globulin	: 2.70	g/dL	2.3 - 3.5 g/dL
A/G Ratio	: 1.7	: 1	1.5 - 2.5 : 1
Bilirubin - Total	: 0.2	mg/dL	0.00 - 1.00 mg/dL
Bilirubin - Direct	: 0.1	mg/dL	Upto 0.30 mg/dL
Bilirubin - Indirect	: 0.6	mg/dL	0.1 - 1.0 mg/dL
SGPT	: 23.0	IU/L	10 - 40 IU/L
SGOT	: 34.0	IU/L	Upto 40 IU/L
Serum Alkaline Phosphatase	: 122.0	U/L	37 - 147 U/L
<b><u>LIPID PROFILE</u></b>			
Serum Cholesterol	: 162.00	mg/dL	130 - 200 mg/dL
Serum Triglyceride	: 154.00	mg/dL	60 - 165 mg/dL
HDL Cholesterol	: 43.00	mg/dL	30 - 70 mg/dL
LDL Cholesterol	: 88.20	mg/dL	Upto 150 mg/dL
VLDL	: 27.00	mg/dL	Upto 30 mg/dL
<b><u>FASTING (FBS)</u></b>			
Blood Glucose	: 96.0	mg/dL	70.00 - 110.00 mg/dL
<b><u>POST-PRANDIAL</u></b>			
Blood Glucose	: 127.0	mg/dL	80 - 140 mg/dL
<b><u>SPECIAL TESTS</u></b>			
GGTP	: 28	U/L	05 - 85 U/L
Gamma Glutamyltransferase			

Done By Fully Auto Analyzer MIURA, A-1004



**DR JIGAR SHAH (G23327)**  
**M.D. Pathologist**

Time : 7 a.m. to 9.00 p.m. • Emergency 24 Hrs.

FF-5, Pancham Elite, Khodiyar Nagar, New V.I.P. Road, Vadodara-390 022.

☎ 8320343731 / 9601969303 ✉ jkvlaboratory2021@gmail.com

Test Report are subject to technical limitations & should be clinically correlated. Laboratory may be contacted whenever required.

Free Home Service



# JKV LABORATORY



Name : SHIKHA  
Ref By : ICURE HEART & DIET CLINIC

Age/Sex : 46 Yrs./F  
Date : 22/01/2022  
Report ID. : 13

## HAEMOGRAM PROFILE

TEST	RESULT	UNIT	METHOD	REFERENCE INTERVAL
<b>BLOOD COUNTS &amp; INDICES</b>				
Haemoglobin	: 15.20	gm%		12.0 - 16.0 gm%
Total RBC	: 5.10	mill/cmm		4.2 - 5.4 mill/cmm
PCV	: 42.00	%		37 - 47 %
MCV	: 82.35	fL		80 - 96 fL
MCH	: 29.80	pg		27 - 31 pg
MCHC	: 34.00	%		32 - 36 %
RDW	: 13.00	%		10 - 15 %
Total WBC	: 4,800	/cmm		4,000 - 11,000/cmm
<b>DIFFERENTIAL LEUCOCYTES COUNT</b>				
Band Cells	: 00	%		00 - 06 %
Neutrophils	: 61	%		55 - 70 %
Lymphocytes	: 31	%		20 - 40 %
Eosinophils	: 04	%		01 - 06 %
Monocytes	: 04	%		02 - 08 %
Basophils	: 00	%		00 - 01 %
Platelet In Smear	: ADEQUATE			
<b>ERYTHROCYTES SEDIMENTATION RATE</b>				
ESR After 1st Hour	: 5	mm	Westergren	03 - 12 mm
Blood Group	: " A "			
Rh Factor (Anti D.)	: " POSITIVE "			

(By Fully Automated Cell Counter Sysmex KX - 21, Japan)

END OF REPORT

  
DR JIGAR SHAH (G23327)  
M.D. Pathologist

Time : 7 a.m. to 9.00 p.m. • Emergency 24 Hrs.

FF-5, Pancham Elite, Khodiyar Nagar, New V.I.P. Road, Vadodara-390 022.

☎ 8320343731 / 9601969303 ✉ jkvlaboratory2021@gmail.com

Test Report are subject to technical limitations & should be clinically correlated. Laboratory may be contacted whenever required.

Free Home Service



  
**Heart & General Clinic**

Icure Heart & Diet Clinic, 402 Epsilon Tower, opp. Pashabhai Park, Nr. Natubhai Circle, Race course, Vadodara, 390007

<b>Name: SHIKHA</b>	<b>Date: 22/01/2022</b>
<b>Age / Sex : 46yrs/ Female</b>	

**PAP SMEAR CYTOLOGY (CONVENTIONAL)**

**Specimen**

Pap smear for cytology (conventional)

**Gross Description**

Received one unstained smear.  
Smear-1 [PAP]

**Microscopic Description**

See below in diagnosis.

**Diagnosis**

Satisfactory for evaluation.  
PAP Smears is negative for intra-epithelial lesion or malignancy.  
Trichomonas or monilia are not seen.  
Endo cervical cells are not seen.

PAP test is a screening test for cervical cancer with inherent false negative results.

----- End Of Report -----

All cytology tests reveal only cytological characteristics of individual cells and not architectural details which are very important in morphological diagnosis. All cytology methods have their own inherent limitations of false positive and false negative results due to variabilities related to sample collection methods, smear preparation, fixation and staining along with microscopic interpretation, hence whenever required tissue diagnosis and/or immunohistochemistry study after correlation with clinical and radiological findings should be done for further confirmation before any definitive medical or surgical treatment.

**Dr. Krish P. Vaidya**  
MD, PGDCC  
Associate Consultant - Cardiology  
Reg. No. G-50510

**Dr. Krish P Vaidya**  
MD G-50510



# PARAMOUNT DIAGNOSTIC & RESEARCH CENTRE

( A Unit of Paramount Charity Trust )

Radiology ■ Pathology ■ Histopathology ■ Molecular Biology

NAME : SHIKHA	AGE : 34 Y/F	DATE : 22/01/2022
---------------	--------------	-------------------

## X RAY CHEST (PA)

### OBSERVATIONS:

Both the lung fields and apices appear clear.  
Both the hilar shadow appears normal.  
Cardiac silhouette appears normal.  
Both the costophrenic sinuses are clear.  
Mediastinal and tracheal shadows are normal.  
Both the domes of diaphragm are normal.  
Visualized rib cage and clavicle are normal.

### COMMENTS:

- No significant abnormality is seen.

*Mehul Prajapati*

DR. MEHUL PRAJAPATI  
CONSULTANT RADIOLOGIST



24 hours Emergency Service Available for CT Scan / MRI / Pathology AMBULANCE SERVICE AVAILABLE  
Main Branch : Paramount Complex, Gotri Road, Race Course, Vadodara Ph: 0265 - 2395772, 2397438, 6647222, +91 - 6352731483,  
Path. Lab : 0265 - 6603900/901/902/903, +91 - 8160225911, +91 - 9099066029  
City Branch : Opp. Brahman Sabha Hall, Pratap Road, Dandiabazar, Vadodara Ph: 0265 - 2423233, +91 - 6352734810



# PARAMOUNT DIAGNOSTIC & RESEARCH CENTRE

( A Unit of Paramount Charity Trust )

Radiology ■ Pathology ■ Histopathology ■ Molecular Biology

NAME : SHIKHA	AGE : 34 Y/F	DATE : 22/01/2022
---------------	--------------	-------------------

## ULTRASONOGRAPHY OF WHOLE ABDOMEN (Screening Only)

**Liver** is normal in size and echotexture and shows normal parenchymal reflectivity. No focal lesion is seen. Hepatic veins appear normal. There is no evidence of any dilated intra hepatic biliary radicals.

**Portal Vein** appears normal in diameter.

**Common Bile Duct** is of normal diameter.

**Gallbladder** is physiologically distended with normal wall thickness. There are evidence of multiple calculi noted at gallbladder, largest measured 18mm in size. No evidence of peri-cholecystic fluid or probe tenderness.

**Pancreas** is normal in size and shows homogenous reflectivity. There is no evidence of any calcification or ductal dilatation.

**Spleen** is normal size and shows a homogenous echotexture. There is no evidence of any focal lesion.

**Both Kidneys** are normal in position and size. They show normal cortical reflectivity and cortico-medullary distinction. Right kidney measures 106x50mm. Left kidney measures 107x54mm. There is no evidence of renal calculi, hydronephrosis or mass seen.

**Bladder** is well distended and shows normal wall thickness. No evidence of intra-luminal mass or calculi.

**Uterus** appears normal in size . Uterine myometrial echotexture is homogeneous. No focal lesion is seen.

**Both Ovaries** appears normal in size & reflectivity. No evidence of any adnexal mass.

There is no evidence of ascites.

No evidence of any gross bowel mass seen.

No evidence of any aorto-caval or mesenteric root lymphadenopathy.

No mass or collection in right iliac fossa.

### CONCLUSION:

- Cholelithiasis without changes of cholecystitis.
- No other sonographic abnormality is seen.

*Mehul Prajapati*

**DR. MEHUL PRAJAPATI**  
CONSULTANT RADIOLOGIST



24 hours Emergency Service Available for CT Scan / MRI / Pathology AMBULANCE SERVICE AVAILABLE  
Main Branch ; Paramount Complex, Gotri Road, Race Course, Vadodara Ph : 0265 - 2395772, 2397438, 6647222, +91 - 6352731483,  
Path. Lab : 0265 - 6603900/901/902/903, +91 - 8160225911, +91 - 9099066029  
City Branch ; Opp. Brahman Sabha Hall, Pratap Road, Dandlabazar, Vadodara Ph : 0265 - 2423233, +91 - 6352734810