



भारतीय विशिष्ट ओळख प्राधिकरण

भारत सरकार

Unique Identification Authority of India

Government of India


नोंदविण्याचा क्रमांक / Enrollment No 1207/24143/00287

To,
किरण पांडेय
Kiran Pandey
W/O: Sunil Kumar Pandey
Flat No. 402, Sai Suparna, Plot No. 16
Sector - 8, Kamothe
Kalamboli Node
Kalamboli Node Panvel Raigarh
Maharashtra 410218
9860457724

Ref: 64 / 11D / 89118 / 89563 / P



SE047862944FT



आपला आधार क्रमांक / Your Aadhaar No. :

9846 4353 3563

आधार - सामान्य माणसाचा अधिकार

Dr. Mahesh V. Padsalge
MD. (Medicine)
Consultant Physician
Reg. No. 91424 (MMC)




भारत सरकार

Government of India



किरण पांडेय
Kiran Pandey
जन्म तारीख / DOB : 30/09/1970
स्त्री / Female



9846 4353 3563

आधार - सामान्य माणसाचा अधिकार

किरण

Female

QRS : 72 ms
QT / QTcBaz : 350 / 401 ms
PR : 148 ms
P : 102 ms
RR / PP : 762 / 759 ms
P / QRS / T : 70 / 85 / 25 degrees

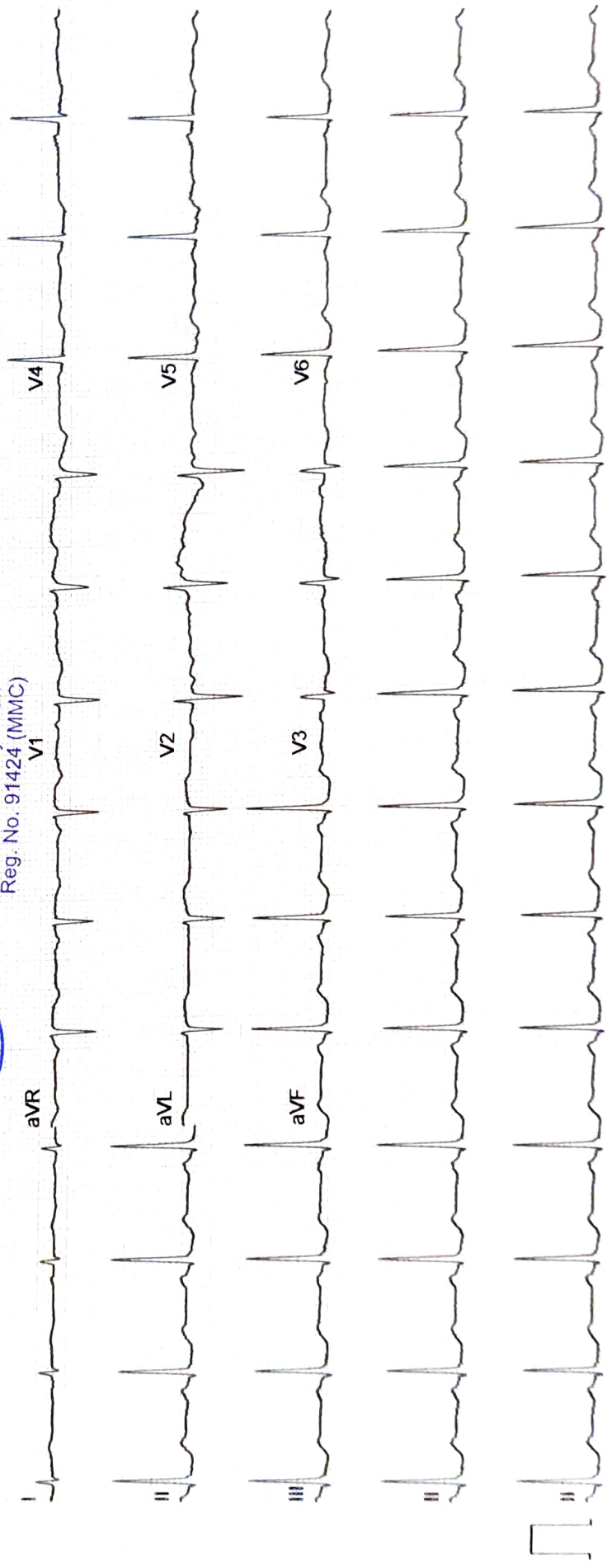
Normal sinus rhythm
Nonspecific T wave abnormality
Abnormal ECG



Dr. Mahesh V. Padsalge
MD. (Medicine)
Consultant Physician
Reg. No. 91424 (MMC)

19/2/20

Normal sinus rhythm



DIABECARE - DIABETES & ENDOCRINE CLINIC
 OFFICE NO-03, PLOT NO-46647, RAMKRISHNA CHS, OPP. GRAND CENTRAL MALL, SEAWOODS , NAVIMUMBAI-400706

MRS KIRAN PANDEY

ID : 9843

DATE : 20/02/2022

AGE/SEX : 50 /M

HT/WT : 148 / 56

REF. BY : MEDIWHEEL

TREADMILL TEST REPORT

PROTOCOL : Bruce

HISTORY : MEDIWHEEL

INDICATION : .

MEDICATION : .

PHASE	TOTAL TIME	STAGE TIME	SPEED Km/Hr	GRADE %	H.R. bpm	B.P. mmHg	RPP x100	ST LEVEL (MM)			METS
								II	V1	V5	
SUPINE					86	130 / 90	111	-0.6	0.1	-0.4	
HYPERVENT					83	130 / 90	107	-0.7	0.2	-0.4	
STANDING					84	130 / 90	109	-0.8	0.4	-0.5	
Stage 1	2:55	2:55	2.7	10	107	140 / 90	149	-0.4	0	0.6	4.67
Stage 2	5:55	2:55	4	12	120	150 / 90	180	0	0.6	-0.9	7.04
Stage 3	8:55	2:55	5.4	14	125	160 / 90	200	1.4	0.2	0	9.92
PK-EXERCISE	11:25	2:25	6.7	16	147	170 / 90	249	0.4	0.3	1	13.22
RECOVERY	14:30	2:55			94	160 / 90	150	-1.1	0.4	-0.5	
RECOVERY	17:30	5:55			92	150 / 90	138	-0.7	0.3	-0.3	
RECOVERY	20:30	8:55			90	140 / 90	126	-0.4	0.3	-0.2	

RESULTS

EXERCISE DURATION : 11:25
 MAX HEART RATE : 147 bpm
 MAX BLOOD PRESSURE : 170 / 90 mm Hg
 REASON OF TERMINATION : Achieved THR,
 BP RESPONSE : Normal,
 ARRYTHMIA : None,
 H.R. RESPONSE : Normal Chronotropic Response,
 IMPRESSIONS :
 Negative for Provocable myocardial ischemia,

MAX WORK LOAD : 13.22 METS



Kiran
Dr. Mahesh V. Padsalghe
 MD (Medicine)
 Consultant Physician
 Reg. No: 91424 (MMC)

Technician :

DR. MAHESH PADSALGE (MD)

DIABECARE - DIABETES & ENDOCRINE CLINIC

MRS KIRAN PANDEY
 I.D. 9843
 Age 50/M
 Date 20/02/2022

RATE 86bpm
 B.P. 130/90


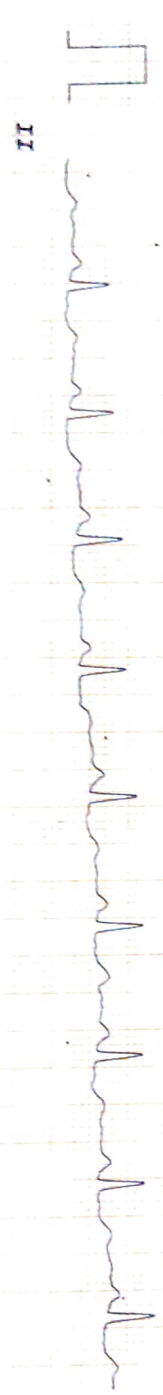

PRETEST
 SUPINE

ST @ 10mm/mV
 80ms Post J

LINKED MEDIAN

Mag. X 2

III



RACE

DIABECARE - DIABETES & ENDOCRINE CLINIC

MRS KIRAN PANDEY
 I.D. 9843
 Age 50/M
 Date 20/02/2022

RATE 83bpm
 B.P. 130/90

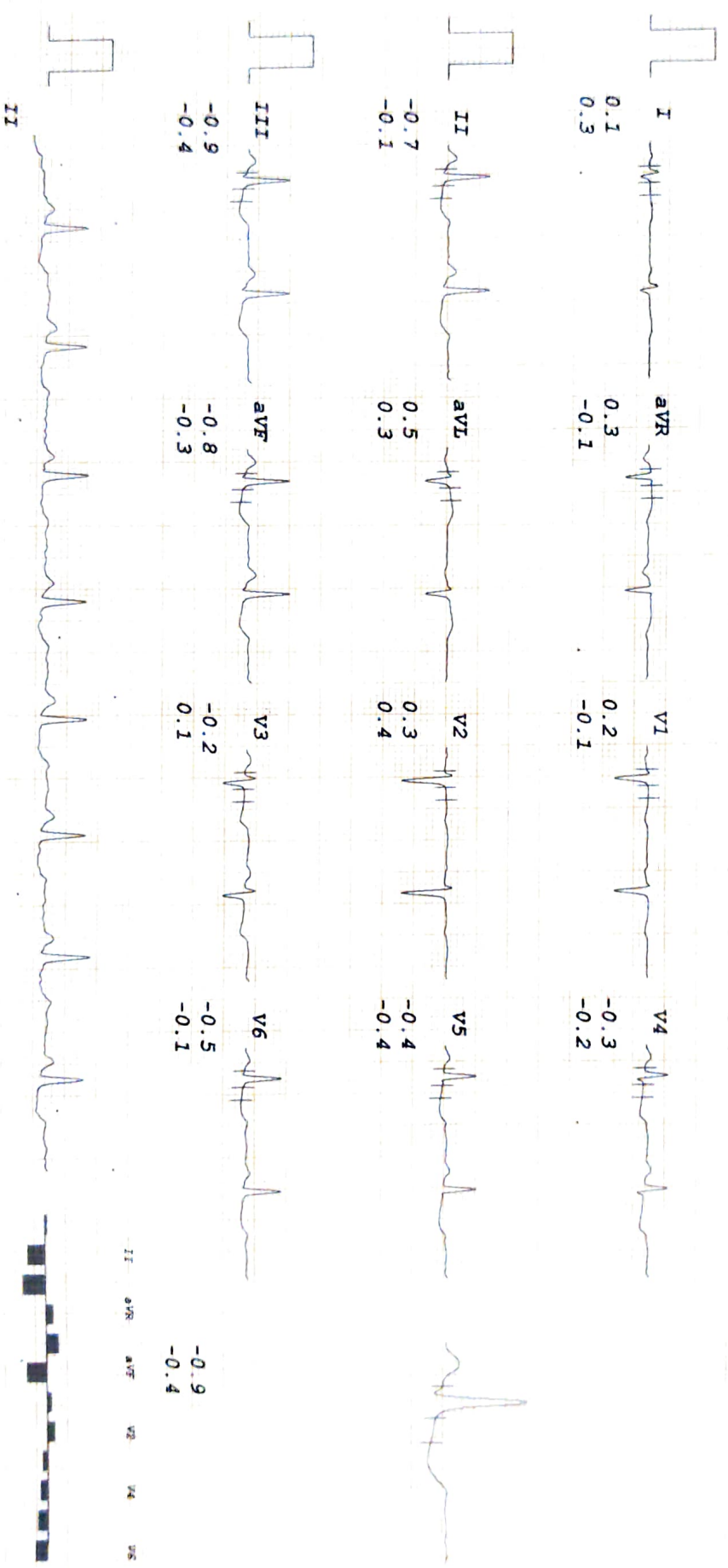
PRETEST
 HYPERVENT

ST @ 10mm/mV
 80ms PostJ

PHASE TIME 0:16

Mag. X 2

III



DIABECARE - DIABETES & ENDOCRINE CLINIC

MRS KIRAN PANDEY
 I.D. 9843
 Age 50/M
 Date 20/02/2022

RATE 84bpm
 B.P. 130/90





PRETEST
 STANDING

ST @ 10mm/mv
 80ms PostJ

LINKED MEDIAN

Mag. X 2

III



DIABECARE - DIABETES & ENDOCRINE CLINIC

MRS KIRAN PANDEY
 I.D. 9843
 Age 50/M
 Date 20/02/2022

RATE 107bpm
 B.P. 140/90




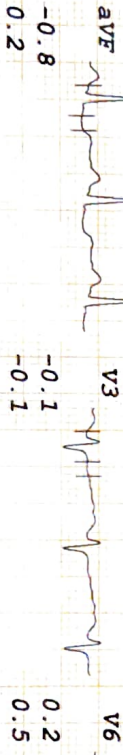


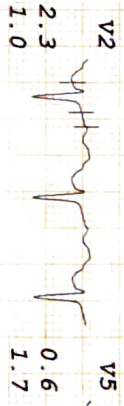





Bruce
 Stage 1
 TOTAL TIME 2:55
 PHASE TIME 2:55

ST @ 10mm/mV
 80ms PostJ
 Speed 2.7 km/hr
 SLOPE 10 %

LINKED MEDIAN

Mag. X 2

III



DIABECARE - DIABETES & ENDOCRINE CLINIC

MRS KIRAN PANDEY
I.D. 9843
Age 50/M
Date 20/02/2022

Rate 120bpm
B.P. 150/90


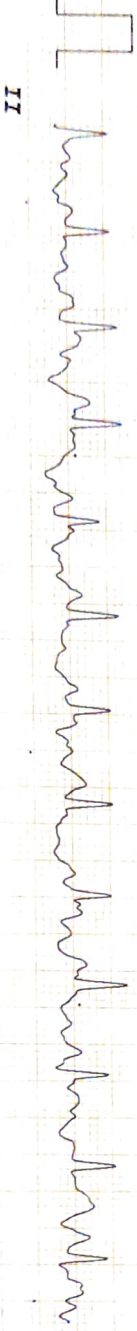



Bruce
Stage 2
TOTAL TIME 5:55
PHASE TIME 2:55

ST @ 10mm/mV
80ms PostJ
Speed 4 km/hr
SLOPE 12 &

LINKED MEDIAN

Mag. X 2

V5



DIABECARE - DIABETES & ENDOCRINE CLINIC

MRS KIRAN PANDEY
 I.D. 9843
 Age 50/M
 Date 20/02/2022

RATE 125bpm
 B.P. 160/90

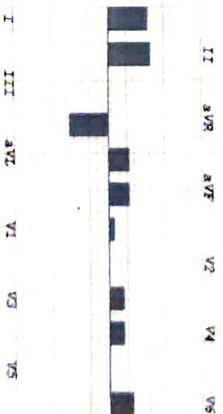




Bruce
 Stage 3
 TOTAL TIME 8:55
 PHASE TIME 2:55

ST @ 10mm/mv
 80ms PostJ
 Speed 5.4 km/hr
 SLOPE 14 %

LINKED MEDIAN

Mag. X 2

V5



DIABECARE - DIABETES & ENDOCRINE CLINIC

MRS KIRAN PANDAY
 I.D. 9843
 Age 50/M
 Date 20/02/2022

RATE 147bpm
 B.P. 170/90





Bruce
 PK-EXERCISE
 TOTAL TIME 11:25
 PHASE TIME 2:25

ST @ 10mm/mV
 80ms PostJ
 Speed 6.7 km/hr
 SLOPE 16 %

LINKED MEDIAN

Mag. X 2

III



DIABECARE - DIABETES & ENDOCRINE CLINIC

MRS KIRAN PANDEY
 I.D. 9843
 Age 50/M
 Date 20/02/2022

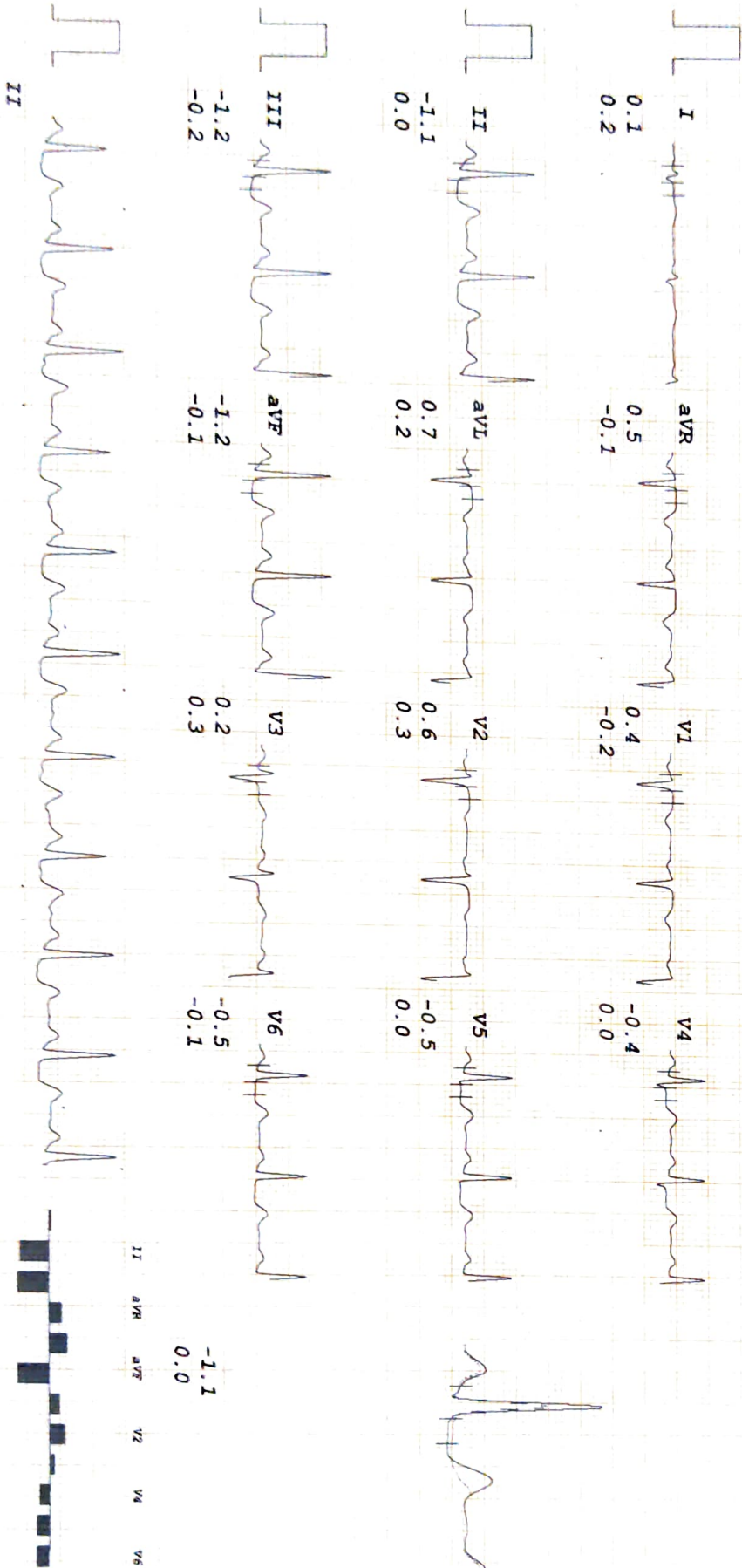
RATE 94bpm
 B.P. 160/90

Brice
 RECOVERY
 TOTAL TIME 14:30
 PHASE TIME 2:55

ST @ 10mm/mV
 80ms PostJ

LINKED MEDIAN

Mag. X 2



DIABECARE - DIABETES & ENDOCRINE CLINIC

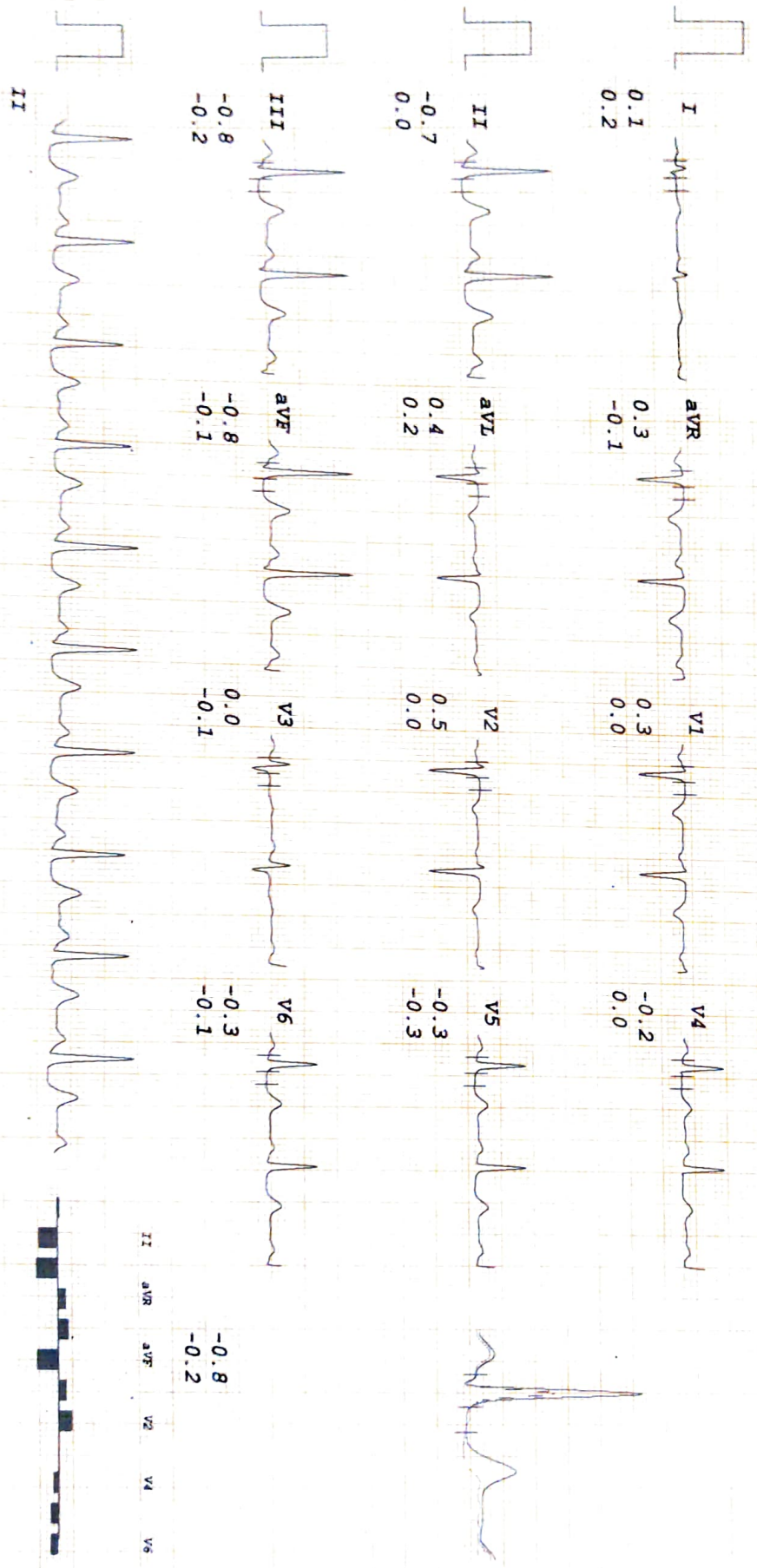
MRS KIRAN PANDEY
 I.D. 9843
 Age 50/M
 Date 20/02/2022

Rate 92bpm
 B.P. 150/90
 Bruce
 RECOVERY
 TOTAL TIME 17:30
 PHASE TIME 5:55

ST @ 10mm/mV
 80ms Post J

LINKED MEDIAN

Mag. X 2



DIABECARE - DIABETES & ENDOCRINE CLINIC

WPS KIRAN PAHLEY
 I.D. 9843
 Age 50/M
 Date 20/02/2022

Rate 90bpm
 B.P. 140/90



Bruce
 RECOVERY
 TOTAL TIME 20:30
 PHASE TIME 8:55

ST @ 10mm/mV
 80ms PostJ

LINKED MEDIAN

MAG. X 2

II



NAME- MRS.KIRAN PANDEY

Date- FEB 20, 2022

AGE- 50/F

BILATERAL BREAST FILM SCREEN MAMMOGRAPHY REPORT

Both breasts film screen mammography was performed in cranio-caudal and medio-lateral oblique views.

Both breasts show fatty glandular parenchyma.ACR-A.

No evidence of dominant mass, clusters of microcalcifications,nipple retraction,skin thickening or vascular calcification seen bilaterally.

No evidence of axillary lymphadenopathy.

Impression:- No mass lesion seen in both breasts.

Adv:- Clinical correlation & Regular follow up.

For, **DR.MRUDULA BABAR****RADIOLOGIST**

Dr. MRUDULA BABAR
DMRE CPS Mumbai 2009
(RADIOLOGIST)
Reg. No. 2005/03/2139

NAME - KIRAN PANDEY

DATE- 20/2/2022

AGE- 50/F

X-RAY CHEST PA

THE SOFT TISSUES AND BONY THORAX ARE NORMAL.

BOTH THE COSTOPREHNIC AND CARDIOPHRENIC ANGLES ARE CLEAR.

THE LUNG FIELDS ARE NORMAL.

CARDIAC SHAPE AND SIZE APPEARS NORMAL.

BOTH THE HILA ARE NORMAL IN DENSITY AND POSITION.

BOTH THE DOMES OF DIAPHRAGM AND MEDIASTINUM ARE NORMAL.

IMPRESSION: NORMAL CHEST X-RAY.

For, 

DR.MRUDULA BABAR
RADIOLOGIST

Dr. MRUDULA BABAR
DMRE (C.S.) Mumbai 2009
(RADIOLOGIST)
Reg. No. 2005/03/2139

Name: MRS KIRAN PANDEY	Age/sex: 50 Yrs / FEMALE
Ref by: MEDIWHEEL	Date: 20/02/2022

ULTRASOUND EXAMINATION OF ABDOMEN & PELVIS

Findings-

The Liver is normal in size shape and echogenicity. No focal lesion is seen. The Hepatic veins appear normal. There is no IHBR dilatation. The portal vein appears normal.

The gall bladder no visualized – post operative status. The extra hepatic C.B.D. is of normal caliber.

The visualized Pancreas appears normal in size and reflectivity. The pancreatic duct is not dilated. The spleen is normal in size, No focal lesion is seen. Splenic vein is normal at hilum.

Both kidneys are normal in position and size. They show normal cortical reflectivity and cortico-medullary differentiation. There is no evidence of renal calculus, hydronephrosis or mass.

Right kidney measures 9.34 x 4.55 cm

Left kidney measures 10.27 x 4.43 cm

The Urinary bladder is well distended. No evidence of any intraluminal mass or calculi.

Uterus is anteverted post-menopausal status .Endometrial echoes are mid line and measure 5.5 mm. Cervix appears normal.

No adnexal mass lesion noted
No free fluid is noted in abdomen and pelvis .

No probe tenderness seen in present study

IMPRESSION :-

- **Post cholecystectomy status**
- **Rest no significant abnormality is seen in present study.**

Adv: clinical correlation



DR.MRUDULA BABAR
CONSULTANT RADIOLOGIST.

Dr. MRUDULA BABAR
DMRE.CPS Mumbai 2009
(RADIOLOGIST)
Reg. No. 2005/03/2139

