

CITY ULTRASOUND CLINIC

Dr Madkaiker's City hospital
"Ashirwad bldg" 1st floor,
Opp Meenaxi hotel
Isidor Baptista road,
Margao- Goa 403601

Name: MR YESHWANT PRAKASH DESAI
Age: 42 years/M.

Date: 14/4/2023
REF:MEDIWHEEL

ABDOMINAL SONOGRAPHY

LIVER

Liver parenchyma normal size liver
No echogenic or echolucent mass lesion seen.
Intrahepatic branching of hepatic & portal radicles within
Normal limits.
No abscess formation noted. No cyst or hematoma.

GALL-BLADDER:

Well contacted no evidence of biliary calculi.
No free fluid around gall bladder

SPLEEN

: Normal size 11x6x5cms with no any focal lesion.

PANCREAS

: Maintained in its size with normal echotexture. No per pancreatic fluid seen

RIGHT KIDNEY:

Measures 11.56x 6.6 x5mcsms.
Pelvi -calyceal system appears normal.
No hydronephrosis.

LEFT KIDNEY

: Measures 10.59 x6.92 cms.
Echotexture is normal.
No calculus or hydronephrosis noted.

PARA AORTIC REGION

: Appears Normal.
No Probe tenderness over abdomen
No free fluid seen

URINARY BLADDER

: Fully distended

Prostate:

, Normal echotexture vol 13 cc

IMPRESSION:

NORMAL ABDOMEN SCAN.



R. A. Desai
689

SONOLOGIST
CITY HOSPITAL



DENTAL EXAMINATION RECORD

Date: 14/4/23

Name: Yeshwant . P. Desai Age: 42 Sex: M

ORAL HEALTH CONDITION:

Date of Examination				
Age last birthday				
Presence of Debris	<input checked="" type="checkbox"/> Y	<input type="checkbox"/> N	<input type="checkbox"/> Y	<input type="checkbox"/> N
Inflammation of Gingiva	<input checked="" type="checkbox"/> Y	<input checked="" type="checkbox"/> N	<input type="checkbox"/> Y	<input type="checkbox"/> N
Presence of Calculus	<input checked="" type="checkbox"/> Y	<input type="checkbox"/> N	<input type="checkbox"/> Y	<input type="checkbox"/> N
Under Orthodontic Treatment	<input type="checkbox"/> Y	<input checked="" type="checkbox"/> N	<input type="checkbox"/> Y	<input type="checkbox"/> N

Dentofacial Anomaly, Neoplasm, Others, specify:

INITIAL SOFT TISSUE EXAM

<input type="checkbox"/> Lips	<input type="checkbox"/> Floor of Mouth	<input type="checkbox"/> Palate	<input type="checkbox"/> Tongue	<input type="checkbox"/> Neck & Nodes
INITIAL PERIODONTAL EXAM				
GINGIVAL INFLAMMATION:	<input type="checkbox"/> Slight	<input type="checkbox"/> Moderate	<input type="checkbox"/> Severe	
SOFT PLAQUE BUILDUP:	<input type="checkbox"/> Slight	<input type="checkbox"/> Moderate	<input type="checkbox"/> Heavy	
HARD CALC BUILDUP:	<input type="checkbox"/> Light	<input type="checkbox"/> Moderate	<input type="checkbox"/> Heavy	
STAINS:	<input type="checkbox"/> Light	<input type="checkbox"/> Moderate	<input type="checkbox"/> Heavy	
HOME CARE EFFECTIVENESS:	<input type="checkbox"/> Good	<input type="checkbox"/> Fair	<input type="checkbox"/> Poor	
PERIODONTAL CONDITION:	<input type="checkbox"/> Good	<input type="checkbox"/> Fair	<input type="checkbox"/> Poor	
PERIODONTAL DIAGNOSIS:	<input type="checkbox"/> Normal		<input type="checkbox"/> Gingivitis	
PERIODONTITIS:	<input type="checkbox"/> Early	<input type="checkbox"/> Moderate	<input type="checkbox"/> Advanced	
MUCOGINGIVAL DEFECTS:				

CLINICAL DATA:

OCCLUSIO N:	<input checked="" type="checkbox"/> Class 1	<input type="checkbox"/> Class II	<input type="checkbox"/> Class III	
T.M.J. EXAM:	<input checked="" type="checkbox"/> No Pain	<input type="checkbox"/> Popping	<input type="checkbox"/> Deviation	<input type="checkbox"/> Tooth Wear

Tooth Count	T	P	T	P
Number of Teeth Present	32			
Number of Caries Free Teeth	32			
Number of Decayed Teeth	-			
Number of Missing Teeth	-			
Number of Filled Teeth	-			
Total <i>df</i> & DMF Teeth	-			

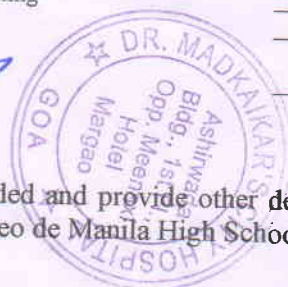
DENTAL/ORAL EXAMINATION REVEALED THE FOLLOWING CONDITIONS AND RECOMMENDATIONS.

- Caries Free
- Poor Oral Hygiene (Materia Alba, Calculus, Stain)
- Indicated for Restoration/Filling
- Indicated for Extraction
- Gingival inflammation
- Needs Oral Prophylaxis

- No Needs Prosthesis (Denture)
- For Endodontic Treatment
- For Orthodontic Consultation
- For Pits and Fissures Sealant Application
- Others
- No Dental Treatment Needed at Present

TO: The Examining Dentist

Please accomplish the treatment needed and provide other dental history of the patient. Kindly sign and send back this form for inspection to the Ateneo de Manila High School Dental Health Services.



Speed : 25 mm/sec

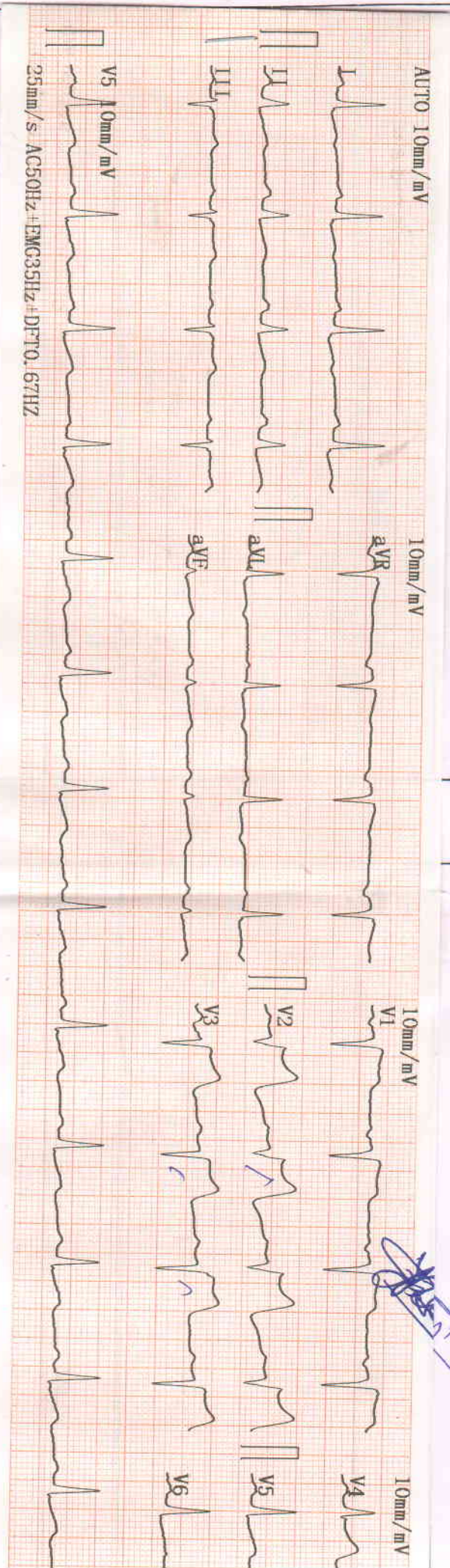
Standardization : 1 cm : 1 mV

I

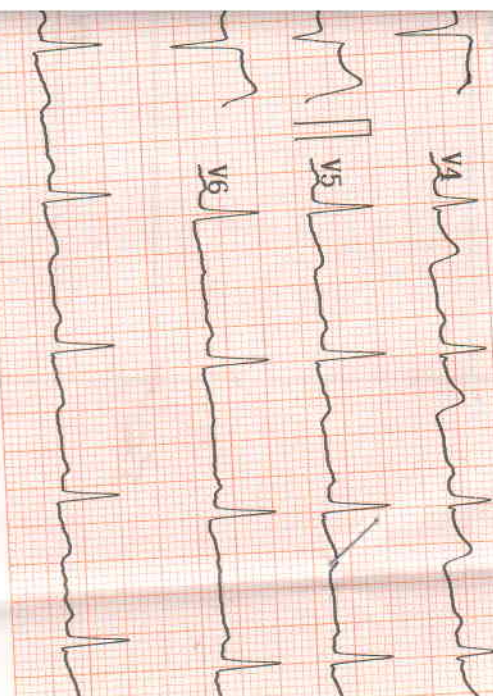
AVR

VI

V4



10mm/mV



2023-04-14 08:53

ID : _____
 Name : yeshwant desai
 Sex : Male Age : 42
 Height : _____ cm Weight : _____ kg
 SYS : _____ mmHg
 DIA : _____ mmHg

HR	bpm	: 74
PR Interval	ms	: 193
P Duration	ms	: 120
QRS Duration	ms	: 68
T Duration	ms	: 200
QT/QTc	ms	: 373/415
P/QRS/T Axis	deg	: 44.8/9.9/108.5
R (V5)/S (V1)	mV	: 0.78/0.79
R (V5) : S (V1)	mV	: 1.57

<< Conclusions >>

Normal Sinus Rhythm;
 Longitudinal left axis deviation;
 ST depression, possible mild anterolateral myocardial ischemia;
 ST depression, mild high lateral myocardial ischemia;
 I aVL V5 V6 Abnormal T wave;

Physician _____

Dr. Madkaikar's

CITYHOSPITAL

2D Echocardiography Study

Date 2023.04.14 Ref No. 2023.04.14.02

Name **Yeshwant Prakkas Desai** Sex **Male** Age **42**
Ref Dep 0 OP No. 0 IP No. 0 Ref Dr. 0
Diagnosis/ ECG Old MI. PTCA. Stenting.

AO cm	2.37	IVSd cm	1.01	LVIDs cm	3.08
LA cm	3.11	LVIDd cm	4.65	LVPWs cm	1.57
EPSS cm	0.73	LVPWd cr	1.06	EF %	62.58
HR /m	74	IVSs cm	1.23	FS %	33.73

Valves Seem Normal

Chambers Seem Normal

Wall Motion Anterior and septal walls mid and apex hypokinetic.

Doppler Gradients across valves seem normal.

Pericardium Seems Normal

Clots / Vegetations Not seen

Comments

Impression **Involvement of Anterior and septal walls.Old MI.**
Well preserved LV systolic function.



J D'Costa
14/4/23

Dr. Terrence D'Costa
M.D., D.N.B.

Dr. Terrence D'Costa
MD, DNB
Reg. No. KMC 23787

CITY LAB
(Clinical laboratory)

Dr Madkaikar's City hospital
"Ashirwad bldg, 1st floor ,
opp meenaxi hotel,
Isidor Baptista road,
Margao- Goa 403601
Ph. : 2714354

Name of Examinee: MR. YESHWANT DESAI

Age: 42yrs Sex: Male

Nationality: Indian

Date of Examination: 14/04/2023

General Examination & Lifestyle

Height: 172cms

Weight: 76 kgs BMI : 25.7

B.P: 130/90 mmHg Diet : Mix

Pulse Rate: 74 per min

Personal H/o: Hypertension & Diabetes since 14yrs

Past/ Family H/o: Diabetes & Hypertension (Mother)

System Examination

CVS: Normal RS : Normal

CNS: Normal

Abdomen: Normal

Others

Hernia: Nil

Varicose Veins: Nil

Extremities: Nil

Deformities: Nil

Skin: Normal

EYE CHECKUP :

- Far Vision : Right Eye- 6/6 Left Eye- 6/6 (With Glasses)
- Near Vision : Right Eye – N/5 Left Eye-N/5 (With Glasses)
- Color Vision: Normal.



Signature and stamp of medical Officer



Dr. R.N. Madkaikar
M.D., D.G.O., D.F.P. C.P.S.
Reg. No. GMC 689
Medical Director

CITY LAB

(clinical laboratory)

Dr Madkaikar's City hospital
"Ashirwad bldg, 1st floor ,
opp meenaxi hotel,
Isidor Baptista road,
Margao- Goa 403601
Ph. : 2714354

NAME: Mr. Yeshwant Desai

42 yrs/M

Date: 14-04-2023

REF. BY: MEDI WHEEL

COMPLETE HAEMOGRAM

		MALE	FEMALE
Haemoglobin	13.7 gm%	(13.0-18)	(11.5-16.5)
PCV	41.0 cc%	(40-50)	(37-47)
ESR(westergren's method)	30 mm/hr	(up to 15)	(up to 20)
R.B.C COUNT	4.4 millions/cmm	(4.5-6.0)	(4.0-5.5)

Erthrocytes Indices

MCH	29 pg	27-32
MCHC	32 %	32-36
MCV	87 cu-microns	82-92
Platelet Count	2,18,000 cells/cmm	(150,000-500,000)
Total W.B.C Count	6,800 /cmm	(4,000-10,000)

Differential Count

Neutrophils	68 %	(50-70)
Lymphocytes	28 %	(20-50)
Eosinophils	02 %	(0-8)
Basophils	00 %	(0-2)
Monocytes	02 %	(0-8)

TEST	RESULT	UNITS	NORMAL RANGE
------	--------	-------	--------------

GLYCOSYLATED HB (HbA1c) (A.B.G – 160.7 mg/dl)	7.2	%	Normal : Up to 6% Good control : 6-7 % Fair control : 7-8 % Unsatisfactory: 8-10 % Poor control : > 10
--	-----	---	--



Dr. Shet Sunayana Sudhir
M.D. (Path.)
Reg. No. GMC 3311
Pathologist/Analyst

CITY LAB

(clinical laboratory)

Dr Madkaikar's City hospital
"Ashirwad bldg, 1st floor ,
opp meenaxi hotel,
Isidor Baptista road,
Margao- Goa 403601
Ph. : 2714354

NAME: Mr. Yeshwant Desai

42 yrs/M

Date: 14-04-2023

REF. BY: MEDI WHEEL

BLOOD BIOCHEMISTRY

TEST	PATIENT'S VALUE	NORMAL RANGE
LFT		
Total Bilirubin	0.9 mg./dL	0.2-1.0 mg./dL
Direct Bilirubin	0.2 mg./dL	0.1-0.2 mg./dL
Indirect Bilirubin	0.7 mg./dL	Up to 0.8 mg/dl
S.G.P.T	34.0 Units/L	0-49 units/L
S.G.O.T	32.0 Units/L	0-46 units/L
Alkaline Phosphatase	196.0 Units/L	108-306 units/L
Total Protein	7.8 gm./dL	6-8 gm.dL
Albumin	4.6 gm./dL	3.5-5.5gm./dL
Globulin	3.2 gm./dL	1.8-3.6gm/dL
A/G	1.4	1.2-2.1
RFT		
Blood Urea	29.0 mg./dL	14-40mg./dL
Serum Creatinine	0.9 mg./dL	0.5-1.4mg./dL
Serum Uric Acid	4.7 mg./dL	M: 2.4-7.0 F: 2.4-6.0mg./dL
BUN	13.5 mg./dl	5-25 mg/dl
BUN/CREATINE	15.0 mg./dl	5-20 mg/d
LIPID PROFILE		
Serum Cholesterol	205.0 mg./dL	25- 260 mg./dL
Serum Triglycerides	146.0 mg./dL	M:60-165 F:40 140mg./dL
HDL Cholesterol	42.0 mg./dL	M:30-63 F: 35- 75 mg./dL
LDL Cholesterol	134.0 mg./dL	Upto 145 mg./dL
Total Chol/HDL Chol Ratio	4.9	2-5
LDL Chol/HDL Chol Ratio	3.2	Up to 3.5

HEMATOLOGY

TEST	PATIENT'S VALUE	REFERANCE RANGE
BLOOD GROUP	'B' Rh- "POSITIVE"	



Dr. Shet Sunayana Sudhir
M.D. (Path.)

Reg. No. GMC 3311
Pathologist/Analyst

CITY LAB
(clinical laboratory)

Dr Madkaikar's City hospital
"Ashirwad bldg, 1st floor ,
opp meenaxi hotel,
Isidor Baptista road,
Margao- Goa 403601
Ph. : 2714354

NAME: Mr. Yeshwant Desai

42 yrs/M

Date: 14-04-2023

REF. BY: MEDI WHEEL

GLUCOSE TEST

Time	Blood Sugar	Urine sugar
'0' Hrs (fasting)	114.0 mg/dl	Absent
2Hrs.after Breakfast	248.0 mg/dl	+

EXAMINATION OF URINE

PHYSICAL EXAMINATION

Colour ... Pale yellow

Odour ... Ammonical

Appearance Clear

pH. 6.5

Sp. Gravity ...1.005

Deposits ...Nil

MICROSCOPIC EXAMINATION

Pus cells/HPF 1-2

R.B.C.s /HPF Nil

Epithelial Cells/HPF ... 1-2

Crystals/HPFNil

Casts/HPFNil

CHEMICAL EXAMINATION

Albumin ... Absent.

Sugar ... Absent

Ketone bodies ...Nil

BilirubinNil

Occult Blood ... Nil

Urobilinogen.... Nil

OTHER FINDINGS : Nil



Dr. Shet Sunayana Sudhir
M.D. (Path.)
Reg. No. GMC 3311

.....
Pathologist/Analyst

PROCESSED AT :**Thyrocare**D-37/1, TTC MIDC, Turbhe,
Navi Mumbai-400 703

Tests you can trust

Corporate office : Thyrocare Technologies Limited, D-37/3, TTC MIDC, Turbhe, Navi Mumbai - 400 703

☎ 022 - 3090 0000 / 6712 3400 📞 9870666333 ✉ wellness@thyrocare.com 🌐 www.thyrocare.com

REPORT

NAME : YESHWANT DESAI (39Y/M)
REF. BY : MEDIWHEEL
TEST ASKED : PSA, T3-T4-TSH

SAMPLE COLLECTED AT :
 (4036018288), CITY LAB, CITY LAB, ASHIRWAD
 BLDG, 1ST FLOOR, OPP. MEENAXI HOTEL, ISIDOR
 BAPTISTA ROAD, MARGAO, GOA, 403601

TEST NAME

PROSTATE SPECIFIC ANTIGEN (PSA)
Reference Range :-

TECHNOLOGY

C.L.I.A

VALUE

0.24

UNITS

ng/mL

Normal : < 4.00 ng/ml

Border line : 4.01 to 10.00 ng/ml

Clinical Significance:

Elevated levels of PSA are associated with prostate cancer, but may also be seen with prostatitis (Inflammation of the prostate) and benign prostatic hyperplasia (BPH). PSA test done along with free PSA provides additional information. Studies have suggested that the percentage of free PSA in total PSA is lower in patients with prostate cancer than those with benign prostate hyperplasia.

Specification:

Precision: Intra assay (%CV): 4.38%, Inter assay (%CV): 4.67%; Sensitivity: 0.01 ng/ml

Kit validation references:

Wang MC, Valenzuela LA, Murphy GP, and Chu TM. Purification of a human prostate-specific antigen. Invest. Urol. 1979; 17: 159

Please correlate with clinical conditions.

Method:- TWO SITE SANDWICH IMMUNOASSAY



Sample Collected on (SCT) : 14 Apr 2023 07:35
Sample Received on (SRT) : 15 Apr 2023 04:41
Report Released on (RRT) : 15 Apr 2023 07:05
Sample Type : SERUM
Labcode : 1404113513/A4884
Barcode : AB488752



[Signature]
 Dr Kuldeep Singh MD(Path)

[Signature]
 Dr Sachin Patil MD(Path)

PROCESSED AT :**Thyrocare**D-37/1, TTC MIDC, Turbhe,
Navi Mumbai-400 703**Thyrocare**

Tests you can trust

Corporate office : Thyrocare Technologies Limited, D-37/3, TTC MIDC, Turbhe, Navi Mumbai - 400 703

☎ 022 - 3090 0000 / 6712 3400 ☎ 9870666333 ✉ wellness@thyrocare.com 🌐 www.thyrocare.com

REPORT

NAME : YESHWANT DESAI (39Y/M)
REF. BY : MEDIWHEEL
TEST ASKED : PSA,T3-T4-TSH

SAMPLE COLLECTED AT :
 (4036018288),CITY LAB,CITY LAB, ASHIRWAD BLDG,
 1ST FLOOR, OPP. MEENAXI HOTEL, ISIDOR BAPTISTA
 ROAD, MARGAO, GOA,403601

TEST NAME	TECHNOLOGY	VALUE	UNITS	REFERENCE RANGE
TOTAL TRIIODOTHYRONINE (T3)	C.L.I.A	49	ng/dL	60-200
TOTAL THYROXINE (T4)	C.L.I.A	2.23	µg/dL	4.5-12
THYROID STIMULATING HORMONE (TSH)	E.C.L.I.A	2.41	µIU/mL	0.54-5.30

Comments : IF NOT ON DRUGS SUGGESTED FT3 & FT4 ESTIMATION**Please correlate with clinical conditions.****Method :**

T3 - Competitive Chemi Luminescent Immuno Assay

T4 - Competitive Chemi Luminescent Immuno Assay

TSH - Fully Automated Electrochemiluminescence Sandwich Immunoassay

Disclaimer :

Results should always be interpreted using the reference range provided by the laboratory that performed the test.
 Different laboratories do tests using different technologies, methods and using different reagents which may cause difference
 In reference ranges and hence it is recommended to interpret result with assay specific reference ranges provided in the reports.
 To diagnose and monitor therapy doses, it is recommended to get tested every time at the same Laboratory.

~~ End of report ~~

**Sample Collected on (SCT)** : 14 Apr 2023 07:35**Sample Received on (SRT)** : 15 Apr 2023 04:41**Report Released on (RRT)** : 15 Apr 2023 07:05**Sample Type** : SERUM**Labcode** : 1404113513/A4884**Barcode** : AB488752

Dr Kuldeep Singh MD(Path)

Dr Sachin Patil MD(Path)

Page : 2 of 3

CITY LAB

(Clinical laboratory)

Dr Madkaikar's City hospital
"Ashirwad bldg, 1st floor ,
opp meenaxi hotel,
Isidor Baptista road,
Margao- Goa 403601
Ph. : 2714354

NAME: Mr. Yeshwant Desai

42 yrs/M

Date: 14-04-2023

REF. BY: MEDI WHEEL

X-RAY Chest PA

Lungs are clear.

Hilar and the mediastinal shadows are normal.

Pleura, the c.p angles are clear.

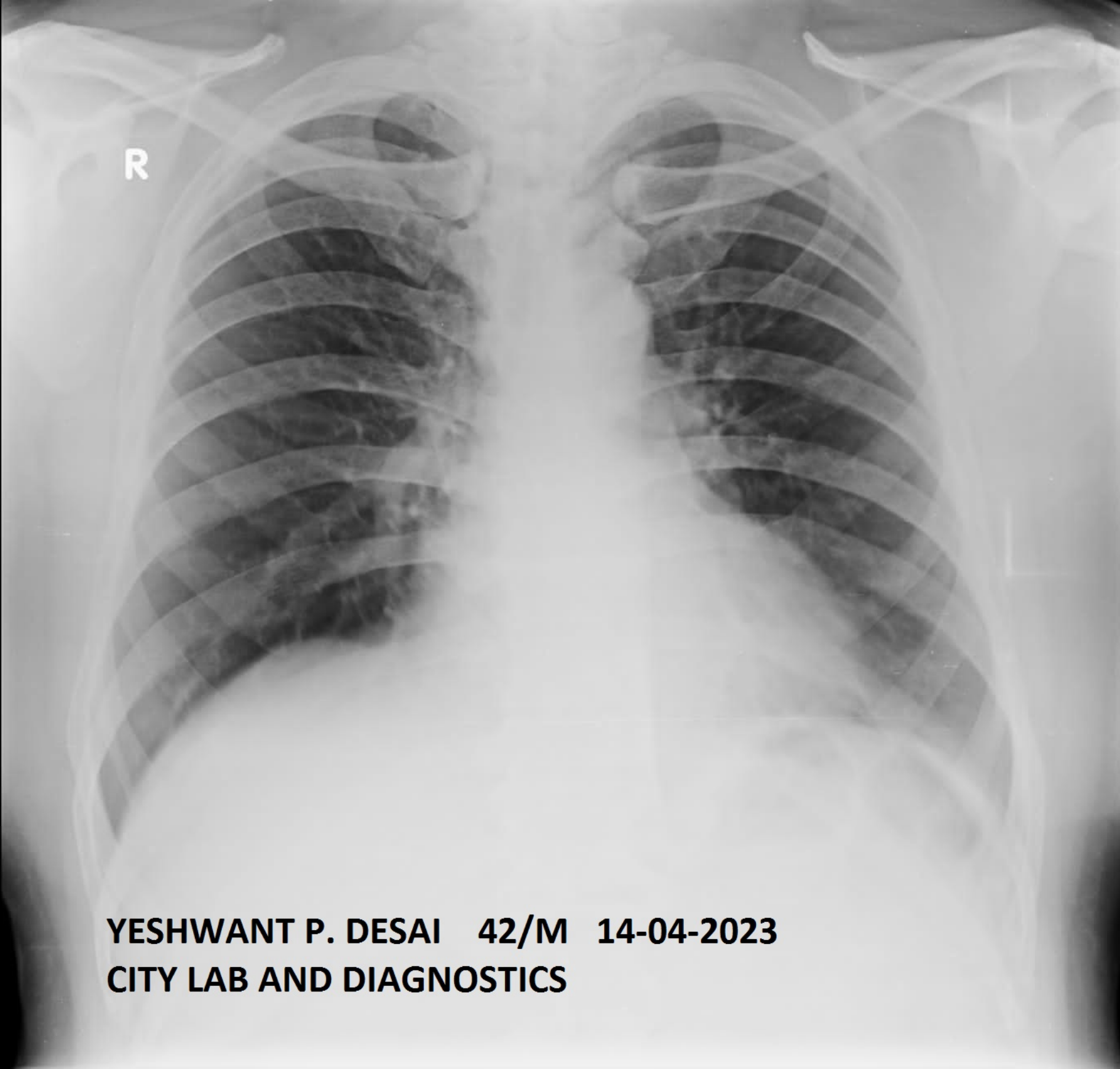
Cardiac aortic Silhouette is normal

Soft tissues of the chest wall and Bony cage are normal.

Impression: Normal



Dr. Francis Almeida
M.B.B.S. D.M.R.D. (BOM) F.C.P.S. (CPS)
Consultant Radiologist
Reg. No. 1553 GMC



YESHWANT P. DESAI 42/M 14-04-2023
CITY LAB AND DIAGNOSTICS