

DR SHISHIR mehe swani

24.12.2022 11:18:16
KRISHNA SUPER SPECIALITY HOSPITAL
PAL ROAD
JODHPUR

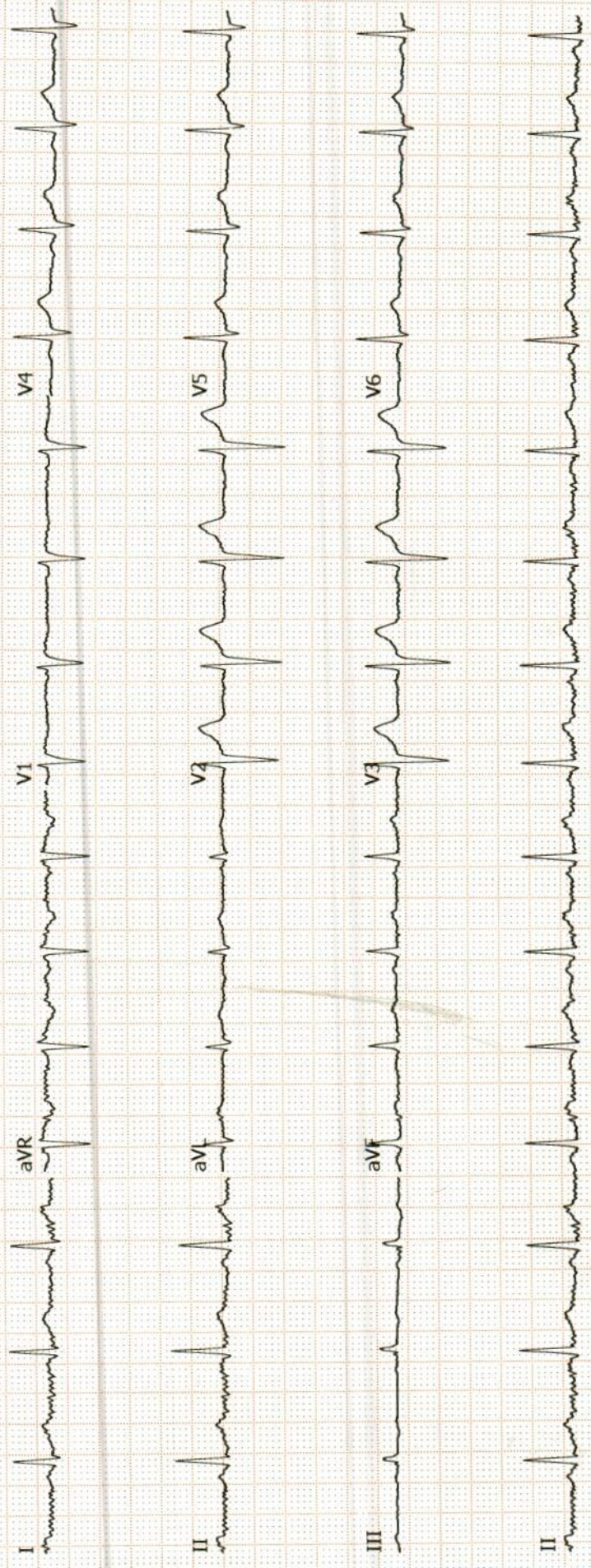
QRS : 80 ms
QT / QTcBaz : 346 / 425 ms
PR : 118 ms
P : 108 ms
RR / PP : 660 / 659 ms
P / QRS / T : 39 / 47 / 37 degrees


Normal sinus rhythm
Normal ECG

Technician:
Ordering Ph:
Referring Ph:
Attending Ph:

Location:
Room:
Order Num:
Indication:
Medication 1:
Medication 2:
Medication 3:

91 bpm
/ / mmHg





Krishna Super Speciality Hospital

10, Shri Krishna Nagar, Nehar Road, Jodhpur (Raj.)342008

Ph: 09799940046, Email: ksshospital28@gmail.com, Web.ksshospital.com



DR. ROOM NO. 102

PT. Name	: MR. SHISHIR MAHESWARI	Date	: 24/12/2022 11:11:04 AM
Age	: 35-0-0 Y/M/D	Sex	: Male
Reg No	: KH27126	Mobile No	: 9001210982
Consultant	: DR. DHRUVA SHARMA	Fees	: 450.00
Department	: CARDIOLOGY	Bill No	: 22-042392
OPD NO	: 81	Receipt Time	: 11:11AM
Address	: NEAR MINERVA CENTER SOJATI GATE	User Name	: KANCHAN
Doc No	: 9829803663		

Diagnosis :-

B.P - 130/90 mmHg
P - 89 bpm
SpO2 - 97%
W - 113 Kg

Investigation :-

F/H CD
DM⁰
HT⁰
Ches⁺
Sharma

Shishir Maheswari
Sharma

Krishna Super Speciality Hospital

(A Unit of CNG Super Speciality Hospital P. Ltd.)

10, Shri Krishna Nagar, Nehar Road, Jodhpur (Raj.) 342 008

Ph.: 0291-2711004 Call # 09799940046 E-mail:Ksshospital28@gmail.com



Krishna Super Speciality Hospital

(A Unit of CNG Super Speciality Hospital P. Ltd.)



Echocardiography Report

Mr. Shishir Maheshari

Age/Sex: 35 Yrs / Male

Date: - 24.12.2022

Clinical History: - R/D SHD

Reg. No KH - 27126

Procedure (Routine/ Emergency): - Routine Test

Consultant Doctor: - Dr. Dhruva Sharma

Tech.: - Siraj

Right Atrium normal in size

Tricuspid Valve normal Morphology

Right Ventricle normal in size & normal function

Pulmonary Valve normal Morphology, Normal MPA

Mitral Valve normal Morphology

Left Atrium normal in size

LV normal in size & Normal LV Function

Aortic Valve normal.

Aortic Arch / IVC normal. **No Coarctation of Aorta**

Pericardium normal

IAS intact

IVS intact

**Impression: Normal LV function, LVEF = 60%, No RWMA, Mild Concentric LVH.
No Clot / Vegetation / Pericardial Effusion.**

Consultant Cardiologist:


Dr. Dhruva Sharma

MD, DM (Cardiology)

Consultant & Interventional Cardiologist
Contact No. 9829803663

Dr. Rakesh Choudhary

MD, DM (Cardiology)

Consultant & Interventional Cardiologist
Contact No. 8130490516

Dr. D.P. Suthar

MD, DNB (Cardiology)

Consultant & Interventional Cardiologist
Contact No. 7597945325



Krishna Super Speciality Hospital



(A Unit of CNG Super Speciality Hospital P. Ltd.)

Measurements:

	PATIENT VALUES				NORMAL VALUES (cm)
	(cm)				
Aortic Root Diameter	3.3				2.0 - 3.7
Aortic Valve Opening	2.0				1.5 - 2.6
Right Ventricle Dimension					2.0 - 2.8
Right Atrial Dimension					2.9 - 4.5
Left Atrial Dimension	3.6				1.9 - 4.0
Left Ventricle ED Dimension	4.4				3.7 - 5.6
Left Ventricle ES Dimension	3.0				2.2 - 4.0
Inter Ventricle Septal Thickness	ED	1.3	ES	1.5	0.6 - 1.2
Left Ventricle PW Thickness	ED	1.3	ES	1.5	0.5 - 1.0
LV EJECTION FRACTION	60%				(N) 60 ± 6.5%

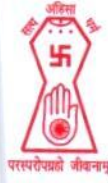Doppler & Color Flow

Aortic valve (Native)			
Max/Mean Velocity	1.3 cm/sec	Aortic Stenosis	Nil
Max/Mean PG	6.68 mmHg	Aortic Regurgitation	Nil

Mitral valve (Native)			
MV E/A Velocity	70/50 cm s	MV dt E	M sec
Max/Mean Velocity	cm/sec	Mitral Stenosis	Nil
Max/Mean PG	mmHg	Mitral Regurgitation	Trace
MVA Planimetry	cm ²	Prosthetic Valve	Nil
MVA PHT	cm ²	Valvular / Paravalvular:	

Tricuspid valve (Native)			
Max / Mean Velocity	0.56 cm/sec	Tricuspid Stenosis	Nil
Max / Mean PG	1.24 mmHg	Tricuspid Regurgitation	Trace
PAH		PASP	27 mmHg

Pulmonary valve (Native)			
Max / Mean Velocity	1.12 cm/sec	Pulmonary Stenosis	Nil
Max / Mean PG	5.0 mmHg	Pulmonary Regurgitation	Nil
RV Diastolic	Cm/sec	Mean PADP	mmHg



Shishir Maheshwari / 13234 / 24.12.2022
Ref by: Dr. Nand Kishore Chhangani

Transabdominal sono screening scan – whole abdomen

Extensive bowel gases precluded optimal examination.

Hepato-biliary system:

Liver is enlarged in size. Hepatic parenchymal echotexture is bright, homogenous and uniform. No focal lesion seen. Intrahepatic biliary radicles are not dilated. Portal vein and cbd are normal in caliber. Gall bladder is seen in normal distension. Walls are normal in thickness and are smooth. No mass is seen. Lumen is anechoic. Pancreas is normal in size and echotexture. Pancreatic duct is not dilated. No area of calcification is seen in pancreas.

Uro-genital system:

Both the kidneys are normal in size. Parenchymal echotexture is normal. Corticomedullary differentiation is maintained. Central echo-complexes are normal. Urinary bladder is seen in full distension. Walls are smooth and normal in thickness. Lumen is anechoic. Prostate is normal in size measuring approx 29 x 28 x 24 mm vol 10 cm³. Prostatic echotexture is normal. Contours are normal. No obvious mass is seen.

Spleen & retroperitonium:

Spleen is normal in size. Parenchymal echotexture is normal. Most of the retroperitonium is not seen clearly, obscured by bowel gases.

No ascites seen.

Sonographic findings are suggestive of:-

- Hepatomegaly with fatty changes grade – I.

This is only professional opinion based on imaging finding and not the diagnosis
It should be correlated clinically, to arrive at proper conclusion.

Dr. Rakesh Middha

M.D.

Consultant Radiologist
[R.M.C. No 017628]

SHISHIR
E33942 22 12 24 1

ROG JANCH SEWA, JODHPUR

Tis 0.1 24.12.2022
Tib 0.1 10:27:58 AM
MI 1.0 C1 6 D
22Hz/16.3cm
65/71.2
Abd Sharp/ABD
Hi M P 6.50 - 4.30
Gn 8
C7/M4
F1/1/2

1 D1 2.46cm
2 D2 2.96cm
3 D3 2.81cm
Vol 10.714cm³

SHISHIR
E33942 22 12 24 1

ROG JANCH SEWA, JODHPUR

Tis 0.1 24.12.2022
Tib 0.1 10:28:14 AM
MI 1.0 C1 6 D
22Hz/16.3cm
65/71.2
Abd Sharp/ABD
Hi M P 6.50 - 4.30
Gn 8
C7/M4
F1/1/2

SHISHIR
E33942 22 12 24 1

ROG JANCH SEWA, JODHPUR

Tis 0.2 24.12.2022
Tib 0.2 10:28:31 AM
MI 0.9 C1 6 D
24Hz/21.1cm
65/71.3
Hi Penetration/ABD
P 6.10 - 4.50
Gn 15
C7/M4
F1/1/2

SHISHIR
E33942 22 12 24 1

ROG JANCH SEWA, JODHPUR

Tis 0.2 24.12.2022
Tib 0.2 10:28:46 AM
MI 0.9 C1 6 D
24Hz/21.1cm
65/71.3
Hi Penetration/ABD
P 6.10 - 4.50
Gn 15
C7/M4
F1/1/2

SHISHIR
E33942 22 12 24 1

ROG JANCH SEWA, JODHPUR

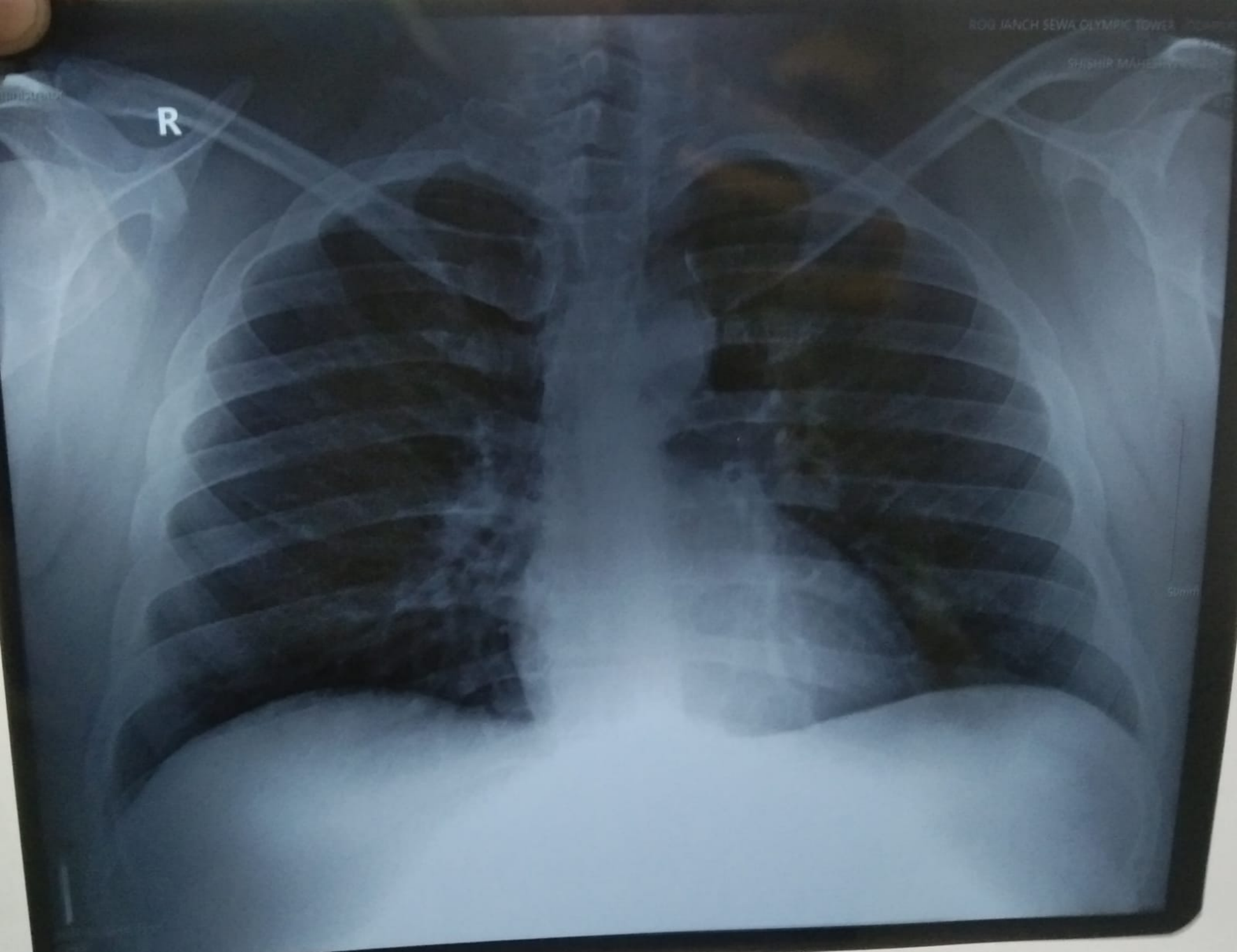
Tis 0.2 24.12.2022
Tib 0.2 10:29:07 AM
MI 0.9 C1 6 D
24Hz/21.1cm
65/71.3
Hi Penetration/ABD
P 6.10 - 4.50
Gn 20
C7/M4
F1/1/2

SHISHIR
E33942 22 12 24 1

ROG JANCH SEWA, JODHPUR

Tis 0.2 24.12.2022
Tib 0.2 10:29:39 AM
MI 0.9 C1 6 D
24Hz/21.1cm
65/71.3
Hi Penetration/ABD
P 6.10 - 4.50
Gn 15
C7/M4
F1/1/2

R



5cm

Issue Date: 15/06/2015



भारत सरकार
Government of India



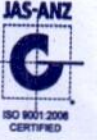शिशिर माहेश्वरी
Shishir Maheshwari
जनम तिथि/DOB: 21/01/1987
लिंग/ GENDER: MALE



VID : 9117 6185 6185 6332
4706
भारत आयोग, भारत सरकार

Handwritten signature

Case
Dr. Nand Kishore Chhangani
MD-Physician
RMC No.-20
JCUr-UR
Handwritten signature



MEDICAL CERTIFICATE

NAME : SHISHIR MAHESHWARI
AGE/SEX: 35 Yrs/MALE

DATE-24-12-2022

HEIGHT-172CMS
BP -126/24

WEIGHT-113KG
PULSE- 70

BMI- 38.20

EYE SIGHT- BOTH EYESIGHT NORMAL.
NORMAL COLOUR VISION.

TEETH AND GUMS ARE HEALTHY.

THIS IS TO CERTIFY THAT MR. SHISHIR MAHESHWARI IS MEDICALLY & PHYSICALLY FIT & FINE FOR PERFORMING ALL TYPE OF PROFESSIONAL WORK.

Dr. N. K. Vishore Chitambar
MD-Physician & Radiologist
RMC No.-2017
JCOUR

ई.सी.जी. | डिजिटल एक्सरे | टी. एम. टी. | ई. ई. जी. | ई. एम. जी. | एन. सी. वी. | बेरा | पी. एफ. टी. | ऑडियोमैट्री

ब्रह्म बाग, पुष्पक कोरियर के पास, इंदगाह रोड, जालोरी गेट, जोधापुर (राज.)

फोन : 0291-2620214 E-mail : srdmedical@gmail.com

THIS REPORT IS NOT VALID FOR MEDICO LEGAL PURPOSES



SRD
X-RAY CHEST PA-VIEW
Complete Diagnostic Solution



NAME : SHISHIR MAHESHWARI
REF. BY: BANK OF BARODA

AGE-35

SEX : MALE

DATE : 24-12-2022

BOTH LUNG -

PARENCHYMA.

BOTH C.P ANGLES -

NORMAL.

CARDIAC SHADOW IS WITHIN -

NORMAL LIMITS.

DOMES OF DIAPHRAGM -

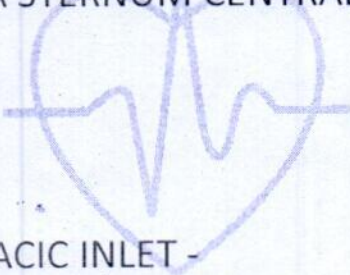NORMAL.

BONY CAGE -

NORMAL.

MEDIA STERNUM CENTRAL

./L./



SRD

THORACIC INLET -

NORMAL.

Complete Diagnostic Solution

IMPRESSION :-

NORMAL CHEST PA-VIEW.

Dr. Rakesh Gaur
M.D. Radiology
R.M.C. NO. 5698

DR. RAKESH GAUR (M.D)

(RADIO LOGIST) R.M.C NO. 5698

ई.सी.जी. | डिजिटल एक्सरे | टी. एम. टी. | ई. ई. जी. | ई. एम. जी. | एन. सी. बी. | बेरा | पी. एफ. टी. | ऑडियोमैट्री

ब्रह्म बाग, पुष्पक कोरियर के पास, इंदगाह रोड़, जालोरी गेट, जोधपुर (राज.)

फोन : 0291-2620214 E-mail : srdmedical@gmail.com

THIS REPORT IS NOT VALID FOR MEDICO LEGAL PURPOSES



Client Name	Mr SHISHIR MAHESHWARI	Sex/Age	35 Year / Male
IC Name	REF By.	TPA Name	
Date	24 Dec 2022	Lab No.	18361
Reporting Date	24 Dec 2022	Remark	

Test Name	Result	Unit	Ref-Range
-----------	--------	------	-----------

HEMATOLOGY

Glycosylated Hemoglobin (HbA1C)	5.3	%	- %
ABG(Average Blood Glucose)	105.41	MG/DL	- MG/DL

Methodology: Ion exchange H.P.L.C. Using instrument: D-10 with EDTA

Hemoglobin A1C % Degree of Glucose Control

> 8	Action suggested
<7	Goal
< 6	Non – Diabetic level

Clinical Information:

Glycated hemoglobin testing is recommended for both (a) checking blood sugar control in people who might be pre – diabetic and (b) monitoring blood sugar control in patients with more elevated levels, termed diabetes mellitus. The American diabetes association guidelines suggest that the Glycosylated hemoglobin test be performed at least two times a year in patients with diabetes that are meeting treatment goals (and that have stable glycemic control) and quarterly in patients with diabetes whose therapy has changed or that are not meeting glycemic goals. Glycated hemoglobin measurement is not appropriate where there has been a change in diet or treatment within 6 weeks. Hence, people with recent blood loss, hemolytic anemia, or genetic differences in the hemoglobin molecule (hemoglobinopathy) such as sickle-cell disease and other conditions, as well as those that have donated blood recently are not suitable for this test.

*****End Of Reports*****

BIO - CHEMISTRY

BUN/SR.CREATININE RATIO	19.08	Ratio	6-25 Ratio
-------------------------	-------	-------	------------

*****End Of Reports*****

TECHNOLOGIST	Lab. INCHARGE	PATHOLOGIST
--------------	---------------	-------------

Dr. Pankaj Malhotra
MD - Pathology
RMC No. 1977

ई.सी.जी. | डिजिटल एक्सरे | टी. एम. टी. | ई. ई. जी. | ई. एम. जी. | एन. सी. वी. | बेरा | पी. एफ. टी. | ऑडियोमैट्री

ब्रह्म बाग, पुष्पक कोरियर के पास, ईदगाह रोड, जालोरी गेट, जोधापुर (राज.)

फोन : 0291-2620214 E-mail : srdmedical@gmail.com

THIS REPORT IS NOT VALID FOR MEDICO LEGAL PURPOSES



SRD

Complete Diagnostic Solution



Client Name	Mr SHISHIR MAHESHWARI	Sex/Age	35 Year / Male
IC Name	REF By.	TPA Name	
Date	24 Dec 2022	Lab No.	18361
Reporting Date	24 Dec 2022	Remark	

Test Name	Result	Unit	Ref-Range
-----------	--------	------	-----------

HEMATOLOGY

COMPLETE BLOOD COUNT

HAEMOGLOBIN	L <u>12.8</u>	GM%	13-18 GM%
TOTAL LEUCOCYTE COUNT	7500	/Cumm	4000-11000 /Cumm

DIFFERENTIAL LEUCOCYTE COUNT

PLOYMORPHS	65.7	%	40-70 %
LYMPHOCYTES	28.9	%	20-40 %
EOSINOPHILS	2.4	%	0-6 %
MONOCYTES	3.0	%	0-8 %
BASOPHILES	00	%	0-2 %
RBC	4.13	Lakh/Cumm/	3.5-5.5 Lakh/Cumm/
PLATELETS COUNT	2.10	Lakh/Cumm	1.5-4 Lakh/Cumm
HCT	39.4	%	34-48 %
MCV	95.40	fl	30-100 fl
MCH	30.99	pg	27-32 pg
MCHC	32.49	g/dl	32-36 g/dl
ESR	16	mm/1Hrs	0-20 mm/1Hrs
ABO RH-FACTOR	B (+) POSITIVE		

*****End Of Reports*****

TECHNOLOGIST

Lab. INCHARGE

PATHOLOGIST

Dr. K. Malhotra
MD - Pathology
RMC No. 177

ई.सी.जी. | डिजीटल एक्सरे | टी. एम. टी. | ई. ई. जी. | ई. एम. जी. | एन. सी. वी. | बेरा | पी. एफ. टी. | ऑडियोमैट्री

ब्रह्म बाग, पुष्पक कोरियर के पास, इंदगाह रोड, जालोरी गेट, जोधापुर (राज.)

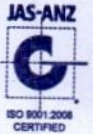फोन : 0291-2620214 E-mail : srdmedical@gmail.com

THIS REPORT IS NOT VALID FOR MEDICO LEGAL PURPOSES



SRD

Complete Diagnostic Solution



Client Name	Mr SHISHIR MAHESHWARI	Sex/Age	35 Year / Male
IC Name	REF By.	TPA Name	
Date	24 Dec 2022	Lab No.	18361
Reporting Date	24 Dec 2022	Remark	

Test Name	Result	Unit	Ref-Range
-----------	--------	------	-----------

BIO-CHEMISTRY

BLOOD SUGAR (F)	96.3	mg/dl	60-110 mg/dl
BLOOD SUGAR *	136.2	mg/dl	60-160 mg/dl
SERUM CREATININE	1.01	mg/dl	0.6-1.4 mg/dl
SERUM URIC ACID	5.2	mg%	3-6.5 mg%
LIPID PROFILE			
CHOLESTEROL	180.3	mg/dl	130-250 mg/dl
TRIGLYCERIDES	H <u>200.1</u>	mg/dl	60-170 mg/dl
HDL-CHOLESTEROL	45.50	mg/dl	30-70 mg/dl
LDL-CHOLESTEROL	94.78	mg/dl	65-160 mg/dl
VLDL	H <u>40.02</u>	mg/dl	0-35 mg/dl
CHO/HDL RATIO	3.96	mg/dl	3.8-5.8 mg/dl
LDL/HDL RATIO	2.08	Ratio	1.5-3.5 Ratio
LIVER FUNCTION TEST			
BILIRUBIN (TOTAL)	0.69	mg/dl	0.3-1.3 mg/dl
BILIRUBIN (DIRECT)	0.20	mg/dl	0-0.3 mg/dl
BILIRUBIN (IN-DIRECT)	0.49	mg/dl	0.1-0.9 mg/dl
SGOT (AST)	37.3	Units/Lit	5-40 Units/Lit
SGPT (ALT)	31.6	Units/Lit	5-40 Units/Lit
ALKALINE PHOSPHATSE	87.0	Units/Lit	65-306 Units/Lit
TOTAL.PROTEIN	6.95	g/dl	6.1-8.6 g/dl
ALBUMIN	4.10	g/dl	3.5-5 g/dl
GLOBULIN	2.85	mg/dl	2.3-3.5 mg/dl
A/G RATIO	1.44 : 1	mg/dl	1-2.3 mg/dl
GGT	30	IU/L	4-54 IU/L
BUN	20	mg/dl	12-40 mg/dl

*****End Of Reports*****

TECHNOLOGIST	Lab. INCHARGE	PATHOLOGIST
--------------	---------------	-------------

Dr. V. K. Malhotra
Pañ & Micro.
977

ई.सी.जी. | डिजीटल एक्सरे | टी. एम. टी. | ई. ई. जी. | ई. एम. जी. | एन. सी. वी. | बेरा | पी. एफ. टी. | ऑडियोमैट्री

ब्रह्म बाग, पुष्पक कोरियर के पास, ईदगाह रोड, जालोरी गेट, जोधापुर (राज.)

फोन : 0291-2620214 E-mail : srdmedical@gmail.com

THIS REPORT IS NOT VALID FOR MEDICO LEGAL PURPOSES



SRD

Complete Diagnostic Solution



Client Name	Mr SHISHIR MAHESHWARI	Sex/Age	35 Year / Male
IC Name	REF By.	TPA Name	
Date	24 Dec 2022	Lab No.	18361
Reporting Date	24 Dec 2022	Remark	

Test Name	Result	Unit	Ref-Range
-----------	--------	------	-----------

URINE EXAMINATION REPORT

PHYSICAL EXAMINATION

COLOUR	YELLOW	-
REACTION	ACIDIC	-
PH	6.5	+
DEPOSITE	ABSENT	-
APPEARANCE	CLEAR	-

CHEMICAL EXAMINATION

ALBUMIN	ABSENT	-
SUGAR	ABSENT	-
BILE SALTS	ABSENT	-
KITONES	ABSENT	-
SPEC GRAV	1.030	-

MICROSCOPIC EXAMINATION

PUS CELLS	NIL	-
RBCs CELLS	NIL	-
EPITHELIAL CELLS	0-1	-
CASTS	NIL	-
CRYSTAL :-	NIL	+
BACTERIA	NIL	-

*****End Of Reports*****

TECHNOLOGIST

Lab. INCHARGE

PATHOLOGIST

ई.सी.जी. | डिजिटल एक्सरे | टी. एम. टी. | ई. ई. जी. | ई. एम. जी. | एन. सी. वी. | बेरा | पी. एफ. टी. | ऑडियोमैट्री

* ब्रह्म बाग, पुष्पक कोरियर के पास, ईदगाह रोड़, जालोरी गेट, जोधापुर (राज.)

फोन : 0291-2620214 E-mail : srdmedical@gmail.com

THIS REPORT IS NOT VALID FOR MEDICO LEGAL PURPOSES



SRD

Complete Diagnostic Solution



Client Name	Mr SHISHIR MAHESHWARI	Sex/Age	35 Year / Male
IC Name	REF By.	TPA Name	
Date	24 Dec 2022	Lab No.	18361
Reporting Date	24 Dec 2022	Remark	

Test Name	Result	Unit	Ref-Range
-----------	--------	------	-----------

HARMONES

THYROID PROFILE

T3	0.96	ng/ml	0.6-1.81 ng/ml
T4	6.14	ug/dl	4.5-12.6 ug/dl
TSH	1.20	uIU/ml	0.35-5.5 uIU/ml

Interpretation of TSH :

Kindly correlate with age & clinical findings.

Biological reference range:

Children: Pregnancy:

1 - 2 days 3.20 - 34.6 uIU/ml 1st Trimester : 0.10 - 2.50

3 - 4 days 0.70 - 15.4 uIU/ml 2nd Trimester : 0.20 - 3.00

15 days - 5 mths 1.70 - 9.10 uIU/ml 3rd Trimester : 0.30 - 3.00

5 mths - 20 yrs 0.70 - 6.40 uIU/ml

Primary malfunction of the thyroid gland may result in excessive (hyper) or low(hypo) release of T3 or T4.

In additional, as

TSH directly affect thyroid function, malfunction of the pituitary or the hypothalamus influences the thyroid gland

activity. Disease in any portion of the thyroid-pituitary-hypothalamus system may influence the level of T3 and T4 in the

blood, in Primary hypothyroidism, TSH levels are significantly elevated, while in secondary and tertiary hypothyroidism, TSH

levels may be low. In addition, in Euthyroid sick Syndrom, multiple alterations in serum thyroid function test findings have been recognized.

*****End Of Reports*****

TECHNOLOGIST	Lab. INCHARGE	PATHOLOGIST
--------------	---------------	-------------

Dr. V. Malhotra
MD - Pathology
RMC No. : 97

ई.सी.जी. | डिजीटल एक्सरे | टी. एम. टी. | ई. ई. जी. | ई. एम. जी. | एन. सी. वी. | बेरा | पी. एफ. टी. | ऑडियोमैट्री

ब्रह्म बाग, पुष्पक कोरियर के पास, ईदगाह रोड, जालोरी गेट, जोधापुर (राज.)

फोन : 0291-2620214 E-mail : srdmedical@gmail.com

THIS REPORT IS NOT VALID FOR MEDICO LEGAL PURPOSES



Pt Name : SHISHIR MAHESHWARI
Ref By. : Dr.
Serial No : 15911

Age : 35
Sex : Male
Date : 24/12/2022

URINE EXAMINATION REPORT

Test	Result(s)
CHEMICAL	
SUGAR - (F)	NIL
SUGAR - (PP)	NIL

[ TECHNOLOGIST]

_____ END OF REPORT _____

Dr. Y. K. Malhotra
MD - Micro.
RMC No. 1577
[PATHOLOGIST]



ई.सी.जी. | डिजिटल एक्सरे | टी. एम. टी. | ई. ई. जी. | ई. एम. जी. | एन. सी. वी. | बेरा | पी. एफ. टी. | ऑडियोमैट्री

ब्रह्म बाग, पुष्पक कोरियर के पास, ईदगाह रोड़, जालोरी गेट, जोधापुर (राज.)

फोन : 0291-2620214 E-mail : srdmedical@gmail.com

THIS REPORT IS NOT VALID FOR MEDICO LEGAL PURPOSES



Pt Name : SHISHIR MAHESHWARI
Ref By. : Dr.
Serial No : 15911

Age : 35
Sex : Male
Date : 24/12/2022


STOOL EXAMINATION REPORT

Test	Result
PHYSICAL	
COLOUR	BLACK
CONSISTENCY	SEMI SOLID
MICROSCOPIC	
PUS CELLS	NIL
RED BLOOD CELLS	NIL
EPITHELIAL CELLS	NIL
UNDIGESTED MATTER	NIL
CELLULAR MATTER	NIL
BACTERIAL FLORA	NORMAL
HELMINTHIC OVA	NIL
PROTOZOA	NIL

[TECHNOLOGIST]

END OF REPORT

[PATHOLOGIST]

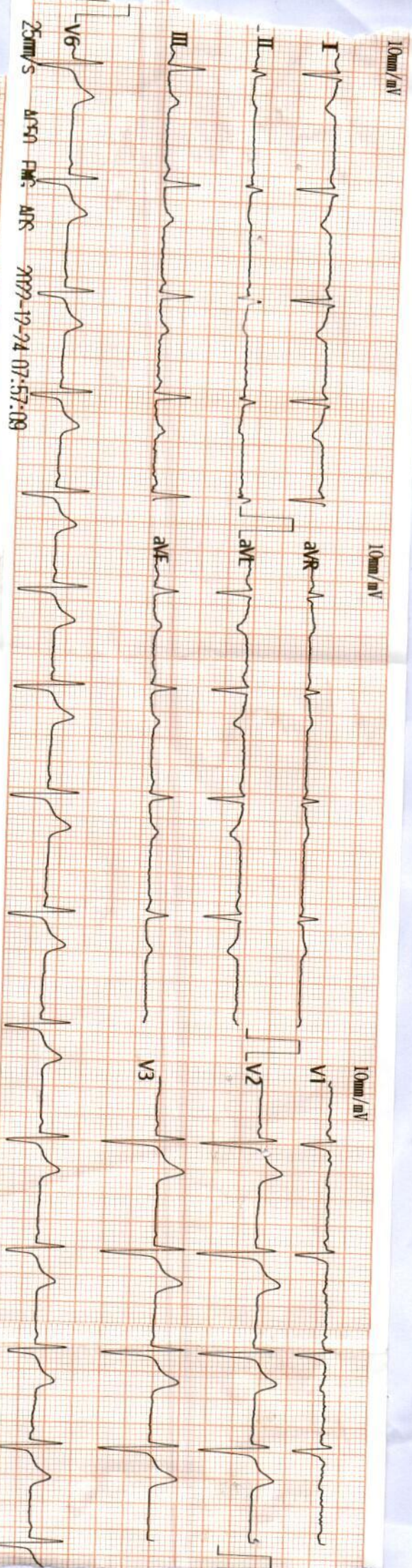


ई.सी.जी. | डिजिटल एक्सरे | टी. एम. टी. | ई. ई. जी. | ई. एम. जी. | एन. सी. वी. | बेरा | पी. एफ. टी. | ऑडियोमैट्री

ब्रह्म बाग, पुष्पक कोरियर के पास, ईदगाह रोड़, जालोरी गेट, जोधपुर (राज.)

फोन : 0291-2620214 E-mail : srdmedical@gmail.com

THIS REPORT IS NOT VALID FOR MEDICO LEGAL PURPOSES



Shishir Maheshwari

24/12/22

Vent. Rate(BPM) : 76
PR Int.(ms) : 108
P/QRS/T Int.(ms) : 71 108 166
QT/QTc Int.(ms) : 365 414
P/QRS/T Axis(Deg.) : 124 133 139
RV1/SV5 Amp.(mV) : 0.10 0.63
RV5/SV1 Amp.(mV) : 0.56 0.49

V2.33 Technician :

- <ECG Analysis Result>:
- 803 Sinus Arrhythmia
 - 401 Short P-R Interval
 - 612 T Abnormality(Negative T)
 - 121 Clockwise Rotation
 - 220 Marked Right Axis Deviation
 - *** Abnormal ECG ***

Note: Unconfirmed Report, Needs Review.

Dr. Nand Lal Joshi
MD-Physician & Cardiologist
KMGH-DOS-1001
Jodhpur

[Signature]
989900004976

cm/kg mHg