

Name : Mr. PARSHURAM D PAVALE (38/M)
E apollo@ashik@apollohospitals.com

Date 09/08/2022

Address : AAI NIVAS SAI NAGAR MERI LINK ROAD BEHIND SAISHIV NAGAR AMRUTDHAM
NASHIK, NASHIK, NASHIK, MAHARASHTRA, INDIA



Examined by:

UHID : MHN1.0000124076

Package : MediWheel Full Body Health Checkup Male Below 40
Package

AHC No : NSKAH27277

CHIEF COMPLAINTS

For corporate health checkup
No specific complaints

DRUG ALLERGY

NO KNOWN ALLERGY :10/08/2022

SYSTEMIC REVIEW

Cardiovascular system
- Nil Significant

Past medical history

Do you have any allergies? - No
Do you have any drug allergies? - No
Past medical history - nil significant
Covid 19 - No

Surgical history

Surgical history - Nil

Personal history

Marital status - Married
No. of children - 2
Diet - Vegetarian
Alcohol - does not consume alcohol
Smoking - No
Chews tobacco - No
Chews paan - No
Uses snuff - No
Illicit substance use - No
Physical activity - Active

Family history

Father - alive
Aged - 65 yrs
Mother - has expired
Aged - 36 yrs
Cause - accident
Coronary artery disease - none
Cancer - None

PHYSICAL EXAMINATION

General

General appearance - normal
Build - normal
Height - 167 Cm
Weight - 55.5 Kg
BMI - 19.9
Pallor - No
Oedema - no
Temperature - 96.3
SpO2 - 98

Cardiovascular system


Heart rate (Per minute) - 73
Rhythm - Regular
- B.P. Supine
Systolic(mm of Hg) - 100
Diastolic(mm of Hg) - 70
Heart sounds - S1S2+

Swaminarayan Nagar, Off Mumbai-Agra Highway,
Panchvati, Nashik - 422 003.

+91- 253 - 2510250 / 350 / 450 / 550 / 750

apollonashik@apollohospitals.com
www.askapollo.com

QFAHN/BILL/003/V1



Date : 09/08/2022

AHC No : NSKAH27277

Name : Mr. PARSHURAM D PAVALE (38 / M) UHID : MHN1.0000124076

Package : MediWheel Full Body Health Checkup Male Below 40 Package

Respiratory system

Breath sounds - Normal vesicular breath sounds

Abdomen

Organomegaly - No

Tenderness - No



Printed By : Shweta Sharad Shardul

Name : Mr. PARSHURAM D PAVALE (38 Y/M)

Package : MediWheel Full Body Health Checkup Male Below 40 Package

C B C WITH ESR (AUTOMATION + STANDARD METHOD)

Test Name	Result	Unit	Level	Range
Hemoglobin	16.9	g/dl	●	13.0-18.0
Haematocrit	52.4	%	●	39.0-54.0
RBC COUNT	5.4	Million/ ul	●	4.2-6.5
MCV	97.3 *	fl	●	75.0-95.0
MCH	31.4	pg	●	26.0-32.0
MCHC	32.3	g/dl	●	31.0-36.0
RDW	14.6	%	●	11-16
Platelet Count(Optical/Impedance)	382	10 ³ /m ³	●	140-440
TLC Count	7.0	10 ³ /m ³	●	4.0-11.0
Neutrophils	53	%	●	45-75
Lymphocytes	39	%	●	20-45
Eosinophils	02	%	●	1-6
Monocytes	06	%	●	1-10
Basophils	00	%	●	0-1
ERYTHROCYTE SEDIMENTATION RATE (ESR)	04	mm/1st hr	●	0-10

BLOOD GROUPING AND TYPING (ABO and Rh)

Test Name	Result	Unit	Level	Range
ABO Group:	O			
Rh (D) Type:	POSITIVE			

LIVER FUNCTION TEST (PACKAGE)

Test Name	Result	Unit	Level	Range
ALT(SGPT) - SERUM / PLASMA	28 *	U/L	●	30-65
ALBUMIN - SERUM	4.9	g/dL	●	3.5-5
ALKALINE PHOSPHATASE - SERUM/PLASMA	76	U/L	●	0-100
AST (SGOT) - SERUM	44 *	U/L	●	15-37
BILIRUBIN, TOTAL - SERUM	2.2 *	mg/dL	●	0.0-1.0

LIPID PROFILE TEST (PACKAGE)

Test Name	Result	Unit	Level	Range
Total Cholesterol	195	mg/dL	●	0-200

CREATININE - SERUM / PLASMA

Test Name	Result	Unit	Level	Range
CREATININE - SERUM / PLASMA	1.0	mg/dL	●	0.8-1.3

LIVER FUNCTION TEST (PACKAGE)

Test Name	Result	Unit	Level	Range
GGTP: GAMMA GLUTAMYL TRANSPEPTIDASE - SERUM	68 *	U/L	●	0-50

GLUCOSE - SERUM / PLASMA (FASTING)

Test Name	Result	Unit	Level	Range
Glucose - Plasma (Fasting)	104 *	mg/dL	●	70-100
URINE GLUCOSE(FASTING): (Strip Method)	Nil			

GLUCOSE - SERUM / PLASMA (POST PRANDIAL)

Test Name	Result	Unit	Level	Range
Glucose - Plasma (POST PRANDIAL)	110	mg/dL	●	70-140
URINE GLUCOSE(POST PRANDIAL):(Strip Method)	Nil			

LIPID PROFILE TEST (PACKAGE)

Test Name	Result	Unit	Level	Range
HDL CHOLESTEROL - SERUM / PLASMA	58	mg/dL	●	40-60
TOTAL CHOLESTEROL/HDL CHOLESTEROL RATIO(Calculated)	3.4		●	0.0-4.5
LDL Cholesterol (Direct LDL)	145	mg/dL		

LIVER FUNCTION TEST (PACKAGE)

Test Name	Result	Unit	Level	Range
-----------	--------	------	-------	-------


● Within Normal Range ● Borderline High/Low ● Out of Range

H Swaminarayan Nagar, Off Mumbai-Agra Highway,
Panchvati, Nashik - 422 003.

+91- 253 - 2510250 / 350 / 450 / 550 / 750

apollonashik@apollohospitals.com
www.askapollo.com

QFAHN/BILL/003/V1



Date : 09/08/2022

AHC No : NSKAH27277

Name : Mr. PARSHURAM D PAVALE (38 Yr)

UHID : MHN1.0000124076

Package : MediWheel Full Body Health Checkup Male Below 40 Package

PROTEIN, TOTAL - 8.2 g/dL ● 6.4-8.2
SERUM / PLASMA

PROTEIN, TOTAL - 8.2 g/dL ● 6.4-8.2
SERUM / PLASMA

INVESTIGATIONS NOT DONE / NOT YET REPORTED / NOT
PART OF PACKAGE(LAB,RADIOLOGY & RADIOLOGY)

Haematology

STOOL ROUTINE

THYROID PROFILE - I(T3,T4 AND TSH)

Test Name	Result	Unit	Level	Range
TOTAL T3: TRI IODOTHYRONINE - SERUM	154	ng/dL	●	Healthy Adults: 69 - 215
TOTAL T4: THYROXINE - SERUM	9.8	µg/dL	●	Healthy Adults:5.2-12.7

LIPID PROFILE TEST (PACKAGE)

Test Name	Result	Unit	Level	Range
Lipid Profile - Serum	105	mg/dL	●	0-150

THYROID PROFILE - I(T3,T4 AND TSH)

Test Name	Result	Unit	Level	Range
TSH: THYROID STIMULATING HORMONE - SERUM	1.4	uIU/mL	●	Euthyroid: 0.3 - 4.5 Hypothyroid: 7.1 - >75

URIC ACID - SERUM

Test Name	Result	Unit	Level	Range
URIC ACID - SERUM	7.5 *	mg/dL	●	3.5-7.2

LIVER FUNCTION TEST (PACKAGE)

Test Name	Result	Unit	Level	Range
BILIRUBIN CONJUGATED (DIRECT) - SERUM	0.4 *	mg/dL	●	0.0-0.3
BILIRUBIN UNCONJUGATED - SERUM(Calculated)	1.8 *	mg/dL	●	0.0-0.7

CARDIAC STRESS TEST - (TMT)

ECG

ULTRASOUND - WHOLE ABDOMEN

No significant abnormality is detected.

Suggest : Clinical correlation.

X-RAY CHEST PA

● Within Normal Range ● Borderline High/Low ● Out of Range

Pavale, Parshuram

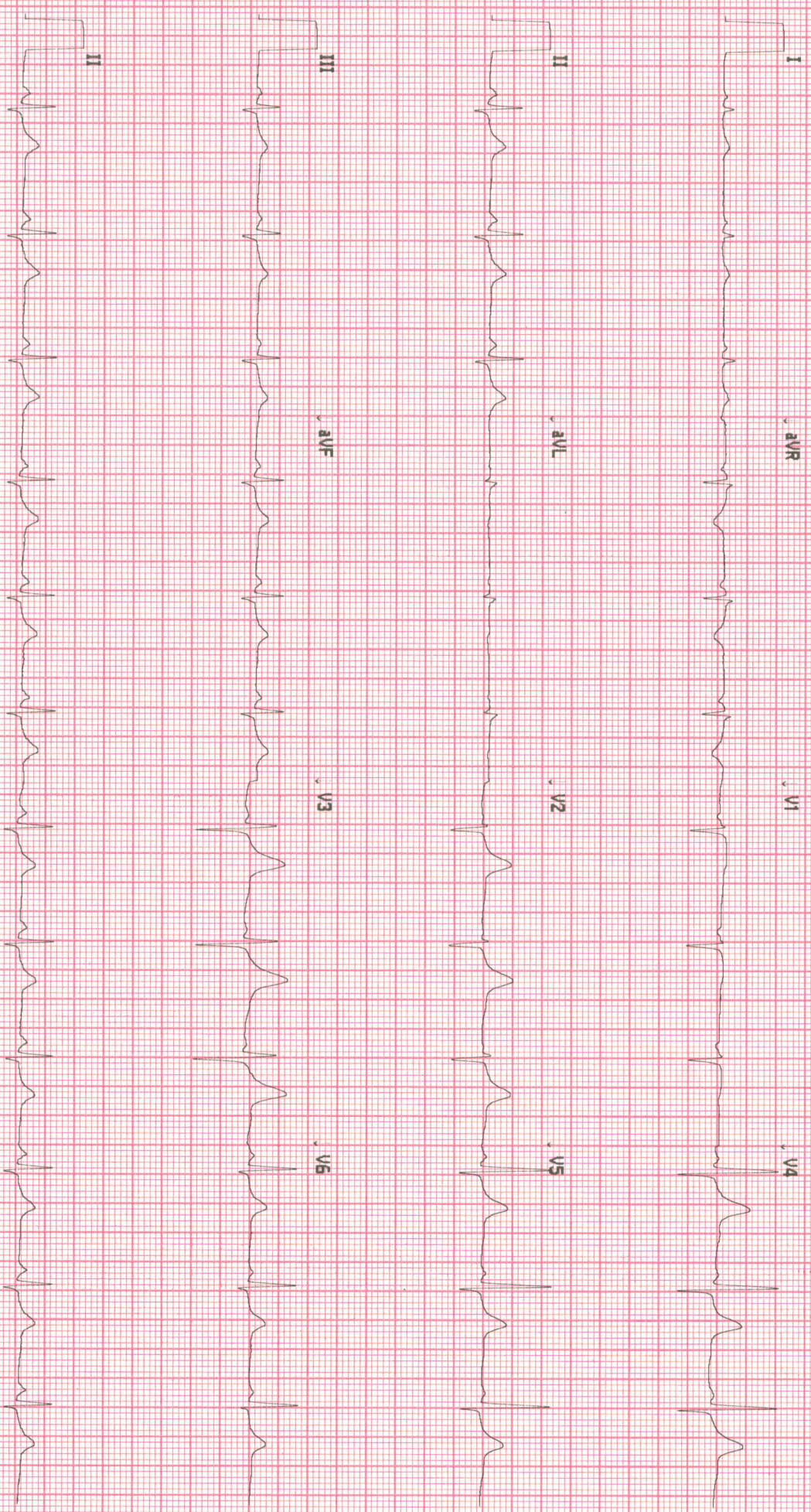
ID:
DOB:
38yr, Male

9-Aug-2022 13:47:06

Vent Rate: 73 BPM
PR Int: 117 ms
QRS dur: 83 ms
QT/QTc: 373/399 ms
P-R-T axes: 62 63 68

SINUS RHYTHM WITH SHORT PR INTERVAL
BORDERLINE ECG

UNCONFIRMED REPORT



113500188213

No Site Name

Site # 0 Cart # 2 Version 2.0.4.0 Sequence #19718 25mm/s 10mm/mV 0.05-40 Hz



Radiology

Patient Details : Mr. PARSHURAM D PAVALE | Male | 38Yr 0Mth 0Days

UHID : MHN1.0000124076 **Patient Location:** AHC

Patient Identifier: NSKAH27277



DRN : 222017740 **Completed on :** 09-AUG-2022 11:51

Ref Doctor : DR. Rajashri Dhongade

ULTRASOUND - WHOLE ABDOMEN

LIVER : Normal in size and measures 14cm. Echotexture is uniform and normal. No I.H.B.D./ focal lesions.

PORTAL VEIN: Normal in size.

GALL BLADDER: Well distended with normal walls and lumen.
No calculi/pericholecystic fluid.

COMMON BILE DUCT: Normal in size.

PANCREAS : Visualized portion of head and body of pancreas appears normal in size and echotexture. Rest of the pancreas is obscured due to bowel gases.

AORTA, IVC and para aortic areas are normal.

SPLEEN : Normal in size (10cm) and echotexture.

KIDNEYS: Both kidneys are normal in site, size and echotexture.

No evidence of calculi/ hydronephrosis.

Right kidney measures: 8.3 x 3.5 cm.

Left kidney measures : 9.0 x 4.5 cm.

URINARY BLADDER: Well distended with normal walls.

No evidence of calculi/ growth/ diverticula .

PROSTATE : Normal in size with homogenous echogenicity. No evidence of calcification within.

Seminal vesicles are normal.

H Swaminarayan Nagar, Off Mumbai-Agra Highway,
Panchvati, Nashik - 422 003.

+91- 253 - 2510250 / 350 / 450 / 550 / 750

apollonashik@apollohospitals.com

www.askapollo.com

QFAHN/BILL/003/V1



Mr. PARSHURAM D PAVALE

MHN1.0000124076

NSKAH27277

ULTRASOUND - WHOLE ABDOMEN

Visualized bowel loops appear grossly normal.

No evidence of any free fluid in the peritoneal cavity.

Impression


No significant abnormality is detected.

Suggest : Clinical correlation.

--- END OF THE REPORT ---



Dr. Harshal S Dhongade
Consultant - Radiology





Radiology

Patient Details : Mr. PARSHURAM D PAVALE | Male | 38Yr 0Mth 0Days

UHID : MHN1.0000124076

Patient Location: AHC

Patient Identifier: NSKAH27277



DRN : 122029348

Completed on : 09-AUG-2022 11:17

Ref Doctor : DR. Rajashri Dhongade

X-RAY CHEST PA

Moderate rotation.

Left hilar prominence due to rotation.

Rest of the lung fields are clear.

Costophrenic angles are clear.

Cardiac size and contour are within normal limits.


Rib cage is normal.

Soft tissues are normal.

Suggest : Clinical correlation.

Impression

---- END OF THE REPORT ----


Dr. Gorakhnath T

CONSULTANT-RADIOLOGY

DEPARTMENT OF ENT

Patients Name Mr. Parshuram

Pavale 9/8/22
Date

Age / Sex 38 y/m

UHID 124076

Consultant : Dr. Purwa Totala Birla (MS ENT, DNB)

Right

Left

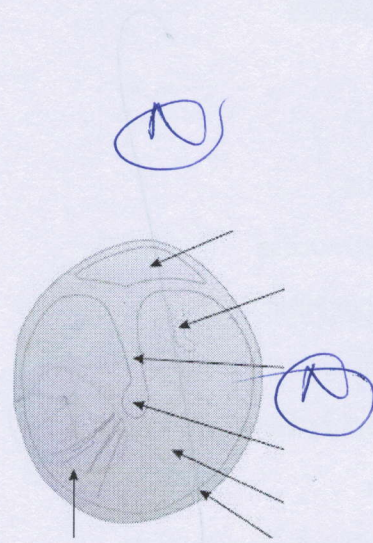
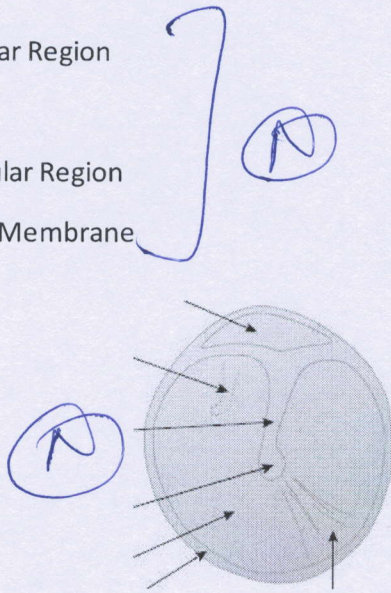
EAR

Preauricular Region

Pinna

Postauricular Region

Tympanic Membrane



Tuning Fork Test

Rinnies 256 Hz

+

+

512 Hz

+

+

1024 Hz

+

+

Weber test

Central

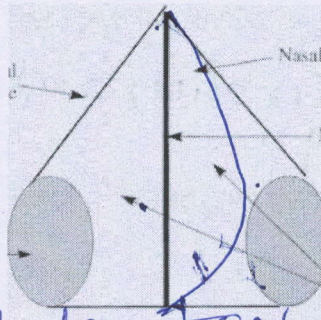
ABC test

same as examiner

Pure Tone Audiometry (PTA)

NOSE

Anterior Rhinoscopy




DNS to (LL)
 (total block)
 (LL) side blast test

cold spatula test

PNS tenderness


ORAL Cavity

- Lip
- Teeth
- Tongue
- Buccal mucosa
- Anterior Pillar
- Tonsils
- Posterior pillar
- Uvula
- Posterior pharyngeal wall



NECK

- Laryngeal crepitus
- Laryngeal widening
- Cervical Lymph node
- Others



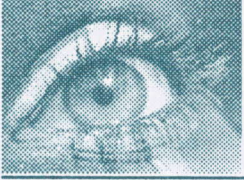
COMMENT

Adv
 CT PNS (plain)

ADVICE

Septo plasty

Signature



OPHTHALMOLOGY



Name : Mrs Parshuram Pawate Date 09/08/22 UNIT _____
 Occupation : _____ Room No. _____ Out Patient
 Age : 38 Sex : Male Female S/M/W/D Ref. Physician : _____
 Address : NSIC Copies to : _____
 _____ Tel. No. _____

REPORT ON OPHTHALMIC EXAMINATION

HISTORY : _____

PRESENT COMPLAINT : (BE) Dizziness

PAST HISTORY : DM / HTN / ALLERGY

ON EXAMINATION

VISION :

		RE RIGHT				LE LEFT			
		SPH	CYL	AXIS	VA	SPH	CYL	AXIS	VA
DIST		<u>6/6</u>				<u>6/6</u>			
NEAR		<u>6/6</u>				<u>6/6</u>			

AC / Retinoscopy :

RIGHT			LEFT		
SPH	CYL	AXIS	SPH	CYL	AXIS
<u>-0.25</u>	<u>—</u>	<u>—</u>	<u>-0.25</u>	<u>—</u>	<u>—</u>


Refraction or Acceptance :

		RIGHT				LEFT			
		SPH	CYL	AXIS	VA	SPH	CYL	AXIS	VA
DIST		<u>-0.25</u>	<u>—</u>	<u>—</u>	<u>6/6</u>	<u>-0.25</u>	<u>—</u>	<u>—</u>	<u>6/6</u>
NEAR		<u>—</u>	<u>—</u>	<u>—</u>	<u>N/6</u>	<u>—</u>	<u>—</u>	<u>—</u>	<u>N/6</u>


Handwritten signature

CONSULTANT OPTOMETRIST

Anterior Segment :



Fundus :



Diagnosis :

AV	SV	IP	HS	AV	SV	IP	HS	SV

Advise / Rx:

anti-allergy drops

- Hot fomentation
- Olopat 1% qid (BR) / Cefta 1% qid (BR)
- Eyemist eyedrops (BR)
- regular use
- 1% SW SW

ORAL EXAMINATION FORM



Date: 9/8/22

Patient ID: _____

MHC

Patient Name: Mr. Passhuram Panale

Age: 38

Sex: Male Female

Chief Complaint:

Medical History:

Drug Allergy:

Medication currently taken by the Guest:

Initial Screenign Findings:

Dental Caries:

Impacted Teeth:

Bleeding:


Calculus / Stains:

Restored Teeth:

Malocclusion:

class I malocclusion unilaterally

Missing Teeth:



Attrition / Abrasion:


Pockets / Recession:

Mobility:

Non - restorable Teeth for extraction /
Root Stumps:

Others:

Advice:- FPD



Doctor
Name & Signature:

Dr. Poojamma Patil

9096986290 / 8275015672

ID: 000124076

Visit:

38years

Asian

Male

BRUCE

Max HR: 150bpm 86% of max predicted 173bpm

Max BP: 120/70

Reason for Termination: Max HR attained

Total Exercise time: 7:03

Maximum workload: 8.6METS

25.0 mm/s

10.0 mm/mV

100hz

9-Aug-2022

13:08:51

Referred by:

Test ind:

Comments:

Phase Name	Stage Name	Time in Stage	Speed (mph)	Grade (%)	WorkLoad (METS)	HR (bpm)	BP (mmHg)	RPP (x100)
PRETEST	SUPINE	0:37	**.*	**.*	1.0	84	100/70	84
	STANDING	0:12	**.*	**.*	1.0	82	100/70	82
	HYPERVERENT	0:16	0.1	0.0	1.0	80	100/70	80
EXERCISE	STAGE 1	3:00	1.7	10.0	4.6	104	100/70	104
	STAGE 2	3:00	2.5	12.0	7.0	129	110/70	142
	STAGE 3	1:03	3.4	14.0	8.6	150	120/70	180
RECOVERY	Post	3:45	**.*	**.*	1.0	94	120/70	113

TMT Negative for STI 