


MER- MEDICAL EXAMINATION REPORT

Date of Examination	23-09-2023		
NAME	Dinesh Kumar		
AGE	32	Gender	Male
HEIGHT(cm)	170 cm.	WEIGHT (kg)	65 kg
B.P.	120/70		
EKG	Normal		
X Ray	Normal		
Vision Checkup	Normal		
Present Ailments	-		
Details of Past ailments (If Any)	-		
Comments / Advice : She /He is Physically Fit	fit		
$BMI = 22.5 \text{ kg/m}^2 \text{ (Normal)}$			


 Signature with Stamp of Medical Examiner

Dr. Mukesh Dubey
 : (MBBS DCP)
 Registration No.-10632

Panel Medical Examiner
 Triveni Diagnostic & Research Centre
 Agrawal Plaza, B-7, H.I.G. Main Road,
 INDORE



भारत सरकार
Government of India



आधार


भारत सरकार
Government of India

भारतीय विशिष्ट पहचान प्राधिकरण
Unique Identification Authority of India

नामांकन क्रम/ Enrolment No.: 0000/00387/34744

To
दिनेश कुमार वर्मा
Dinesh Kumar Verma
S/O: Devchand
Mandawar
Rajgarh Madhya Pradesh - 465685
8120860026

Signature Not Verified
Digitally signed by Dinesh Kumar Verma
DN: cn=Dinesh Kumar Verma, o=Unique Identification
Authority of India, ou=UIDAI, email=Dinesh.Kumar.Verma@uidai.gov.in, c=IN



आपका आधार क्रमांक / Your Aadhaar No. :

5012 6448 0857

VID : 9106 6945 0748 6426

मेरा आधार, मेरी पहचान



भारत सरकार
Government of India



दिनेश कुमार वर्मा
Dinesh Kumar Verma
जन्म तिथि/DOB: 10/10/1990
पुरुष/ MALE

Issue Date: 08/05/2015

5012 6448 0857

VID : 9106 6945 0748 6426

मेरा आधार, मेरी पहचान



भारत सरकार
Government of India



आधार

सूचना / INFORMATION


- आधार पहचान का प्रमाण है, नागरिकता का नहीं।
- आधार विशिष्ट और सुरक्षित है।
- सुरक्षित क्यूआर कोड/ऑफलाइन एक्सएमएल/ऑनलाइन प्रमाणीकरण का उपयोग करके पहचान सत्यापित करें।
- आधार के सभी रूप जैसे आधार पत्र, पीवीसी कार्ड, ई-आधार और एम-आधार समान रूप से मान्य हैं। १२ अंकों की आधार संख्या के स्थान पर आभासी (वर्चुअल) आधार पहचान (VID) का भी उपयोग किया जा सकता है।
- १० साल में कम से कम एक बार आधार अपडेट जरूर करें।
- आधार आपको विभिन्न सरकारी और गैर-सरकारी योजनाओं /सेवाओं का लाभ उठाने में मदद करता है।
- आधार में अपना मोबाइल नंबर और ई-मेल आईडी अपडेट रखें।
- आधार सेवाओं का लाभ उठाने के लिए स्मार्टफोन पर mAadhaar ऐप डाउनलोड करें।
- आधार/बायोमेट्रिक्स को लॉक/अनलॉक करने की विशेषता का उपयोग सुरक्षा सुनिश्चित करने के लिए करें।
- आधार (पत्र/ नंबर) चाहने वाली संस्थायों को उचित सहमति लेने के लिए बाध्य किया गया है।
- Aadhaar is a proof of identity, not of citizenship.
- Aadhaar is unique and secure.
- Verify identity using secure QR code/offline XML/online Authentication.
- All forms of Aadhaar like Aadhaar letter, PVC Cards, eAadhaar and mAadhaar are equally valid. Virtual Aadhaar Identity (VID) can also be used in place of 12 digit Aadhaar number.
- Update Aadhaar at least once in 10 years.
- Aadhaar helps you avail various Government and Non- Government benefits/services.
- Keep your mobile number and email id updated in Aadhaar.
- Download mAadhaar app on smart phones to avail Aadhaar Services.
- Use the feature of lock/unlock Aadhaar/biometrics to ensure security.
- Entities seeking Aadhaar are obligated to seek due consent.



भारतीय विशिष्ट पहचान प्राधिकरण
Unique Identification Authority of India



पता:
आत्मज: देवचंद, मंडावर, राजगढ़,
मध्य प्रदेश - 465685
Address:
S/O: Devchand, Mandawar, Rajgarh,
Madhya Pradesh - 465685



5012 6448 0857

VID : 9106 6945 0748 6426

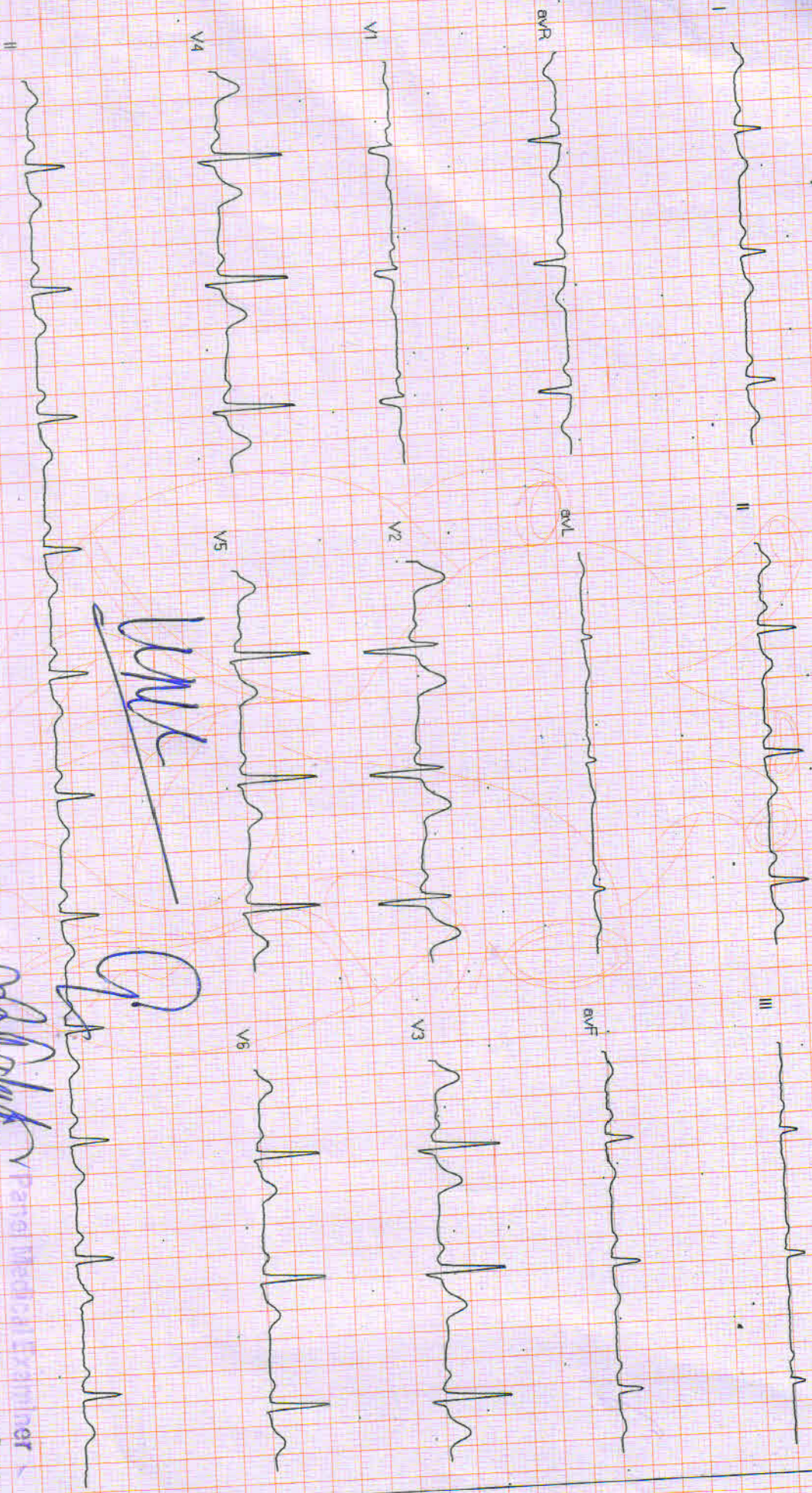
1947 | help@uidai.gov.in | www.uidai.gov.in

Panel Medical Examiner
Triveni Diagnostic & Research Centre
Agrawal Plaza, B-7, H.I.G Main Road,
INDORE

RAVENI DIAGNOSTICS & RESEARCH CENTRE

NAME / MR DINESH KUMAR VERMA / 32 Yrs / M / Non Smoker
Heart Rate : 70 bpm / Tested On : 23-Sep-23 08:40:29 / HF 0.05 Hz - LF 20 Hz / Notch 50 Hz / Sn 1.00 Cm/mV / Sw 25 mm/s

ECG



VMK
Q

[Signature]

Reported By:

Agrawal Pooja, B-7, H.O.G Main Road,
INDORE



डॉ. मनोज भटनागर

नेत्र रोग विशेषज्ञ एवं सर्जन एम.एस.

Reg. No. 5453

R

Dinesh Kumar

Verma

Eye
Surgery

विशेषज्ञ

- ◆ इन्ट्राओक्युलर लेंस इम्प्लांट
- ◆ फेको विधि द्वारा बगैर टांके का मोतियाबिंद ऑपरेशन
- ◆ कॉन्टेक्ट लेंस विशेषज्ञ
- ◆ लेसिक लेजर (चशमा उतारने की विधि)

दिनांक 23 9 23

Vision { 6/6
6/24
C Slam { 6/6
6/9 or 6/18

OK
RT Plan
LE -1.08D

Need Vision N/A

Colored Vision Normal

Ext Exam N/A

Funds ~~N/A~~

समय : दोप 12 से 2 एवं शाम 6 से 9 एवं रविवार एपॉईमेन्ट द्वारा

क्लिनिक : ई-4, एच,आई.जी. कॉलोनी, एच,आई.जी. मेन रोड (आंध्रा बैंक एवं एल.आई.जी सर्कल के बीच), इन्दौर (म.प्र.)

मो. : 94250-73027 www.drmanojbhatnagar.com

Dr. Bhatnagar's Multispeciality Dental Clinic

Dr. Nikita Bhatnagar

B.D.S., M.D.S. (Gold Medalist)
Reg. No. A-3503
Mob.: 96699-37000

Clinic: E-4, HIG Colony, HIG Main Road
Indore-452011(M.P.)

डॉ. निकिता भटनागर

बी.डी.एस., एम.डी.एस., (गोल्ड मेडलिस्ट)
रजि. नं. ए-3503
मो.: 96699-37000

क्लीनिक: ई-4, एच.आई.जी. कॉलोनी, एच.आई.जी. मेनरोड
इन्दौर-452011 (म.प.)

Mr. Dinesh Kumar Verma

Date: 23/09/2023

Rp

Denti 91 mouthwash

Hydent Pro toothpaste

Tab. Lincex ~~1000~~ (15) x 15 days

Adv: ① DPG

② Replacement of missing teeth



③ Midline diastema Closure.

COSMETIC DENTISTRY

- Smile designing
- Teeth whitening & bleaching
- Tooth jewellery
- Composite & ceramic veneers
- Invisalign / Orthodontic braces
- Tooth colored fillings

GENERAL DENTISTRY

- Instant Dental X-rays
- Root Canal Treatment
- Gum treatment
- Atraumatic Extractions
- Wisdom tooth treatment
- Crown and bridges

PREVENTIVE DENTISTRY

- Teeth cleaning & polishing
- Flouride application
- Treatment for Precancerous
- Conditions & Lesions
- Tobacco chewing habit cessation

GERIATRIC DENTISTRY

- Dental Implants
- Dentures
- Oro-Facial pain
- TMJ Disorders
- Snoring while sleeping

DR. NIKITA BHATNAGAR
Master of Dental Surgery
Dental Surgeon
Reg. No. A-3503

Nikita



Triveni Diagnostic Centre

Reg No. : 77872 VISITID : 0000082302
PATIENT NAME : Mr. DINESH KUMAR VERMA SPEC. NO : 1905406323
AGE/SEX : 32 YEARS/MALE SAMP. DATE : 23/09/2023 12:19:00
REF. BY : Dr. ARCOFEMI HEALTHCARE LIMITED RESULT DATE : 25/09/2023 11:36:28

HEMATOLOGY

CBC (COMPLETE BLOOD COUNT)

NAME OF TEST	RESULT VALUE	REFERENCE RANGE	UNIT
HAEMOGLOBIN	13.1	13.5 - 18	gm/dl
TOTAL RBC COUNT	5.88	4 - 6.5	mill/cummm
HAEMATOCRIT (PCV)	44.3	41.5 - 50.4	%
MEAN CORPUS VOL(MCV)	75.34	80 - 96	f l
MEAN CORPUS HB (MCH)	22.28	27.5 - 33.2	picograms
MEAN CORPUS HB CONC (MCHC)	29.57	33.4 - 35.5	%
RDW	19.6	11.5 - 15.5	%
PDW	12.6	-	f l
MPV	11.5	-	f l
PCT	0.37	-	%
P-LCR	33.5	-	%
TOTAL WBC	8600	4000 - 11000	/cumm
PLATELET COUNT	3.25	1.5 - 4.0	Lacs/cumm
<u>DIFFERENTIAL COUNT</u>			
NEUTROPHILS	67	40 - 70	%
LYMPHOCYTES	30	20 - 40	%
MONOCYTES	02	1 - 8	%
EOSINOPHILS	01	0 - 6	%
BASOPHILS	00	0 - 1	%
ABSOLUTE NEUTROPHILS	5.77	2 - 7	X1000/cumm
ABSOLUTE LYMPHOCYTES	2.52	1 - 3	X1000/cumm
ABSOLUTE MONOCYTE	0.16	0.2 - 1	X1000/cumm
ABSOLUTE EOSINOPHIL	0.13	0.02 - 0.5	X1000/cumm
ABSOLUTE BASOPHIL	00	0.02 - 0.1	X1000/cumm
ESR	14	0 - 20	mm at end of 1
MP (MALARIA PARASITE)	.	-	

METHOD: - By five part automated analyzer (sysmex XS1000 i) Japan

DR. MUKESH DUBEY
(MBBS, DCP) (DIRECTOR)

DR. VIJAY BHURIYA
MBBS DMRD

DR. YOGESH PAWDE
M. D. (CONS. PATHOLOGIST)

DR. P.S. TRIPATHI
M.D. (RADIO DIAGNOSIS)

DR. SANJAY YADAV
CON. MICROBIOLOGIST

Report Checked By:

Address : Agrawal Plaza, B-7, HIG Main Road, Indore Ph. : 0731-4289992-3
Website : www.trivenidiagnostic.com email : trivenidiagnostic@yahoo.co.in

Page 1 of 1



Triveni Diagnostic Centre

Reg No. : 77872 VISITID : 0000082302
PATIENT NAME : Mr. DINESH KUMAR VERMA SPEC. NO : 1905406323
AGE/SEX : 32 YEARS/MALE SAMP. DATE : 23/09/2023 12:19:00
REF. BY : Dr. ARCOFEMI HEALTHCARE LIMITED RESULT DATE : 25/09/2023 11:34:21

DEPARTMENT OF PATHOLOGY

NAME OF TEST	RESULT VALUE	REFERENCE RANGE	UNIT
--------------	--------------	-----------------	------

BLOOD GROUP

BLOOD GROUP	"O"	-	
RH FACTOR	Positive	-	

RESULT REMARKS :

FBS

FBS	99	70 - 110	mg / dl
-----	----	----------	---------

RESULT REMARKS : Test done by -"Roche COBAS- ENTEGRA 400 PLUS "fully bichemistry analyser .

GAMA GT

GGT (GAMMA GLUTAMYL TRANSFERASE)	35	8 - 52	U / L
----------------------------------	----	--------	-------

RESULT REMARKS :

PPBS

PPBS (POST PRANDIAL BLOOD SUGAR)	122	70 - 140	mg / dl
----------------------------------	-----	----------	---------

RESULT REMARKS : Test done by -"Roche COBAS- ENTEGRA 400 PLUS "fully bichemistry analyser .

DR. MUKESH DUBEY
(MBBS. DCP) (DIRECTOR)

DR. VIJAY BHURIYA
MBBS DMRD

DR. YOGESH PAWDE
M. D. (CONS. PATHOLOGIST)

DR. P.S. TRIPATHI
M.D.(RADIO DIAGNOSIS)

DR. SANJAY YADAV
CON. MICROBIOLOGIST

Report Checked By :

Page 1 of 1



Triveni Diagnostic Centre

Reg No. : 77872 VISITID : 0000082302
PATIENT NAME : Mr. DINESH KUMAR VERMA SPEC. NO : 1905406321
AGE/SEX : 32 YEARS/MALE SAMP. DATE : 23/09/2023 12:19:00
REF. BY : Dr. ARCOFEMI HEALTHCARE LIMITED RESULT DATE : 25/09/2023 11:34:39

BIO-CHEMISTRY

NAME OF TEST	RESULT VALUE	REFERENCE RANGE	UNIT
LIPID PROFILE			
CHOLESTEROL	176	0 - 200	mg / dl
TRIGLYCERIDES	101	50 - 190	mg / dl
HDL(HIGH DENSITY LIPIDS)	48	35 - 65	mg / dl
LDL	107.8	50 - 190	mg / dl
VLDL (VERY LOW DENSITY LIPIDS)	20.2	15 - 30	mg / dl
Cholestrol : HDL	3.6	3.5 - 5.5	
LDL : HDL	2.25	0 - 3.5	mg / dl

RESULT REMARKS : Test done by -"Roche COBAS- ENTEGRA 400 PLUS "fully bichemistry analyser .

RENAL PROFILE

UREA	23	10 - 40	mg / dl
CREATININE	0.81	0.7 - 1.4	mg / dl
SERUM SODIUM	140.2	135 - 155	mmol/L
SERUM POTASIUM	4.1	3.5 - 5.5	mmol/L

RESULT REMARKS :

DR. MUKESH DUBEY
(MBBS, DCP) (DIRECTOR)

DR. VIJAY BHURIYA
MBBS DMRD

DR. YOGESH PAWDE
M. D. (CONS. PATHOLOGIST)

DR. P.S. TRIPATHI
M.D. (RADIO DIAGNOSIS)

DR. SANJAY YADAV
CON. MICROBIOLOGIST

Report Checked By :

Address : Agrawal Plaza, B-7, HIG Main Road, Indore Ph. : 0731-4289992-3
Website : www.trivenidiagnostic.com email : trivenidiagnostic@yahoo.co.in

Page 1 of 1



Triveni Diagnostic Centre

Reg No. : 77872
PATIENT NAME : Mr. DINESH KUMAR VERMA
AGE/SEX : 32 YEARS/MALE
REF. BY : Dr. ARCOFEMI HEALTHCARE LIMITED

VISITID : 0000082302
SPEC. NO : 1905406321
SAMP. DATE : 23/09/2023 12:19:00
RESULT DATE : 25/09/2023 11:35:14

NAME OF TEST	RESULT VALUE		REFERENCE RANGE	UNIT
	IN RANGE	OUT RANGE		
LFT (LIVER FUNCTION TEST)				
TOTAL BILIRUBIN	0.79		0.2 - 1.3	mg/dL
DIRECT BILIRUBIN	0.47		0.2 - 0.65	mg / dl
INDIRECT BILIRUBIN	0.32		0.2 - 0.8	mg / dl
SGOT(AST)	24		0 - 40	U / L
SGPT(ALT)	28		0 - 40	U / L
ALKALINE PHOSPHATASE	101		37 - 143	U / L
PROTEINS	7.12		6 - 8.3	g / dl
ALBUMIN	4.16		3.5 - 5	gm/dl
GLOBULIN	2.94		1.9 - 3.5	g / dl
A.G.RATIO	1.41		0.5 - 2	mg / dl
PT (PROTHROMBIN TIME)		14	-	seconds
CONTROL		14	-	seconds
(INR) INTERNATIONALNARMLISED RATIO		1.0	-	seconds

REMARKS :

METHOD: BY COBAS INTEGRA 400 PLUS.

DR. MUKESH DUBEY
(MBBS, DCP) (DIRECTOR)

DR. VIJAY BHURIYA
MBBS DMRD

DR. YOGESH PAWDE
M. D. (CONS. PATHOLOGIST)

DR. P.S. TRIPATHI
M.D. (RADIO DIAGNOSIS)

DR. SANJAY YADAV
CON. MICROBIOLOGIST

Report Checked By :

Address : Agrawal Plaza, B-7, HIG Main Road, Indore Ph. : 0731-4289992-3
Website : www.trivenidiagnostic.com email : trivenidiagnostic@yahoo.co.in



Triveni Diagnostic Centre

Reg No. : 77872 VISITID : 0000082302
PATIENT NAME : Mr. DINESH KUMAR VERMA SPEC. NO : 1905406324
AGE/SEX : 32 YEARS/MALE SAMP. DATE : 23/09/2023 12:19:00
REF. BY : Dr. ARCOFEMI HEALTHCARE LIMITED RESULT DATE : 25/09/2023 11:35:42

BIO-CHEMISTRY

HBA1 C (GLYCOSYLATED HEAMOGLOBIN)

NAME OF TEST	RESULT VALUE	REFERENCE RANGE	UNIT
HBA1 C (GLYCOSYLATED HEAMOGLOBIN)	5.7	Normal: 4-6 Good cntrol:6.1-7.0 Fair control :7.0-8.2 Unsatisfactory control: 8.0-10.2 Poor control: Above 10.0	%
MEAN PLASMA GLUCOSE (MPG)	117	Exelent Control:90-120 Good Control:121-150 Avrege Control:151-180 Action Suggested:181-210 Panic value :>211	mg/dL

Test done by -"Roche COBAS- ENTEGRA 400 PLUS "fully bichemistry analyser .

METHOD BY: Turbidimetric inhibition immunoassay(TINIA)

Average blood glucose value is calculated from HBA1C value and indicates average blood sugar level over past three months.

DR. MUKESH DUBEY
(MBBS. DCP) (DIRECTOR)

DR. VIJAY BHURIYA
MBBS DMRD

DR. YOGESH PAWDE
M. D. (CONS. PATHOLOGIST)

DR. P.S. TRIPATHI
M.D. (RADIO DIAGNOSIS)

DR. SANJAY YADAV
CON. MICROBIOLOGIST

Report Checked By:

Address : Agrawal Plaza, B-7, HIG Main Road, Indore Ph.: 0731-4289992-3
Website : www.trivenidiagnostic.com email : trivenidiagnostic@yahoo.co.in

Page 1 of 1



Triveni Diagnostic Centre

Reg No. : 77872 VISITID : O000082302
PATIENT NAME : Mr. DINESH KUMAR VERMA SPEC. NO : 1905406321
AGE/SEX : 32 YEARS/MALE SAMP. DATE : 23/09/2023 12:19:00
REF. BY : Dr. ARCOFEMI HEALTHCARE LIMITED RESULT DATE : 25/09/2023 11:34:56

IMMUNO ASSAY

T3,T4 TSH

NAME OF TEST	RESULT VALUE	REFERENCE RANGE	UNIT
T3 (TRIIODOTHYRONINE)	1.09	Adults:- 0.60-1.58 Children:- 0-3 days:- 0.96- 2.92 1-11 months 0.81-2.81 1-5 years 0.83-2.52 6-10 years 0.92-2.19 11-15years 0.83-2.15	ng/ml
T4 (THYROXINE)	8.6	Adults:- 5.01-11.0 Children:- 0-3 days 11.80-22.60 4-30 days not Established 1-2 weeks 9.80-16.60 1-4 months 7.20-14.40 4-12 months 7.80-16.50	ug/dl
TSH (THYROID STIMULATING HORMONE)	5.66	Adults:- 0.38-4.31 Children:- 0-3 days:- 1.0-39.0 4-30 days:- 0.43-16.1 2-12 months:- 0.62-8.05 2-6 years:- 0.54-4.53 7-11 years:- 0.66-4.14 12-19 years:- 0.53-3.59	uIU/ml

Method: By AIA-360 (TOSOH) fully automated electro chemiluminescence immunoassay

INTERPRETATION: Suppressed TSH values are seen in hyperthyroid patients with the exception of hyperthyroidism caused by a TSH producing pituitary tumors. In addition TSH is suppressed in individuals treated with the exogenous thyroid hormones.

Elevated TSH values are seen in primary hypothyroidism with the exception of hypothyroidisms caused by pituitary disorders.

Note: Total T3 and T4 values may also be altered in other conditions due to changes in serum proteins or binding sites pregnancy, drugs (Androgens, Estrogens, O C pills, Phenyton) nephrosis etc. In such cases free T3 and T4 give corrected values.

DR. MUKESH DUBEY
(MBBS. DCP) (DIRECTOR)

DR. VIJAY BHURIYA
MBBS DMRD

DR. YOGESH PAWDE
M. D. (CONS. PATHOLOGIST)

DR. P.S. TRIPATHI
M.D. (RADIO DIAGNOSIS)

DR. SANJAY YADAV
CON. MICROBIOLOGIST

Report Checked By:

Address : Agrawal Plaza, B-7, HIG Main Road, Indore Ph. : 0731-4289992-3
Website : www.trivenidiagnostic.com email : trivenidiagnostic@yahoo.co.in

Page 1 of 1



Triveni Diagnostic Centre

Reg No. : 77872 VISITID : O000082302
PATIENT NAME : Mr. DINESH KUMAR VERMA SPEC. NO : 1905406322
AGE/SEX : 32 YEARS/MALE SAMP. DATE : 23/09/2023 12:19:00
REF. BY : Dr. ARCOFEMI HEALTHCARE LIMITED RESULT DATE : 25/09/2023 11:35:58

CLINICAL-PATHOLOGY

URINE EXAMINATION

NAME OF TEST	RESULT VALUE	REFERENCE RANGE	UNIT
PHYSICAL EXAMINATION			
QUANTITY	30	-	ml
COLOUR	Pale Yellow	-	
APPEARANCE	Clear	-	
REACTION	Acidic	-	
Specific Gravity	1.010	-	
CHEMICAL EXAMINATION			
ALBUMIN	Nil	-	
URINE SUGAR	Nil	-	
Ketone Bodies	Nil	-	
BLOOD	Nil	-	
Bile Pigment	Nil	-	
Bile Salts	Nil	-	
MICROSCOPIC EXAMINATION			
Pus Cells	1-2/hpf	2 - 5	/hpf
Epithelial Cells	1-2/hpf	5 - 10	
RBCs	Nil	-	/hpf
Casts	Nil	-	
Crystals	Nil	-	
Spermatozoa	Nil	-	
Bacteria	Nil	-	
Others		-	

DR. MUKESH DUBEY
(MBBS, DCP) (DIRECTOR)

DR. VIJAY BHURIYA
MBBS DMRD

DR. YOGESH PAWDE
M. D. (CONS. PATHOLOGIST)

DR. P.S. TRIPATHI
M.D. (RADIO DIAGNOSIS)

DR. SANJAY YADAV
CON. MICROBIOLOGIST

Report Checked By:

Address : Agrawal Plaza, B-7, HIG Main Road, Indore Ph. : 0731-4289992-3
Website : www.trivenidiagnostic.com email : trivenidiagnostic@yahoo.co.in

Page 1 of 1



Triveni Diagnostic Centre

Reg. No. : 77872 Visit ID : 0000082302
Patient Name : Mr. DINESH KUMAR VERMA
Age / Sex : 32 YEARS / MALE Order Date : 23/09/23 11:56AM
Ref. By : Dr. ARCOFEMI HEALTHCARE LIMITED Report Date : 23/09/23 01:16PM

SONOGRAPHY

USG WHOLE ABDOMEN(MALE)

Liver is normal in size 13.6cm , shape and **echotexture appears raised**. No focal parenchymal lesion noted. Portal vein is of normal caliber. There is no evidence of dilatation of Intra and extra hepatic biliary radicals.

☉ Gall bladder appears normal. Does not show any sludge or calculus. Its walls are smooth and normal in wall thickness.

Pancreas is normal in size, shape and shows normal echogenicity, no localised solid or cystic mass is identified in pancreas. Pancreatic duct is not dilated.

Spleen is normal in size 11.6cm , and shows normal echogenicity, no localised or cystic mass is identified in spleen.

Both kidneys are normal in size (Rt. 11.0 x 5.2 cm & Lt. 10.4 x 4.8 cm), shape and echotexture. There is no evidence of dilation of collecting system of either of the kidney. Ureters are not dilated.

Visualised bowel loops appear normal.
No evidence of any adenopathy or ascitis.


Urinary bladder is adequately filled with anechoic contents. The wall appears thin with smooth mucosa.

☉ Prostate appears normal in size , shape and echotexture.

IMPRESSION: Mild fatty liver.

Kindly correlate.

DR. MUKESH DUBEY
(MBBS, DCP)


DR. VIJAY BHURIYA
MBBS DMRD

DR. AMIT SHANKHWAR
M.D. RADIO DIAGNOSIS

DR. P.S. TRIPATHI
M.D. (RADIO DIAGNOSIS)

DR. SANJAY YADAV
CONSULTANT MICROBIOLOGIST

Note: This report is not valid for medico legal purpose.
Address : Agrawal Plaza, B-7, HIG Main Road, Indore Ph. : 0731-4289992-3
Website : www.trivenidiagnostic.com email : trivenidiagnostic@yahoo.co.in



Triveni Diagnostic & Research Centre

Reg. No. : 77872

Visit ID : O000082302

Patient Name : Mr. DINESH KUMAR VERMA

Age / Sex : 32 YEARS / MALE

Order Date : 23/09/23 11:56AM

Ref. By : Dr. ARCOFEMI HEALTHCARE LIMITED

Report Date : 23/09/23 12:18PM

CARDIOLOGY

2D ECHO

INTERPRETATION:- Normal 2-D Echo / Dopplar.

No LV RWMA seen.

LVEF IS 65 %.

2 IMAGING M Mode examination revealed normal movement of both mitral leaflets during diastole. No SAM or mitral valve prolapsed is seen. Aortic cups are normal and enclosure line is central. Tricuspid valve is normal. Pulmonary valve is normal. Aortic root is normal in size. Dimension of left atrium and left ventricles are normal.

3. Dimaging in PLAX.SAX and apical views revealed a normal left ventricle. Movement of septum anterior, posterior, inferior and lateral walls is normal. Global LVEF 65%, mitral valve opening is normal. No evidence of mitral valve prolapsed is seen. Aortic valve has three cups and its opening is not restricted. Right atrium & right ventricle are normal sized. Tricuspid valve leaflets move normally. Pulmonary valve is normal. Interatrial and intraventricular septa are intact. No intracardiac mass or thrombus is seen. No pericardial pathology is observed.


Dr. RAHUL TALATI MD

DR. MUKESH DUBEY

(MBBS, DCP)

DR. VIJAY BHURIYA

MBBS DMRD

DR. AMIT SHANKHWAR

M.D. RADIO DIAGNOSIS

DR. P.S. TRIPATHI

M.D. (RADIO DIAGNOSIS)

DR. SANJAY YADAV

CONSULTANT MICROBIOLOGIST

Note: This report is not valid for medico legal purpose.
Address : Agrawal Plaza, B-7, HIG Main Road, Indore Ph. : 0731-4289992-3
Website : www.trivenidiagnostic.com email : trivenidiagnostic@yahoo.co.in

Page 1 of 1

Mr. dinesh

Valve

Aortic root diameter	3.0cms	2.0-3.7cm<2.2cm/M2
Aortic valve opening	1.8cms	1.5-2.6cm
Right ventricular dimension	2.1cms	0.7-2.5cm<2.2cm/M2
Left atrium dimension	3.5cms	1.9-4.0cm<2.2cm/M2

Left ventricular ED dimension	4.3cms	3.7-5.6cm<3.2cm/M2
Left ventricular ES dimension	2.5cms	2.2-4.0cm
Intraventricular ED septal thickness	0.9cms	0.6-1.2 cm
Left vent ED PW thickness	0.9cms	0.5- 1.0 cm
IVS/LVPW	<N	<1.3

INDICES OF LEFT VENTRICLE FUNCTION:

Mitral E – septal separation	.5	cms <0.9 cm
LV Ejection Fraction	65%	60 %- 80%

COLOR DOPPER

	PV(m/sec)	PG(mm of Hg)	Regurgitation
AV	1.5	9.06	NIL
MV	0.8	2.75	NIL
TV	N	N	NIL
PV	1.15	5.25	NIL



Triveni Diagnostic Centre

Reg. No. : 77872 Visit ID : 0000082302
Patient Name : Mr. DINESH KUMAR VERMA
Age / Sex : 32 YEARS / MALE Order Date : 23/09/23 11:56AM
Ref. By : Dr. ARCOFEMI HEALTHCARE LIMITED Report Date : 23/09/23 01:02PM

X-RAY X-RAY CHEST PA

Trachea is central.

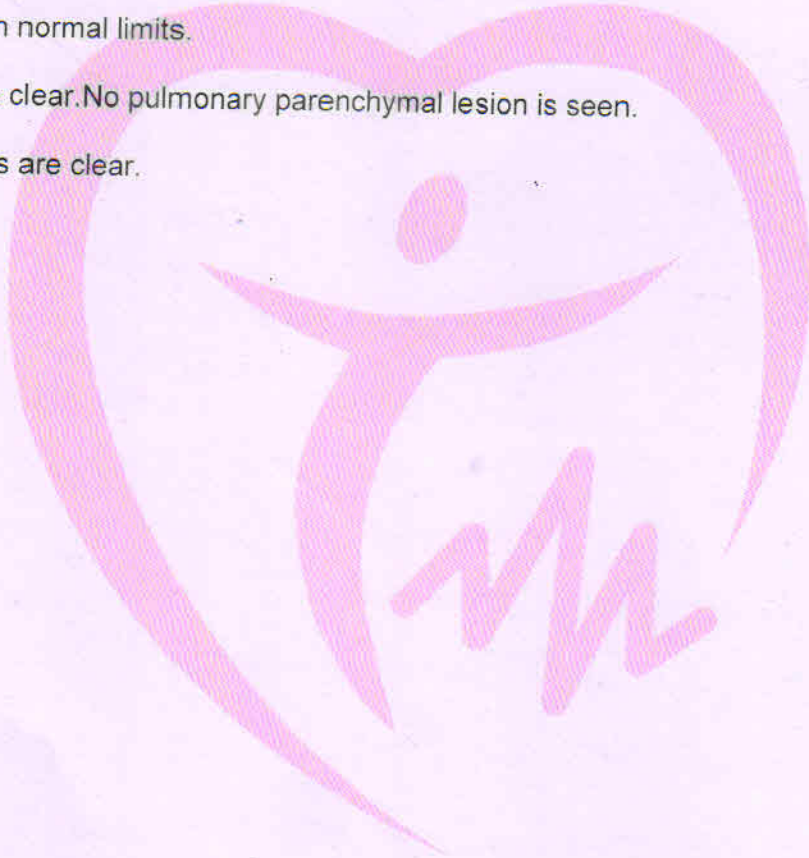
Bony rib cage and soft tissue wall of the thorax are normal.

Cardiac size is within normal limits.

Both lungs fields are clear. No pulmonary parenchymal lesion is seen.

Costo-phrenic angles are clear.

Kindly correlate.



DR. MUKESH DUBEY
(MBBS, DCP)

DR. VIJAY BHURIYA
MBBS DMRD

DR. AMIT SHANKHWAR
M.D. RADIO DIAGNOSIS

DR. P.S. TRIPATHI
M.D. (RADIO DIAGNOSIS)

DR. SANJAY YADAV
CONSULTANT MICROBIOLOGIST

Note: This report is not valid for medico legal purpose.
Address : Agrawal Plaza, B-7, HIG Main Road, Indore Ph. : 0731-4289992-3
Website : www.trivenidiagnostic.com email : trivenidiagnostic@yahoo.co.in