

PARASHAR HOSPITAL



(A Unit of Vijayesh Kumar & Sons Pvt Ltd.)
 MURLI MANOHAR COMPLEX, KHADI BHANDAR CHOWK, MUZAFFARPUR-842002 (BIHAR)
 Mob.: 6200471018, 7992247583 E-mail: parasharhospital@gmail.com

Reg. No.- 815

PATIENT NAME: KUMAR DHARMENDRA
 AGE/SEX: 32Y/Adult-M
 REF. BY DR.: DR. PARASAR HOSPITAL
 INVESTIGATIONS: REF. NO: 23/08/21CP/51
 TEST. DATE: 23/08/2021
 RPT. DATE: 23/08/2021
 UNIT

HAEMATOLOGY

CBC (COMPLETE BLOOD COUNT)

PARAMETER	VALUE	REF. RANGE	UNIT
RBC (Red Blood Cells)	4.18	3.8-6.5	M/ML
Hb (Haemoglobin)	13.4	12-16	gm/dl
HCT (Haematocrit)	38.2	37-54	%
MCV	91.4	76-96	fL
MCH	32.1	27-32	pg
MCHC	35.1	31-36	gm%
TC of WBC	7,200	4500-10500	/cumm

Neutrophil (seg)

PARAMETER	VALUE	REF. RANGE	UNIT
Neutrophil (seg)	62	50 - 70	%
Lymphocyte	36	20 - 40	%
Eosinophil	01	1 - 6	%
Monocyte	01	2 - 8	%
Basophil	00	0 - 1	%
Platelets	1.35	1.5-3.5	Lakh/cumm
Red Cell Distribution Width (RDW)	12.9	11.5-14.5	fL
ESR (DONE BY AUTO ANALYZER)	08	0-20	mm/hr

Blood Group

ABORH

"A" POSITIVE

BIOCHEMISTRY

LIPID PROFILE

PARAMETER	VALUE	REF. RANGE	UNIT
Plasma Glucose (Fasting)	86	70-110	mg/dl
Plasma Glucose (Post Prandial)	131	100-140	mg/dl
Serum Total Cholesterol	168	50-230	mg/dl
Serum HDL Cholesterol Direct	37	30-65	mg/dl

Dr. Sima Kumari
 Ph.D (Micro)
 M.Sc (Micro)
 Ex. Project Trainee
 AllMS New Delhi (Lab. Medicine Dept.)

Dr. R.K. Narayan
 M.D. (Path.)
 Regd. No. 14962

Date:

PARASHAR HOSPITAL

Reg. No.- 815

(A Unit of Vijayesh Kumar & Sons Pvt Ltd.)
 MURLI MANOHAR COMPLEX, KHADI BHANDAR CHOWK, MUZAFFARPUR-842002 (BIHAR)
 Mob.: 6200471018, 7992247583 E-mail : parashar.hospital@gmail.com

Date :

PATIENT NAME : KUMAR DHARMENDRA
 AGE/SEX : 32Y/Adult-M
 REF. BY DR. : DR. PARASAR HOSPITAL
 REF. NO : 23/08/21CP/51
 TEST. DATE : 23/08/2021
 RPT. DATE : 23/08/2021

INVESTIGATIONS	VALUE	REF. RANGE	UNIT
----------------	-------	------------	------

Serum Triglycerides	105	25-200	mg/dl
Serum LDL Cholesterol	110.00	85-130	mg/dl
Serum VLDL Cholesterol	21.00	7-32	mg/dl
TC/HDL Cholesterol Ratio	4.54	3.0-5.0	Ratio
LDL/HDL Ratio	2.97:1	1.5-3.5	Ratio

Serum Bilirubin

Total	0.7	0.1-1.2	mg%
Direct	0.3	0-0.3	mg%
Indirect	0.40	0-0.6	mg%

Serum SGPT (ALAT)

Serum SGPT (ALAT)	55	9-38	IU/L
-------------------	----	------	------

Serum SGOT (ASAT)

Serum SGOT (ASAT)	42	10-40	IU/L
-------------------	----	-------	------

Total Protein

Protein	7.3	6.0-8.0	g/dl
Albumin	4.4	3.7-5.3	g/dl
Globulin	2.90	2.3-3.6	g/dl
A:G Ratio	1.52:1	1.0-2.3	Ratio

RENAL FUNCTION TEST (RFT)

Serum Creatinine	0.8	0.7-1.4	mg/dl
Blood Urea Nitrogen (Bun)	11.21	7-21	mg/dl
Serum Uric Acid	5.0	3.6-7.7	mg/dl
Serum Calcium (Total)	9.6	8.7-11.0	mg/dl
Blood Urea	24	13-45	mg/dl

Gamma Glutamyl transferase (GGT)

Gamma Glutamyl transferase (GGT)	33	9-58	U/L
----------------------------------	----	------	-----

Dr. Sima Kumari
 Ph.D (Micro)
 M.Sc (Micro)
 Ex. Project Trainee
 AIIMS New Delhi (Lab. Medicine Dept.)

Dr. R.K. Narayan
 M.D. (Path)
 Regd. No. 14962

PARASHAR HOSPITAL



(A Unit of Vijayesh Kumar & Sons Pvt Ltd.)
 MURLI MANOHAR COMPLEX, KHADI BHANDAR CHOWK, MUZAFFARPUR-842002 (BIHAR)
 Mob.: 6200471018, 7992247583 E-mail : parasharhospital@gmail.com

Reg. No.- 815

Date:

PATIENT NAME : KUMAR DHARMENDRA
 AGE/SEX : 32Y/Adult-M
 REF. BY DR. : DR. PARASAR HOSPITAL
 INVESTIGATIONS

REF. NO	TEST. DATE	RPT. DATE	REF. RANGE	VALUE	UNIT
23/08/21CP/51	23/08/2021	23/08/2021	135-150	143.1	m mol/L
			3.5-5.1	4.4	m mol/L
			97-111	104.5	m mol/L

SERUM ELECTROLYTE
 Sodium (Na) +
 Potassium (K) +
 Chloride (Cl) -

Dr. Sima Kumari
 Ph.D (Micro)
 M.Sc (Micro)
 Ex. Project Trainee
 AIIMS New Delhi (Lab. Medicine Dept.)

Dr. R.K. Narayan
 M.D. (Path.)
 Regd. No. 14962

Dr. Sima Kumari
Ph.D (Micro)
M.Sc (Micro)
Ex. Project Trainee
AIIMS New Delhi (Lab. Medicine Dept.)

Dr. R.K. Narayan
M.D. (Path)
Regd. No. 14962

HbA1c 5.1
4.2-6.0
Good Diabetic Control 5.5 - 6.8 Fair Control 6.8 - 7.6 Poor Control Above 7.6

INVESTIGATIONS	VALUE	REF. RANGE	UNIT
PATIENT NAME : KUMAR DHARMENDRA			
AGE/SEX : 32Y/Adult-M			
REF. BY DR. : DR. PARASAR HOSPITAL			
REF. NO : 23/08/21CP/51			
TEST. DATE : 23/08/2021			
RPT. DATE : 23/08/2021			

Date :

(A Unit of Vijayesh Kumar & Sons Pvt Ltd.)
MURLI MANOHAR COMPLEX, KHADI BHANDAR CHOWK, MUZAFFARPUR-842002 (BIHAR)
Mob.: 6200471018, 7992247583 E-mail : parashar.hospital@gmail.com

PARASHAR HOSPITAL

Reg. No.- 815



PARASHAR HOSPITAL

Reg. No.-815



(A Unit of Vijayesh Kumar & Sons Pvt Ltd.)

MURLI MANOHAR COMPLEX, KHADI BHANDAR CHOWK, MUZAFFARPUR-842002 (BIHAR)

Mob.: 6200471018, 7992247583 E-mail: parashar.hospital@gmail.com

Date:

PATIENT NAME : KUMAR DHARMENDRA	REF. BY DR. : DR. PARASAR HOSPITAL
AGE/SEX : 32Y/Adult-M	RPT. DATE : 23/08/2021
TEST. DATE : 23/08/2021	REF. RANGE : 23/08/2021
REF. NO : 23/08/21CP/51	UNIT

URINE ROUTINE

Physical Examination	Colour	Pale Straw
Appearance	Specific Gravity	1.030
Chemical Examination	pH	Acidic
	Sugar	Negative
	Albumin	Negative
Microscopic Examination	Crystal	Nil
	RBC	Nil
	WBC	0-1/HPF
	Epithelial cells	A Few
	Granular Cast	Absent
	Bacteria	Absent
	Cast	Absent
	Other	Nil

Dr. R.K. Narayan

M.D.(Path.)
Regd.No.14962

Dr. Sima Kumari

Ph.D (Micro)

M.Sc.(Micro)

EX. Project Trainee

AIIMS New Delhi(Lab.Medicine Dept.)

PARASHAR HOSPITAL



(A Unit of Vijayesh Kumar & Sons Pvt Ltd.)

MURLI MANOHAR COMPLEX, KHADI BHANDAR CHOWK, MUZAFFARPUR-842002 (BIHAR)

Mob.: 6200471018, 7992247583 E-mail: parashar.hospital@gmail.com

Reg. No.- 815

Date:

PATIENT NAME : KUMAR DHARMENDRA
 AGE/SEX : 32Y/Adult-M
 REF. BY DR. : DR. PARASAR HOSPITAL
 RPT. DATE : 24/08/2021
 TEST. DATE : 24/08/2021
 REFF. NO : 24/08/21CP/57
 UNIT

ROUTINE

Stool Examination.

COLOUR	Yellow
Consistency	Semt Solid
Reducing Sugar	Nil
Mucus	Nil
Epithelial cells	Nil
* Occult Blood	Negative
Parasites	Not Found
RBC	Nil
Undigested Food Particles	Absent
WBC	Nil
CYSTS	Nil
OVA	Nil

Dr. Sima Kumari
 Ph.D (Micro)
 M.Sc (Micro)
 Ex. Project Trainee
 AIIMS New Delhi (Lab. Medicine Dept.)

Dr. R.K. Narayan
 M.D. (Path.)
 Regd. No. 14962



PARASHAR HOSPITAL

(A Unit of Vijayesh Kumar & Sons Pvt Ltd.)

MURLI MANOHAR COMPLEX, KHADI BHANDAR CHOWK, MUZAFFARPUR-842002 (BIHAR)

Mob.: 6200471018, 7992247583 E-mail : parashar.hospital@gmail.com

Kumar Dharmendra

Date : 24/08/21

32/M, Sitamadhhi' BP 122/80

Go - Regular checkup

E/E - chest - clear
hr sp / v

Haemogram - NAD

[Signature]
24/08/21



ANUPAM

ULTRASOUND & COLOR DOPPLER CENTRE

ROAD NO. 1, JURAN CHAPRA, MUZAFFARPUR - 842 001
Phones : 0621 - 2224133, 9525971756, E-mail : anupct1@gmail.com

Dr. Ajay Jaiswal
MBBS, MRSH

Dr. A. K. Shah
PGDM (Sonologist)

Thanks for referral

U/S Reg. No- 07/2001

Reg. No- BMR- 16156

Name : Mr. Dharmendra Kumar
Part scanned : Whole Abdomen
Refd. by Dr. : Parashar Hospital
Muz.

Age/ Sex : Y/M
ID No - : 396
Date/ Time : 23.08.2021

USG OF WHOLE ABDOMEN REPORT

Liver is normal in size, shows fatty infiltration echotexture. There is no focal lesion or dilatation of intrahepatic biliary radicles, portal vein is normal.

Gall bladder shows normal wall thickness and echofree lumen.

C.B.D. is normal in caliber.

Pancreas is normal in size, shape and echotexture.

Spleen is normal in size .

There is no abdominal lymphadenopathy seen.

Both kidneys are normal in size , shape and position. The C.M. differentiation is well maintained and there is no hydronephrosis.

No evidence of ascites/ pleural effusion.

Urinary bladder is smooth in outlined. There is no calculus within.

No collection or mass lesion seen in RIF.

OPINION: Fatty Liver.

On request
Not valid for medico-legal purpose.


Sonologist



Thanks for referral

ANUPAM

ULTRASOUND & COLOR DOPPLER CENT

ROAD NO. 1, JURAN CHAPRA, MUZAFFARPUR - 842
Phones : 0621 - 2224133, 9525971756, E-mail : anupct1@gmail.com

Dr. Ajay Jaiswal
MBBS, MRSH

Dr. A. K
PGDM (Sor

U/S Reg. No- 07/2001

Reg. No- BMR- 16156

Name	: Mr. Dharmendra Kumar	Age/ Sex	: Y/M
Part scanned	: Echocardiography	ID No -	: 397
Refd. by Dr.	: Parashar Hospital Muz.	Date -	: 23.08.2021

ECHOCARDIOGRAM REPORT

2D echo / color doppler studies done in parasternal long and short axis, apical and subcostal view.

The aortic valves appears normal. There is no aortic regurgitation. The aorta appears normal and its dimension is 2.84cm. Aortic valve opening dimension 1.90cm in begning and 1.88 cm at end. The doppler velocity of aortic valve is 0.92m/sec. The mitral valves appears normal . There is no mitral regurgitation, the velocity of mitral valve is 0.84m/sec and valve leaflets excursion (D - DE -1.42cm, and V -EF - 0.12m/sec).

Tricuspid valves are normal. There is no tricuspid regurgitation. The doppler velocity of TV is 0.68m/sec.

Pulmonary valve is normal.

The left atrium appears normal and its dimension is 3.96 cm. There is no atrial fibrillation seen.

Left ventricle is normal and the dimention of L.V.C is 4.53cm at the end of diastole . Left ventricular E/F at rest is about 62%.

Right ventricle is normal and its dimention is 3.48 cm. Right atrium is normal . No VSD or ASD seen .

No segemental wall motion abnormality are seen at rest .

There is no intracardiac thrombi or clot seen .

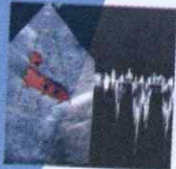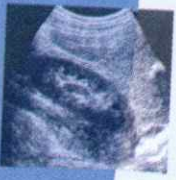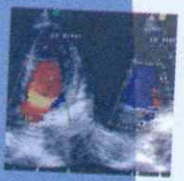
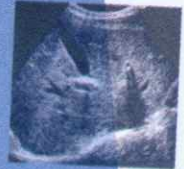There is no pericardial effusion seen.

On TVI the mean velocity of early systole S early diastole E and Late diastole A wave at basal ant and basal lat wall appears normal

M mode measurement : IVSD -0.98cm, LVIDd - 4.53cm, LVPWd - 0.86cm, IVSs - 1.23cm, LVIDs - 3.00cm, LVPWs -1.15cm, EDV- 93.71ml, SV - 58.61ml; ESV-35.10ml, EF - 62.54%.

OPINION - Normal Study

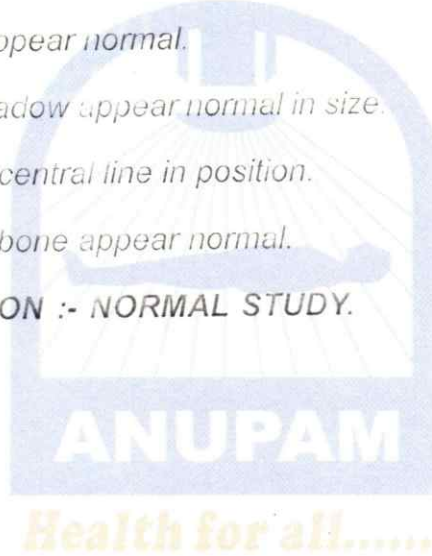
Sonologist



Name	: Dharmendra Kumar	Age/ Sex	: Y/M
Part scanned	: X-Ray Chest PA View	Date/Time	: 23.08.2021
Refd. by Dr.	: Parashar Hospital Muz.	ID No-	: 1507

X - RAY REPORT

Mid expiratory phase film.
Lung fields appear clear on both side.
Both CP angles is clear.
Both hila appear normal.
Cardiac shadow appear normal in size.
Trachea is central line in position.
Visualized bone appear normal.
IMPRESSION :- NORMAL STUDY.



Please correlate clinically.

On request
Not valid for medico-legal purpose.


Dr. Abhitesh Kumar
MBBS; DMRD.
Radiologist.

