



Reg. No. NH/6333/DEC-2017

GREEN CITY HOSPITAL

Near V-Mart, DIG Bungalow, Berasia Road, Bhopal
Ph.: 0755-2733323

AN ISO 2015-9001 & NABH CERTIFIED HOSPITAL



Pt Name = *Pratima Bhargava* Age: *29y/f*
Date = *21/04/22*

B/P = 100/60

Height = 162 cm

Weight = 76

Pulse = 72/m

SpO2 = 98%

ENT = } WNL

Eye = } G/G

Chest = WNL

Teeth & Gums = Healthy / Normal

SKIN = Normal / Integrated.

CVS = S1, S2 ⊕

Temp = AFB.





GREEN CITY HOSPITAL

Near V-Mart, DIG Bungalow, Berasia Road, Bhopal

AN ISO 2015-9001 & NABH CERTIFIED HOSPITAL

Reg. No. NH/6333/DEC-2017



PATHOLOGY REPORT

Name : Mrs. Garima Bhargav Corp Age : 29 Years Sex : Female
Advised By : GREEN CITY HOSPITAL Lab No. : OPD / 3 Date & : 21-Apr-2022
Time : 10:06 am

LIPID PROFILE

Test Performed	Value Observed	Reference Range
S. Cholesterol (Total)	187.6mg/dl	Desirable Level : < 200 mg/dl Borderline level : 200-239 mg/dl High Level > 240 mg/dl
S. Triglycerides	118.4mg/dl	Desirable level : < 150 mg/dl Borderline level : 150 - 200 mg/dl High Level: > 200 mg/dl
HDL Cholesterol	43.6 mg/dl	35 - 70 mg/dl
LDL Cholesterol	120.32	Desirable Level:< 130 mg/dl Borderline level:130-180mg/dl High level: >180 mg/dl
VLDL Cholesterol	23.68	Desirable level:< 30 mg/dl Borderline level:30-45 mg/dl High level: > 45 mg/dl

Dr. Manal Asraf Ali

MBBS.DCP,DNB

Reg No.19938

Technologist

Please Correlate clinically as well as with other investigative findings. This report is not valid for medico legal purpose

For Emergency / Ambulance Service Contact No.: 0755-2733323



GREEN CITY HOSPITAL

Near V-Mart, DIG Bungalow, Berasia Road, Bhopal
AN ISO 2015-9001 & NABH CERTIFIED HOSPITAL

Reg. No. NH/6333/DEC-2017



PATHOLOGY REPORT

Name : Mrs. Garima Bhargav Corp

Age : 29 Years Sex : Female

Advised By : GREEN CITY HOSPITAL

Lab No. : OPD / 3

Date & : 21-Apr-2022

Time : 10:05 am

BIOCHEMISTRY

<u>Test Performed</u>	<u>Value Observed</u>	<u>Reference Range</u>
Blood Glucose(Fasting)	: 117.8 mg/dl	70 - 110 mg/dl
Blood Glucose (Post-Prandial)	: 145.6mg/dl	upto 140 mg/dl
Serum Creatinine	: 0.78mg/dl	0.50 - 1.0
Serum Uric Acid	: 5.6	Male : < 7.0 mg/dl Female : < 6.0 mg/dl

Dr. Manal Asraf Ali
MBBS,DCP,DNB
Reg No.19938

Technologist

Please Correlate clinically as well as with other investigative findings. This report is not valid for medico legal purpose.

For Emergency / Ambulance Service Contact No.: 0755-2733323



GREEN CITY HOSPITAL

Near V-Mart, DIG Bungalow, Berasia Road, Bhopal

AN ISO 2015-9001 & NABH CERTIFIED HOSPITAL

Reg. No. NH/6333/DEC-2017



PATHOLOGY REPORT

Name : Mrs. Garima Bhargav Corp Age : 29 Years Sex : Female
Advised By : GREEN CITY HOSPITAL Lab No. : OPD / 3 Date & : 21-Apr-2022
Time : 10:05 am

GGTP

Test Performfed	Value Observed	Reference Range
Gamma GT	39.5	10 - 45 U/L

Dr. Manal Asraf Ali

MBBS,DCP,DNB

Reg No.19938

Technologist

Please Correlate clinically as well as with other investigative findings. This report is not valid for medico legal purpose

For Emergency / Ambulance Service Contact No.: 0755-2733323



GREEN CITY HOSPITAL

Near V-Mart, DIG Bungalow, Berasia Road, Bhopal
AN ISO 2015-9001 & NABH CERTIFIED HOSPITAL

Reg. No. NH/6333/DEC-2017



PATHOLOGY REPORT

Name : Mrs. Garima Bhargav Corp Age : 29 Years Sex : Female
Advised By : GREEN CITY HOSPITAL Lab No. : OPD / 3 Date & : 21-Apr-2023
Time : 10:06 am

URINE ROUTINE MICROSCOPIC EXAMINATION

Test Performed	Value Observed
<u>Physical Examination</u>	
Volume	20 ml
Colour	Pale Yellow
Appearance	Clear
Reaction (pH)	Acidic
<u>Chemical Examination</u>	
Albumin	Nil
SUGAR	Nil
<u>Microscopic Examination</u>	
PUS(WBC) Cells	5-6 /hpf
RBC	Nil /hpf
Epithelial Cells	2-3 /hpf
Casts	Absent
Crystals	Absent
Bacteria	Absent

Dr. Manal Asraf Ali

MBBS, DCP, DNB

Reg No. 19038

Technologist

Please Correlate clinically as well as with other investigative findings. This report is not valid for medico legal purpose.

For Emergency / Ambulance Service Contact No.: 0755-2733323



GREEN CITY HOSPITAL

Near V-Mart, DIG Bungalow, Berasia Road, Bhopal

AN ISO 2015-9001 & NABH CERTIFIED HOSPITAL

Reg. No. NH/6333/DEC-2017




PATHOLOGY REPORT

Name : Mrs. Garima Bhargav Corp Age : 29 Years Sex : Female
Advised By : GREEN CITY HOSPITAL Lab No. : OPD / 3 Date & : 21-Apr-2022
Time : 10:06 am

STOOL EXAMINATION

Test Performed	Value Observed
<u>Physical Examination</u>	
Colour	Brown
Consistency	Soft
Mucus	Trace
<u>Chemical Examination</u>	
Reaction	Acidic
Occult blood	Negative
<u>Microscopic Examination</u>	
Pus cells	Absent /hpf /hpf
RBC	Absent /hpf /hpf
Food Particles	Few+ /hpf /hpf
Fat Globules	Absent


Dr. Manal Asraf Ali
MBBS, DCP, DNB
Reg No. 19838

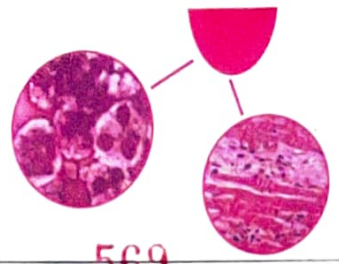

Technologist

Please Correlate clinically as well as with other investigative findings. This report is not valid for medico legal purpose

For Emergency / Ambulance Service Contact No.: 0755-2733323

FOCUS PATHOLOGY

SPECIALITY : Histopathology, Cytology, Bone marrow, Haematology
(A Complete Computerized Automated Lab Since- 2017)



Patient Name : MRS GARIMA BHASGAV
Age & Sex : 29 Years / Female
Referred By : GREEN CITY HOSPITAL

569
LAB No. : 0000365
Registration Date : 21/04/2022 07:34 pm
Report Date : 21/04/2022 08:06 pm

BIOCHEMISTRY

TEST

HbA1c

RESULTS

REFERENCE RANGE

Glycosylated Haemoglobin % (Hb A1c) : 5.0

Normal : 4.2 to 6.2

Good control: 5.5 to 6.8

Fair control : 6.8 to 7.6

Poor control : > 7.6 Unit : %

Mean Plasma Glucose : 96.8

NOTES:

1. The HbA1c test shows your average blood sugar for last 3 months.
2. The HbA1c test does not replace your day-to-day monitoring of blood glucose. Use this test result along with your daily test results to measure your overall diabetes control.

How does HbA1c works?

The HbA1c test measures the amount of sugar that attaches to protein in your red blood cells. RBCs live for about 3 months, so this test shows your average blood sugar levels during that time. Greater the level of sugar & longer it is high, the more sugar that will attach to RBCs.

Why is this test so important?

Research studies demonstrated that the closer to normal your HbA1c level was, the less likely your risk of developing the long-term complications of diabetes. Such problems include eye disease, nerve damage, heart and blood vessel disease and kidney problems.

Who should have the HbA1c test done?

Everyone with diabetes can benefit from taking this test. Knowing your HbA1c level helps you and your doctor decide if you need to change your diabetes management plan.

How often should you have a HbA1c test?

You should have this test done when you are first diagnosed with diabetes. Then at least twice a year if your treatment goals are being met & blood glucose control is stable.

More frequent HbA1c testing (4 times / year) is recommended if your therapy has been recently changed or if you are not

Barcode :



***** End Of Report *****



Jaykiran

Dr. Jay Kiran Verma (MBBS, DNB)
Sr. Consultant Pathologist (Reg. No. 5659)
National Hospital, Bhopal
Formerly-
-Apollo Hospitals, Hyderabad

◆ 24 Hour Services ◆ Free Sample Collection Home and Office Facility Available

Shop No.1, Plot No.25, Next to IDBI Bank, Main Road, C-Sector, Near Beema Hospital, Indrapuri, Raisen Road, Bhopal 462022
Phone : 0755 - 4245014, +91-9630904774, +91 8839402126 Email | focusin.report@gmail.com

PATIENT'S NAME: MRS. GARIMA
REF. BY: GREEN CITY HOSPITAL

Date: 21.04.2022

AGE: 24Y

SEX: FEMALE

Ultrasonography : Whole Abdomen

Liver: Appears normal in size measures 13.2 cm in long axis in mid clavicular line and shows mildly raised hepatic echotexture with normal visualization of intrahepatic vessel walls. Margins are smooth and regular. Intra and extra hepatic biliary and vascular channels are normal. No evidence of any focal or diffuse mass lesion seen. Gaseous distension of bowel loops noted.

Gall Bladder: Reveal a clear anechoic lumen. Its wall of normal thickness. No pericholecystic pathology seen. CBD & PV are of normal calibre.

Right Kidney: Normal in size, shape & echotexture measures 10.2 x 4.1 cm. Cortical echotexture appears to be normal. Cortico-medullary differentiation is maintained. No hydronephrosis, calculus or scarring seen.

Left Kidney: Normal in size, shape & echotexture measures 10.2 x 4.1 cm. Cortical echotexture appears to be normal. Cortico-medullary differentiation is maintained. No hydronephrosis, calculus or scarring seen. **Spleen:** Is normal in size, shape and echotexture.

Pancreas: Appear to be normal in shape, size & echotexture. Pancreatic duct is not dilated.

Urinary Bladder: Is central smooth in contour and reveal a clear lumen. Their walls are of normal thickness.

Uterus: Is anteverted and normal in size shape and echotexture measures 7.2 x 4.2 x 3.5 cm. Endometrial echo is in midline measures 10 mm. Cervix appears normal.

Right Ovary: Visualized normal in size, shape and echotexture.

Left Ovary: Visualized normal in size, shape and echotexture.

- No evidence of obvious adnexal mass lesion is seen.
- No evidence of any free fluid/lymphadenopathy.
- No evidence of bowel wall thickening noted.
- There is e/o increased gap between bilateral rectus abdominals muscle with approximate distance 6-6.5 cm with protrusion of intraabdominal contents trough s/o diastasis of rectus muscle.

Impression: USG Study Reveals:

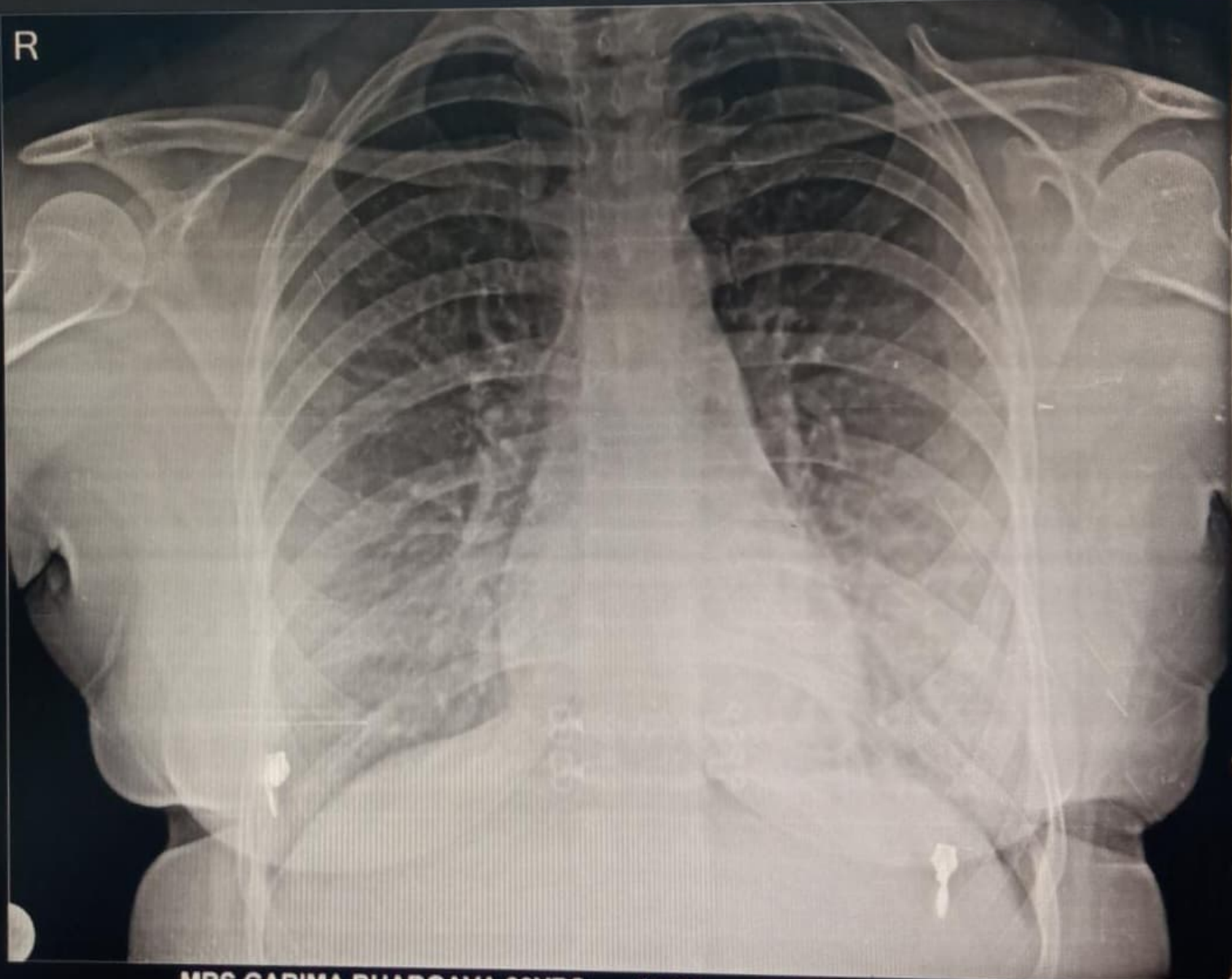
- **Normal sized liver with grade – I fatty infiltration and Gaseous distension of bowel loops.**
- **Increased gap between bilateral rectus abdominals muscle with approximate distance 6-6.5 cm with protrusion of intraabdominal contents trough s/o diastasis of rectus muscle.**



Dr. Ritesh Kumawat
MBBS, DMRD, DNB (Radio Diagnosis)
Consultant Radiologist



R



MRS GARIMA BHARGAVA 29YRS.... 14111 CHEST PA 21-Apr-22
GREEN CITY HOSPITAL, D.I.G. BUNGLOW, BHOPAL

2022-04-21 11:03:48

BIONARCH MEDITECH

6 Channel + 1 Rhythm Report

Hosp:

Prescribed by:

ID :

Name: *Ghosime*

Age : 0 years *29y/f*

Sex : Female

H : 0 cm / W : 0 kg

Heart Rate: 84 bpm

PR/RR Int.: 128/714 ms

QRS Dur: 108 ms

QT/QTc: 420/496 ms

P-R-T axes: 48 67 -18

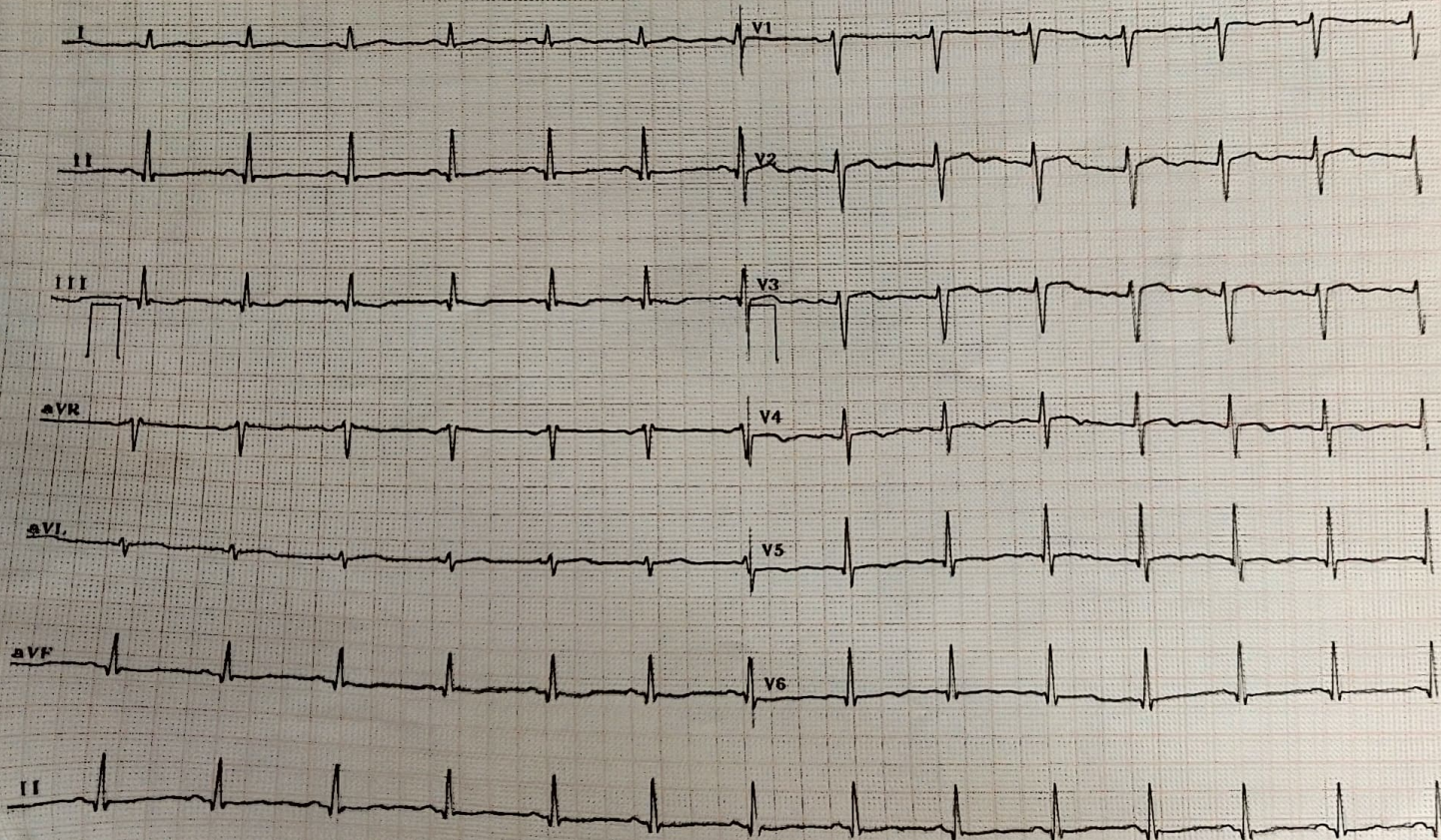
SV1/RV5/R+S: 0.65/0.92/1.57mV [Moderately Abnormal ECG]

** Analysis Result ** (To be finally confirmed by physician)

Normal Sinus Rhythm

Normal Axis

Prolonged QT






बैंक ऑफ़ बड़ोदा
Bank of Baroda



नाम
Name **MR. RAHUL BHARGAVA**

कर्मचारी कूट क्र.
E. C. No. **106885**


जारीकर्ता प्राधिकारी
Issuing Authority


धारक के हस्ताक्षर
Signature of Holder

आयकर विभाग
INCOME TAX DEPARTMENT



भारत सरकार
GOVT. OF INDIA



स्थायी लेखा संख्या कार्ड
Permanent Account Number Card
BQDPB8414P



नाम / Name
GARIMA BHARGAVA

पिता का नाम / Father's Name
AKHIL KUMAR BHARGAVA

जन्म की तारीख
Date of Birth
14/08/1993

31082019

PAN Application Digitally Signed, Card
Not Valid unless Physically Signed.



भारतीय विशिष्ट पहचान प्राधिकरण

भारत सरकार

Unique Identification Authority of India
Government of India

नामांकन क्रम / Enrollment No.: 1468/10455/03072

To
गरिमा भार्गव
Garima Bhargava
W/O Rahul Bhargava
D-56 Shahanshah Garden
Huzur
Govindpura
Huzur Bhopal
Madhya Pradesh 462023
9425453947

14/02/2013

40837221



MD408372216FH



आपका आधार क्रमांक / Your Aadhaar No. :

6207 7286 3413

मेरा आधार, मेरी पहचान



भारत सरकार

Government of India



गरिमा भार्गव
Garima Bhargava
जन्म तिथि / DOB : 14/08/1993
महिला / Female



6207 7286 3413

मेरा आधार, मेरी पहचान